

# Outcome of peroral endoscopic myotomy in achalasia cardia: Experience with a new triangular knife

Zaheer Nabi, Mohan Ramchandani, Radhika Chavan, Rakesh Kalapala, Santosh Darisetty<sup>1</sup>, D. Nageshwar Reddy  
Consultant Gastroenterologist, <sup>1</sup>Consultant Anaesthesiologist, Department of Gastroenterology, Asian Institute of Gastroenterology, Hyderabad, Telangana, India

## Abstract

**Background and Aim:** Peroral endoscopic myotomy (POEM) is a technically demanding procedure. Recently, a new triangular knife with integrated water jet function (TTJ) has been introduced. The present study was aimed to analyze and compare the operating time, efficacy, and adverse events (AEs) between the conventional (TT knife) and new knife (TTJ).

**Patients and Methods:** All patients with achalasia cardia (AC) who underwent POEM between August 2015 and November 2016 were analyzed retrospectively. Operating time (OT), technical success, and AEs were assessed and compared between TT and TTJ knife.

**Results:** A total of 193 patients with AC underwent POEM during the specified period. Both groups had equivalent number of different subtypes of AC (I, II, and III). There was no difference in technical success between the two groups (TT, 99% vs TT, 98.9%). OT was significantly less in the TTJ group as compared to TT group ( $53.8 \pm 15.2$  vs  $66.26 \pm 19.2$ ;  $P = 0.0001$ ). On subanalysis, OT taken for submucosal tunneling was significantly less with TTJ knife ( $34.6 \pm 10.1$  vs  $45.83 \pm 14.80$ ), whereas OT was similar for myotomy and clipping in both the groups. Significantly fewer use of coagulation forceps and exchanges of accessories were required in TTJ knife group ( $2.92 \pm 1.77$  vs  $10.5 \pm 3.58$ ;  $P = 0.0001$ ). There were no major AEs. Minor AEs were noted in 21.5% and 31% of patients in TTJ and TT knife groups, respectively.

**Conclusion:** New triangular knife reduces procedure time and technical difficulty with POEM. POEM is an efficacious treatment for achalasia and can be safely executed in an endoscopy unit.

**Keywords:** Achalasia, endoscopy, peroral endoscopic myotomy

**Address for correspondence:** Dr. Zaheer Nabi, Consultant gastroenterologist, Asian institute of Gastroenterology, Hyderabad, Telangana, India.  
E-mail: zaheernabi1978@gmail.com

## INTRODUCTION

Achalasia cardia (AC) is a primary motility disorder of esophagus defined by aperistalsis and inability of gastroesophageal junction to relax.<sup>[1]</sup> The standard of endoscopic management for AC has been graded

pneumatic balloon dilatation (PBD) for several decades now. However, multiple sessions of PBD are often required. With the introduction of peroral endoscopic myotomy (POEM), the endoscopic armamentarium for AC has been strengthened.<sup>[2,3]</sup> Since its initial description in

Access this article online	
Quick Response Code:	Website: www.saudijgastro.com
	DOI: 10.4103/sjg.SJG_361_17

This is an open access article distributed under the terms of the Creative Commons Attribution-NonCommercial-ShareAlike 3.0 License, which allows others to remix, tweak, and build upon the work non-commercially, as long as the author is credited and the new creations are licensed under the identical terms.

**For reprints contact:** reprints@medknow.com

**How to cite this article:** Nabi Z, Ramchandani M, Chavan R, Kalapala R, Darisetty S, Reddy DN. Outcome of peroral endoscopic myotomy in achalasia cardia: Experience with a new triangular knife. Saudi J Gastroenterol 2018;24:18-24.

2008, multiple studies have concluded the safety and short to mid-term efficacy of POEM in AC.<sup>[4-8]</sup>

In contrast to PBD and laparoscopic Heller's myotomy, POEM is relatively new.<sup>[2]</sup> Therefore, the techniques and devices related to POEM procedure are still evolving. Some of the variation in techniques include orientation of myotomy (anterior or posterior), length of myotomy (short vs long), simultaneous tunneling and myotomy, and partial vs full thickness myotomy.<sup>[9-12]</sup> The devices used for POEM are more homogenous except for the choice of knife for submucosal dissection and myotomy. Most operators use one of the two commercially available knives, namely triangular tip (TT) knife and hybrid knife.<sup>[13,14]</sup> In addition to these, the use of stag beetle knife and needle knife with spherical tip (FlushKnife BT, DK2618JB; Fujifilm, Tokyo, Japan) has also been described.<sup>[15,16]</sup> The difference in the choice of knife is mainly based on operator's preference. Recently, a new knife equipped with water jet function (TTJ knife) has been introduced.<sup>[17]</sup> The utility of this knife has been recently demonstrated in pediatric patients with AC.<sup>[18]</sup> The safety, efficacy and ease of performing POEM using TTJ knife has not been comprehensively assessed in adult patients with AC.

In this study, we analyzed the operative time (OT), adverse events (AE), and efficacy of POEM when performed with new knife.

## PATIENTS AND METHODS

The patients diagnosed with AC who underwent POEM between August 2015 to November 2016 were included in the analysis. The study was approved by the institutional review board.

### Diagnosis of achalasia cardia

All patients underwent standard battery of tests used for diagnosing AC including high resolution manometry (HRM), timed barium swallow (TBS), and gastroscopy. The subtyping of AC (type I, II, III) was performed by HRM using Chicago classification v3.

### Operative time and intraoperative events

Operative time (OT) was measured for all the patients. Total OT was defined as the time taken from submucosal lifting injection to the complete closure of mucosal incision with clips. Separate analyses of time taken for submucosal tunneling, myotomy, and clipping was also done. The requirement of exchange of accessories and use of coagulation forceps during POEM procedure were calculated.

### Adverse events

Intraoperative AEs including bleeding, mucosal perforations, and gas-related AEs were recorded. AEs were defined as those requiring an intervention, temporarily stoppage of procedure, and prolongation of hospital stay. Major bleeding episodes were defined as those requiring blood transfusion. Minor bleeding events controlled with coagulation forceps and gas-related events not requiring any intervention were not considered as AEs. Fluoroscopy was utilized in cases of significant abdominal distension perceived clinically to identify gas related events and differentiate capno-peritoneum from retroperitoneal CO<sub>2</sub>.

### Clinical outcome measures

Technical success was defined as successful completion of the procedure. Clinical success was defined as Eckardt score  $\leq 3$ .

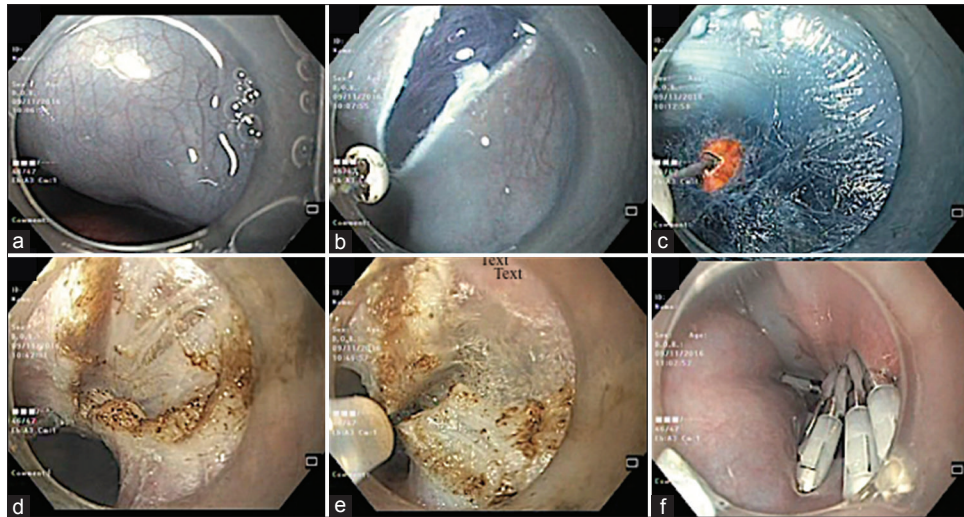
### Procedure technique

All cases of POEM were performed by three experienced operators (DNR, ZN, MR) in the endoscopy unit at our center. An anterior (1–2 O'clock) or posterior approach (5–6 O'clock) to POEM was used depending on the esophageal anatomy and history of prior Heller's myotomy. The technique of POEM procedure has been described in detail in our previous studies.<sup>[6,19]</sup> An important modification in our technique is regarding the method of mucosal incision.<sup>[20]</sup> After creating a mucosal bleb (saline with indigo-carmin), a small mucosal incision was made. An insulated tip knife was used to enlarge the incision. Subsequently, entry into the tunnel, submucosal tunneling, and myotomy were performed in the usual manner. Myotomy was selectively circular in the upper part and full thickness in lower part of the tunnel [Figure 1].


### Details of two triangular knives used

Conventional TT knife (TriangleTipKnife, KD-640L, Olympus, Japan) has a cutting knife length and diameter of 4.5 × 0.4 mm. The triangular tip has a length and thickness of 0.7 mm and 0.4 mm, respectively [Figure 2]. The knife was exchanged with a spray catheter for submucosal injection with saline mixed with indigo-carmin dye. The settings on the electrosurgical unit (VIO300D; ERBE, Tübingen, Germany) during dissection and myotomy were identical, i.e., ENDO CUT Q at 50 W, effect 3.

TT Knife J (TriangleTipKnife J, KD-645L, Olympus, Japan) has a triangular tip length and thickness of 0.4 mm and 0.3 mm, respectively. The cutting knife length and diameter are similar to the conventional TT knife i.e., 4.5 × 0.4 mm [Figure 2]. TTJ knife is equipped with a water jet nozzle for submucosal injection without



**Figure 1:** Technique of peroral endoscopic myotomy (using new knife) – (a) submucosal injection, (b) enlargement of mucosal incision with IT knife, (c) submucosal tunneling, (d) selective circular myotomy, (e) full thickness myotomy, (f) closure of mucosal incision with clips



**Figure 2:** Triangular tip knife – (a) conventional triangular tip knife and (b) triangular tip knife with water jet function

exchanging the device [Figure 3]. The settings on electro-surgical unit with this knife were - ENDO CUT Q at 50 W, effect 1 for both dissection and myotomy.

### Statistical analysis

The outcomes are described as mean  $\pm$  standard deviation for quantitative variables and percentages for categorical variables. *t*-test was used to compare two means of continuous variables. Fisher exact test was used for categorical variables. Two-sided *P* value  $<0.05$  was considered statistically significant.

### RESULTS

A total of 193 patients with AC underwent POEM at our center from August 2015 to November 2016. Three operators with a cumulative experience of 270 cases performed all the POEM procedures.

Of the 193 cases, conventional TT knife was used in 100 patients and TTJ knife in 93 patients. Mean age of patients and proportion of patients with different subtypes of AC were equal in both the groups. Type II AC was the most common subtype (TTJ, 68.8% vs TT, 61%), followed by type I (TTJ, 24.7% vs TT, 31%) and type III AC (TTJ, 6.5% vs TT, 7%). Pre-POEM Eckardt scores and LES pressures were also comparable in both the groups. Overall, 72 (37.3%) patients had history of prior treatment including pneumatic balloon dilatation (30.56%), Heller's myotomy (3.1%), both (1.5%), botulinum toxin injection (1%), and POEM (1.5%) [Table 1].

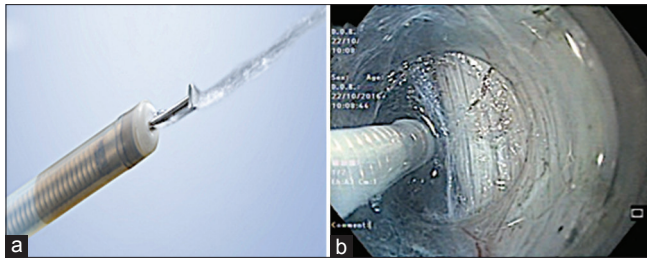
### Intraoperative details

POEM was performed via an anterior approach in majority (TTJ, 65.6% and TT, 61%) of patients. The length of total, esophageal, and gastric myotomies was equivalent in the two groups [Table 2].

### Operative time

The mean OT was significantly lower in the TTJ knife group ( $53.8 \pm 15.2$  vs  $66.26 \pm 19.18$  min;  $P = 0.0001$ ). On sub-analyses, the mean time taken for submucosal tunnelling was significantly less with TTJ knife ( $34.6 \pm 10.1$  vs  $45.83 \pm 14.80$ ;  $P = 0.0001$ ). However, time taken during myotomy and clipping was equal in both the groups [Table 2].

The mean frequency of accessory exchanges ( $2.92 \pm 1.77$  vs  $10.5 \pm 3.58$ ;  $P = 0.0001$ ) and the use of coagulation forceps was significantly less in the TTJ knife group [Table 2]. OT was equivalent between anterior and posterior approach to POEM in both the groups [Table 3].



**Figure 3:** (a) Triangular tip knife with integrated water jet function; (b) submucosal injection with new triangular tip knife

**Adverse events**

There were no major AEs. Minor AEs requiring an intervention were more in the TT knife group (31% vs 21.5%). However, the difference was not statistically significant. Minor AEs (TTJ vs TT) included capno-peritoneum (11.8 vs 17%), retroperitoneal CO<sub>2</sub> (7.5% vs 10%), and mucosotomies (2.1% vs 4%) requiring closure with endoclips. There was one occurrence of capno-mediastinum in the TT knife group [Table 4].

**Technical and clinical success**

POEM could be successfully completed in 92 patients (98.9%) in the TTJ knife group and 99 (99%) patients in the TT knife group. Significant submucosal fibrosis and inadvertent enlargement of mucosal incision precluded the completion of POEM procedure in one patient each in TTJ and TT knife groups.

Clinical success (Eckardt score, ≤3) was achieved in 90/93 (96.8%) in the TTJ knife group and 98/100 (98%) in the TT knife group at a median follow-up of 9 (range, 6–13 months) and 12 months (6–22 months), respectively [Table 5].

**DISCUSSION**

In this study, we found that the new triangular knife with water jet facility can be efficaciously used for POEM procedure. In addition, the integration of water jet reduces the OT significantly.

POEM is a novel procedure for AC with encouraging results in recent studies.<sup>[21,22]</sup> POEM has been found to be effective, associated with less postoperative pain, and cost effective in comparison to laparoscopic Heller’s myotomy.<sup>[23-26]</sup> Evolution of new devices and techniques aim at reducing the technical difficulty with this procedure.<sup>[10,16]</sup> One of the markers of technical difficulty with an endoscopic procedure is OT which reduces after the completion of learning curve.<sup>[27]</sup>

In this study, we used a new triangular tip knife (TTJ knife) which is equipped with a water jet to facilitate submucosal injections. There are important differences

**Table 1: Demographics and preoperative characteristics of study patients**

	TTJ knife (N=93)	TT knife (N=100)	P
Mean age, years (±SD, range)	39.50±13.33	39.61±14.17	0.96
Male	45 (48.38%)	57 (57%)	0.25
Achalasia cardia subtypes			
Type I	23 (24.7%)	32 (31%)	0.34
Type II	64 (68.8%)	61 (61%)	0.29
Type III	6 (6.5%)	7 (7%)	1.00
Eckardt score (Pre-POEM)	6.79±1.48	7.04±1.26	0.21
LES pressure (Pre-POEM)	32.92±11.24	35.40±11.85	0.14
Previous therapy	n=33 (35.5%)	n=39 (39%)	0.65
Botulinum toxin injection	-	2	
PBD	29	30	
LHM/HM	3	2/1	
PBD and LHM	1	2	
POEM	1	2	

TT: Triangular tip; TTJ: Triangular tip knife with water jet; LES: Lower esophageal sphincter; POEM: Peroral endoscopic myotomy; PBD: Pneumatic balloon dilatation; LHM: Laparoscopic Heller’s myotomy

**Table 2: Comparison of POEM procedure details between the two groups**

	TTJ Knife N=93	TT knife N=100	P
Site of myotomy			
Anterior (cm)	61 (65.6%)	61 (61%)	0.55
Posterior (cm)	32 (34.4%)	39 (39%)	0.55
Total length of myotomy	11.31±2.70	11.91±2.70	0.12
Esophageal	8.34±2.69	9.02±2.63	0.08
Gastric	2.92±0.26	2.89±0.40	0.54
Total Operating time (min)	53.8±15.2	66.26±19.18	0.0001
Mean±S.D. (Range)			
anterior POEM	55.8±16.5	67.01±17.08	0.0001
posterior POEM	49.9±11.5	65.08±22.26	0.0001
Submucosal dissection time	34.6±10.1	45.83±14.80	0.0001
Myotomy duration	10.31±6.13	11.45±6.51	0.21
Clipping duration	8.81±7.20	10.08±7.60	0.23
Use of Coagulation forceps	2.92±1.77	4.7±2.59	0.0001
Exchange of accessories	2.92±1.77	10.5±3.58	0.0001
No. of clips	5.67±1.26	5.8±0.75	0.38

TTJ knife: Triangular tip knife with water jet; POEM: Peroral endoscopic myotomy; cm: Centimeter

**Table 3: Comparison of operative time between anterior and posterior POEM**

	Anterior POEM	Posterior POEM	P
TTJ knife	55.86±16.59 (min)	49.9±11.5 (min)	0.72
TT knife	67.01±17.08 (min)	65.08±22.26 (min)	0.50

TTJ knife: Triangular tip knife with water jet; POEM: Peroral endoscopic myotomy

between TTJ knife and conventional TT knife [Figure 2]. The most crucial difference is the incorporation of a water jet facility into this knife which facilitates submucosal injections without the need of exchange of accessories. In contrast, multiple exchanges of accessories are required during submucosal tunneling while using the conventional knife (TT), i.e., spray catheter for submucosal injection and TT knife for dissection.

**Table 4: Comparison of adverse events between the two groups**

	TTJ knife	TT knife	P
Adverse events	n=20 (21.5%)	31 (31%)	0.15
Mucosal injury	2 (2.1%)	4 (4%)	0.68
Capno-peritoneum (requiring intervention)	11 (11.8%)	17 (17%)	0.41
Retroperitoneal air requiring temporary stoppage of procedure	7 (7.5%)	10 (10%)	0.62
Capno-mediastinum	-	1	-
Other gas related events			
Subcutaneous emphysema	17 (18.3%)	22 (22%)	0.59
Capno-peritoneum (not requiring intervention)	3 (3.2%)	7 (7%)	0.33
Retroperitoneal air (not requiring intervention)	8 (8.6%)	13 (13%)	0.36

**Table 5: Comparison of technical and clinical success between both groups**

	TTJ	TT	P
Technical success (%)	92/93 (98.9)	99/100 (99)	1.000
Clinical success (%)	90/93 (96.8%)	98/100 (98)	1.000
Eckardt score	1.02±0.60	0.99±0.69	0.76
Follow-up (median)	9 months	12 months	

Submucosal tunneling is the most time consuming part of POEM procedure. Therefore, OT is largely attributable to time spent during submucosal dissection. In the present study, exchange of accessories and requirement of coagulation forceps were significantly fewer while using the TTJ knife. This in turn translated into reduced length of POEM procedures. The mean OT was significantly less in the TTJ knife group (<60 min). This difference in OT was mainly due to faster submucosal dissection in the TTJ knife group. Similar findings were noted in an earlier study which compared hybrid knife with TT knife for POEM procedure. OT was significantly less while using hybrid knife as compared to TT knife ( $22.9 \pm 6.7$  vs  $35.9 \pm 11.7$ ).<sup>[28]</sup> Moreover, minor bleeding episodes were significantly fewer presumably due to larger volume of injection in the hybrid knife group. In another prospective study, factors predicting technical difficulty during POEM were assessed. Use of TT knife and learning curve were the only factors related to technical difficulty.<sup>[29]</sup> In addition to triangular and hybrid knives, the use of a new short needle-knife with a spherical tip has been described recently. This knife (FlushKnife BT, DK2618JB; Fujifilm, Tokyo, Japan) is also equipped with water jet, and therefore, reduces the exchanges of accessories.<sup>[16]</sup>

Although all cases in the TT knife group were performed during an earlier time frame (August 2015 to April 2016) than those in the TTJ knife group (May 2016 to November 2016), it was unlikely to produce a significant impact on OT as the cumulative experience of operators before the study was approximately 270 cases ( $\geq 80$  cases for each operator). In a recent study, efficiency and mastery were attained after 40

and 60 POEMs, respectively.<sup>[30]</sup> Similarly, few other studies have also concluded that OT largely reduces and stabilizes after the completion of learning curve.<sup>[30,31]</sup> However, OT can be reduced even after the completion of learning curve, as evident in our study. Therefore, use of new knife makes the procedure technically easier and less time consuming. This may have implications on the length of learning curve as well as the cost of procedure related to the occupancy of endoscopy suit.

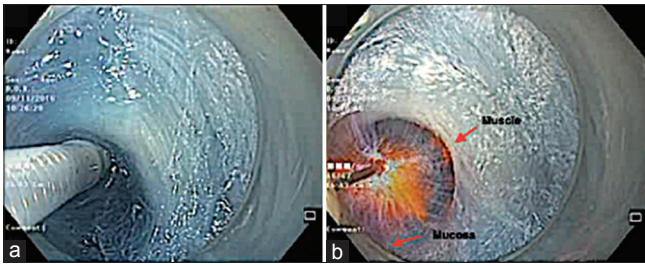
Besides the use of new knife, other factors which could have affected the OT include length of myotomy and history of prior treatment. Both the groups had similar length of myotomies and near equal proportion of prior treated cases precluding the possibility of bias due to these factors.

Overall, 26% patients had occurrence of minor AEs. Although AEs were numerically higher in the TT knife group (TT, 31% vs TTJ, 21.5%), the difference was not statistically significant and none of the minor AEs led to clinically significant signs or symptoms. Similar incidence of AEs was noticed in a recent study (31%).<sup>[32]</sup> Most of the gas-related events are inconsequential and do not require any intervention.<sup>[32-34]</sup> The occurrence of gas-related events may theoretically correlate with OT due to insufflation of CO<sub>2</sub> for a longer period. However, there is limited data which demonstrates this correlation. In a recent prospective study, procedure length was the only predictor of AEs.<sup>[35]</sup> The authors did not specify the category of AEs in this study.

The occurrence of mucosal injuries was nonsignificantly higher in the TT knife group in our study. Submucosal dissection is technically more demanding at or near GE junction compared to elsewhere in the submucosal tunnel [Figure 4]. Inadvertent spray by the knife may injure the mucosa due to limited space at GE junction. TTJ knife is more compact than TT knife, and therefore, may allow more precise dissection at narrow spaces such as GE junction. In addition, repeated injections near GE junction to maintain adequate dissecting space between muscle and mucosa are easier and less cumbersome with TTJ knife.

POEM could not be completed in 2 patients due to severe submucosal fibrosis and inadvertent enlargement of mucosal incision. Submucosal fibrosis is an important reason for aborting the POEM procedure and has been described in previous studies.<sup>[36]</sup> Inadvertent extension of mucosal incision has been reported less frequently and is likely to occur if the esophageal mucosa is not healthy due to stasis-related inflammation.<sup>[19]</sup>

All POEM procedures were performed in an endoscopy suit and none of the patients required transfer to an operating



**Figure 4:** (a) Submucosal injection and dissection with new TT knife at gastroesophageal junction. (b) Note the inadvertent spray to mucosa due to proximity of mucosa and muscle

theatre for untoward events. This is in concordance with a recent study which concluded that POEM can be securely accomplished in an endoscopy suite.<sup>[35]</sup> POEM procedures in a surgical theatre may cost more than those accomplished in an endoscopy room. However, there are no studies to support this assumption as of now.

The clinical success in both groups was >90%, thereby confirming the results of previously published studies regarding short-term efficacy of POEM.

The strengths of our study include: (1) This is the first study reporting the outcomes with TTJ knife in a large number of patients; (2) Sub-analysis of procedure duration; and (3) Objective evaluation of clinical success. However, certain drawbacks are noteworthy and include retrospective nature of our study, different time frames when the two knives were used, and short follow-up in both the groups. Therefore, randomized trials are required to establish the results of the current study. In addition, a multivariate analysis inclusive of all the factors which could have affected OT was not performed (such as disease duration, sigmoid esophagus, pediatric patients).

## CONCLUSION

In conclusion, use of the new triangular tip knife is safe and efficacious and may reduce technical difficulty even after the completion of learning curve. Integration of a water jet may render its usefulness for other procedures such as endoscopic submucosal dissection, submucosal tunneling endoscopic resection, and gastric-POEM.

## Financial support and sponsorship

Nil.

## Conflicts of interest

There are no conflicts of interest.

## REFERENCES

- Nabi Z, Reddy DN. Achalasia Cardia – Recent Advances in Diagnosis and Endoscopic Management. *J Gastrointest Dig Syst* 2016;6:393.

- Inoue H, Minami H, Kobayashi Y, Sato Y, Kaga M, Suzuki M, et al. Peroral endoscopic myotomy (POEM) for esophageal achalasia. *Endoscopy* 2010;42:265-71.
- Nabi Z, Ramchandani M, Reddy DN. The choice of myotomy in achalasia cardia: Heller's or per-oral endoscopic myotomy. *Saudi J Gastroenterol* 2017;23:73-4.
- Talukdar R, Inoue H, Nageshwar Reddy D. Efficacy of peroral endoscopic myotomy (POEM) in the treatment of achalasia: A systematic review and meta-analysis. *Surg Endosc* 2015;29:3030-46.
- Werner YB, Costamagna G, Swanstrom LL, von Renteln D, Familiari P, Sharata AM, et al. Clinical response to peroral endoscopic myotomy in patients with idiopathic achalasia at a minimum follow-up of 2 years. *Gut* 2016;65:899-906.
- Ramchandani M, Nageshwar Reddy D, Darisetty S, Kotla R, Chavan R, Kalpala R, et al. Peroral endoscopic myotomy for achalasia cardia: Treatment analysis and follow up of over 200 consecutive patients at a single center. *Dig Endosc* 2016;28:19-26.
- Hungness ES, Sternbach JM, Teitelbaum EN, Kahrilas PJ, Pandolfino JE, Soper NJ. Per-oral Endoscopic Myotomy (POEM) After the Learning Curve: Durable Long-term Results With a Low Complication Rate. *Ann Surg* 2016;264:508-17.
- Hoppo T, Thakkar SJ, Schumacher LY, Komatsu Y, Choe S, Shetty A, et al. A utility of peroral endoscopic myotomy (POEM) across the spectrum of esophageal motility disorders. *Surg Endosc* 2016;30:233-44.
- Stavropoulos SN, Modayil RJ, Brathwaite C, Halwan B, Kollaras MM, Taylor SI, et al. Anterior vs Posterior PerOral Endoscopic Myotomy (POEM): Is There a Difference in Outcomes? *Gastrointest Endosc* 2016;83:AB145.
- Philips GM, Dacha S, Keilin SA, Willingham FF, Cai Q. Concurrent myotomy and tunneling after establishment of a half tunnel instead of myotomy after establishment of a full tunnel: A more efficient method of peroral endoscopic myotomy. *Endosc Int Open* 2016;4:E403-8.
- Wang J, Tan N, Xiao Y, Chen J, Chen B, Ma Z, et al. Safety and efficacy of the modified peroral endoscopic myotomy with shorter myotomy for achalasia patients: A prospective study. *Dis Esophagus* 2015;28:720-7.
- Li QL, Chen WF, Zhou PH, Yao LQ, Xu MD, Hu JW, et al. Peroral endoscopic myotomy for the treatment of achalasia: A clinical comparative study of endoscopic full-thickness and circular muscle myotomy. *J Am Coll Surg* 2013;217:442-51.
- Inoue H, Sato H, Ikeda H, Onimaru M, Sato C, Minami H, et al. Per-Oral Endoscopic Myotomy: A Series of 500 Patients. *J Am Coll Surg* 2015;221:256-64.
- Tang X, Gong W, Deng Z, Zhou J, Ren Y, Zhang Q, et al. Comparison of conventional versus Hybrid knife peroral endoscopic myotomy methods for esophageal achalasia: A case-control study. *Scand J Gastroenterol* 2016;51:494-500.
- Bittinger M, Messmann H. Use of the stag-beetle knife for peroral endoscopic myotomy for achalasia: A novel method for myotomy. *Gastrointest Endosc* 2015;82:401-2.
- Tanaka S, Toyonaga T, Kawara F, Grimm IS, Hoshi N, Abe H, et al. Peroral endoscopic myotomy using FlushKnife BT: A single-center series. *Endosc Int Open* 2017;5:E663-9.
- Balassone V, Sumi K, Inoue H. Peroral endoscopic myotomy: First human experience with a water-jet-assisted triangle knife. *Gastrointest Endosc* 2016;83:1279.
- Nabi Z, Ramchandani M, Chavan R, Tandan M, Kalapala R, Darisetty S, et al. Per-oral Endoscopic Myotomy in Children- First Experience with a New Triangular Knife. *J Pediatr Gastroenterol Nutr* 2018;66:43-47.
- Nabi Z, Ramchandani M, Chavan R, Kalapala R, Darisetty S, Rao GV, et al. Per-oral endoscopic myotomy for achalasia cardia: Outcomes in over 400 consecutive patients. *Endosc Int Open* 2017;5:E331-9.
- Ramchandani M, Nageshwar Reddy D. Peroral endoscopic myotomy: Technique of mucosal incision. *Clin Gastroenterol Hepatol* 2014;12:900-1.
- Ngamruengphong S, Inoue H, Chiu PW, Yip HC, Bapaye A, Ujiki M, et al. Long-term outcomes of per-oral endoscopic myotomy in patients with achalasia with a minimum follow-up of 2 years: An international

- multicenter study. *Gastrointest Endosc* 2017;85:927-33 e922.
22. Martinek J, Svecova H, Vackova Z, Dolezel R, Ngo O, Krajciová J, *et al.* Per-oral endoscopic myotomy (POEM): Mid-term efficacy and safety. *Surg Endosc* 2017. doi: 10.1007/s00464-017-5807-3. [Epub ahead of print].
  23. Miller HJ, Neupane R, Fayeizadeh M, Majumder A, Marks JM. POEM is a cost-effective procedure: Cost-utility analysis of endoscopic and surgical treatment options in the management of achalasia. *Surg Endosc* 2017;31:1636-42.
  24. Docimo S, Jr., Mathew A, Shope AJ, Winder JS, Haluck RS, Pauli EM. Reduced postoperative pain scores and narcotic use favor per-oral endoscopic myotomy over laparoscopic Heller myotomy. *Surg Endosc* 2017;31:795-800.
  25. Khashab MA, Kumbhari V, Tieu AH, El Zein MH, Ismail A, Ngamruengphong S, *et al.* Peroral endoscopic myotomy achieves similar clinical response but incurs lesser charges compared to robotic heller myotomy. *Saudi J Gastroenterol* 2017;23:91-6.
  26. Schlottmann F, Luckett DJ, Fine J, Shaheen NJ, Patti MG. Laparoscopic Heller Myotomy Versus Peroral Endoscopic Myotomy (POEM) for Achalasia: A Systematic Review and Meta-analysis. *Ann Surg* 2017. doi: 10.1097/SLA.0000000000002311. [Epub ahead of print].
  27. El Zein M, Kumbhari V, Ngamruengphong S, Carson KA, Stein E, Tieu A, *et al.* Learning curve for peroral endoscopic myotomy. *Endosc Int Open* 2016;4: E577-82.
  28. Cai MY, Zhou PH, Yao LQ, Xu MD, Zhong YS, Li QL, *et al.* Peroral endoscopic myotomy for idiopathic achalasia: Randomized comparison of water-jet assisted versus conventional dissection technique. *Surg Endosc* 2014;28:1158-65.
  29. Tang X, Ren Y, Wei Z, Zhou J, Deng Z, Chen Z, *et al.* Factors predicting the technical difficulty of peroral endoscopic myotomy for achalasia. *Surg Endosc* 2016;30:3774-82.
  30. Patel KS, Calixte R, Modayil RJ, Friedel D, Brathwaite CE, Stavropoulos SN. The light at the end of the tunnel: A single-operator learning curve analysis for per oral endoscopic myotomy. *Gastrointest Endosc* 2015;81:1181-7.
  31. Kurian AA, Dunst CM, Sharata A, Bhayani NH, Reavis KM, Swanström LL. Peroral endoscopic esophageal myotomy: Defining the learning curve. *Gastrointest Endosc* 2013;77:719-25.
  32. Werner YB, von Renteln D, Noder T, Schachschal G, Denzer UW, Groth S, *et al.* Early adverse events of per-oral endoscopic myotomy. *Gastrointest Endosc* 2017;85:708-18.
  33. Haito-Chavez Y, Inoue H, Beard KW, Draganov PV, Ujiki M, Rahden BHA, *et al.* Comprehensive Analysis of Adverse Events Associated With Per Oral Endoscopic Myotomy in 1826 Patients: An International Multicenter Study. *Am J Gastroenterol* 2017;112:1267-76.
  34. Zhang XC, Li QL, Xu MD, Chen SY, Zhong YS, Zhang YQ, *et al.* Major perioperative adverse events of peroral endoscopic myotomy: A systematic 5-year analysis. *Endoscopy* 2016;48:967-78.
  35. Khashab MA, El Zein M, Kumbhari V, Besharati S, Ngamruengphong S, Messallam A, *et al.* Comprehensive analysis of efficacy and safety of peroral endoscopic myotomy performed by a gastroenterologist in the endoscopy unit: A single-center experience. *Gastrointest Endosc* 2016;83:117-25.
  36. Wu QN, Xu XY, Zhang XC, Xu MD, Zhang YQ, Chen WF, *et al.* Submucosal fibrosis in achalasia patients is a rare cause of aborted peroral endoscopic myotomy procedures. *Endoscopy* 2017;49:736-44.