



CLINICAL ARTICLE

Per Pedicel-Ligament Flavum Tunnel Outside-In Foraminoplasty for T₁₀-T₁₂ Discectomy under a Percutaneous Endoscope

Wei Lin, MD[†] , Wei Liu, MD[†], Wen-ting Ma, MD[†], Yuan Xue, MD, PhD 

Department of Orthopaedic Surgery, Tianjin Medical University General Hospital, Tianjin, China

Objective: To describe the effectiveness of T₁₀-T₁₂ discectomy and per pedicel-ligament flavum tunnel outside-in foraminoplasty protocols under percutaneous endoscope.

Methods: This retrospective study from September 2017 to June 2019 comprised 10 patients (mean age was 64.7 years, with 7 men and 3 women) with symptomatic thoracic disc herniation. Patients who had 12 months of follow-up and no cervical and lumbar spine surgery or trauma during the follow up period were included in the study. Patients underwent surgery at different levels: 3 patients for T₁₀-T₁₁ and 7 patients for T₁₁-T₁₂. Percutaneous endoscopic thoracic discectomy was performed following under-vision foraminoplasty, which was based on lower pedicel-ligament flavum tunnel detection. Patients who presented with symptomatic soft disc herniation of the thoracic spine and did not respond to conservative treatments were included. Patients with calcified disc herniation or concomitant ossification of the posterior longitudinal ligament were excluded. The surgery involves four steps: (i) facet joint reaching procedures; (ii) sliding the working sleeve caudally to attach the pedicel, rotating the scope to detect the lower border of the superior articular process, the pedicel, and the lower pedicel-ligamentum flavum tunnel (PEFT) under vision, respectively; (iii) milling the superior articular process under vision; and (iv) finding and removing the disc protrusion after the posterior longitudinal ligament is resected. Patient outcomes were evaluated using vision analog scale scores, Oswestry disability index scores, and Japanese Orthopaedic Association scores. The VAS scores, Oswestry disability index scores, and Japanese Orthopaedic Association scores before and after the operation were compared by *t*-test for statistical analysis. MRI, CT, and plain X-rays were performed in of all the patients before and after surgery.

Results: The patient was usually able to stand and walk approximately 2 h after the surgery. During the 12-month follow-up, all patients showed a significant improvement in pain. Postoperative thoracic MRI examination of all patients showed full decompression of the spinal cord and no residual pressure. Postoperative back pain and nerve root pain were significantly alleviated in all patients, and spinal cord function was significantly restored. The mean visual analog scale scores of patients postoperation were significantly better than those of patients preoperation (6.10 ± 1.37 vs 1.80 ± 0.79 , $P < 0.05$). The mean ODI scores of patients postoperation were better than those of patients preoperation ($13\% \pm 2.36\%$ vs $55\% \pm 9.20\%$, $P < 0.05$). The mean JOA scores increased from 3.2 ± 0.75 to 9.3 ± 0.64 . The JOA improvement rate was $79.6\% \pm 5.1\%$. There was 1 patient who had transient intercostal neuralgia.

Conclusion: Following pedicel-ligament flavum tunnel outside-in foraminoplasty protocols, T₁₀-T₁₂ discectomy is relatively safe when conducted under percutaneous endoscope.

Key words: Thoracic transforaminal percutaneous endoscopy; Foraminoplasty; Pedicel-ligament flavum tunnel; Disc herniation

Address for correspondence Yuan Xue, MD, PhD, Department of Orthopaedic Surgery, Tianjin Medical University General Hospital, 154 Anshan Rd, Heping District, Tianjin, China 300052 Tel: +86-022-60363934; Fax: +86-022-60363190; Email: xueyuanzy@163.com

[†]These authors contributed equally to this work.

Disclosure: The authors have nothing to disclose.

Received 28 November 2020; accepted 2 December 2020

Orthopaedic Surgery 2021;13:253-259 • DOI: 10.1111/os.12916

This is an open access article under the terms of the Creative Commons Attribution-NonCommercial-NoDerivs License, which permits use and distribution in any medium, provided the original work is properly cited, the use is non-commercial and no modifications or adaptations are made.

Introduction

Compared with lumbar spine herniation, thoracic disc herniation (TDH) is relatively rare^{1,2}, and 75% of TDH occurs between T₈ and L₁³. Over the past century, based on the little available literature and due to the lack of sensitive diagnostic procedures, the incidence of symptomatic thoracic disc disease has been estimated to be 1 case per 1 000 000 people⁴. However, the prevalence of TDH is increasing with the wide application of MRI and CT for the detection of myelopathies and radiculopathies⁵. Today, TDH with or without symptoms has a frequency of 1 per 1000 people⁶.

Thoracic disc herniation is most common in adults aged 30 to 50 years, with equal distribution between the two genders³. Symptomatic TDH patients experience symptoms of medullary compression along with ataxia or motor deficiency; sensory deficiency and bladder symptoms can also occur⁷.

Surgical decompression is usually considered for symptomatic TDH with motor deficiency; however, surgery for TDH is not viewed favorably because of its technical difficulties, the potential hard-to-treat complications³, and the low number of thoracic discectomies carried out (approximately 0.15% to 4% of all disc surgical procedures)⁸. Various surgical approaches for decompression of the TDH have been advocated, including: thoracotomy, thoracoscopic, laminectomy, lateral extracavitary, costotransversectomy, and transpedicular approaches^{8,9}. The variety of choices of surgical approaches make the surgery of TDH more challenging.

Percutaneous nucleotomy (PN) is also used in thoracic discectomy, but is commonly regarded as primitive. PN was developed by Hijikata. Based on the Hijikata method, around the end of the last century, the spinal endoscope was introduced in surgery with the PN technique; this is referred to as percutaneous endoscopic lumbar discectomy (PELD). The PELD technique was developed following the invention of an ultra-thin high-speed surgical drill that can safely enlarge the intervertebral foramen under endoscopic guidance. To prevent the cannula compressing the exiting nerve root when inserting the cannula in the narrow foramen, foraminal plastic PELD was established using the high-speed drill and/or a trephine reamer. Rosenthal¹⁰ was one of the first to describe minimally invasive endoscopic approaches to the thoracic spine, and Horowitz *et al.*¹¹ later pioneered video-assisted thoracoscopic surgery for thoracic discectomy. In 1997, Jho described the technique of percutaneous endoscopic transpedicular thoracic discectomy from the posterolateral approach¹². Percutaneous endoscopic thoracic discectomy (PETD) has been developed to reduce trauma and enhance the postoperative outcome for TDH from posterior or posterolateral approaches. In 2010, Choi *et al.*¹³ demonstrated the low energy nonablative laser for thermodiscoplasty using a 4 mm 0° endoscope. PETD is still not favored by surgeons because PETD is a technical challenge compared to lumbar spine and open thoracic discectomy. Spine surgeons believe that the source of the difficulty in PETD discectomy is the foraminal plasticity. Because the thoracic intervertebral foramen is smaller than the lumbar intervertebral foramen, widening

the foramen is necessary before introducing the cannula into the thoracic canal.

Thoracic myelopathy from the ossification ligamentum flavum (OLF) is also a challenging surgery. The tunnel between the pedicle and the ossification ligamentum flavum (POT) is a relatively large, nerve-free compartment that can accommodate the tip of the bone-cutting instrument. The inside-out per POT upper facet joint resection (from the POT entrance to exit) is a safe procedure for posterior decompression of the OLF using the open posterior approach. The thoracic myelopathy from the disc protrusion is usually not combined with OLF, but the tunnel between the pedicle-ligamentum flavum tunnel (PEFT) in the disc protrusion is wider than the POT peri-OLF. The most difficult technique in the endoscope is the foraminal plasticity. The exit of the PEFT may accommodate the tip of the reamer at the beginning of the reaming procedure for the foraminal plasticity.

This retrospective study evaluated the clinical outcomes of PETD with foraminal plasticity per PEFT. The aim of the present study was: (i) to demonstrate the feasibility of the PETD; and (ii) to illustrate the feasibility of the procedure the per PEFT outside-in foraminal plasticity procedure for the treatment of thoracic myelopathy from T₁₀-T₁₂ disc protrusion.

Methods

Patient demographics

Each patient provided informed consent for participation in the present study. This retrospective study was conducted in accordance with the Declaration of Helsinki (Ethical Principles for Medical Research Involving Human Subjects) and was approved by the Ethics Committee of Tianjin Medical University General Hospital.

The inclusion criteria for PETD patients treated between September 2017 and June 2019 were as follows: (i) patients who presented with recurrent lower limb symptoms (ataxia during walking or progressive deficit of the lower limbs in the context of pyramidal tract syndrome or with vesico-sphincter signs) due to TDH; (ii) soft TDH (diagnosed by CT and MRI); and (iii) patients in whom conservative treatment had failed to relieve the recurrent symptoms. The exclusion criteria were: (i) calcified TDH; (ii) ossification of the ligamentum flavum; (iii) skin and soft tissue infection in the operative area; and (iv) uncorrected coagulation dysfunction. Finally, 10 patients (mean age was 64.7 years, with 7 men and 3 women) with soft TDH who underwent PETD from 2017 to 2019 met the inclusion criteria. Patients underwent surgery at different levels: 3 patients for T₁₀-T₁₁ and 7 patients for T₁₁-T₁₂. MRI, CT, and plain X-rays were performed in all the patients before and after surgery.

Surgery

Preoperatively, the target level was determined. The surgery was performed in four steps. First, the facet joint reaching procedure was performed following the standard transforaminal endoscopic discectomy technique under local

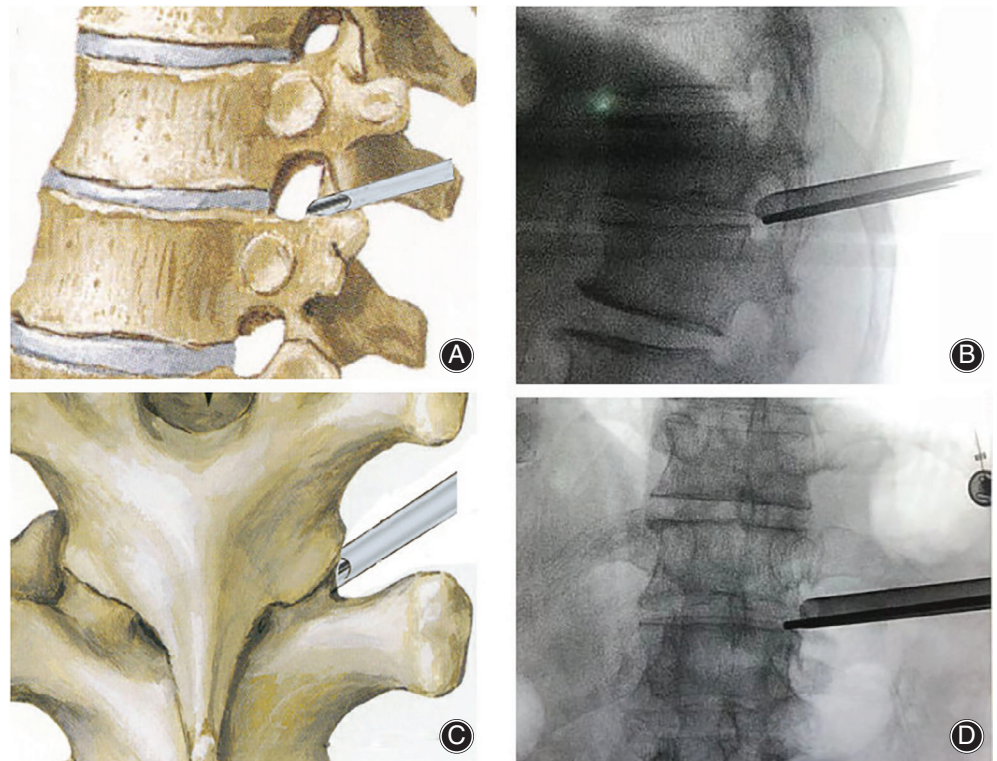


Fig. 1 The working sleeve landed on the superior articular process. (A) Lateral view of working sleeve location and (C) dorsal view of working sleeve location. (B) and (D) Sagittal and coronal view, respectively, of working sleeve under X-ray fluoroscopy.

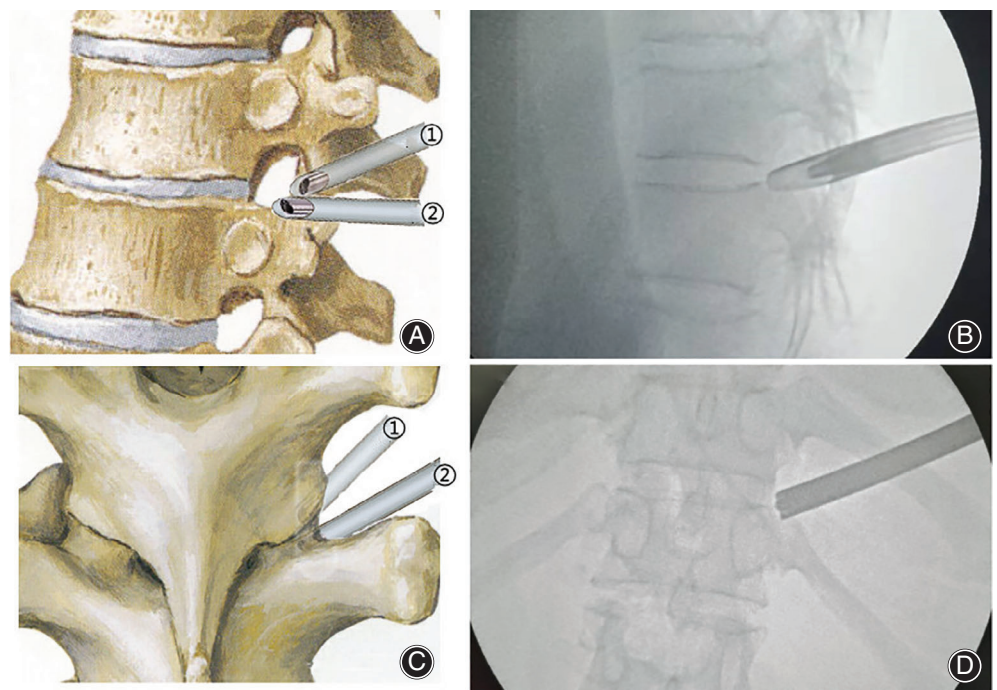


Fig. 2 Localization of superior articular process, pedicel, and lower pedicel-ligamentum flavum tunnel (PEFT) under vision. (A) and (C) Lateral and dorsal view of working sleeve and scope location, respectively. ① Working sleeve positioned on the superior articular process, ② The working sleeve is slid caudally to attach the pedicel, rotating the scope to detect the lower border of superior articular process, pedicel, and lower PEFT under vision, respectively. (B) and (D) Sagittal and coronal view, respectively, of working sleeve location under X-ray fluoroscopy.

anesthesia with continuous monitoring of oxygen saturation, heart rate, and blood pressure. The local anesthetic was 0.5% lidocaine. With the patient in the prone position, under the guidance of X-ray fluoroscopy, the puncture point was selected to be 6 cm from the spinous process; the puncture

needle directly reached the upper facet joint and local anesthetic was injected. The soft tissue was expanded by sleeve to build a soft-tissue passage. After that, a 2.0-mm diameter K-wire was inserted, and then the protective sleeve was replaced by the working sleeve (Fig. 1). At this point, the facet

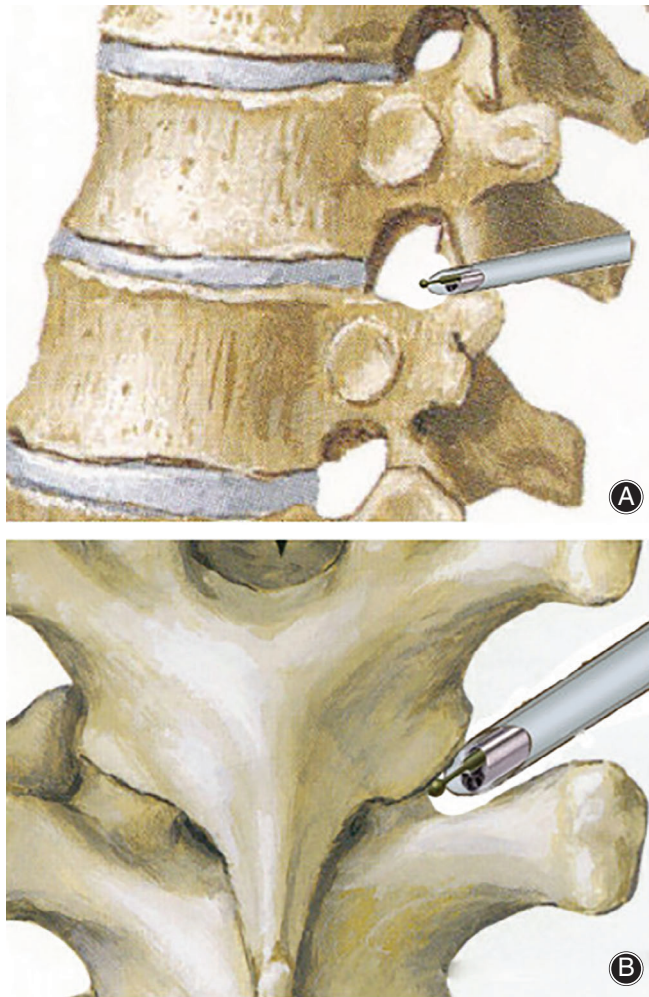


Fig. 3 Milling of the superior articular process under vision. (A) Lateral view of milling of the superior articular process. (B) Dorsal view of milling the superior articular process.

joint reaching procedure was complete. Second, the low PEFT vision was established (Fig. 2): After the endoscope was positioned on the side surface of the superior articular process, the working sleeve was slid caudally until it attached to the pedicle and the scope was rotated to find the exit of the lower PEFT. The pedicle, PEFT, and facet joint were visualized, respectively. Third, after the lower border of the superior articular process was detected, the superior articular process was milled (Fig. 3) under endoscope vision by the motor burr to enlarge the intervertebral foramen until the foraminoplasty was completed (foramen larger than 8 mm). Fourth, the dural sac was revealed after resecting the ligamentum flavum, and the disc protrusion was found and removed after the posterior longitudinal ligament was resected (Fig. 4).

The patient had a postoperative MRI to make sure symptoms had completely subsided after the procedure. Patient was usually able to stand and walk approximately 2 h after the surgery.

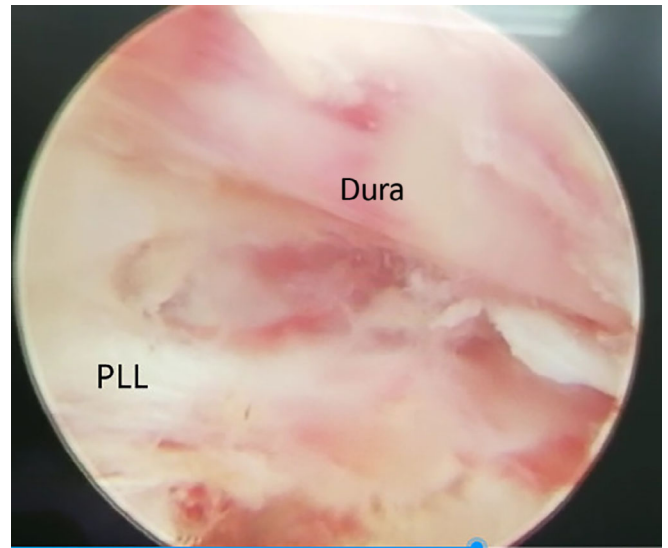


Fig. 4 Surgical field after disc herniation removed under scope vision.

Clinical Assessment

Each participant was asked to complete three quality-of-life questionnaires before surgery and at each follow up: vision analog scale, Oswestry disability index, and Japanese Orthopaedic Association questionnaires.

Visual Analogue Scale

Using a ruler, the VAS score is determined by measuring the distance (cm) on a 10-cm line between a “no pain” anchor and the patient’s mark, providing a range of scores from 0 to 10. A higher score indicates greater pain intensity. Based on the distribution of VAS scores in postsurgical patients describing their postoperative pain intensity as none, mild, moderate, or severe, the following cut points on the pain VAS have been recommended: no pain (0–2), mild pain (3–5), moderate pain (6–8), and severe pain (8–10). Normative values are not available. The scale has to be shown to the patient; otherwise it is an auditory scale, not a visual one.

Oswestry Disability Index

The ODI is a principal condition-specific outcome measure used in the management of spinal disorders and to assess patient progress in routine clinical practice. The ODI score system includes 10 sections: pain intensity, personal care, lifting, walking, sitting, standing, sleeping, sex life, social life, and traveling. For each section of six statements, the total score is 5. Intervening statements are scored according to rank. If more than one box is marked in each section, the highest score is taken. If all 10 sections are completed, the score is calculated as follows: total scored out of total possible score $\times 100$. If one section is missed (or not applicable), the score is calculated as: $(\text{total score} / (5 \times \text{number of questions answered})) \times 100\%$. A total of 0%–20% is considered mild dysfunction, 21%–40% is moderate dysfunction, 41%–60%

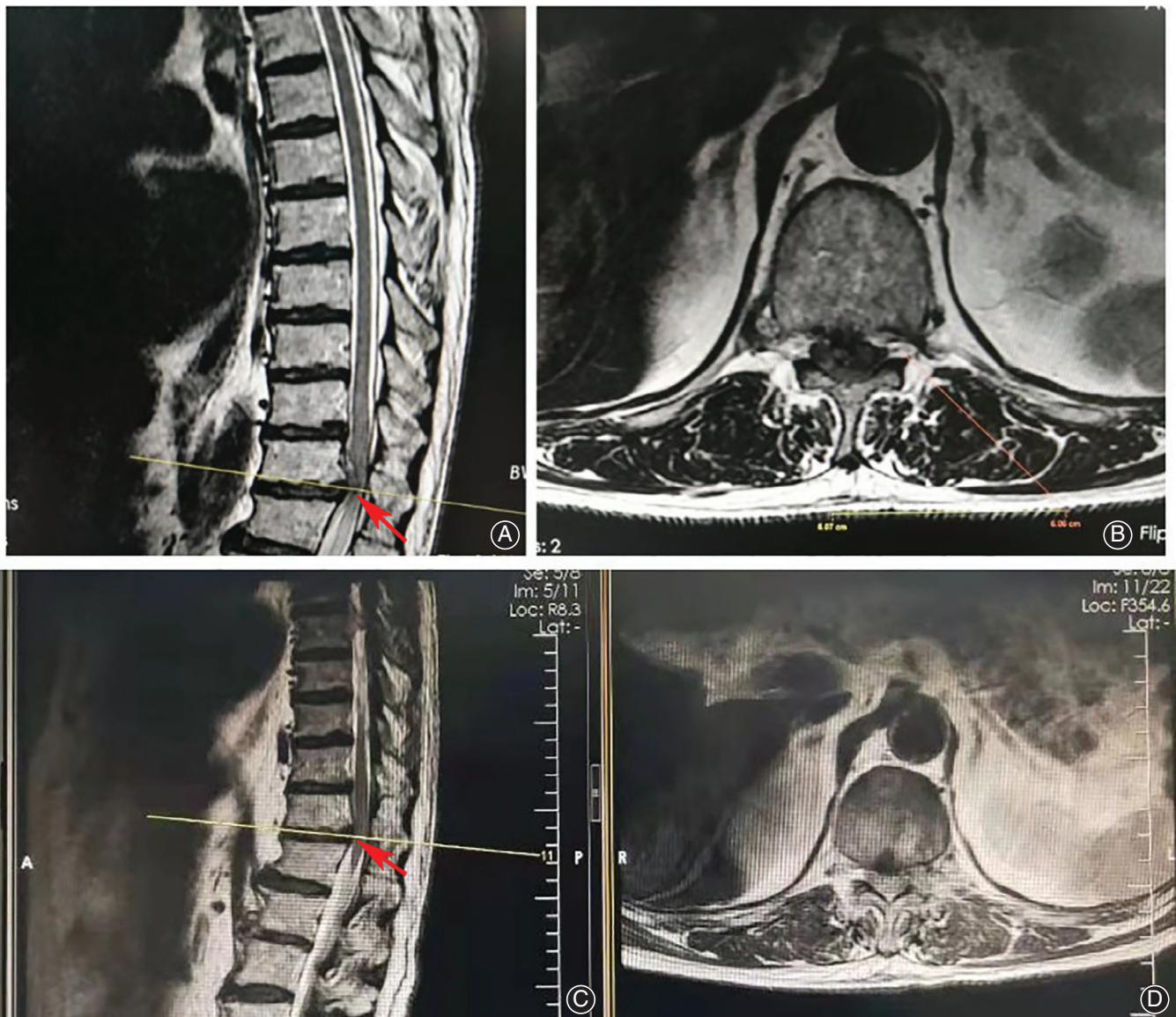


Fig. 5 The patient (male, 64 years old) who underwent percutaneous endoscopic thoracic discectomy (T₁₁–T₁₂) had progressive deficit of the lower limbs in the context of pyramidal tract syndrome before the operation. (A) and (B) Preoperative MRI of sagittal and axial views, respectively, of the thoracic spine show the T₁₁–T₁₂ disc herniation. (C) and (D) Postoperative MRI indicated that the disc herniation was cleared and the decompression was successful.

is severe dysfunction, and 61%–80% is considered a disability. For cases with a score of 81%–100%, patients are either long-term bedridden or exaggerating the impact of pain on their life.

The patients were followed up at 1, 6, and 12 months postoperatively. In addition, complications were documented.

Japanese Orthopaedic Association

The JOA scores were used to evaluate the neurological function of patients with thoracic degeneration and the effectiveness of treatment. The highest possible total score from categories for a normal person is 11 points. Therefore, the

treatment improvement rate = $[(\text{posttreatment score} - \text{pretreatment score}) / (11 - \text{pretreatment score})] \times 100\%$; $\geq 75\%$ means excellent; 50%–74% means good; 25%–49% means fair; and 0%–24% means poor.

Statistical Analysis

Data were entered and analyzed using the IBM SPSS 24.0 (International Business Machines, Armonk, New York, USA). The VAS, ODI score, and JOA score before and after the operation were expressed as mean \pm standard deviation and compared by *t*-test for statistical analysis. A *P*-value less than 0.05 was considered statistically significant ($P < 0.05$).

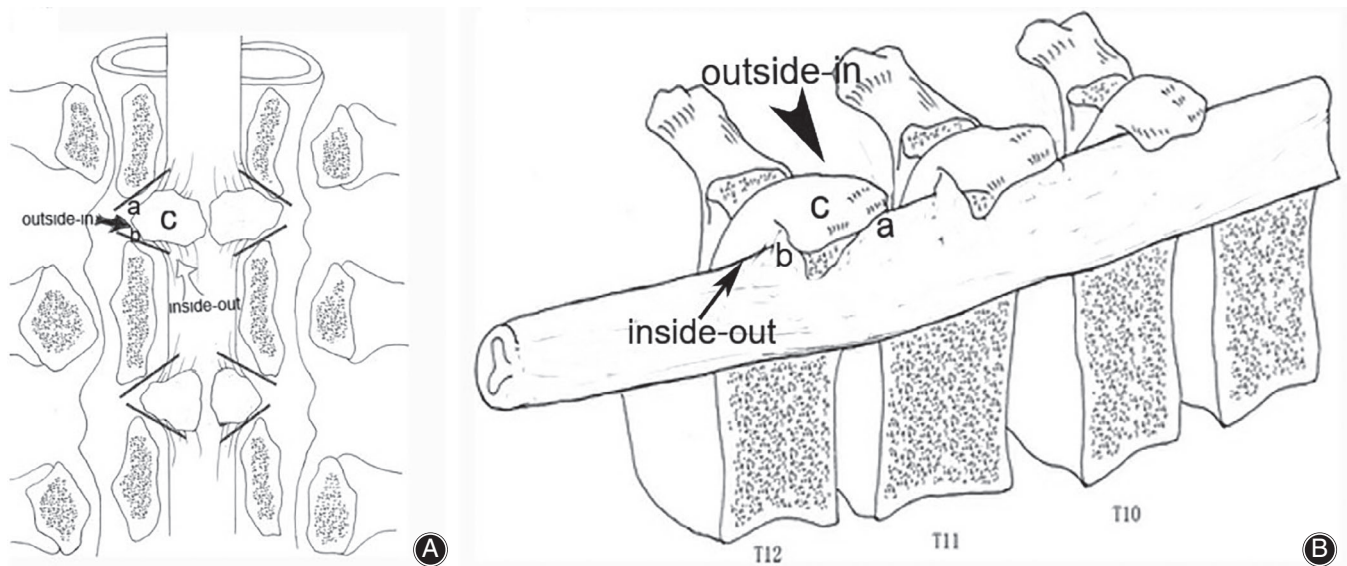


Fig. 6 The foramen is divided by the facet joint into three parts: the upper PEFT (a), the lower PEFT (b), and the facet joint (c). (A) Dorsal view of PEFT. (B) Lateral view of PEFT. The foraminoplasty in this study used the outside-in route of the lower PEFT.

Results

Clinical Outcomes

The PETD that the patients in this study underwent were successful. Postoperative thoracic MRI examination of all patients showed full decompression of the spinal cord and no residual pressure. Postoperative back pain and nerve root pain were significantly alleviated in all patients, and spinal cord function was significantly restored. The preoperative and postoperative MRI of 1 patient are shown in Fig. 5. The mean VAS scores of patients postoperation were significantly better than those of patients preoperation (6.10 ± 1.37 vs 1.80 ± 0.79 , $P < 0.05$). The mean ODI scores of patients postoperation were better than those of patients preoperation ($13\% \pm 2.36\%$ vs $55\% \pm 9.20\%$, $P < 0.05$). The mean JOA scores of patients postoperation were better than those of patients preoperation (9.3 ± 0.64 vs 3.2 ± 0.75 , $P < 0.05$). The JOA improvement rate was $79.6\% \pm 5.1\%$.

Complications

One patient developed transient intercostal neuralgia after surgery, which was relieved after conservative treatment with antiinflammatory analgesia and physiotherapy. There were no complications such as cerebrospinal fluid leakage, recurrence of disc herniation, postoperative infection, or aggravation of symptoms of postoperative spinal cord injury.

Discussion

Challenges for Percutaneous Endoscopic Lumbar Discectomy Surgery

In most cases, the foraminal distance (distance between the posterior edge of the disc and the ventral aspect of the

facet joint) was less than 8 mm, which is the diameter of the cannula of PELD¹⁴. The significance of the foraminoplasty is that the foramen could be expanded to more than 8 mm, so the cannula in the PETD could be inserted and the operation could be done under vision. The difficulty of PETD is that the thoracic foraminal distance is smaller than that of the lumbar foramen, and the upper facet joint is attached to the dorsal part of thoracic dura, which covers the spinal cord or medullary cone. The dura and the cord are more vulnerable to injury in the thoracic foraminoplasty by reamer or motor bur under fluoroscope during the PETD. Therefore, examining the safety of foraminoplasty protocols under vision is particularly important for PETD.

Advantage of Per Lower Pedicle-Ligament Flavum Tunnel Foraminoplasty

The foraminoplasty in this study involved: (i) facet joint reaching procedures; (ii) localization of the superior articular process, pedicle, and lower PEFT under vision; and (iii) milling the superior articular process under vision. Unlike previous foraminoplasties, the foraminoplasty used in this study used the lower PEFT to find the location between the facet joint and the dural sac, and was performed under endoscopic vision, which could reduce the possibility of operation injury to the dural sac and thoracic spinal cord. When the operation is performed under endoscopic vision, bleeding points can be detected and hydrostatic pressure to the cord can be avoided. Therefore, a reliable, repeatable, and reproducible intervertebral foraminoplasty technique is valuable for the PETD procedure.

Structure of Pedicel-Ligament Flavum Tunnel

The per PEFT outside-in foraminoplasty is a comparatively safe procedure for T₁₀–T₁₂ discectomy under a percutaneous endoscope. Per POT inside-out upper facet joint resection (from the POT entrance to exit) is a relatively safety procedure for posterior decompression of the OLF using the open posterior approach¹⁵. The foramen is divided by the facet joint into three parts (Fig. 6): the upper PEFT, the facet joint, and the lower PEFT. The facet joint is attached to the dorsal part of the thoracic dura. The top of the upper PEFT is the inferior articular process and its junction with the pedicle; the outside portal is the intervertebral foramen, and the inside portal leads to the spinal canal. The anterior–lateral wall is the pedicle and the posterior–medial wall is the facet joint capsular ligament and the ligamentum flavum. The top of the lower PEFT is the superior articular process and its junction with the pedicle; the outside portal is the intervertebral foramen, and the inside portal leads to the spinal canal. The anterior–medial wall is the facet joint capsular ligament and the ligamentum flavum, and the posterior–lateral wall is the pedicle. The lower PEFT is localized in the

Kambin's triangle and is a relatively large and nerve-free compartment.

Limitations

In this study, the per lower PEFT foraminoplasty was only performed in T₁₀–T₁₂. Some thoracic disc pathologies showing calcification contraindicate the use of PETD considering the constrained position of the endoscope and instruments¹⁶.

Conclusion

The current study demonstrates that following per lower PEFT outside-in foraminoplasty protocols (i.e. facet joint reaching procedures; localization of the superior articular process, the pedicle, and the lower PEFT under vision; and milling the superior articular process under vision), T₁₀–T₁₂ discectomy is relatively safe when conducted under a percutaneous endoscope.

Acknowledgments

Funding was received for this work from the National Natural Science Foundation of China (81871124).

References

- Gille O, Soderlund C, Razafimahandri HJ, Mangione P, Vital JM. Analysis of hard thoracic herniated discs: review of 18 cases operated by thoracoscopy. *Eur Spine J*, 2006, 15: 537–542.
- Arce CA, Dohrmann GJ. Herniated thoracic disks. *Neurol Clin*, 1985, 3: 383–392.
- Court C, Mansour E, Bouthors C. Thoracic disc herniation: surgical treatment. *Orthop Traumatol Surg Res*, 2018, 104: S31–S40.
- Quint U, Bordon G, Preissl I, Sanner C, Rosenthal D. Thoracoscopic treatment for single level symptomatic thoracic disc herniation: a prospective followed cohort study in a group of 167 consecutive cases. *Eur Spine J*, 2012, 21: 637–645.
- Bae J, Chachan S, Shin SH, Lee SH. Percutaneous endoscopic thoracic discectomy in the upper and midthoracic spine: a technical note. *Neurospine*, 2019, 16: 148–153.
- McAfee PC. Vascular injury during anterior lumbar spine surgery. *Spine J*, 2005, 5: 118–119; author reply.
- Quillo-Olvera J, Kim JS. A novel, minimally invasive hybrid technique to approach intracanal herniated thoracic discs. *Oper Neurosurg (Hagerstown)*, 2020, 19: E106–E116.
- Malham GM, Parker RM. Treatment of symptomatic thoracic disc herniations with lateral interbody fusion. *J Spine Surg*, 2015, 1: 86–93.
- Hulme A. The surgical approach to thoracic intervertebral disc protrusions. *J Neurol Neurosurg Psychiatry*, 1960, 23: 133–137.
- Rosenthal D. Endoscopic approaches to the thoracic spine. *Eur Spine J*, 2000, 9: S8–S16.
- Horowitz MB, Moossy JJ, Julian T, Ferson PF, Huneke K. Thoracic discectomy using video assisted thoracoscopy. *Spine (Phila Pa 1976)*, 1994, 19: 1082–1086.
- Jho HD. Endoscopic transpedicular thoracic discectomy. *J Neurosurg*, 1999, 91: 151–156.
- Choi KY, Eun SS, Lee SH, Lee HY. Percutaneous endoscopic thoracic discectomy; transforaminal approach. *Minim Invasive Neurosurg*, 2010, 53: 25–28.
- Henmi T, Terai T, Nagamachi A, Sairyo K. Morphometric changes of the lumbar intervertebral foramen after percutaneous endoscopic foraminoplasty under local anesthesia. *J Neurol Surg A Cent Eur Neurosurg*, 2018, 79: 19–24.
- Zhao Y, Xue Y, Shi N, et al. The CT and intraoperative observation of pedicel-ossification tunnel in 151 cases of thoracic spinal stenosis from ossification of ligamentum flavum. *Eur Spine J*, 2014, 23: 1325–1331.
- Bae J, Chachan S, Shin SH, Lee SH. Transforaminal endoscopic thoracic discectomy with foraminoplasty for the treatment of thoracic disc herniation. *J Spine Surg*, 2020, 6: 397–404.