

# Bullous pemphigoid associated with ipilimumab therapy for advanced metastatic melanoma

T Hanley<sup>1</sup>, S Papa<sup>2,3</sup> and M Saha<sup>1</sup>

<sup>1</sup>Department of Dermatology, Queen Elizabeth Hospital, London SE18 4QH, UK

<sup>2</sup>Cancer Studies, Bermondsey Wing, King's College London, London SE1 9RT, UK

<sup>3</sup>Department of Medical Oncology, Guy's and St Thomas' NHS Foundation Trust, London, UK

**Corresponding author:** M Saha. Email: monikasaha@nhs.net

## Lesson

Immunotherapy is now being routinely used in the management of many cancers. It is therefore vital that all clinicians are aware of the diverse array of cutaneous manifestations that can result from their use, which can vary from mild to life threatening.

## Keywords

Cancer, dermatological, clinical, dermatology, oncology, pharmacology and therapeutics, unwanted effects/adverse reactions

## Introduction

The immune checkpoint inhibitors are a new group of cancer therapeutics conferring a significant survival benefit for patients with advanced metastatic melanoma. The first-in-class immune checkpoint inhibitors, Ipilimumab, blocks the cytotoxic T lymphocyte associated antigen 4, a checkpoint inhibitor of T cell activation, potentiating antitumour T cell responses. Survival is significantly improved for a sub-set of advanced metastatic melanoma patients at the expense of immune-related adverse events.<sup>1</sup> Cutaneous immune-related adverse events associated with ipilimumab are common and vary from mild to life threatening.<sup>2</sup> Here, we report a case of ipilimumab-induced bullous pemphigoid after unsuccessful treatment with pembrolizumab.

## Case

A 72-year-old gentleman, receiving treatment with ipilimumab for advanced metastatic melanoma, presented with a one-week history of a widespread blistering pruritic cutaneous eruption. In January 2016, he was diagnosed with a stage IIIB primary malignant melanoma of his upper back which was treated with wide local excision and completion lymph node dissection. A Positron Emission Tomography – Computed Tomography scan, undertaken in June

2016 for surveillance as part of his follow-up, showed multiple areas of uptake in the lung, supraclavicular fossa and right scapular. He was subsequently commenced on pembrolizumab and completed six cycles. Restaging Positron Emission Tomography – Computed Tomography scan showed disease progression and the patient was commenced on ipilimumab, six weeks after the last dose of pembrolizumab.

One week after commencing the ipilimumab, the patient developed grade 4 diarrhoea. He was treated for ipilimumab-associated colitis with prednisolone 60 mg once mane, which was slowly tapered over the following two months once daily. Ipilimumab was therefore withheld and a palliative approach adopted. Within a week of cessation of the prednisolone for the colitis, the patient developed a cutaneous eruption on his limbs and trunk. Clinical examination revealed a widespread erythematous urticated and blistering eruption. No mucosal involvement was demonstrated (Figure 1(a) and (b)).

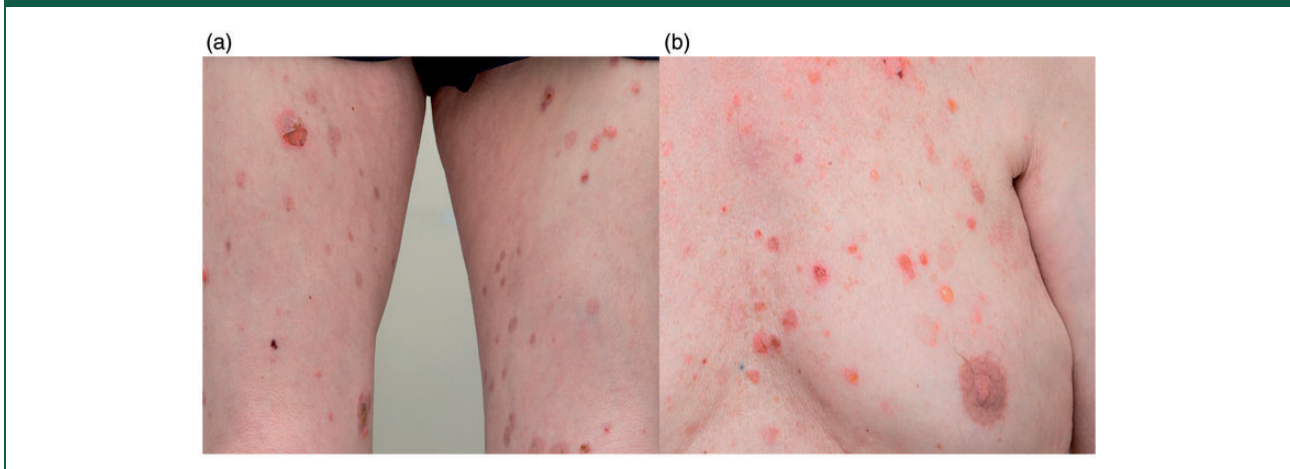
A skin biopsy from the left anterior thigh showed a sub-epidermal blister, with the dermis comprising of perivascular lymphocytic infiltrates mixed with multiple eosinophils. Direct immunofluorescence revealed linear deposition of the IgG and C3 at the basement membrane zone. Elisa for BP180 was elevated at 86 U/mL and indirect immunofluorescence demonstrated anti-basement membrane zone antibodies detected at a titre of 1/200, with antibodies localising to the roof on split-skin substrate, all in keeping with a diagnosis of bullous pemphigoid (Figure 2(a) and (b)).

The patient was commenced on 40 mg prednisolone once daily and topical clobetasol propionate 0.05% ointment. He is currently being considered for a secondary immunosuppressive therapy, following relapse when the prednisolone dosage was tapered.

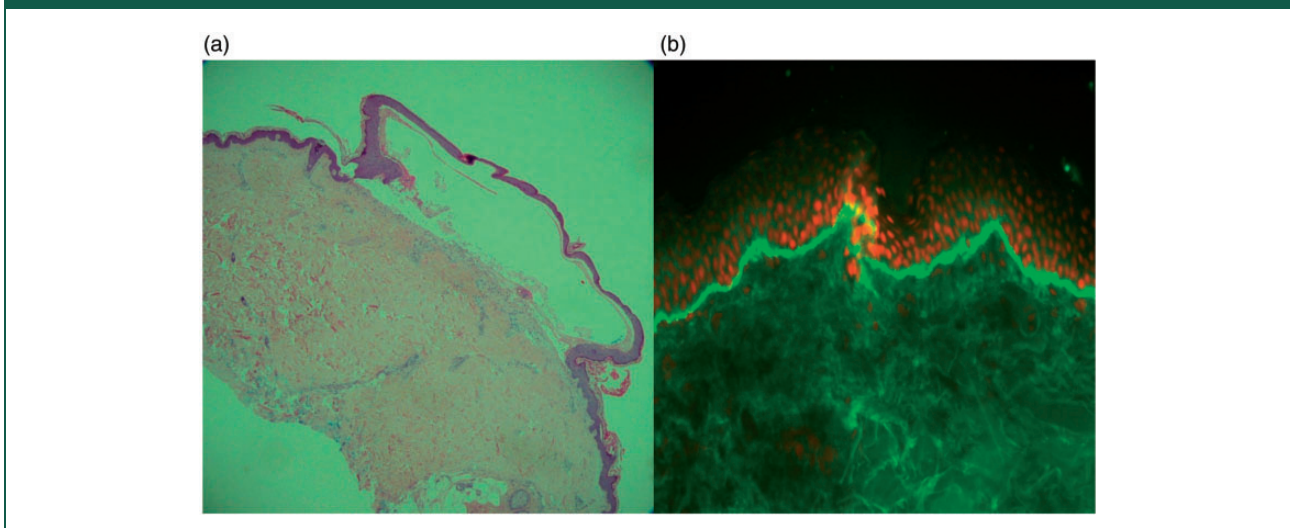
## Discussion

Bullous drug eruptions are uncommon with immune checkpoint therapy; however, there been seven case

**Figure 1.** (a) Clinical image from patient's thigh demonstrating blister sites and erosions. (b) Clinical image from patient's chest.



**Figure 2.** (a) Haematoxylin and eosin stain reveals a sub-epidermal blister. (b) Direct immunofluorescence revealed linear deposition of IgG to the basement membrane zone.



reports of bullous pemphigoid in those treated for metastatic melanoma occurring with pembrolizumab, nivolumab and durvalumab (specific for programmed death 1 ligand) therapy, three of which received prior treatment with ipilimumab.<sup>3-7</sup> There has only been one prior case report of a patient developing bullous pemphigoid following sequential treatment with ipilimumab, after unsuccessful treatment of metastatic melanoma with nivolumab.<sup>7</sup>

Such cutaneous manifestations resulting from cytotoxic T lymphocyte associated antigen 4/programmed death ligand 1 receptor inhibitor treatment are thought to originate from a persistently stimulated immune system.<sup>6</sup> Immune checkpoints are

inhibitory pathways that are vital for self-tolerance and modulating physiological immune responses.<sup>8</sup> Tumours can adopt these pathways as a mechanism of immune evasion, therefore suppressing anti-tumoural T cell responses. Through blockade of immune checkpoints immune checkpoint inhibitors unleash anti-tumour immunity.<sup>8</sup>

Why some patients may go onto develop such immune-related adverse events is unclear. It has previously been postulated to be a class effect of programmed death ligand 1 inhibitors.<sup>6</sup> In previous case reports of pembrolizumab-induced bullous pemphigoid, onset of bullous pemphigoid had a latent period ranging from nine weeks to seven months.<sup>3-6</sup>

The authors note that in three of these case reports, patients had received prior treatment with ipilimumab, the significance of which is uncertain. Sequencing ipilimumab therapy after programmed death ligand 1 monoclonal antibody may result in a higher frequency and intensity of immune-related adverse events.<sup>3,9</sup> It is possible the development of bullous pemphigoid in this case is either a delayed effect of pembrolizumab, idiopathic or paraneoplastic; however, the severity of the gastrointestinal immune-related adverse event following the initial ipilimumab dose, with subsequent development of bullous pemphigoid on the withdrawal of corticosteroids, suggests a temporal association with the ipilimumab.

Current management options for most mild/moderate cutaneous manifestations include topical steroids and antihistamines. Severe toxicity (grade 3/4) may require high dose oral/systemic corticosteroids which must be slowly tapered.<sup>10</sup>

Immunotherapy is now routinely used in the management of many cancers and prescribing clinicians need to be aware of the vast array of cutaneous manifestations which may result from its use.

#### Declarations

**Competing Interests:** None declared.

**Funding:** None declared.

**Ethics approval:** Written informed consent was obtained with a signed copy of the form attached with this submission.

**Guarantor:** MS.

**Contributorship:** Each of the authors in this submission contributed in the literature review and writing of this paper.

**Acknowledgements:** Photomicrographic images courtesy of Dr Damian Collins, Consultant Histopathologist, Lewisham and Greenwich NHS Trust.

Direct immunofluorescence images courtesy of Dr John Mee Clinical Scientist and Dr Richard Groves Consultant Dermatologist, St John's Institute of Dermatology.

The authors would also like to acknowledge Dr Katie Lacy, Consultant Dermatologist, Dr Mark Harries, Consultant Oncologist, and Dr Christos Nikolaou, Clinical Fellow, Guy's and St Thomas' NHS Foundation Trust for their role in the patient's care.

**Provenance:** Not commissioned; peer-reviewed by Cristina Rodriguez.

#### References

1. Hodi FS, O'Day SJ, McDermott DF, et al. Improved survival with ipilimumab in patients with metastatic melanoma. *N Engl J Med* 2010; 363: 711–723.

2. Dika E, Ravaoli GM, Fanti PA, et al. Cutaneous adverse effects during ipilimumab treatment for metastatic melanoma: a prospective study. *Eur J Dermatol* 2017; 27: 266–270.
3. Damsky W, Kole L and Tomayko MM. Development of bullous pemphigoid during nivolumab therapy. *JAAD Case Rep* 2016; 2: 442–444.
4. Hwang SJ, Carlos G, Chou S, Wakade D, Carlino MS and Fernandez-Penas P. Bullous pemphigoid, an auto-antibody-mediated disease, is a novel immune-related adverse event in patients treated with anti-programmed cell death 1 antibodies. *Melanoma Res* 2016; 26: 413–416.
5. Hwang SJ, Carlos G, Wakade D, et al. Cutaneous adverse events (AEs) of anti-programmed cell death (PD)-1 therapy in patients with metastatic melanoma: a single-institution cohort. *J Am Acad Dermatol* 2016; 74: 455–461.e1.
6. Naidoo J, Schindler K, Querfeld C, et al. Autoimmune bullous skin disorders with immune checkpoint inhibitors targeting PD-1 and PD-L1. *Cancer Immunol Res* 2016; 4: 383–389.
7. Kuwatsuka Y, Iwanaga A, Kuwatsuka S, et al. Bullous pemphigoid induced by ipilimumab in a patient with metastatic malignant melanoma after unsuccessful treatment with nivolumab. *J Dermatol* 2018; 45: e21–e22.
8. Pardoll DM. The blockade of immune checkpoints in cancer immunotherapy. *Nature Rev Cancer* 2012; 12: 252–264.
9. Bowyer S, Prithviraj P, Lorigan P, et al. Efficacy and toxicity of treatment with the anti-CTLA-4 antibody ipilimumab in patients with metastatic melanoma after prior anti-PD-1 therapy. *Br J Cancer* 2016; 114: 1084–1089.
10. Lacouture ME, Wolchok JD, Yosipovitch G, Kahler KC, Busam KJ and Hauschild A. Ipilimumab in patients with cancer and the management of dermatologic adverse events. *J Am Acad Dermatol* 2014; 71: 161–169.