



Contents lists available at ScienceDirect

## International Journal of Surgery Case Reports

journal homepage: [www.casereports.com](http://www.casereports.com)

## Large bronchogenic cyst of stomach: A case report



Amine Chhaidar<sup>a,\*</sup>, Housseem Ammar<sup>b</sup>, Nihed Abdessayed<sup>c,d</sup>, Mohamed Azzaza<sup>a</sup>,  
Rahul Gupta<sup>e</sup>, Nefis Abdennaceur<sup>a</sup>, Ahlem Bdioui<sup>c,d</sup>, Moncef Mokni<sup>c,d</sup>, Ali Ben Ali<sup>a</sup>

<sup>a</sup> Department of Surgery, Sahloul Hospital, Sousse, Tunisia<sup>b</sup> Department of Surgery, Monastir University Hospital, Monastir, Tunisia<sup>c</sup> Department of Pathology, Farhat Hached University Hospital, Sousse, Tunisia<sup>d</sup> Research Lab: Transfer in Technology in Anatomic Pathology (LR12SP08), Tunisia<sup>e</sup> Department of HPB Surgery and Liver Transplantation, CARE Hospital, Hyderabad, India

## ARTICLE INFO

## Article history:

Received 9 January 2017

Received in revised form 15 March 2017

Accepted 16 March 2017

Available online 23 March 2017

## Keywords:

Gastric bronchogenic cyst

Foregut cystic developmental malformation

Subdiaphragmatic cyst

Pseudostratified columnar ciliated

epithelium

Case report

## ABSTRACT

**INTRODUCTION:** Bronchogenic cysts are congenital cysts arising as an abnormal budding from primitive tracheobronchial tree. They are lined by pseudostratified columnar or cuboidal ciliated epithelium and contain smooth muscle fibers, submucosal bronchial glands and/or cartilage. They are most frequently located in the mediastinum or the lung parenchyma. Intramural occurrence of bronchogenic cyst in the gastric wall is very rare.

**PRESENTATION OF CASE:** We present a case of 65-year-old lady with a 7 × 8 cm lesion in the gastric cardia suspicious of gastrointestinal stromal tumor. Because of the large size, total gastrectomy with Roux-en-Y esophagojejunal anastomosis was performed. The postoperative course was uneventful. Histopathological examination revealed a sub-mucosal cyst lined by PCCE with presence of smooth muscle fibers and focal mucous glands. Final diagnosis of bronchogenic cyst was made. On the last follow up at one year, she was symptom free.

**DISCUSSION:** On extensive Medline/Pubmed search, only 38 cases of gastric bronchogenic cysts were found to be reported till date. They are typically located in the posterior gastric wall close to the gastric cardia. On radiological imaging, they appear as well defined intramural cystic lesion without any characteristic features. Surgical resection is considered in symptomatic cases or in case of diagnostic dilemma.

**CONCLUSION:** Gastric bronchogenic cysts often mimic gastrointestinal stromal tumor on preoperative imaging. They should be included in the differential diagnosis while dealing with an intramural gastric lesion close to the cardia or gastroesophageal junction.

© 2017 The Author(s). Published by Elsevier Ltd on behalf of IJS Publishing Group Ltd. This is an open access article under the CC BY-NC-ND license (<http://creativecommons.org/licenses/by-nc-nd/4.0/>).

## 1. Introduction

Bronchogenic cysts are congenital cysts occurring due to a developmental malformation in the foregut during embryogenesis [1]. Most of them are asymptomatic at birth and early childhood. Symptoms develop later in life due to cyst enlargement leading to compression of adjacent organs, secondary infection or perforation [2]. They are lined by pseudostratified columnar or cuboidal ciliated (respiratory) epithelium (PCCE) [1]. In most of the cases, the cyst wall also contains elastic fibers, smooth muscle fibers, submucosal

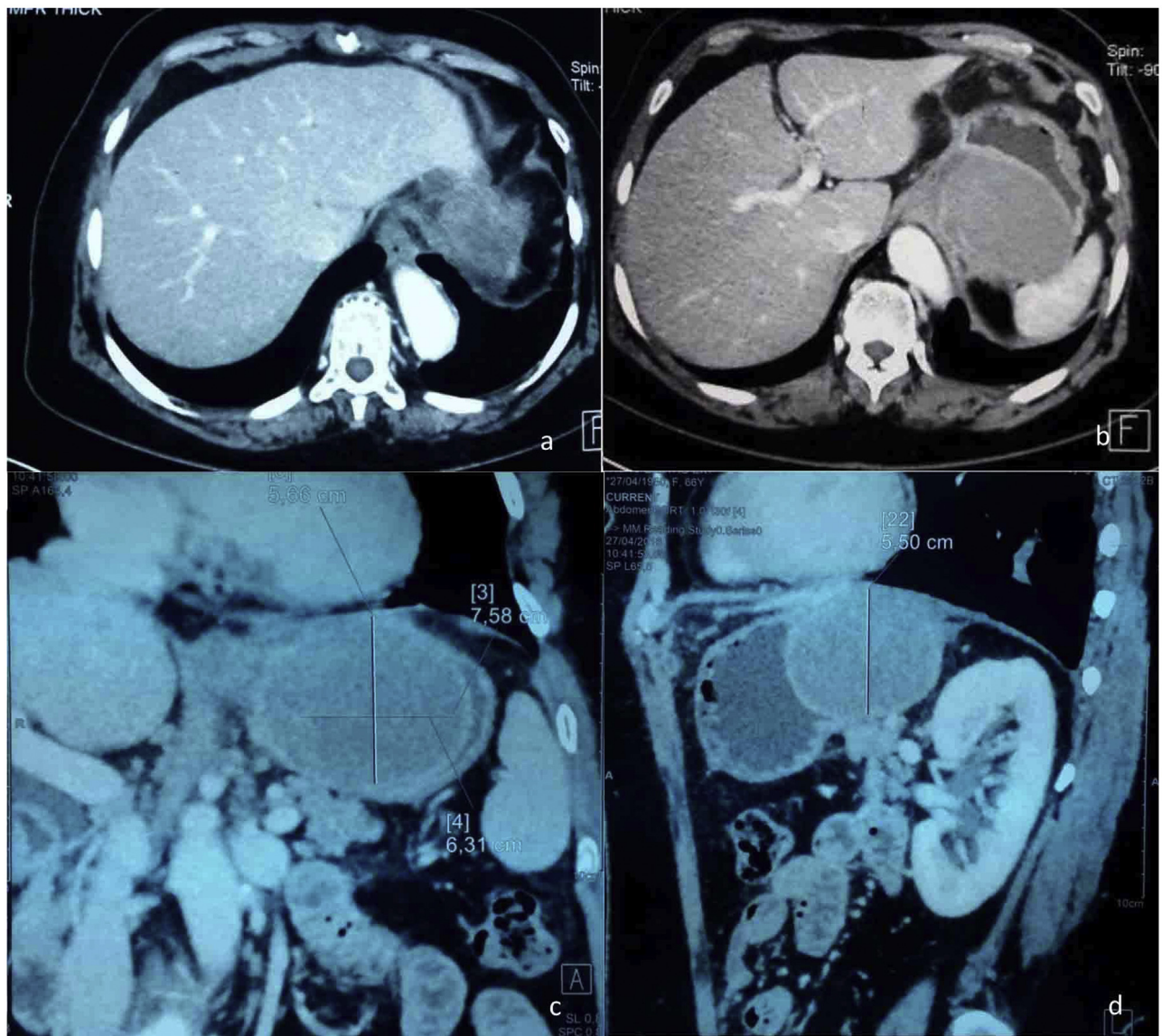
bronchial glands and/or cartilage which help to differentiate them from other developmental cysts like foregut cyst, duplication cyst [1]. As they arise due to abnormal budding from primitive tracheobronchial tree, they are most frequently located in the mediastinum or the lung parenchyma [3]. However, in some cases they can get detached and migrate in to the abdomen. Depending upon the extent of migration, they can be found anywhere within the abdominal cavity including ileal mesentery [4] and hepatogastric ligament [5]. Occurrence of bronchogenic cyst in the gastric wall is extremely rare. We report a case of large gastric bronchogenic cyst in an adult treated successfully by total gastrectomy. This case has been reported in line with the SCARE criteria [6].

## 2. Case description

A 65-year-old lady presented with history of epigastric pain for 2 months. There was no history of associated vomiting, hematemesis or weight loss. She had previous history of total thyroidectomy

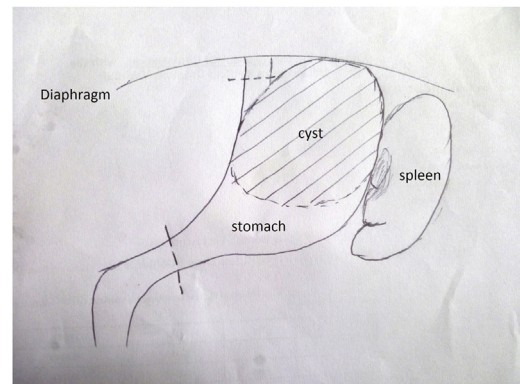
\* Corresponding author at: Department of Surgery, Sahloul Hospital, Route Ceinture, Cité Sahloul, 4054 Sousse, Tunisia.

E-mail addresses: [aminechhaidar@rns.tn](mailto:aminechhaidar@rns.tn) (A. Chhaidar), [Hosshoss24@hotmail.fr](mailto:Hosshoss24@hotmail.fr) (H. Ammar), [nihedabdessayed@gmail.com](mailto:nihedabdessayed@gmail.com) (N. Abdessayed), [mohamedazzaza@gmail.com](mailto:mohamedazzaza@gmail.com) (M. Azzaza), [rahul.g.85@gmail.com](mailto:rahul.g.85@gmail.com) (R. Gupta), [nafisabdennaceur@hotmail.com](mailto:nafisabdennaceur@hotmail.com) (N. Abdennaceur), [ahlembdioui@hotmail.com](mailto:ahlembdioui@hotmail.com) (A. Bdioui), [moncefimokni@gmail.com](mailto:moncefimokni@gmail.com) (M. Mokni), [alibenali@hotmail.com](mailto:alibenali@hotmail.com) (A.B. Ali).



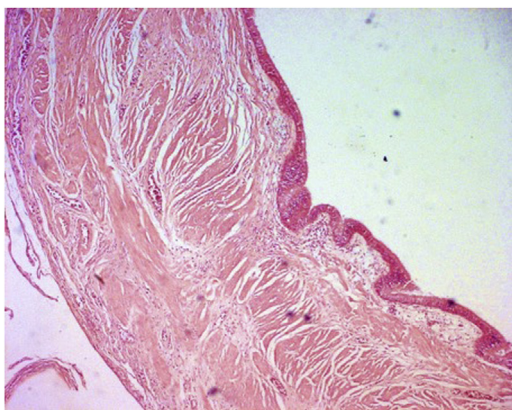
**Fig. 1.** Contrast enhanced computed tomography of abdomen showing a large gastric mass with heterogenous content and enhancing wall arising from the posterior wall of the gastric cardia and its relation with the esophagus, diaphragm and splenic hilum in the axial (a, b), coronal (b) and sagittal view (d).

for thyroid nodule and laparoscopic cholecystectomy for gallstones. On examination, there was no anemia, icterus or palpable abdominal lump. Routine blood investigations and tumor markers were within normal range. Abdominal ultrasound revealed a heterogenous lesion in the subdiaphragmatic location close to the medial surface of spleen measuring  $6 \times 7$  cm with echogenic center. Computed tomography (CT) showed a large mass of  $7 \times 8$  cm in relation to the gastric cardia with regular outlines and heterogeneous enhancement (Fig. 1). Upper gastrointestinal endoscopy found large ulcerated fundic folds with a bulge in to the lumen suggestive of extrinsic compression. There was presence of congestive gastropathy. Esophagus was normal. Biopsy from fundic mucosa showed moderately active chronic gastritis with absence of intestinal metaplasia or *H. pylori* infection or malignancy in the samples examined. Based on the above findings, gastrointestinal stromal tumor was suspected and she was planned for tumor excision. On abdominal exploration, an exophytic mass measuring  $8 \times 7$  cm was found arising from the gastric cardia adherent to the adjoining diaphragm and encroaching upon the splenic hilum (Fig. 2). After dissection, the mass could be separated from the diaphragm

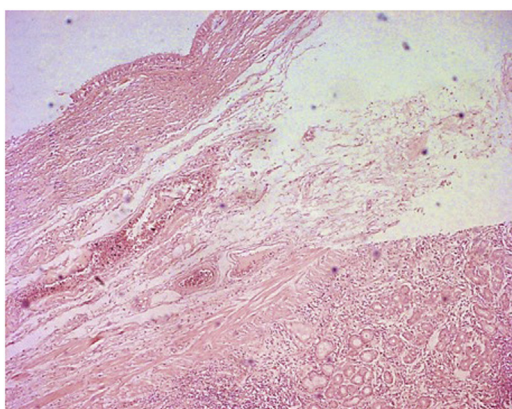


**Fig. 2.** Schematic diagram showing the location of the bronchogenic cyst and its relation with the surrounding structures. The dotted lines represent the extent of surgical resection.





**Fig. 3.** Microscopic examination of the cyst wall shows pseudostratified columnar ciliated epithelium without cellular atypia along with the surrounding smooth muscle fiber bundles (HE  $\times$  200).



**Fig. 4.** Microscopic examination of the cyst wall revealed focal areas of mucous glands, hemorrhagic remodeling and hemosiderin deposits. Areas of chronic gastritis without intestinal metaplasia were also noted (HE  $\times$  40).

and splenic hilum. Because of the large size, total gastrectomy with Roux-en-Y esophagojejunal anastomosis was performed. The postoperative course was uneventful and patient was discharged on postoperative day 7. The cyst contained thick mucinous fluid. Histopathological examination of the resected specimen revealed a sub-mucosal cyst lined by PCCE without cellular atypia (Fig. 3). There was no communication between the cyst and the gastric lumen. The cystic wall consisted of smooth muscle fibers with focal mucous glands showing hemorrhagic remodeling with hemosiderin deposits (Figs. 3 and 4). The gastric mucosa showed mild chronic gastritis with presence of *H. pylori* without intestinal metaplasia. Based on these findings, final diagnosis of bronchogenic cyst was made. On the last follow up at one year, she was symptom free with no evidence of recurrence.

### 3. Discussion

Congenital cysts are rare benign lesions of the stomach. There are several types of congenital cysts reported in literature including foregut cyst, gastric duplication cyst and bronchogenic cyst. They are differentiated from each other by the type of lining epithelium and the surrounding layer which may contain smooth muscles, cartilage, bronchial glands or may be absent. Bronchogenic cyst is the term, traditionally, used to describe a cyst lined by PCCE with the presence of cartilage or glandular tissue in the cyst wall. However, some recent studies have grouped intra mural gastric cyst with a lining of PCCE into a single entity as gastric foregut

cystic developmental malformation which includes foregut cyst, bronchogenic cyst and duplication lined by PCCE [7,8]. On extensive Medline/Pubmed search, we found only 38 reported cases of classical gastric bronchogenic cyst till date.

Bronchogenic cysts are more common in females than males [1]. In most of the cases, cysts become symptomatic after third decade of life with epigastric pain being the most common symptom [1]. They are typically located on the posterior or the posterolateral gastric wall near the gastroesophageal junction or the gastric cardia [1,9]. The cyst size is variable. In the present case, due to the large size, the cyst was occupying proximal two-third part of the stomach unlike the previously reported cases. Most of them are present in the submucosal or the smooth layer of the stomach without any communication with the gastric lumen as seen in our case. On gastroscopy, the larger cyst may appear as submucosal lesion bulging in to the lumen like in the present case. On conventional imaging, such as CT, they appear as a well-defined cystic lesion with or without calcifications [9]. On magnetic resonance imaging (MRI), the lesion appears as iso-intense to hyper-intense on T1-weighted images and hyper-intense on T2-weighted images resembling solid tumors like GIST with cystic degeneration [1,9,10]. High signal intensity on T1-weighted images seen in bronchogenic cysts, in contrast to low signal intensity seen in other cystic lesions is likely due to the presence of methemoglobin, mucin and proteins within the cyst [1,9]. However, the wall is thin with regular borders in bronchogenic cysts unlike the irregular thick wall seen in cystic degeneration [9]. Endoscopic ultrasound (EUS) may help in determining the exact location of the cyst within the gastric wall. CT or EUS guided needle biopsy may reveal mucoid material providing a clue towards the correct diagnosis [10,11]. However, it is not pathognomonic of bronchogenic cyst. Due to their submucosal location and hypoechoic appearance, they are often misdiagnosed as gastrointestinal stromal tumor (GIST) preoperatively similar to the current case [1,9].

Surgical resection remains the most suitable treatment due to the presence of diagnostic dilemma and rare possibility of malignant transformation [10,12]. However, there are anecdotal reports of successful conservative management when the diagnosis was confirmed on EUS guided biopsy [11]. Type of surgical resection depends upon the location, size of the lesion and the surgical expertise. Small lesions can be managed by minimally invasive partial gastrectomy while larger size like the one seen in our case are better treated by open conventional gastrectomy [13].

### 4. Conclusion

Gastric bronchogenic cysts are rare benign lesions, often misdiagnosed as GIST due to similar presentation and radiological appearance on CT scan and ultrasound. These cysts should be considered in the differential diagnosis especially when dealing with an intramural gastric lesion close to the cardia or gastroesophageal junction.

### Conflict of interest

The authors declare that they have no conflict of interest.

### Funding

This study has not received any funding.

### Ethical approval

The study was approved by Ethics Committee of Hospital Sahloul.

**Consent**

Written informed consent was obtained from the patient.

**Authors' contribution**

Amine Chhaidar – data collection, Editing of manuscript.  
 Housseem Ammar – Data collection, Editing of the manuscript.  
 Nihed Abdessaied – Histopathological examination of the specimen and reporting, data collection.  
 Mohamed Azzaza – Editing of manuscript.  
 Rahul Gupta – Editing of manuscript, literature review.  
 Ahlem Bdioui – Drafting of manuscript.  
 Nefis Abdennaceur – Editing of manuscript.  
 Moncef Mokni – Editing of the manuscript.  
 Ali Ben Ali – Editing of the manuscript.

**Guarantors**

Amine Chhaidar.  
 Housseem Ammar.

**Acknowledgement**

None.

**References**

- [1] C. Tu, J. Zhu, C. Shao, W. Mao, X. Zhou, Q. Lin, et al., Gastric bronchogenic cysts: a case report and literature review, *Exp. Ther. Med.* 11 (2016) 1265–1270.
- [2] X. Yang, K. Guo, Bronchogenic cyst of stomach: two cases report and review of the English literature, *Wien Klin Wochenschr* 125 (2013) 283–287.
- [3] S. Aktoğlu, G. Yuncu, H. Halilcolar, S. Ermete, T. Buduneli, Bronchogenic cysts: clinicopathological presentation and treatment, *Eur. Respir. J.* 9 (1996) 2017–2021.
- [4] A. Petrina, C. Boselli, R. Cirocchi, P. Covarelli, E. Eugeni, M. Badolato, et al., Bronchogenic cyst of the ileal mesentery: a case report and a review of literature, *J. Med. Case Rep.* 4 (2010) 313.
- [5] Y.G. Wang, H. Fang, X. Xu, W. Yu, K. Zhang, Y. Yu, Bronchogenic cyst in the hepatogastric ligament masquerading as an esophageal mesenchymal tumor: a case report, *Int. J. Clin. Exp. Pathol.* 8 (2015) 15307–15311.
- [6] R.A. Agha, A.J. Fowler, A. Saeta, I. Barai, S. Rajmohan, D.P. Orgill, for the SCARE Group, The SCARE statement: consensus-based surgical case report guidelines, *Int. J. Surg.* 34 (2016) 180–186.
- [7] S. Sharma, N. Nezakatgoo, P. Sreenivasan, J. Vanatta, N. Jabbour, Foregut cystic developmental malformation: new taxonomy and classification—unifying embryopathological concepts, *Indian J. Pathol. Microbiol.* 52 (2009) 461–472.
- [8] Y.H. Geng, C.X. Wang, J.T. Li, Q.Y. Chen, X.Z. Li, H. Pan, Gastric foregut cystic developmental malformation: case series and literature review, *World J. Gastroenterol.* 21 (2015) 432–438.
- [9] L. Sun, W. Lu Li Fu, W. Li, T. Liu, Gastric bronchogenic cyst presenting as a gastrointestinal stromal tumor, *Int. J. Clin. Exp. Pathol.* 8 (2015) 13606–13612.
- [10] S. Belli, T. Noyan, F. Kayaselçuk, G. Erbay, Gastric duplication (bronchogenic) cyst mimicking a gastrointestinal stromal tumour, *Ulusal Cer Derg* 29 (2013) 35–37.
- [11] M. Sato, A. Irisawa, M.S. Bhutani, V. Schnadig, T. Takagi, G. Shibukawa, et al., Gastric bronchogenic cyst diagnosed by endosonographically guided fine needle aspiration biopsy, *J. Clin. Ultrasound* 36 (2008) 237–239.
- [12] S.M. Sullivan, S. Okada, M. Kudo, Y. Ebihara, A retroperitoneal bronchogenic cyst with malignant change, *Pathol. Int.* 49 (1999) 338–341.
- [13] T. Kurokawa, M. Yamamoto, T. Ueda, T. Enomoto, K. Inoue, A. Uchida, et al., Gastric bronchogenic cyst histologically diagnosed after laparoscopic excision: report of a case, *Int. Surg.* 98 (2013) 455–460.

**Open Access**

This article is published Open Access at [sciencedirect.com](https://www.sciencedirect.com). It is distributed under the [IJSCR Supplemental terms and conditions](#), which permits unrestricted non commercial use, distribution, and reproduction in any medium, provided the original authors and source are credited.