



An Unusual Case of Calcific Periarthritis Causing Carpal Tunnel Syndrome and Its Management with Ultrasound-Guided Barbotage

Sisith Ariyaratne¹ Joban Babhulkar² Ashish Babhulkar² Karthikeyan P. Iyengar³ Rajesh Botchu¹

¹Department of Musculoskeletal Radiology, The Royal Orthopaedic Hospital, Birmingham, United Kingdom

²Department of Shoulder and Sports Injuries, Deenanath Mangeshkar Hospital and Research Centre, Pune, Maharashtra, India

³Department of Orthopaedics, Southport and Ormskirk Hospitals, Mersey and West Lancashire Teaching NHS Trust, Southport, United Kingdom

Address for correspondence Sisith Ariyaratne, MBBS (Hons.), FRANZCR, Department of Musculoskeletal Radiology, The Royal Orthopaedic Hospital, Bristol Road South, Northfield B31 2AP, Birmingham, United Kingdom (e-mail: sisithariyaratne@gmail.com).

Indian J Radiol Imaging 2024;34:553–557.

Abstract

Hydroxyapatite crystal deposition disease (HADD) is a common disorder resulting from the deposition of calcium hydroxyapatite crystals in various soft tissues, typically in periarticular distribution, including tendons, tendon sheaths, joint capsules, ligaments, bursae, periarticular soft tissues, and occasionally within the joints. The more commonly known subtypes of HADD are calcific tendinopathy and calcific periarthritis. Carpal tunnel syndrome (CTS) can be rarely caused by calcific deposits within the carpal tunnel in the setting of HADD-related calcific periarthritis. Imaging, particularly ultrasound and radiographs, is crucial in distinguishing this entity from the conventional form of CTS that tends to be idiopathic. We describe a rare presentation of CTS secondary to calcific periarthritis in a 45-year-old patient, with imaging demonstrating mass-like calcification within the carpal tunnel, with typical features of those seen with HADD. The patient was treated with ultrasound-guided barbotage, with significant clinical improvement. The case highlights a lesser-known cause of CTS as well as a presentation of HADD, and the role of ultrasound-guided barbotage, a minimally invasive procedure, as a viable first-line management option as an alternative to surgery.

Keywords

- ▶ calcific periarthritis
- ▶ hydroxyapatite crystal deposition disease
- ▶ HADD
- ▶ carpal tunnel
- ▶ barbotage
- ▶ ultrasound

Introduction

Hydroxyapatite crystal deposition disease (HADD) is a well-known systemic disorder resulting from the abnormal periarticular and/or intra-articular deposition of calcium hydroxyapatite crystals.¹ Its commonest presentation is calcific tendinopathy, also known as calcific tendinosis/tendonitis, and typically involves the rotator cuff tendons (mainly supraspinatus),^{1,2} a condition with a prevalence of up to 7.5% in adults and usually affecting middle aged women.

However, several other sites can be involved including bursae, joint capsules, tendon sheaths, and ligaments.³ Ultrasound-guided barbotage is a needling and lavage procedure and is an established method of treating calcific tendinopathy of rotator cuff tendons.

Carpal tunnel syndrome (CTS) is a commonly encountered condition of the wrist resulting from compression of the median nerve as it traverses the carpal tunnel, and is characterized by pain, numbness, and paraesthesia of the hand in the distribution of the median nerve.⁴ While there are multiple risk

article published online
March 25, 2024

DOI <https://doi.org/10.1055/s-0043-1778650>.
ISSN 0971-3026.

© 2024. Indian Radiological Association. All rights reserved.
This is an open access article published by Thieme under the terms of the Creative Commons Attribution-NonDerivative-NonCommercial-License, permitting copying and reproduction so long as the original work is given appropriate credit. Contents may not be used for commercial purposes, or adapted, remixed, transformed or built upon. (<https://creativecommons.org/licenses/by-nc-nd/4.0/>)
Thieme Medical and Scientific Publishers Pvt. Ltd., A-12, 2nd Floor, Sector 2, Noida-201301 UP, India

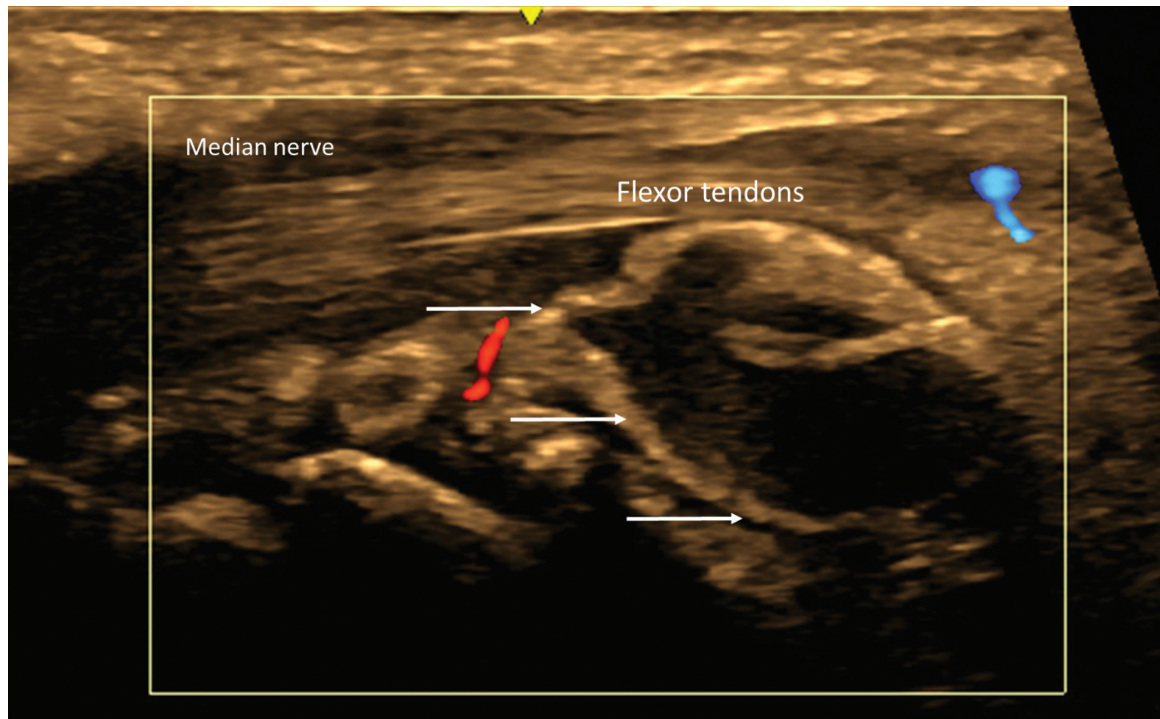


Fig. 1 Longitudinal sonographic view of the wrist demonstrating ill-defined, mass-like calcification within carpal tunnel (white arrow), deep to the flexor tendons and median nerve (labeled). No significant vascularity within the calcification. Also note the isoechoic-to-hyperechoic appearance of calcification and absence of any appreciable acoustic shadowing, features which are characteristic of type 3 calcification.

factors associated with CTS including obesity, repetitive activity of the wrist, pregnancy, genetics, and rheumatoid inflammation, the condition is largely idiopathic.⁴ Calcific deposits within the carpal tunnel resulting in median nerve compression have been established as a rare cause of CTS, and several case reports exist in the literature describing this entity.^{3,5-8}

We described a case of a 45-year-old female patient who presented with excruciating right wrist pain and symptoms of CTS. Ultrasound and radiographs demonstrated ill-defined, mass-like calcification within the right carpal tunnel causing median nerve compression. Ultrasound-guided barbotage was used as a first-line treatment, with a large amount of milky, calcific material aspirated. The patient subsequently reported significant improvement in her symptoms.

The case highlights the importance of recognizing HADD as a lesser-known cause of CTS, and also outlines the valuable role of ultrasound-guided barbotage as a reliable first-line management option, potentially negating the need for the conventional and more invasive carpal tunnel surgery.

Case Report

A 45-year-old female presented with several days of excruciating right volar wrist pain, resulting in marked restriction of wrist movements. There was also significant pain in her hand in the distribution of the median nerve (thenar eminence and three radial digits) with tingling and paraesthesia of the medial aspect of hand. She was otherwise well, with no significant past medical or surgical history. There was no history of trauma to the wrist. This was a first presentation, with no prior history of CTS or arthropathy elsewhere.

On examination, there was markedly reduced range of movement of the right wrist. There was no significant soft tissue swelling or erythema, and no palpable mass was evident. An ultrasound was performed that revealed an amorphous mass-like calcification within the carpal tunnel, deep to the flexor digitorum profundus tendons resulting in stretching and compression of the overlying flexor tendons and the median nerve (→**Fig. 1**) (→**Video 1** and **2**). The mass was avascular on color Doppler. A radiograph was also obtained subsequently which confirmed the presence of a lobulated soft calcification on the volar aspect of the wrist joint (→**Fig. 2**). The appearance of the calcification both on ultrasound and radiograph was typical of that seen with calcific peri-arthritis and hence a provisional diagnosis of HADD was made based on these features.

Video

(**1** and **2**) Long axis (**1**) and short axis (**2**) cine clips demonstrating ill-defined, mass-like calcification within the carpal tunnel deep to the flexor tendons and median nerve. Note the absence of appreciable acoustic shadowing in relation to the calcification and isoechoic to hyperechoic appearance, characteristic of type 3 calcification. Online content including video sequences viewable at: <https://www.thieme-connect.com/products/ejournals/html/10.1055/s-0043-1778650>.

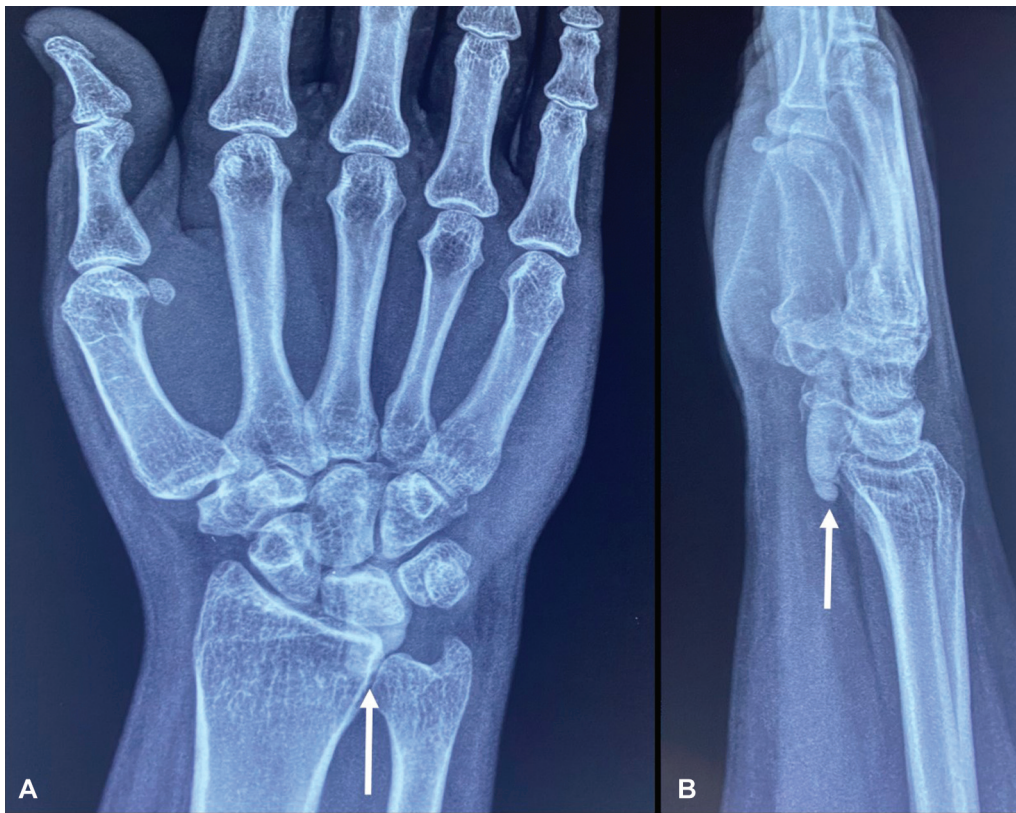

Fig. 2 Anteroposterior (A) and lateral (B) radiographs demonstrating soft, mass-like calcification within the carpal tunnel (white arrows).

The patient was initially managed with ultrasound-guided barbotage of the calcific deposits. After administering local anesthesia, an 18-gauge hypodermic needle was introduced into the mass-like calcification in the carpal tunnel, taking care to avoid the overlying flexor tendons and median nerve. Under direct visualization, the calcification was simultaneously fragmented and flushed with approximately 5 mL of normal saline (► **Video 3**). The contents were then aspirated into a 10 mL syringe via the same needle until the calcification was substantially reduced in size; the latter was visualized in real time (► **Video 4**). A milky white solution was aspirated (► **Fig. 3**). Following this, 40 mg of methylprednisolone acetate, a corticosteroid, was injected into the carpal tunnel.

Video

(3–4) Long axis cine clips demonstrating saline lavage of the calcification (3) followed by aspiration (4). Online content including video sequences viewable at: <https://www.thieme-connect.com/products/ejournals/html/10.1055/s-0043-1778650>.

The procedure was performed in the outpatient department, and the patient was discharged home on the same day after an uneventful 20-minute period of observation. On

subsequent follow-up several days later, the patient reported significant improvement of her initial symptoms, and had regained the ability to move her wrist with minimal pain and restriction. She received ongoing conservative management via her primary care physician.

Discussion

While HADD commonly affects the rotator cuff tendons, in particular the supraspinatus tendon, a range of other periarticular soft tissues can be involved. Calcific deposits may be seen within tendons, tendon sheaths, joint capsules, ligaments, bursae, periarticular connective soft tissues and rarely within the joints³ and retinacula.⁹ While the rotator cuff tendons, particularly the supraspinatus tendon, is most commonly involved, other tendons in less common locations, such as the rectus femoris, can also be involved.¹⁰ Intramuscular involvement has also been reported.¹¹

HADD, when occurring within tendons, can present in three distinct phases, namely precalcific, calcific and postcalcific, as described by Uthoff and Loehr.¹² The calcific stage is further subdivided into formative, resting and resorptive stages. In the pre-calcific phase, fibrocartilaginous metaplasia, probably related to decreased oxygen tension, leads to the formation of calcification, giving rise to the formative stage. In the resorptive phase, cellular reaction around the calcific deposits, and increased vascularity can result in growth of the deposits, which can become poorly defined. This can also result in migration of the calcific

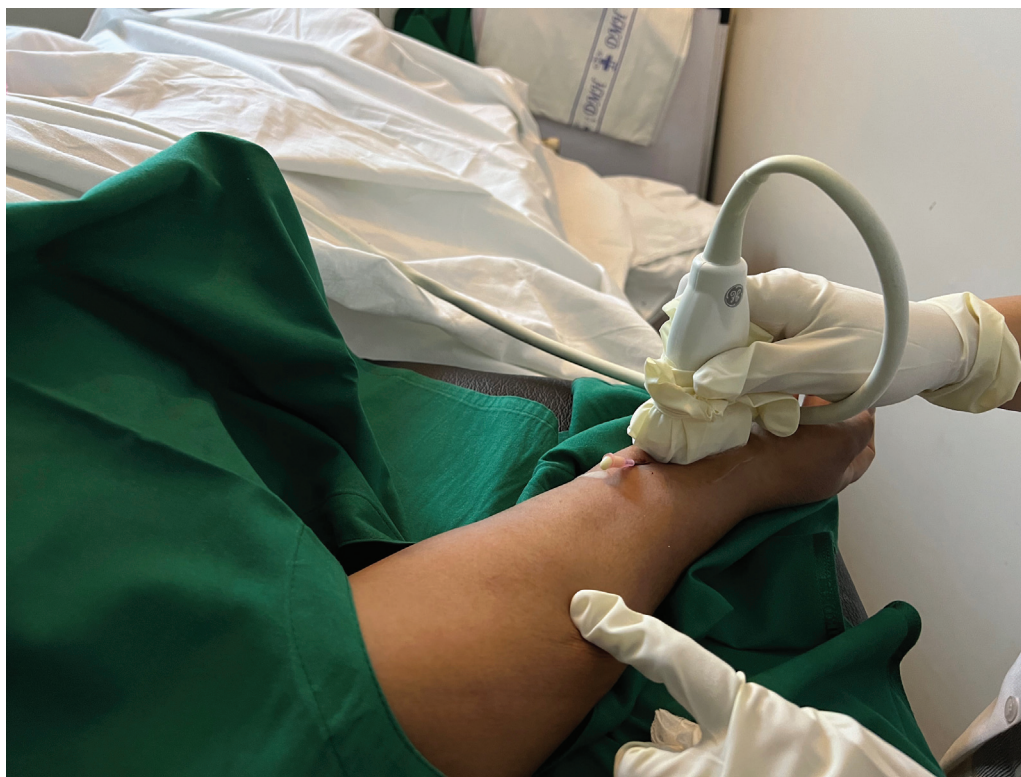

Fig. 3 Ultrasound-guided lavage procedure demonstrating patient and needle position. Note the milky white aspirate of calcific material from the needle.

deposits to surrounding tissues, and hence it is this phase of the disease that is most painful and symptomatic.^{2,12} Post-calcific phase involved formation of granulation tissue and tendon remodeling. Bianchi and Becciolini² described three distinct types of calcification which can be seen in the disease, based on the percentage of calcium within the deposits; type 1 which is calcium rich and correspond to formative and resting phases, and these present as hyperechoic foci with acoustic shadowing on ultrasound; type 2 calcifications which are hyperechoic but only show faint acoustic shadowing, and type 3 calcifications which are isoechoic to tendons, appear ill-defined and show no acoustic shadowing. Types 2 and 3 usually correspond to the resorptive phase and hence more likely to be encountered in acutely symptomatic patients. While the pathogenesis described by Uthoff and Loehr¹² and calcification types described by Bianchi and Becciolini² specifically refer to calcific tendinopathy, similar parallels can be drawn to patients with calcific periarthritis as both conditions result from deposition of hydroxyapatite crystals. The patient described in this report had typical type 3 calcifications, which appeared poorly defined on ultrasound without any acoustic shadowing, and her acute excruciating symptoms at time of presentation suggested the disease was in the resorptive phase.

While the imaging features seen in this case are typical of HADD, it is nonetheless important to consider other potential etiologies in a patient presenting with calcification within the carpal tunnel. These include gout, pseudogout, vascular malformations, tumoral calcinosis, and heterotopic ossification.¹³ The latter can be seen with malunited fractures of the distal

radius.¹³ Neoplasms, particularly synovial sarcoma, which can present as a calcified mass, should also be considered,¹⁴ and when suspected based on preliminary imaging and clinical history, should be investigated further with magnetic resonance imaging prior to attempting any intervention.

Ultrasound-guided barbotage is an established procedure utilized for the treatment of painful calcific tendinopathy and periarthritis of the rotator cuff tendons.¹⁵ It involves a needling and lavaging technique. The procedure has been shown to be effective in the treatment of calcific tendinopathy of the rotator cuff.¹⁰ With ultrasound guidance, a needle is used to fragment the calcific deposits, which attempts to break down the hydroxyapatite crystals, and subsequently flushed with normal saline.¹⁶ The mixture of fragmented calcium hydroxyapatite and the saline mixture is then aspirated, and the contents usually appear as a milky white mixture due to the presence of calcium. A relatively large gauge needle (typically at least an 18-G) needle is used to ensure the fragmented calcifications can be satisfactorily aspirated. The procedure can either be performed as a single- or double-needle technique, the latter utilizing separate needles for fragmentation / saline flush and aspiration.¹⁷ The procedure is often followed by an injection of a corticosteroid into the area, as the anti-inflammatory properties of the steroid can help with analgesia, and improve function.¹⁸

Excellent results have been reported in calcific tendinopathy following partial removal of calcific deposits, due to sufficient disruption and localized bleeding, which facilitates spontaneous resorption of the remaining calcium or its dispersion, in addition to the benefits of directly lavaging

the deposits. Better response has been reported with ill-defined calcifications showing faint acoustic shadowing, and when there is measurable reduction in calcium size and echogenicity post-procedure,¹⁹ as was the case with our patient. While no reports of the utility of this procedure in treatment of CTS due to HADD can be found in the existing literature to the best of our knowledge, satisfactory results have been reported with the use of barbotage for the treatment of HADD in unusual locations other than rotator cuff, such as the spring ligament.²⁰ Given that it is the same entity causing carpal tunnel in this scenario, a similar approach can be used with successful outcomes as demonstrated in this case.

While it is generally a safe procedure, one also needs to be aware of potential complications that may arise from ultrasound-guided barbotage. The complications may be related to the barbotage itself, or secondary to the corticosteroid injection that often accompanies the procedure. Complications related to barbotage include infection, bleeding, tendon rupture, and temporary exacerbation of the inflammation.²¹ In cases involving the carpal tunnel, risk of damage to neurovascular structures including the median nerve, radial artery, and anatomical variants such as a persistent median artery²² should also be considered and discussed with the patient. Performing the procedure under aseptic conditions, and sound procedural technique with adequate needle visualization under ultrasound guidance, taking precautions to avoid critical structures can mitigate these risks. The use of corticosteroid and local anesthetic during the procedure can minimize the exacerbation of symptoms from the procedure. Corticosteroid-related adverse effects are well described in the existing literature that are beyond the scope of this discussion.

Conclusion

HADD can be a rare cause of CTS. Ultrasound and radiographs prove to be valuable tools in diagnosing the condition with a high degree of confidence. Ultrasound-guided barbotage of the calcific deposits is a reliable alternative to surgery in managing these patients and relieving symptoms, potentially negating the need for surgery in some patients.

Patient Consent

Informed consent was obtained from the patient for publication.

Funding

None.

Conflict of Interest

None declared.

References

- Garcia GM, McCord GC, Kumar R. Hydroxyapatite crystal deposition disease. *Semin Musculoskelet Radiol* 2003;7(03):187–193
- Bianchi S, Becciolini M. Ultrasound appearance of the migration of tendon calcifications. *J Ultrasound Med* 2019;38(09):2493–2506
- Krolikowski M, Vargas CR, Chepla KJ, DiLorenzo D. Mass-like calcific peri-arthritis in the wrist: a rare case presenting as acute carpal tunnel syndrome and requiring surgical intervention. *Skeletal Radiol* 2022;51(09):1883–1888
- Genova A, Dix O, Saefan A, Thakur M, Hassan A. Carpal tunnel syndrome: a review of literature. *Cureus* 2020;12(03):e7333
- Harris AR, McNamara TR, Brault JS, Rizzo M. An unusual presentation of acute calcific tendinitis in the hand. *Hand (N Y)* 2009;4(01):81–83
- Duey RE, Beall DP, Ahluwalia JS, Makel MT, Ly JQ. Carpal tunnel syndrome resulting from hydroxyapatite deposition. *Curr Probl Diagn Radiol* 2006;35(06):261–263
- Pai V, Pai V, Muir R. Periarticular calcification causing acute carpal tunnel syndrome: a case report. *J Orthop Surg (Hong Kong)* 2009;17(02):234–237
- Verfaillie S, De Smet L, Leemans A, Van Damme B, Fabry G. Acute carpal tunnel syndrome caused by hydroxyapatite crystals: a case report. *J Hand Surg Am* 1996;21(03):360–362
- Shah A, Iyengar KP, Hegde G, Ramos J, Botchu R. Calcific enthesopathy of the superior extensor retinaculum - an unusual cause of medial ankle pain. *J Ultrason* 2022;22(91):e236–e239
- McLoughlin E, Iqbal A, Tillman RM, James SL, Botchu R. Calcific tendinopathy of the direct head of rectus femoris: a rare cause of groin pain treated with ultrasound guided percutaneous irrigation. *J Ultrasound* 2020;23(03):425–430
- Iyengar KP, Yusta-Zato JA, R B. Calcific tendinopathy of the pronator quadratus muscle: a rare site and cause of ulnar sided wrist pain. *J Clin Orthop Trauma* 2022;32:101968
- Uthoff HK, Loehr JW. Calcific tendinopathy of the rotator cuff: pathogenesis, diagnosis, and management. *J Am Acad Orthop Surg* 1997;5(04):183–191
- Cheng T-F, Chen C-Y, Liu P-T, Yang S-W. Solitary calcified nodules as the cause of carpal tunnel syndrome: two case reports and literature reviews. *Front Neurol* 2019;10:224
- Serinelli S, Gitto L, Zaccarini DJ. Synovial sarcoma of the hand-wrist: a case report and review of the literature. *J Med Case Rep* 2021;15(01):12
- Ahuja A, Lawande M, Daftary AR. Role of radiographs and ultrasound in diagnosing calcific tendinitis and periarthritis in the wrist and hand with ultrasound-guided barbotage as management tool. *Indian J Radiol Imaging* 2021;31(03):605–610
- Tafti D, Byerly DW. Ultrasound-Guided Barbotage. 2023 May 22. In: StatPearls [Internet]. Treasure Island (FL): StatPearls Publishing; 2023 PMID: 34283462
- White R, Croft M, Bird S, Sampson M. Ultrasonography-guided common musculoskeletal interventions from head to toe: procedural tips for general radiologists. *Korean J Radiol* 2021;22(12):2006–2016
- Shah A, Mak D, Davies AM, James SL, Botchu R. Musculoskeletal corticosteroid administration: current concepts. *Can Assoc Radiol J* 2019;70(01):29–36
- McCarthy CL, McNally EG. Chapter 62 - Interventional musculoskeletal ultrasound. In: Allan PL, Baxter GM, Weston MJ, eds. *Clinical ultrasound*. Third edition. Churchill Livingstone: Edinburgh; 2011:1168–1193
- Papineni VRK, Ballal M, Iyengar KP, Botchu R. Hydroxyapatite deposition disease (HADD) of the spring ligament: an unusual cause of medial foot pain. *J Ultrasound* 2023;26(04):923–928
- Gokhan C, Maheshwari S, Nagraj H, Vrizedou S, Tharmalingam T. Complication of barbotage, acute calcific bursitis treated successfully. *J Radiol Case Rep* 2023;17(08):1–7
- Patnaik M, Paul S. Persistent median artery of the forearm and palm: a cadaver study into its origin, course, fate and clinical significance. *Ital J Anat Embryol* 2016;121(01):88–95