



RESEARCH PAPER

# Contemporary use of sentinel lymph node biopsy in the head and neck



Nolan B. Seim<sup>a</sup>, Chadwick L. Wright<sup>b</sup>, Amit Agrawal<sup>a,\*</sup>

<sup>a</sup> Department of Otolaryngology-Head and Neck Surgery, Arthur G. James Cancer Hospital and Richard J. Solove Research Institute, The Ohio State University Wexner Medical Center, 4000 Eye and Ear Institute, 915 Olentangy River Road, Columbus, OH, 43210, USA

<sup>b</sup> Wright Center of Innovation in Biomedical Imaging, Division of Nuclear Medicine and Molecular Imaging, Department of Radiology, The Ohio State University Wexner Medical Center, 395 W, 12th Avenue, Rm. 430, Columbus, OH, 43210, USA

Received 6 April 2016; accepted 11 May 2016  
Available online 25 July 2016

## KEYWORDS

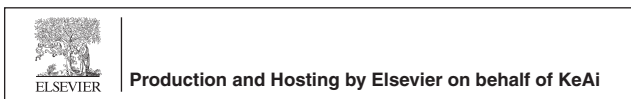Oral cavity cancer;  
Sentinel lymph node;  
Head and neck  
cancer;  
Squamous cell  
carcinoma;  
Lymphoscintigraphy

**Abstract** Sentinel lymph node biopsy has become a well-established and commonplace practice in many oncologic disease sites as a means to stage the regional lymphatics, avoid unnecessary surgery and decrease patient morbidity. In the head and neck, its role is well established for cutaneous melanoma with proven fidelity and survival benefit. Its role in use for other sites such as oral cavity carcinoma continues to develop with promising results from several recent trials. Although not widely adopted, the potential benefits of sentinel lymph node biopsy in the management of oral cavity carcinoma are apparent. Refinements in technology and protocols including development of novel radiopharmaceutical tracers, routine incorporation of detailed anatomic imaging, increasing surgeon experience and development of new intraoperative identification aids will likely lead to improvements in the use and accuracy of this technique.

Copyright © 2016 Chinese Medical Association. Production and hosting by Elsevier B.V. on behalf of KeAi Communications Co., Ltd. This is an open access article under the CC BY-NC-ND license (<http://creativecommons.org/licenses/by-nc-nd/4.0/>).

\* Corresponding author. 320 West 10th Avenue, Rm B-215, Columbus, OH, 43210, USA. Tel.: +1 614 293 8073; fax: +1 614 293 3193.  
E-mail addresses: [Nolan.Seim@osumc.edu](mailto:Nolan.Seim@osumc.edu) (N.B. Seim), [Chadwick.Wright@osumc.edu](mailto:Chadwick.Wright@osumc.edu) (C.L. Wright), [Amit.Agrawal@osumc.edu](mailto:Amit.Agrawal@osumc.edu) (A. Agrawal).

Peer review under responsibility of Chinese Medical Association.



## Introduction

Since its clinical inception in 1992, the role of sentinel lymph node (SLN) biopsy has continued to expand across several surgical oncologic disciplines. Currently, use of SLN biopsy has become routine and regarded as standard of care in clinically node-negative (cN0) cutaneous melanoma as well as breast malignancy. The use of SLN biopsy has also been extensively explored in the head and neck for both cutaneous as well as mucosal malignancy, particularly oral cavity squamous cell carcinoma (SCC), as the presence of nodal metastasis remains the most important factor for recurrence and survival for both melanoma and SCC.<sup>1–4</sup> Traditional efforts to identify the presence of regional nodal disease utilizing history, physical exam, and radiologic imaging lack sufficient sensitivity and specificity in that regard. As such, the use of regional elective neck dissection (END) has been used routinely in the surgical management of head and neck malignancy in cases where risk of occult metastases is significant (>20%). Unfortunately such procedures are invasive, associated with substantial potential morbidity, and furthermore can be argued as unnecessary in a large proportion of patients—i.e. 70%–80% of individuals with T1 or T2 oral cavity carcinoma who ultimately prove negative for nodal metastases.<sup>5</sup> As such, less invasive methods such as SLN biopsy, which accurately predicts the status of regional lymph node basins in cN0 patients, remains of high interest and an active area of investigation.<sup>6,7</sup>

A SLN is defined as the first lymph node (or nodes) on a direct lymphatic drainage pathway from a primary tumor site, and as such, is hypothesized as the most likely location to harbor occult metastasis.<sup>8</sup> When identified and histopathologically assessed, the SLN allows prediction of the regional metastatic potential of that given tumor. Donald Morton originally introduced the application of SLN biopsy in low grade trunk and extremity melanoma as a means to spare roughly 80% of cN0 patients unnecessary lymphadenectomy without sacrificing survival advantage.<sup>9–11</sup>

The adoption of SLN biopsy for head and neck cancer sites was associated with early controversy however. Concern for unpredictable watershed lymphatics, multiple regional nodal basins with adjacent proximity to primary tumors, as well nearby vital structures raised concern regarding both feasibility and accuracy of SLN procedures in this region and led to early hesitation in accepting its use.<sup>12</sup> Over the past several years, however, increasing evidence has become available supporting its use in head and neck cancer, particularly for cutaneous melanoma as well as mucosal SCC of the oral cavity. In 2012, the largest single institution series of prospective data on SLN biopsy in melanoma was published demonstrating its safety and accuracy in 353 patients with a negative predictive value (NPV) of 95.8% and no major surgical complications.<sup>13</sup> Similarly, several prospective multi-institutional studies have yielded promising results examining the role of SLN biopsy in early stage oral cavity SCC.<sup>14–16</sup> Despite seemingly encouraging data however, routine use of SLN biopsy for cN0 oral cavity SCC has not been widely embraced as there remain several issues and caveats regarding its use in this area. These are outlined in the subsequent discussion as

well as novel strategies and technologies employed or being investigated in an effort to address several of these issues as well as those which may serve to improve the overall efficacy and accuracy of SLN biopsy in the head and neck region.

## Evidence-based perioperative technologies, techniques and strategies

Since its inception, much attention and research has been directed at optimizing efficacy and accuracy of SLN biopsy procedures. Protocols for this require significant coordination and attention to detail among multiple departments and hospital services involved in preoperative, intraoperative, and postoperative clinical care.

### Preoperative imaging

Use of perioperative imaging is commonly employed to allow SLN identification and localization prior to surgery and to assist with operative planning. This typically involves preoperative peritumoral injection of a radiotracer several hours prior to surgery. This tracer can then be visualized via various radio-imaging lymphoscintigraphy technologies including planar gamma camera imaging and single photon emission computed tomography (SPECT) with or without concomitant cross-sectional X-ray computed tomography (CT). This tracer can also be detected during surgery using intraoperative radio-guidance equipment such as a hand-held gamma probe.

More specifically, conventional lymphoscintigraphy with planar gamma camera imaging (i.e., 2D assessment), typically shows Technetium-99m-labeled (<sup>99m</sup>Tc) nanocolloids as they migrate from the injection site, identifying lymphatic pathways and eventually SLNs. Very little anatomic data is provided by this modality however and only number, location, and laterality of nodal basins at risk for metastatic disease can be inferred.<sup>8</sup> In recent years however, newer modalities including SPECT/CT which yield tomographic 3D-imaging, provide surgeons with more far more detailed and surgically relevant anatomy with regard to SLN location. At present, SPECT is typically performed using a single-head or dual-headed gamma camera system which acquires a series of 2D images while incrementally rotating 360° around the head and neck region. These images are then reconstructed into a tomographic 3D dataset which can be subsequently viewed in any 2D orientation (e.g., axial, sagittal or coronal SPECT). If X-ray CT images of the head and neck are also obtained, these images can then be used for fusion with the emission SPECT images for anatomical localization of radiotracer deposition (i.e., hybrid SPECT/CT). This allows for more anatomically precise localization of radiolabeled SNL(s) with respect to the complex anatomy of the head and neck.

Previous studies have demonstrated the clinical utility and advantages of SPECT/CT imaging compared to conventional methods.<sup>17,18</sup> Several reports have demonstrated that use of SPECT/CT resulted in alternations of the planned surgical approach more often than not when compared with use of conventional 2-D lymphoscintigraphy alone.<sup>19,20</sup>

Additionally, in one prospective study, use of SPECT/CT was compared to lymphoscintigraphy alone and found to be significantly superior in melanoma by identifying more total SLNs (2.40 vs 1.87; 95% *CI* 1.93–2.18), more positive SLNs (0.34 vs 0.21; 95% *CI* 0.21–0.31) and resulting in an increased 4-year disease free survival (93.9% vs 79.2%;  $P = 0.02$ ).<sup>21</sup> In the current era of precision medicine, it is likely that the use of more detailed perioperative anatomic imaging such as SPECT/CT will become more routinely incorporated in SLN biopsy procedures.

### Intraoperative lymphatic mapping

Although timing can be variable, operative identification and excision of SLNs typically occurs within a few hours of radiotracer injection and imaging. A second method of lymphatic mapping may be employed in the operating room as a visual adjunct utilizing methylene blue, or similar dye material, which is injected peritumorally prior to tumor and SLN excision. The dye is absorbed into the lymphatics traversing afferent lymphatic vessel(s) and eventually depositing in the SLNs which can subsequently be identified during dissection via both radio-guidance using hand-held gamma probe as well as direct visualization via staining.

Prior to incision, the surgeon typically scans the regional basin(s) using a hand-held gamma probe to verify and confirm localization of suspected SLNs. Often the primary tumor is then resected first, particularly if proximity of the primary tumor to potential adjacent SLNs might interfere with radio-guided identification and dissection (i.e. “shine-through effect” referring to primary tumor radio-activity obscuring nearby radio-active SLNs therefore limiting accurate SLN detection). SLN biopsy incision(s) are then planned to allow for adequate access and dissection for identified of nodes identified using the gamma probe for directional surgical guidance and activity confirmation. Suspected lymph nodes are verified both *in vivo* and *ex vivo*.

In addition to use of the intraoperative gamma probe for radio-guidance, portable gamma camera (PGC) technology is available enabling another means of real-time detection, image-guided resection, and verification of *ex vivo* radio-labeled tissues including SLNs.<sup>22,23</sup> Pre-incision intra-operative PGC imaging can also be used to rapidly identify discrete foci of radiotracer activity for targeted resection along with the hand-held surgical gamma probe. After resection, PGC imaging of the *ex vivo* specimen can rapidly verify the presence or lack of radiotracer activity as well. Likewise, PGC imaging of the surgical bed can quickly verify complete resection (i.e., lack of focal radiotracer activity in the surgical bed) or incomplete resection (i.e., persistent radiotracer activity). Intraoperative PGC imaging is not limited to <sup>99m</sup>Tc-based agents either as it has been described in indium-111-pentetreotide for image-guided resection of somatostatin receptor avid malignancies like gastrinoma.<sup>24</sup> Accordingly, the use of dual intra-operative surgical techniques (methylene blue and intraoperative radio-guidance) for SLN identification has been shown to improve sensitivity for detection in utilization of both audio and visual cues.<sup>25,26</sup>

One feature of any radio-colloid is that it possesses the potential to transit beyond primary echelon node(s),

whereby additional lymph nodes (i.e. non SLNs) may be found to emit some degree of radioactivity and thus become detected. Clearly the removal of all such radioactive nodes, many of which may not be biologically relevant, is impractical and defeats the purpose of SLN biopsy. Initially historical, a common threshold of activity for a SLN has been defined as any node demonstrating 10% or greater radio-activity compared to the hottest node *ex vivo*; typically up to 4 nodes per basin. Assessment of this 10% threshold has been validated including one study in which a 4% increase in false negative rate (FNR) was observed when the SLN threshold was increased to 20% activity of the hottest node and an 11% increase in FNR was observed when only the hottest node was removed.<sup>27</sup>

### Postoperative analysis

Following excision, all SLNs are submitted for histopathologic analysis. Current recommendations are for excised SLNs to undergo serial sectioning as well as hematoxylin and eosin (H&E) staining by an experienced pathologist in order to detect micrometastatic nodal disease. In melanoma, the use of immuno-histochemical (IHC) staining (i.e. Melan-A, S-100, HMB-45) is considered standard to aid identification of nodal micrometastases and results in detection of a higher proportion of SLNs involved with tumor.<sup>28</sup> Similarly, IHC techniques utilizing anti-cytokeratin antibodies (AE1/AE3) are increasingly employed in addition to traditional H&E methodology to detect occult nodal disease in oral cavity/pharyngeal SCC. A higher sensitivity for occult nodal disease detection is seen when serial step sectioning and IHC is used compared to H&E assessment alone.<sup>29,30</sup>

### Standard of care in cutaneous melanoma

Support for SLN biopsy as the standard of care in low to intermediate grade melanoma is based on its overwhelmingly supportive data, extensive clinical use and incorporation into national and international consensus statements.<sup>31</sup> Many cases occur in younger patients as well, highlighting the need for appropriate aggressive treatment without undue risk in managing this malignancy. The ability to accurately stage a disease not only guides surgical and adjuvant treatment decisions but also identifies those for clinical trial enrollment when needed.<sup>31</sup>

SLN biopsy is therefore an ideal strategy in melanoma as only 20% of patients with stage I or II disease will be found to have occult regional metastasis and therefore benefit from lymphadenectomy. Its fidelity has been confirmed in numerous reports showing a false negative rate under 5% and identification that the pathologic status of the SLN is the most important prognostic factor for recurrence and survival.<sup>1,13</sup> As such, SLN biopsy is the most specific and sensitive means for regional staging in the absence of END.

As experience with SLN biopsy in cutaneous melanoma has grown, the patient population most likely to benefit from this technique has become more well-defined. One prospective study used both univariate analysis and a multivariate model to concluded patients with a Breslow depth greater than 1 mm or with a lesion depth <1 mm and an additional adverse feature should undergo SLN biopsy.

Prognostic factors identified include: ulceration, extensive regression to 1.0 mm, young age, mitotic rate  $\geq 1/\text{mm}^2$ , angiolymphatic invasion and positive deep margin.<sup>32</sup> The use of SLN biopsy has been confirmed to increase disease-free survival and melanoma-specific survival in these patient cohorts.<sup>13,33</sup>

This standardization of patient selection, pathologic criteria and evidence-based imaging and operative techniques stands as a model for future expansion of SLN use as well as other surgical advances. The World Health Organization (WHO) has issued a statement regarding SLN biopsy as representing the standard of care for melanoma and "a starting point for future policies on surgery and adjuvant treatment strategies."<sup>34</sup> Subsequently, SLN biopsy has become incorporated into National Comprehensive Cancer Network (NCCN) guidelines and recommended by American Society of Clinical Oncology and Society of Surgical Oncology.

### SLN biopsy in oral cavity squamous cell carcinoma

Using cutaneous melanoma as a model for success, SLN biopsy has been extensively explored in oral cavity squamous cell carcinoma (OSCC). Traditional efforts to identify the presence of occult regional nodal disease in cN0 OSCC patients utilizing history, physical exam, and radiologic imaging lacks sufficient sensitivity and specificity in that regard.<sup>6,7</sup> As such, the use of END has been used routinely in the surgical management of OSCC in cases where risk of occult metastases is  $>20\%$ . Unfortunately END is invasive, associated with substantial potential for morbidity, and furthermore can be argued to be unnecessary in a large proportion of patients—i.e. 70–80% of individuals with T1 or T2 oral cavity carcinoma who ultimately prove without nodal metastases.<sup>5,35–38</sup> As such, less invasive methods such as SLN biopsy used to predict the status of regional lymph node basin in cN0 patients may serve to reduce patient morbidity associated with END (scar/contour deformity, facial/shoulder weakness, neuropathic pain/numbness).<sup>16,39,40</sup>

The accuracy of SLN biopsy for OSCC has been published in numerous well-constructed, prospective multi-institutional studies (Table 1). In 2010, Alkureishi et al reported results in 134 subjects with T1-2 N0 oral cavity or oropharyngeal cancer who were prospectively studied as part of a European multi-institutional trial. Patients either underwent SLN biopsy alone or SLN biopsy in combination with END. SLNs were identified in 93% (125/134) of cases

with a lower rate of SLN identification for floor-of-mouth (FOM) tumors (88% vs 96%;  $P = 0.138$ ). Overall a FNR of 9% of was seen after long term follow-up. Additionally, when FOM tumors were analyzed separately, sensitivity and NPV of SLN biopsy were significantly worse compared to all other sites (80% vs 97% and 88% vs 98% respectively;  $P = 0.034$ ).<sup>16</sup>

Similarly in 2010, the American College of Surgeons Oncology Group published the results of a multi-institutional cooperative group study in the United States involving 25 institutions over a 3-year period. This study assessed patients with T1-2 cN0 OSCC, selecting 140 subjects undergoing SLN biopsy followed by planned END. In this group, the observed NPV of SLN biopsy was 96% and a FNR of 9.8% was seen. Similar to prior studies, SLN biopsy results were worse for FOM tumors. In addition to disease subsite, tumor size (T2 vs T1 tumors) as well as lesser surgeon experience were cited as factors reducing accuracy of SLN biopsy.<sup>14</sup>

More recently, a 3-year update on the Sentinel European Node Trial (SENT) trial sponsored by the European Organization for Research and Treatment of Cancer (EORTC) has been reported. In this trial, since 2005, 14 European centers recruited 415 patients with T1-2 N0 oral cavity SCC having undergone SLN biopsy followed by therapeutic neck dissection (for positive SLN) vs observation with a median follow-up of 52 months. A SLN was identified in 99.5% of cases with 23% (94/415) positivity for nodal involvement. False-negative result occurred in 15/109 patients (patients with negative SLN biopsy who subsequently developed regional disease) yielding a FNR of 14%. The NPV for SLN biopsy was 95%. Interestingly, in patients who underwent subsequent therapeutic neck dissection following identification of positive SLN, 22/94 (23.4%) patients suffered recurrence of disease with the majority (16 of 22 cases) recurring in the already-operated neck.<sup>15</sup>

It is clear by these 3 multicenter, prospective trials that SLN biopsy for OSCC is a valid and promising technique, as evidenced by high success in identifying SLNs and consistently high negative predictive value ( $>95\%$ ). Unlike its counterpart in cutaneous melanoma, however, use of SLN biopsy in oral cavity squamous carcinoma has continued to face several challenges and caveats which have likely served to hinder its widespread adoption for use in management of OSCC. These factors have included:

- **False negative rate:** despite high negative predictive value of SLN biopsy for OSCC demonstrated in several prospective trials, the FNR of SLN biopsy in these same

**Table 1** Summary of prospective multi-institution studies for SLN biopsy in OSCC.

Authors	Subjects	Radiotracer/agent	Accuracy (%)	Negative predictive value (%)	False negative rate (%)	False negative rate floor of mouth subsite (%)
Civantos FJ, et al <sup>14</sup>	140	<sup>99m</sup> Tc-sulfur colloid	95	96	9.8	25
Schilling C, et al <sup>15</sup>	415	<sup>99m</sup> Tc nanocolloid + blue dye	96	95	14	13
Alkureishi LW, et al <sup>16</sup>	134	<sup>99m</sup> Tc colloid + blue dye	93	95	9	20
Agrawal A, et al <sup>46</sup>	83	<sup>99m</sup> Tc-tilmanocept	99	98	2.6	0

SLN, sentinel lymph node; OSCC, oral cavity squamous cell carcinoma.

trials has ranged from 9% to 14%. Although not unreasonable, FNR in this range could still be considered suboptimal and source of unreliability when considering SLN biopsy. Factors identified which appear to contribute to a higher FNR include tumor subsite (i.e. floor of mouth tumors) where the phenomenon of "shine-through effect" can obscure identification of relevant adjacent SLNs, larger tumors (T2 or larger lesions where radiotracer distribution is less uniform/consistent), and lesser surgeon experience with SLN biopsy procedures.<sup>14,16</sup>

- **Lack of reliable real-time SLN information:** use of frozen section analyses for SLN assessment yields suboptimal sensitivity in detecting occult nodal disease with sensitivity rates reported less than 50% in some series.<sup>41</sup> Current SLN assessment methodology involving serial specimen sectioning and IHC techniques requires a time-frame of several days for reliable actionable results. Unfortunately, this time-frame remains uncondusive to situations where a single surgical procedure is preferable for both surgeons and patients—for example those patients in whom major reconstruction is required (i.e. microvascular free tissue transfer) where re-entry in to the neck is not desirable, patients who are medically fragile, or in patients in whom staged/delayed procedures would delay/prolong recommended adjuvant treatment measures.
- **Multiple SLN pathways/nodal basins:** one major feature of the head and neck is the variability of lymphatic drainage pathways from a primary tumor to the regional basin where it is not uncommon for multiple SLNs at multiple levels or even contralateral neck drainage to be identified.<sup>15</sup> Given this potential, the procedure for SLN biopsy carried out at multiple levels and/or neck bilaterally can become a technically time-consuming procedure for which it could be argued that the effort/morbidity of SLN biopsy in these cases may be on par with that carried out during END when performed by experienced hands. It is certainly plausible that factors such as those above may cause even experienced head and neck sentinel node surgeons to elect to proceed with END rather than SLN biopsy.

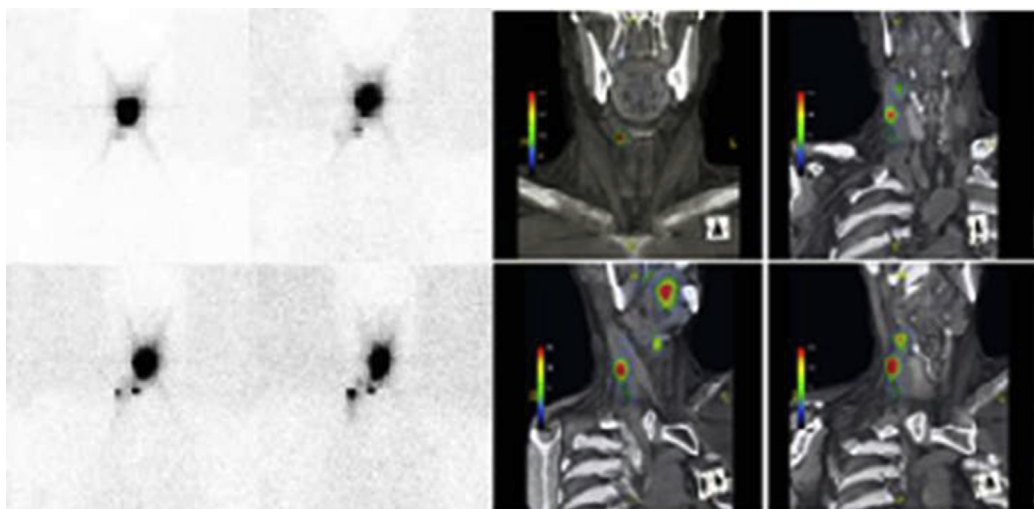
Despite the noted drawbacks of traditional SLN biopsy in OSCC, there exist several promising developing refinements of SLN biopsy procedures which may serve to address issues of reliability, accuracy and ease of use in this patient population. It is hoped that recent technologic advances in development of novel radiotracer agents may lead to improvements in SLN biopsy accuracy by overcoming some of these obstacles associated with traditional agents such as radiolabeled colloid. Due to its particulate nature and unstandardized variation in preparation (100–1000 nm diameter), <sup>99m</sup>Tc radiolabeled colloid is retained for prolonged periods within the injection site increasing the phenomenon of "shine-through effect" which likely contributes to lack of identification of relevant SLN particularly for FOM tumors which are in close proximity to relevant level I neck lymphatics and may thus contribute to FNR associated with SLN procedures.<sup>16,42</sup>

<sup>99m</sup>Tc–diethylenetriamine penta-acetic acid–mannosyl–dextran (<sup>99m</sup>Tc–tilmanocept; Lymphoseek®; Navidea

Biopharmaceuticals Inc, Dublin, OH, USA) is a novel targeted radiopharmaceutical agent approved by the FDA and European Medicines Agency for use in SLN mapping and intraoperative procedures in cases of cutaneous melanoma, breast cancer, and OSCC.<sup>43</sup> Tilmanocept is a soluble synthetic molecule with a dextran-10 backbone and multiple mannose side moieties, making it a CD-206 receptor–targeted radiopharmaceutical with several unique properties compared to radiolabeled colloid. First, as a soluble molecule, it has a small diameter, and exhibits more rapid clearance from the injection site which is hypothesized to reduce "shine-through effect." Second, by binding to the CD-206 mannose-binding receptors located on nodal reticuloendothelial cells, it possesses specificity for nodal tissues allowing sustained SLN uptake without distal lymph node accumulation.<sup>44,45</sup> These properties of Tilmanocept may yield a specific advantage when used for SLN procedures for oral cavity tumors.

The efficacy of <sup>99m</sup>Tc–tilmanocept was investigated in a prospective phase 3, multicenter, single arm study of 83 patients who underwent SLN biopsy per standard protocol followed by planned END at the same surgical setting. At least 1 SLN was identified in 81/83 patients (98%). Thirty-nine patients were found to have occult nodal metastasis based upon histopathologic assessment of SLNs and END specimens. Importantly, only 1 false-negative occurred with this protocol yielding a FNR of 2.6%, NPV of 97.8% and overall accuracy of 98.8%.<sup>46</sup> In addition this series included 20 subjects with floor of mouth tumors, 12 of whom were identified with metastatic nodal disease, and all of whom were identified via SLN biopsy yielding FNR of 0% for this particular subsite.<sup>46</sup> Of note, all of these floor of mouth tumor patients underwent radiopharmaceutical injection the day before surgery as mandated by protocol. The FNR rate was not significantly different as to whether patients underwent tracer injection the day before surgery vs injection on the day of surgery suggesting leeway in injection timing relative to planned surgery (typically within 24 h). Interestingly, the surgeons involved in this trial were all relatively experienced in SLN procedures which may also have led to observed excellent results. Although a head-to-head trial between Tilmanocept and radiocolloid has not been reported, these results overall remain quite promising regarding use of this agent in head and neck SLN procedures.

Another refinement with regard to SLN procedures for oral cavity tumors relates to pre-operative imaging and assessment. Standard perioperative imaging techniques with 2-dimensional planar lymphoscintigraphy has limited value and offers little insight to lymphatic drainage patterns or precise anatomic location of relevant SLNs due to poor anatomic detail as well as shine-through via primary site injection.<sup>16</sup> Anatomic detailed volumetric imaging modalities such as hybrid SPECT/CT offers surgically relevant topographical orientation and delineation of SLNs in relation to adjacent anatomy offering an advantage for surgical planning as well as for delineation of primary tumors from relevant SLNs which might otherwise be obscured via planar imaging techniques (Fig. 1). Several recent studies appear to suggest this advantage using SPECT/CT over planar imaging which may further reduce false negative results.<sup>43,46</sup>



**Fig. 1** 2-D conventional planar lymphoscintigraphy and fused SPECT/CT in evaluation of a patient with floor-of-mouth carcinoma and the relationship of sentinel lymph node location to anatomic landmarks.

The lack of reliable real-time pathologic information pertaining to SLNs, remains a major obstacle to its routine use in head and neck procedures. Efforts aimed toward rapid intra-operative tumor identification in SLNs via molecular methodology currently represents an active area of investigation. One study using automated quantitative real-time polymerase chain reaction (qRT-PCR) to quantify expression of 11 tumor-associated genes identified 2 gene markers for subsequent analyses and validation testing – pemphigus vulgaris antigen (PVA) and tumor-associated calcium signal transducer 1 (TACSTD1), also known as epithelial cell adhesion molecule (EpCAM). Testing of this methodology demonstrated ability to create an automated, reproducible, and rapid process (35 min) with high accuracy of ~96% NPV in identifying nodal tumor involvement.<sup>47</sup> In practice such a process, if accurate and reliable, would practically allow for intra-operative decision making (i.e. need for END) and thus avoid staged operative procedures. As such, the development of practical real-time diagnostic abilities as it pertains to SLN assessment may represent the next most significant advancement in the management of OSCC and thus remove a major hurdle to the use of SLN procedures in this setting.

Additional roles for SLN procedures can be gleaned from data regarding regional nodal behavior in OSCC. Ganly et al reviewed 164 patients from 1985 to 2005, with early, low-risk T1-2 oral tongue SCC treated at Memorial Sloan-Kettering Cancer Center and Princess Margaret Cancer Center in patients having undergone partial glossectomy and ipsilateral END without adjuvant radiation (margin negative, pathologic node negative). This series demonstrated a regional recurrence rate of approximately 20%, and surprisingly, in 39% of these cases, regional recurrence occurred in the contralateral neck and appeared to be linked to factors including original tumor thickness (>4 mm).<sup>48</sup> In the European SENT trial, contralateral neck metastasis was also identified in 12% of cases of lateralized oral tumors.<sup>15</sup> This information points toward a potential unique role that SLN procedures may play in identifying unexpected drainage patterns for OSCC including

contralateral neck or nodal basins outside of typical planned END which may require specific attention during either SLN biopsy or END procedures and merit further formal prospective study in the future.

### New and emerging approaches for advanced molecular imaging

Newer developments in molecular imaging are currently explored as a means to improve SLN efficacy and accuracy. It has been demonstrated that <sup>99m</sup>Tc-labeled nanocolloids can be simultaneously labeled with a near-infrared (NIR) dye, indocyanine green (ICG), in order to facilitate real-time fluorescent visualization of SLNs and lymphatic drainage pathways. ICG is a dicyanine fluorescent imaging agent that emits in the NIR spectrum around 800 nm.<sup>49</sup> One particular dual-labeled agent, ICG–<sup>99m</sup>Tc-nanocolloid, allows for conventional pre-surgical imaging with lymphoscintigraphy as well as SPECT/CT and hand-held surgical gamma probing but also enables rapid fluorescent detection of SLNs during surgery. This particular agent proved superior for the visual detection of SLNs when compared with standard blue dyes with a particular role in head and neck cancer due to proximity of nodal basins.<sup>50–54</sup> Furthermore, no apparent difference in the lymphatic drainage patterns for the dual-labeled ICG–<sup>99m</sup>Tc-nanocolloid agent is found when compared to the conventional <sup>99m</sup>Tc-labeled nanocolloid.<sup>55</sup> At present, there are approximately 7000 optical imaging systems approved for imaging ICG-based agents. When combined with conventional lymphoscintigraphy and current radio-guided surgical approaches, dual-labeled imaging agents like ICG–<sup>99m</sup>Tc-nanocolloid and these intraoperative fluorescent imaging systems promise to enhance the surgeon's ability to rapidly detect and completely resect fluorescently labeled lesions.<sup>56–58</sup>

Another novel approach to improve accuracy in SLN identification is through the use of positron-emission tomography (PET) agents. One such agent used is Zirconium-

89-labeled nanocolloidal albumin which has been reported to enable more precise localization of SLNs when compared with conventional imaging approaches.<sup>59</sup> Although PET-based agents may not be easily imaged within the surgical suite, new operative room approaches have been described for the targeted excision of radiolabeled lymph nodes containing the PET radiotracer fluorine-18 fluorodeoxyglucose (<sup>18</sup>F-FDG) using existing hand-held surgical probes and *ex vivo* specimen PET/CT imaging.<sup>60</sup> Additionally real-time optical imaging of PET-radiolabeled lymph nodes called Cerenkov Luminescence Imaging (CLI) is now available as well. Cerenkov luminescence refers to the visible light produced when a positron is emitted and then passes through the aqueous medium of cells and tissues.<sup>61–63</sup> These light photons can be readily and rapidly detected using bioluminescence imaging systems and the *in vivo* CLI for lymph nodes labeled with <sup>18</sup>F-FDG has already been described clinically.<sup>64</sup> The role for the use of these newer intraoperative adjuncts has not yet been defined but clearly provide unique surgical advantages.

## Conclusions

Sentinel lymph node biopsy procedures have become well-established and commonplace for disease sites including cutaneous melanoma and breast malignancy. Its use for other sites such as oral cavity carcinoma continues to develop with promising results from several recent prospective trials. Refinements in technology including development of novel radiopharmaceutical tracers, routine incorporation of detailed anatomic perioperative imaging, emerging imaging modalities, as well as increasing surgeon experience will likely lead to improvements in use and accuracy of this technique and improved adoption of SLN procedures in the management of OSCC.

## Conflict of interests

The authors declare that there are no conflicts of interest regarding the publication of this paper.

## Acknowledgments

CLW is supported by (1) Grant no. IRG-67-003-50 from the American Cancer Society, (2) Award no. UL1TR000090 from the National Center For Advancing Translational Sciences (The content is solely the responsibility of the authors and does not necessarily represent the official views of the National Center For Advancing Translational Sciences or the National Institutes of Health), (3) Richard P. & Marie R. Bremer Medical Research Fund and William H. Davis Endowment for Basic Medical Research from The Ohio State University Medical Center (The remarks and opinions are the sole responsibility of the authors and do not necessarily reflect the views of the Davis/Bremer Research Fund or The Ohio State University Medical Center), (4) the National Institutes of Health (NIH)/National Cancer Institute (NCI), Clinical Loan Repayment Program, and (5) Wright Center of Innovation in Biomedical Imaging and Ohio TECH 10-012.

## References

- Balch CM, Gershenwalk JE, Soong SJ, et al. Final version of 2009 AJCC melanoma staging and classification. *J Clin Oncol.* 2009;27:6199–6206.
- Alvi A, Johnson JT. Extracapsular spread in the clinically negative neck (N0): implications and outcome. *Otolaryngol Head Neck Surg.* 1996;114:65–70.
- Mamelle G, Pampurik J, Luboinski B, et al. Lymph node prognostic factors in head and neck squamous cell carcinomas. *Am J Surg.* 1994;168:494–498.
- Rassekh CH, Johnson JT, Myers EN. Accuracy of intraoperative staging of the N0 neck in squamous cell carcinoma. *Laryngoscope.* 1995;105:1334–1336.
- Kligerman J, Lima RA, Soares JR, et al. Supraomohyoid neck dissection in the treatment of T1/T2 squamous cell carcinoma of oral cavity. *Am J Surg.* 1994;168:391–394.
- de Bondt RB, Nelemans PJ, Hofman PA, et al. Detection of lymph node metastases in head and neck cancer: a meta-analysis comparing US, USgFNAC, CT and MR imaging. *Eur J Radiol.* 2007;64:266–272.
- Kyzas PA, Evangelou E, Denaxa-Kyza D, Ioannidis JP. 18F-fluorodeoxyglucose positron emission tomography to evaluate cervical node metastases in patients with head and neck squamous cell carcinoma: a meta-analysis. *J Natl Cancer Inst.* 2008;100:712–720.
- Nieweg OE, Tanis PG, Kroon BER. The definition of a sentinel lymph node. *Ann Surg Oncol.* 2001;9:538–541.
- Morton DL, Wen DR, Wong JH, et al. Technical details of intraoperative lymphatic mapping for early stage melanoma. *Arch Surg.* 1992;127:392–399.
- Balch CM. The role of elective lymph node dissection in melanoma: rationale, results, and controversies. *J Clin Oncol.* 1988;6:163–172.
- Sim FH, Taylor WF, Ivins JC, Pritchard DJ, Soule EH. A prospective randomized study of the efficacy of routine elective lymphadenectomy in management of malignant melanoma. Preliminary results. *Cancer.* 1978;41:948–956.
- O'Brien CJ, Uren RF, Thompson JF, et al. Prediction of potential metastatic sites in cutaneous head and neck melanoma using lymphoscintigraphy. *Am J Surg.* 1995;170:461–466.
- Erman AB, Collar RM, Griffith KA, et al. Sentinel lymph node biopsy is accurate and prognostic in head and neck melanoma. *Cancer.* 2012;118:1040–1047.
- Civantos FJ, Zitsch RP, Schuller DE, et al. Sentinel lymph node biopsy accurately stages the regional lymph nodes for T1–T2 oral squamous cell carcinomas: results of a prospective multi-institutional trial. *J Clin Oncol.* 2010;28:1395–1400.
- Schilling C, Stoeckli SJ, Haerle SK, et al. Sentinel European Node Trial (SENT): 3-year results of sentinel node biopsy in oral cancer. *Eur J Cancer.* 2015;51:2777–2784.
- Alkureishi LW, Ross GL, Shoab T, et al. Sentinel node biopsy in head and neck squamous cell cancer: 5-year follow-up of a European multicenter trial. *Ann Surg Oncol.* 2010;17:2459–2464.
- Remenschneider AK, Dilger AE, Wang Y, Palmer EL, Scott JA, Emerick KS. The predictive value of single-photon emission computed tomography/computed tomography for sentinel lymph node localization in head and neck cutaneous malignancy. *Laryngoscope.* 2015;125:877–882.
- Jimenez-Heffernan A, Ellmann A, Sado H, et al. Results of a prospective multicenter international atomic energy agency sentinel node trial on the value of SPECT/CT over planar imaging in various malignancies. *J Nucl Med.* 2015;56:1338–1344.
- Zender C, Guo T, Weng C, Faulhaber P, Rezaee R. Utility of SPECT/CT for periparotid sentinel lymph node mapping in the

- surgical management of head and neck melanoma. *Am J Otolaryngol*. 2014;35:12–18.
20. Vermeeren L, Valdes Olmos RA, Klop WM, et al. SPECT/CT for sentinel lymph node mapping in head and neck melanoma. *Head Neck*. 2011;33:1–6.
  21. Stoffels I, Boy C, Poppel T, et al. Association between sentinel lymph node excision with or without pre-operative SPECT/CT and metastatic node detection and disease-free survival in melanoma. *JAMA*. 2012;308:1007–1014.
  22. Vermeeren L, Valdes Olmos RA, Klop WM, Balm AJ, van den Brekel MW. A portable gamma-camera for intraoperative detection of sentinel nodes in the head and neck region. *J Nucl Med*. 2010;51:700–703.
  23. Hall NC, Plews RL, Agrawal A, et al. Intraoperative scintigraphy using a large field-of-view portable gamma camera for primary hyperparathyroidism: initial experience. *Biomed Res Int*. 2015;2015:930575.
  24. Hall NC, Nichols SD, Pivoski SP, et al. Intraoperative use of a portable large field of view gamma camera and handheld gamma detection probe for radioguided localization and prediction of complete surgical resection of gastrinoma: proof of concept. *J Am Coll Surg*. 2015;221:300–308.
  25. Bostick P, Essner R, Sarantou T, et al. Intraoperative lymphatic mapping for early-stage melanoma of the head and neck. *Am J Surg*. 1997;174:536–539.
  26. Alex JC, Weaver DL, Fairbank JT, et al. Gamma-probe guided lymph node localization in malignant melanoma. *Surg Oncol*. 1993;2:303–308.
  27. Kroon HM, Lowe L, Wong S, et al. What is a sentinel node? Reevaluating the 10% rule for sentinel lymph node biopsy in melanoma. *J Surg Oncol*. 2007;95:623–628.
  28. Yu LL, Thomas FJ, Tanabe KK. Detection of microscopic melanoma metastases in sentinel lymph nodes. *Cancer*. 1999;84:617–627.
  29. Chone CT, Aniteli MB, Magalhaes RS, et al. Impact of immunohistochemistry in sentinel lymph node biopsy in head and neck cancer. *Eur Arch Otorhinolaryngol*. 2013;270:313–317.
  30. Shoaib T, Soutar DS, Prosser JE, et al. A suggested method for sentinel node biopsy in squamous cell carcinoma of the head and neck. *Head Neck*. 1999;21:728–733.
  31. Schmalbach CE, Bradford CR. Is sentinel lymph node biopsy standard of care in cutaneous head and neck melanoma. *Laryngoscope*. 2015;125:153–160.
  32. Pack SC, Griffith KA, Johnson TM, et al. The impact of factors beyond Breslow depth on predicting sentinel lymph node positivity in melanoma. *Cancer*. 2007;109:100–108.
  33. Gershenwald JE, Thompson W, Mansfield PF, et al. Multi-institutional melanoma lymphatic mapping experience: the prognostic value of sentinel lymph node status in 612 stage I or II melanoma patients. *J Clin Oncol*. 1999;17:976–983.
  34. Cascinelli N. *WHO Declares Lymphatic Mapping to be Standard of Care for Melanoma*. Available at: <http://www.cancernetwork.com/articles/whodeclares-lymphatic-mapping-be-standard-care-melanoma>. Accessed 07.02.16.
  35. Rogers SN, Ferlito A, Pellitteri PK, et al. Quality of life following neck dissections. *Acta Otolaryngol*. 2004;124:231–236.
  36. Schmitz S, Machiels JP, Weynand B, et al. Results of selective neck dissection in the primary management of head and neck squamous cell carcinoma. *Eur Arch Otorhinolaryngol*. 2009;266:437–443.
  37. Chone CT, Magalhaes RS, Etchehebere E, et al. Predictive value of sentinel node biopsy in head and neck cancer. *Acta Otolaryngol*. 2008;128:920–924.
  38. Bilde A, von Buchwald C, Therkildsen MH, et al. Need for intensive histopathologic analysis to determine lymph node metastases when using sentinel node biopsy in oral cancer. *Laryngoscope*. 2008;118:408–414.
  39. Schiefke F, Akdemir M, Weber A, et al. Function, postoperative morbidity, and quality of life after cervical sentinel node biopsy and after selective neck dissection. *Head Neck*. 2009;31:503.
  40. Thompson CF, St John MA, Lawson G. Diagnostic value of sentinel lymph node biopsy in head and neck cancer: a meta-analysis. *Eur Arch Otorhinolaryngol*. 2013;270:2115–2122.
  41. Vorburger MS, Broglie MA, Soltermann A, et al. Validity of frozen section in sentinel lymph node biopsy for staging in oral and oropharyngeal squamous cell carcinoma. *J Surg Oncol*. 2012;106:816–819.
  42. Stoeckli SJ. Sentinel node biopsy for oral and oropharyngeal squamous cell carcinoma of the head and neck. *Laryngoscope*. 2007;117:1539–1551.
  43. Marcinow AM, Hall N, Byrum E, et al. Use of a novel receptor-targeted (CD206) radiotracer, 99m Tc-tilmanocept, and SPECT/CT for sentinel lymph node detection in oral cavity squamous cell carcinoma: initial institutional report in an ongoing phase 3 study. *JAMA Otolaryngol Head Neck Surg*. 2013;139:895–902.
  44. Wallace AM, Hoh CK, Ellner SJ, Darrah DD, Schulteis G, Vera DR. Lymphoseek: a molecular imaging agent for melanoma sentinel lymph node mapping. *Ann Surg Oncol*. 2007;14:913–921.
  45. Ellner SJ, Hoh CK, Vera DR, Darrah DD, Schulteis G, Wallace AM. Dose-dependent biodistribution of [(99m)Tc] DTPA-mannosyl-dextran for breast cancer sentinel lymph node mapping. *Nucl Med Biol*. 2003;30:805–810.
  46. Agrawal A, Civantos FJ, Brumund KT, et al. (99m)Tc]Tilmanocept accurately detects sentinel lymph nodes and predicts node pathology status in patients with oral squamous cell carcinoma of the head and neck: results of a phase III multi-institutional trial. *Ann Surg Oncol*. 2015;22:3708–3715.
  47. Ferris RL, Stefanika P, Xi L, et al. Rapid molecular detection of metastatic head and neck squamous cell carcinoma as an intraoperative adjunct to sentinel lymph node biopsy. *Laryngoscope*. 2012;122:1020–1030.
  48. Ganly I, Goldstein D, Carlson DL, et al. Long-term regional control and survival in patients with “low-risk,” early stage oral tongue cancer managed by partial glossectomy and neck dissection without postoperative radiation: the importance of tumor thickness. *Cancer*. 2013;119:1168–1176.
  49. Olive M. *Image-guided Surgery. Dye Chemistries, Targeting Agents, Camera Systems, Preclinical Preparations, and Market Overview*. Lincoln, NE: Olive Consulting; 2014.
  50. Christensen A, Juhl K, Charabi B, et al. Feasibility of real-time near-infrared fluorescence tracer imaging in sentinel node biopsy for oral cavity cancer patients. *Ann Surg Oncol*. 2016;23:565–572.
  51. van den Berg NS, Brouwer OR, Schaafsma BE, et al. Multimodal surgical guidance during sentinel node biopsy for melanoma: combined gamma tracing and fluorescence imaging of the sentinel node through use of the hybrid tracer indocyanine green-(99m)Tc-nanocolloid. *Radiology*. 2015;275:521–529.
  52. Stoffels I, Leyh J, Poppel T, Schadendorf D, Klode J. Evaluation of a radioactive and fluorescent hybrid tracer for sentinel lymph node biopsy in head and neck malignancies: prospective randomized clinical trial to compare ICG-(99m)Tc-nanocolloid hybrid tracer versus (99m)Tc-nanocolloid. *Eur J Nucl Med Mol Imaging*. 2015;42:1631–1638.
  53. van den Berg NS, Brouwer OR, Klop WM, et al. Concomitant radio- and fluorescence-guided sentinel lymph node biopsy in squamous cell carcinoma of the oral cavity using ICG-(99m)Tc-nanocolloid. *Eur J Nucl Med Mol Imaging*. 2012;39:1128–1136.
  54. Brouwer OR, Klop WM, Buckle T, et al. Feasibility of sentinel node biopsy in head and neck melanoma using a hybrid radioactive and fluorescent tracer. *Ann Surg Oncol*. 2012;19:1988–1994.
  55. Brouwer OR, Buckle T, Vermeeren L, et al. Comparing the hybrid fluorescent-radioactive tracer indocyanine green-99mTc-nanocolloid with 99mTc-nanocolloid for sentinel node



- identification: a validation study using lymphoscintigraphy and SPECT/CT. *J Nucl Med.* 2012;53:1034–1040.
56. Loja MN, Luo Z, Greg Farwell D, et al. Optical molecular imaging detects changes in extracellular pH with the development of head and neck cancer. *Int J Cancer.* 2013;132:1613–1623.
  57. van Dam GM, Themelis G, Crane LM, et al. Intraoperative tumor-specific fluorescence imaging in ovarian cancer by folate receptor-alpha targeting: first in-human results. *Nat Med.* 2011;17:1315–1319.
  58. Heath CH, Deep NL, Sweeny L, Zinn KR, Rosenthal EL. Use of panitumumab-IRDye800 to image microscopic head and neck cancer in an orthotopic surgical model. *Ann Surg Oncol.* 2012;19:3879–3887.
  59. Heuveling DA, van Schie A, Vugts DJ, et al. Pilot study on the feasibility of PET/CT lymphoscintigraphy with <sup>89</sup>Zr-nanocolloidal albumin for sentinel node identification in oral cancer patients. *J Nucl Med.* 2013;54:585–589.
  60. Povoski SP, Hall NC, Murrey Jr DA, Wright CL, Martin Jr EW. Feasibility of a multimodal (18)F-FDG-directed lymph node surgical excisional biopsy approach for appropriate diagnostic tissue sampling in patients with suspected lymphoma. *BMC Cancer.* 2015;15:378.
  61. Holland JP, Normand G, Ruggiero A, Lewis JS, Grimm J. Intraoperative imaging of positron emission tomographic radiotracers using Cerenkov luminescence emissions. *Mol Imaging.* 2011;10:177–186, 1–3.
  62. Robertson R, Germanos MS, Li C, Mitchell GS, Cherry SR, Silva MD. Optical imaging of Cerenkov light generation from positron-emitting radiotracers. *Phys Med Biol.* 2009;54:N355–N365.
  63. Spinelli AE, D'Ambrosio D, Calderan L, Marengo M, Sbarbati A, Boschi F. Cerenkov radiation allows in vivo optical imaging of positron emitting radiotracers. *Phys Med Biol.* 2010;55:483–495.
  64. Thorek DL, Riedl CC, Grimm J. Clinical Cerenkov luminescence imaging of (18)F-FDG. *J Nucl Med.* 2014;55:95–98.

Edited by Jie Gao