

## Chandelier-assisted retroillumination for phacoemulsification in phacovitrectomy

Manish P Nagpal, Sheetal A Mahuvakar, Pranita Prakash Chaudhary, Navneet S Mehrotra, Ashish K Jain

**Purpose:** To describe chandelier-assisted retroillumination for phacoemulsification in patients with poor fundal glow due to posterior segment pathology during combined phacovitrectomy procedure. **Methods:** This was a prospective observational study. Thirty eyes underwent combined phacoemulsification and 25G sutureless pars plana vitrectomy. Sclerotomy port for chandelier tip was made in the inferotemporal or superonasal quadrant based on the incision site for phacoemulsification. Later, it was replaced with infusion cannula or endoilluminator. Cases included had posterior segment pathologies such as vitreous hemorrhage and vitritis. **Results:** Red reflex was markedly enhanced during phacoemulsification for all cases. In all eyes, a continuous curvilinear capsulorhexis was achieved without the use of dye. The posterior capsule remained intact in all cases. The visual acuity in all patients improved, and the median best-corrected visual acuity was 20/60 (range: 4/60–20/30) at 6 months. There were no intraoperative or postoperative complications. **Conclusion:** Cases with poor red reflex pose a challenge for anterior segment surgeons, and chandelier-assisted retroillumination proves to be a safe and effective tool in combined phacovitrectomy surgeries. Moreover, no additional cannula port is required for this chandelier insertion.

**Key words:** Chandelier, phacovitrectomy, retroillumination, vitreous hemorrhage

Pars plana vitrectomy (PPV) is used to treat posterior segment disorders such as vitreous hemorrhage and vitreous opacities. Cataracts often co-occur with vitreoretinal pathology, leading to suboptimal surgical outcomes and impaired visibility of the posterior segment during vitreoretinal surgery. Cataract is known to develop faster after vitrectomy.<sup>[1]</sup> In addition, phacoemulsification is technically more difficult to perform in vitrectomized eyes because of the lack of vitreous support.<sup>[2]</sup>

Combined surgery allows better posterior segment visibility and clearing of the vitreous base and faster visual recovery, eliminating the need for a second surgery.<sup>[3,4]</sup> However, cataract surgery in combined procedures can be challenging because of the poor red reflex caused by vitreous hemorrhage and vitritis.<sup>[5,6]</sup> To overcome the challenges in eyes with compromised red reflex, various techniques have been attempted.<sup>[7-9]</sup> Anterior capsule staining with dye, surgeon, or assistant-held intravitreal endoilluminators has been mentioned in literature. A potential complication of staining is corneal endothelial toxicity,<sup>[10]</sup> and it does not aid in the phacoemulsification steps. With handheld illumination, there is the potential for iatrogenic retinal and lens damage.<sup>[9]</sup>

Hence, there is need for a safe and effective technique for enhancing the red reflex in such scenarios to optimize the surgical outcome.

Chandelier illuminating system is now increasingly used in vitrectomy to enhance the endoillumination, at the same time

Department of Retina, Retina Foundation and Eye Research Clinic, Asopalav Eye Hospital, Ahmedabad, Gujarat, India

**Correspondence to:** Dr. Manish P Nagpal, Retina Foundation and Eye Research Clinic, Asopalav Eye Hospital, Shahibagh Under Brigde, Ahmedabad, Gujarat, India. E-mail: drmanishnagpal@yahoo.com

**Manuscript received:** 16.01.18; **Revision accepted:** 13.04.18

### Access this article online

#### Website:

www.ijo.in

#### DOI:

10.4103/ijo.IJO\_85\_18

### Quick Response Code:



allowing a bimanual approach on account of its self-retaining ability.

Here, we describe the use of a 25-gauge chandelier-assisted retroillumination for phacoemulsification in combined cases having a poor glow due to posterior segment pathologies.

## Methods

From November 2016 to November 2017, 30 patients with coexisting cataract and posterior segment pathology causing poor or absent fundus glow underwent microincision phacoemulsification aided by chandelier retroillumination combined with 25G PPV. Intraoperative complications were noted. Patients were examined on postoperative day 1, 1-month, 3-month, and 6-month interval. Informed consent was obtained from all patients. The authors adhered to the tenets of the Declaration of Helsinki. The study protocol was approved by the Institutional Ethics Committee.

## Surgical technique

Peribulbar anesthesia was administered in all cases. All surgeries were performed on the Alcon Constellation Vision System (Alcon Laboratories, Inc. Fort Worth, Texas, USA). Surgeries were performed as a combined procedure by anterior segment and vitreoretinal surgeon. A single sclerotomy was

This is an open access journal, and articles are distributed under the terms of the Creative Commons Attribution-NonCommercial-ShareAlike 4.0 License, which allows others to remix, tweak, and build upon the work non-commercially, as long as appropriate credit is given and the new creations are licensed under the identical terms.

**For reprints contact:** reprints@medknow.com

**Cite this article as:** Nagpal MP, Mahuvakar SA, Chaudhary PP, Mehrotra NS, Jain AK. Chandelier-assisted retroillumination for phacoemulsification in phacovitrectomy. Indian J Ophthalmol 2018;66:1094-7.

made in the inferotemporal or superonasal quadrant [Fig. 1a] at a distance of 3.5 mm from the limbus depending on the placement of the clear corneal incision. Chandelier tip was introduced after a valved cannula insertion. A 2.2 mm clear corneal and two sideport incisions were made at 11, 9, and 2 o'clock positions. Likewise, in patients in whom a temporal phacoemulsification was planned, incisions were placed accordingly. Chandelier light was turned on to enhance the fundus glow and operating microscope, and room lights were turned off. Xenon light source supplied within the Constellation Vision System was used for chandelier illumination. Continuous curvilinear capsulorhexis (CCC) was followed by phacoemulsification [Fig. 1a-c]. The phacoemulsification parameters used for immature cataract were 100% linear OZil torsional phacoemulsification and linear vacuum with an upper limit of 350 mmHg. Aspiration rate was set at 28 cc/min. Direct phaco chop method was used for immature cataract. In mature cataract, a stop and chop technique was employed with 100% linear OZil torsional phacoemulsification, linear vacuum with an upper limit of 80 mmHg and aspiration rate was set at 26 cc/min during sculpting.

Cortex removal and posterior capsule polishing were performed under chandelier-assisted retroillumination [Fig. 1d]. Further, foldable intraocular lens was implanted in the bag, and irrigation and aspiration for the removal of viscoelastic were done. The clear corneal incision was sutured whenever the anterior chamber was not found to be stable at the end of phacoemulsification. Sclerotomies were made in superonasal and superotemporal quadrants. Chandelier tip was replaced with 25-gauge infusion line in the inferotemporal quadrant. Vitrectomies were performed using 25-gauge instruments.

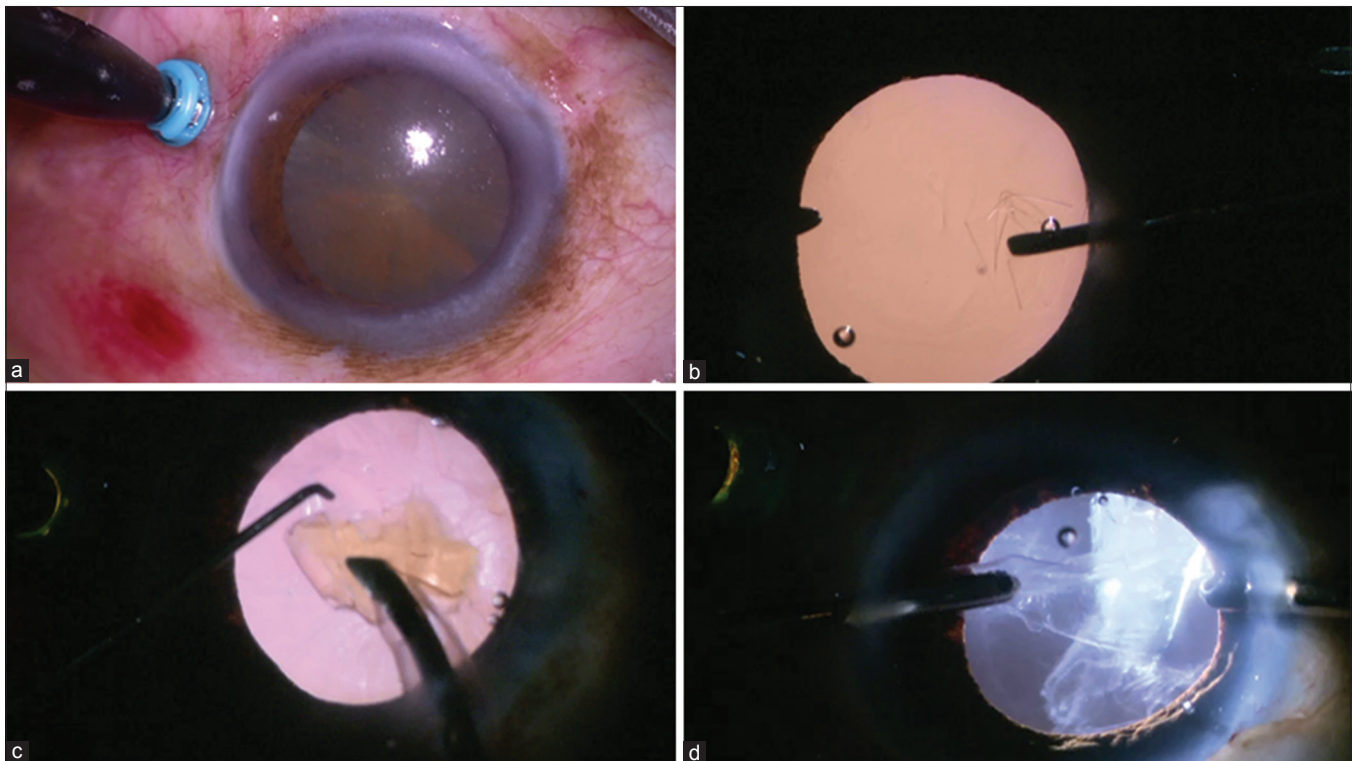
Standard 3-port PPV was carried out, comprising core vitrectomy, a complete peripheral shave, with membrane peeling and endolaser photocoagulation whenever needed.

## Results

The study included 30 eyes. The mean age of patients was 62.5 years, ranging from 55 to 72 years. Of 30 patients, 18 were male and 12 were female. The study had 20 right and 10 left eyes' involvement. Cause of poor red reflex was vitreous hemorrhage in 28 eyes (proliferative diabetic retinopathy in 25 eyes and branch retinal vein occlusion in 3 eyes) and vitritis in 2 eyes. Four patients had associated mature cataract. The preoperative visual acuity ranged from light perception to 20/300. The median follow-up was 4.5 months (range: 3–12 months).

The patients' baseline characteristics and postoperative outcomes are shown in Table 1.

Red reflex was achieved during phacoemulsification in all cases, providing good visualization of the anterior capsule, posterior capsule, lens structure, and cortex. In all eyes, a CCC was achieved without the use of dye, and the posterior capsule remained intact in all cases. Retroillumination was especially useful in cortex wash that enabled visualization of the cortical matter that was otherwise obscured due to compromised red reflex. The visual acuity in all patients improved, and the median best-corrected visual acuity was 20/60 (range: 4/60–20/30) at 6 months. There were no intraoperative or postoperative complications. There was no incidence of phototoxicity noted in our series. In four cases, clear corneal incision was sutured.



**Figure 1:** (a) A single sclerotomy is made in the inferotemporal quadrant at a distance of 3.5 mm from the limbus. 25G chandelier tip was introduced after a valved cannula insertion. (b) Capsulorhexis is performed under retroillumination without the use of dye. (c) Phacoemulsification is carried out with ease with the help of chandelier illumination. (d) Retroillumination is especially helpful for visualizing posterior capsule for removal of cortex

**Table 1: Demographic details**

Demographic parameters	Patients
Total patients	30
Mean age (years)	62.5±20 (range: 55-72)
Sex	
Male	18
Female	12
Eye	
Right	20
Left	10
Cataract	
Mature	4
Immature	26
Cause of poor red reflex	
Vitreous hemorrhage	28
Vitreitis	2
Cataract	
Immature cataract	26
Mature cataract	4
Best-corrected visual acuity	
Preoperative	Light perception to 20/300
Postoperative	4/60-20/30

## Discussion

In the era of microincisions, phacoemulsification and PPV are commonly performed as a combined procedure not only to the patients advantage in reducing the recovery time and cost<sup>[11-13]</sup> but also it enables the vitreoretinal surgeon a clear view during vitrectomy.<sup>[3,4]</sup>

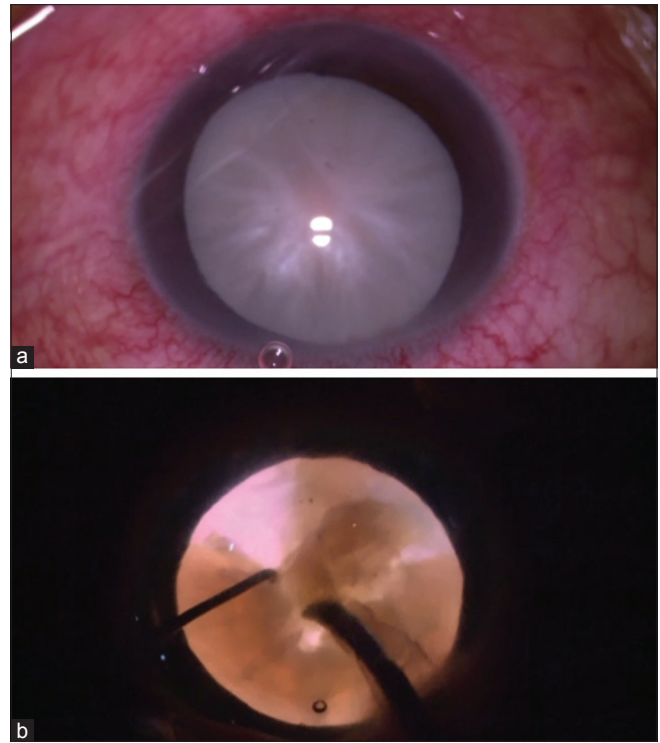
However, combined surgery is technically difficult, which may result in increased operating time and intraoperative complications as the red reflex is often compromised due to posterior segment pathologies.<sup>[5,6]</sup>

In the past, various techniques have been attempted to enhance the fundus glow.

The endoilluminator-assisted technique was described in patients undergoing cataract with decompensated cornea.<sup>[14,15]</sup> Yamamoto *et al.* described a two-step technique, in which the anterior capsule was stained with trypan blue for CCC, and retroillumination was achieved with a conventional handheld endoilluminator.<sup>[7]</sup> Kim *et al.* also used surgeon-controlled-endoillumination technique for the removal of cortex.<sup>[9]</sup>

Although endoilluminator has the advantage that it does not require any special instruments, the technique has its own fallacies. Performing phacoemulsification with endoilluminator in one hand has a long learning curve. It is associated with an increased risk of iatrogenic retinal tear and posterior capsule damage.<sup>[9]</sup> Chandelier has the advantage in that it is self-retaining, thus adding to surgeon's comfort.

In this study, the chandelier retroillumination markedly enhanced the red reflex so that the lens structures, especially the lens capsule, were seen more clearly. Staining of the anterior capsule was not needed in any case. Excellent visualization



**Figure 2:** (a) The light from the 25-gauge chandelier allows an excellent glow through the mature cataract as well. (b) It facilitates phacoemulsification in mature cataract allowing an intact posterior capsule

of the posterior capsule made polishing easier, thus reducing the risk of posterior capsular opacity formation. In addition, there is no extra step or incision when using chandelier retroillumination as chandelier tip was replaced with infusion cannula eventually.

Jang *et al.* used illuminated infusion chandelier in all the phacoemulsification steps in six patients with immature cataract and vitreous hemorrhage.<sup>[6]</sup> Bilgin and Kayikcioglu used dye for staining anterior capsule and a 23G illuminated infusion chandelier in patients with nuclear cataract with minimal cortical cataract and severe vitreous hemorrhage.<sup>[16]</sup> There were four cases of mature cataract in our series [Fig. 2a]. The light from the 25-gauge chandelier improved visualization of the anterior capsule and lens structures enough to facilitate successful CCC and phacoemulsification in mature cataract as well [Fig. 2b].

Yet, there is a theoretical risk of chandelier tip movement inducing retinal breaks and lens damage.<sup>[17,18]</sup> We did not observe any retinal complications. Moreover, lens damage is inconsequential since a cataract surgery was anyways an integral part of our combined procedure.

The use of endoillumination technique is associated with a risk for retinal phototoxicity due to longer period of light exposure.<sup>[19,20]</sup> None of our cases had any signs of phototoxicity noted in the follow-up period. Moreover, all the cases in this study had media opacity in the form of vitreous pathologies such as vitreous hemorrhage or vitritis, which anyways reduced the overall light reaching the retina and macula during the phaco procedure, and so the risk of

phototoxicity is minimized. Further, the chandelier tip is positioned 4–6 mm away from the posterior pole, which also reduces the exposure.

## Conclusion

Cases with poor red reflex pose a challenge for anterior segment surgeons, and chandelier-assisted retroillumination proves to be a safe and effective tool in combined phacovitrectomy surgeries. Moreover, no additional cannula port is required for this chandelier insertion. The same cannula port is used for eventually putting the infusion for the vitrectomy component, which makes it less traumatic.

## Financial support and sponsorship

Nil.

## Conflicts of interest

There are no conflicts of interest.

## References

- Hsuan JD, Brown NA, Bron AJ, Patel CK, Rosen PH. Posterior subcapsular and nuclear cataract after vitrectomy. *J Cataract Refract Surg* 2001;27:437-44.
- Demetriades AM, Gottsch JD, Thomsen R, Azab A, Stark WJ, Campochiaro PA, *et al.* Combined phacoemulsification, intraocular lens implantation, and vitrectomy for eyes with coexisting cataract and vitreoretinal pathology. *Am J Ophthalmol* 2003;135:291-6.
- Hwang JU, Yoon YH, Kim DS, Kim JG. Combined phacoemulsification, foldable intraocular lens implantation, and 25-gauge transconjunctival sutureless vitrectomy. *J Cataract Refract Surg* 2006;32:727-31.
- Sisk RA, Murray TG. Combined phacoemulsification and sutureless 23-gauge pars plana vitrectomy for complex vitreoretinal diseases. *Br J Ophthalmol* 2010;94:1028-32.
- Lee VY, Kwok AK. Multiport-illumination-system-assisted phacoemulsification in eyes with dense vitreous hemorrhage during combined cataract and vitreous surgery. *J Cataract Refract Surg* 2003;29:1252-5.
- Jang SY, Choi KS, Lee SJ. Chandelier retroillumination-assisted cataract extraction in eyes with vitreous hemorrhage. *Arch Ophthalmol* 2010;128:911-4.
- Yamamoto N, Ozaki N, Murakami K. Trypan-blue- and endoillumination-assisted phacoemulsification in eyes with vitreous hemorrhage during combined cataract and vitreous surgery. *Ophthalmologica* 2005;219:338-44.
- Jung Y, Kim IN, Yoon J, Lee JY, Kim KH, Lee DY, *et al.* Intracamerular illuminator-assisted advanced cataract surgery combined with 23-gauge vitrectomy in eyes with poor red reflex. *J Cataract Refract Surg* 2013;39:845-50.
- Kim KH, Sohn HJ, Song HJ, Lee DY, Nam DH. Surgeon-controlled-endoillumination-guided irrigation and aspiration during combined 23-gauge sutureless vitrectomy and cataract surgery in eyes with poor fundus reflex. *J Cataract Refract Surg* 2010;36:2028-31.
- Buzard K, Zhang JR, Thumann G, Stripecke R, Sunalp M. Two cases of toxic anterior segment syndrome from generic trypan blue. *J Cataract Refract Surg* 2010;36:2195-9.
- Chung TY, Chung H, Lee JH. Combined surgery and sequential surgery comprising phacoemulsification, pars plana vitrectomy, and intraocular lens implantation: Comparison of clinical outcomes. *J Cataract Refract Surg* 2002;28:2001-5.
- Hurley C, Barry P. Combined endocapsular phacoemulsification, pars plana vitrectomy, and intraocular lens implantation. *J Cataract Refract Surg* 1996;22:462-6.
- Koenig SB, Mieler WF, Han DP, Abrams GW. Combined phacoemulsification, pars plana vitrectomy, and posterior chamber intraocular lens insertion. *Arch Ophthalmol* 1992;110:1101-4.
- Nishimura A, Kobayashi A, Segawa Y, Sugiyama K. Endoillumination-assisted cataract surgery in a patient with corneal opacity. *J Cataract Refract Surg* 2003;29:2277-80.
- Oshima Y, Shima C, Maeda N, Tano Y. Chandelier retroillumination-assisted torsional oscillation for cataract surgery in patients with severe corneal opacity. *J Cataract Refract Surg* 2007;33:2018-22.
- Bilgin S, Kayikcioglu O. Chandelier retroillumination-assisted cataract surgery during vitrectomy. *Eye (Lond)* 2016;30:1123-5.
- Hu Y, Si S, Xu K, Chen H, Han L, Wang X, *et al.* Outcomes of scleral buckling using chandelier endoillumination. *Acta Ophthalmol* 2017;95:591-4.
- Imai H, Tagami M, Azumi A. Scleral buckling for primary rhegmatogenous retinal detachment using noncontact wide-angle viewing system with a cannula-based 25 G chandelier endoilluminator. *Clin Ophthalmol* 2015;9:2103-7.
- Michels M, Lewis H, Abrams GW, Han DP, Mieler WF, Neitz J, *et al.* Macular phototoxicity caused by fiberoptic endoillumination during pars plana vitrectomy. *Am J Ophthalmol* 1992;114:287-96.
- Koch FH, Schmidt HP, Mönks T, Blumenröder SH, Haller A, Steinmetz RL, *et al.* The retinal irradiance and spectral properties of the multiport illumination system for vitreous surgery. *Am J Ophthalmol* 1993;116:489-96.