



## NOTE

Surgery

# Atlantooccipital overlapping and its effect on outcomes after ventral fixation in dogs with atlantoaxial instability

Fumitaka TAKAHASHI<sup>1,2)\*</sup>, Takaharu HAKOZAKI<sup>1)</sup>, Shigenori KOUNO<sup>1)</sup>,  
Shuji SUZUKI<sup>1)</sup>, Asaka SATO<sup>3)</sup>, Nobuo KANNO<sup>1)</sup>, Yasuji HARADA<sup>1)</sup>,  
Shinya YAMAGUCHI<sup>1,2)</sup> and Yasushi HARA<sup>1)</sup>

<sup>1)</sup>The Laboratory of Veterinary Surgery, Nippon Veterinary and Life Science University, 1-7-1 Kyonan, Musashino-shi, Tokyo 180-0023, Japan

<sup>2)</sup>YPC Tokyo Animal Orthopedic Surgery Hospital, 7-1-13 Oojima, Koutou-ku, Tokyo 136-0072, Japan

<sup>3)</sup>Azabu University Veterinary Teaching Hospital, 1-17-71 Fuchinobe, Chuou-ku, Sagamihara-shi, Kanagawa 252-5201, Japan

**ABSTRACT.** We compared clinical outcomes after ventral fixation in dogs with atlantoaxial instability (AAI) on the basis of the presence or absence of atlantooccipital overlapping (AOO). Of 41 dogs diagnosed with AAI and treated ventral fixation, 12 exhibited AOO (AOO group), whereas 29 did not (non-AOO group). The AOO group had significantly higher neurological scores before ( $P=0.024$ ) and 1 month after ( $P=0.033$ ) surgery compared with the non-AOO group; however, no significant differences were observed between the groups 2 months after surgery. The presence of complicating AOO affected the clinical signs for dogs with AAI, but did not directly affect the outcome of surgical stabilization of AAI.

**KEY WORDS:** atlantoaxial instability (AAI), atlantooccipital overlapping (AOO), surgical outcome, ventral fixation

*J. Vet. Med. Sci.*  
80(3): 526–531, 2018  
doi: 10.1292/jvms.17-0438

Received: 8 August 2017  
Accepted: 16 January 2018  
Published online in J-STAGE:  
5 February 2018

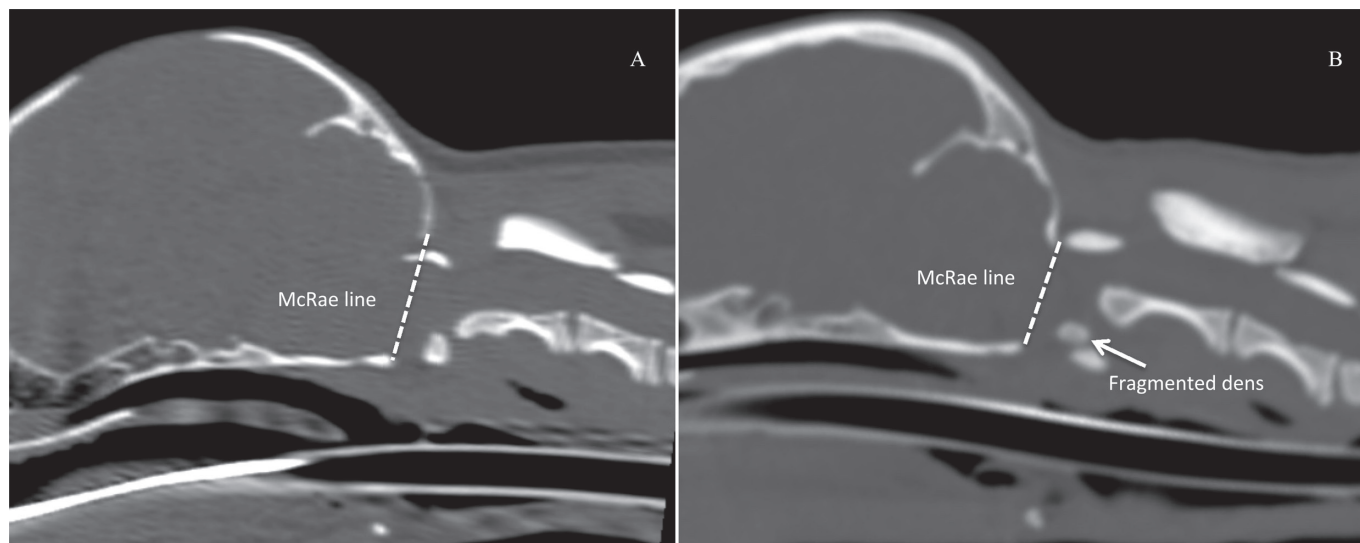
Atlantoaxial instability (AAI) most commonly affects young, small dog breeds [2, 6, 17, 25, 28], and was first reported in dogs in 1967 by Geary *et al.* [9]. AAI occurs secondary to subluxation or dislocation of the atlantoaxial joint, resulting from congenital dysplasia or injury of the atlas or axis [6, 8, 9, 13, 15, 17, 20, 28, 30, 31]. Congenital dysplasia includes aplasia or hypoplasia of the dens, nonunion of the dens with the axis, dorsal angulation of the dens, and incomplete ossification of the atlas. Injury includes fracture or ligament rupture. Marino *et al.* described AAI as a general group of disorders caused by congenital dysplasia in the area from the occipital bone to the cranial cervical vertebrae, and proposed the term craniocervical junction abnormality (CJA) [16]. CJA includes Chiari-like malformation, atlantooccipital instability (AOI), AAI, occipitoatlantoaxial malformation, atlantooccipital overlapping (AOO), dorsal compression (DC), cerebellar compression and dens abnormality. Treatment of AAI includes surgical and conservative management; however, surgical treatment is recommended for cases with neurological abnormalities, severe neck pain, and those with a poor response to conservative management [11, 17, 24]. Ventral stabilization, commonly used for treatment of AAI, has a high success rate and low mortality rate, and rarely requires further surgery [2, 6, 10, 14, 22, 23, 28]. Dorsal decompression may also be performed if necessary [3, 5, 19, 27, 29] and preoperative planning is based on advanced imaging. Cerda-Gonzalez *et al.* reported that although radiographs can confirm a diagnosis of AAI, magnetic resonance imaging (MRI) and computed tomography (CT) provide a complete assessment of the junction of the head and neck [4]. Disturbances in the circulation of cerebrospinal fluid at the junction of the medulla oblongata and the cervical spine have been implicated in the development of syringomyelia and hydrocephalus in dogs with CJA [3, 4, 7]. AOO affects the clinical signs and prognosis for dogs with abnormalities of the junction between the head and neck [4]. Cerda-Gonzalez *et al.* reported that one in four dogs with AOO that undergo dorsal decompression (foramen magnum decompression and dorsal laminectomy of the atlas) exhibit improvement in the symptoms [4]. However, to our knowledge, no convalescent study on AOO has been conducted with a large population to clarify the actual effects of surgical technique on AOO outcomes. Pressure on the spinal cord caused by the dens displacing the axis is generally considered to affect the clinical signs in AAI cases [9, 17, 24]. Even if concurrence of AOO is confirmed in AAI cases, at first, ensuring stabilization of the atlantoaxial joint should be prioritized. In recent years, preoperative MRI and CT examinations have provided opportunities to diagnose complicating dysplasia at the junction of the head and neck; however, the pathology and

\*Correspondence to: Takahashi, F.: takataka.pc1138@gmail.com

©2018 The Japanese Society of Veterinary Science



This is an open-access article distributed under the terms of the Creative Commons Attribution Non-Commercial No Derivatives (by-nc-nd) License. (CC-BY-NC-ND 4.0: <https://creativecommons.org/licenses/by-nc-nd/4.0/>)



**Fig. 1.** Computed tomography image of atlantoaxial subluxation in a dog, with and without complication by atlantooccipital overlapping. Atlantooccipital overlapping was defined in a three-dimensional multiplanar reconstruction of the midsagittal section as the arcus dorsalis of the atlas being located closer to the cranial aspect of the occipital bone than a straight line (the McRae line) joining the opisthion and basion of the occipital bone. A: Complicated by atlantooccipital overlapping, B: Not complicated by atlantooccipital overlapping.

prognosis of CJA remains poorly understood. The purpose of this study was to clarify effects of the concurrent AOO on the clinical outcomes of ventral fixation for dogs with AAI.

Forty-one dogs with AAI that underwent ventral fixation between October 2007 and September 2015 at Veterinary Medical Teaching Hospital, Nippon Veterinary and Life Science University, or at YPC Tokyo Animal Orthopedic Surgery Hospital were included in this study. All dogs underwent preoperative head and neck MRI and CT examinations and were followed-up postoperatively for a minimum of 180 days. Preoperative CT images were surveyed for the presence of AOO, and dogs were divided into AOO and non-AOO groups accordingly. Information recorded included: breed, sex, age (in months), body weight at the time of surgery, time between the onset of clinical signs and surgery ( $\leq 7$  days, 8–30 days, 31–180 days, and  $>180$  days), severity of pre- and postoperative neurological abnormalities, surgical procedure performed, and occurrence of surgical complications (intraoperative,  $<1$  month postoperative, or  $\geq 1$  month postoperative).

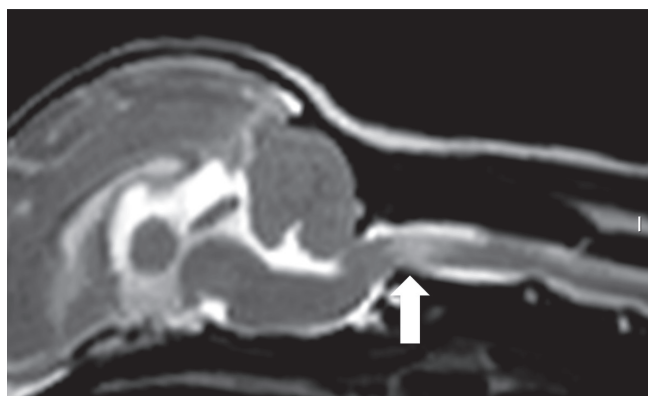
Neurological examinations were performed preoperatively and postoperatively. The severity of neurologic abnormalities was graded according to the scale of Stalin *et al.* [26], where 0=normal, 1=neck pain  $\pm$  mild ataxia, 2=ambulatory with moderate to severe ataxia or paresis, 3=non-ambulatory tetraparesis, 4=tetraplegia, and 5=death or required euthanasia.

All patients were premedicated subcutaneously with atropine sulfate (0.05 mg/kg, Mitsubishi Tanabe Pharma Co., Osaka, Japan). Anesthesia was induced with intravenous midazolam (0.02 mg/kg, Astellas Pharma Inc., Tokyo, Japan) and propofol (4–8 mg/kg, Fresenius Kabi Japan Co., Tokyo, Japan), and maintained with sevoflurane (2.5–3.0%, Mylan Pharma Co., WV, U.S.A.).

CT imaging was performed with the 80-/160-slice CT Aquilion PRIME-TSX-303A (Toshiba Medical Systems Co., Otawara, Japan), with 0.5-sec rotation scans and slice thicknesses and intervals of 0.5 mm each. Patients were kept in a prone position with neutral extension for imaging performed under general anesthesia. Morphological assessment was performed with the Osirix Dicom Viewer image-processing software (open-source version 5.6, 32-bit, <http://www.osirix-viewer.com>). Each dogs' CT image DICOM data were used to create a three-dimensional multiplanar reconstruction (3D-MPR) for AOO evaluation. The conditions for the 3D-MPR CT image evaluation were a window width (WW) of 2500 Hounsfield units (HU) and a window length (WL) of 500 HU, as described by Parry *et al.* [20]. AOO was defined by the arcus dorsalis of the atlas being located closer to the cranial aspect of the occipital bone than a straight line (the McRae line) joining the opisthion and basion of the occipital bone in a 3D-MPR midsagittal section (Fig. 1) [18].

The GE Signa EXCITE 3.0-T system (GE Healthcare Japan Co., Ltd., Tokyo, Japan) is an open MRI system with a vertical magnetic field, and was used to obtain MR images. After CT imaging, MRI was performed with the dog still under general anesthesia and in the same position as for the CT examination. We acquired T2-weighted images under the following conditions: slice thickness=2.0 mm, slice interval=0.4 mm, repetition time=5,000 msec, and echo time=85.1 msec. MR images were morphologically assessed using the Osirix Dicom Viewer. Images were evaluated for the presence of spinal cord compression, central canal enlargement, or high signal intensity in T2-weighted images of the spinal cord parenchyma at the atlantoaxial joint area, and syringomyelia at the cervical spinal area (Fig. 2).

Patients were anesthetized and maintained in a supine position with the neck extended and underwent surgery. The mandible was placed cranially and the forelimbs were pulled caudally. Fentanyl (Janssen Pharmaceutical K.K., Tokyo, Japan) was administered by continuous infusion (2–7  $\mu\text{g}/\text{kg}/\text{hr}$ ) for intraoperative analgesia. Ventral fixation of the atlantoaxial joint was performed using



**Fig. 2.** Sagittal magnetic resonance image of a dog with atlantoaxial subluxation complicated by a high signal level in T2-weighted imaging of the spinal cord substance at the atlantoaxial joint area.

**Table 1.** Signalment of 41 AAI dogs, 12 dogs with AOO (the AOO group) and 29 dogs without AOO (the non-AOO group)

Variable	AOO	non-AOO
Sex (No. of dogs)		
Sexually intact male	5	7
Castrated male	2	5
Sexually intact female	4	11
Spayed female	1	6
Age (month)		
Mean $\pm$ SD	53.9 $\pm$ 47.3	45.2 $\pm$ 40.0
Median (range)	33.0 (5.0–122.0)	35.0 (5.0–125.0)
Weight (kg)		
Mean $\pm$ SD	2.1 $\pm$ 0.8	2.6 $\pm$ 1.4
Median (range)	1.9 (1.3–4.3)	2.1 (1.3–9.0)

the techniques of Schulz *et al.* [23] and Shores [25]. A ventral midline approach of the neck was adopted to facilitate entry into the atlantoaxial joint, and allow exposure of the joint surface so that subluxation of the atlantoaxial joint could be reduced. Transarticular pins (1.00 or 1.25 mm in diameter, Johnson & Johnson K.K., Tokyo, Japan) were inserted to penetrate the pedicle of the vertebral arch of the atlas from the ventrocranial surface on both sides of the axis. Two bone screws (1.5 or 2.0 mm in diameter; Johnson & Johnson K.K.) were then inserted bilaterally into the pedicle of the vertebral arch from the basal–alar region of the atlas, oriented laterally to avoid penetration of the spinal canal. Two additional bone screws (1.5 or 2.0 mm in diameter; Johnson & Johnson K.K.) were inserted into the pedicle of the vertebral arch of the caudal axis, oriented in a caudolateral direction. We used screws of a length that would penetrate halfway through the bone or did not exceed the thickness of the longus colli muscle. After removal of the articular cartilage from the surface of the atlantoaxial joint, autologous cancellous bone, collected from the greater tubercle of the humerus, was transplanted into the space, and polymethylmethacrylate (Japan Stryker K.K., Tokyo, Japan) was used to support fixation. In cases with marked DC at the atlantoaxial joint area, ventral fixation was followed by a change to the prone position to permit dorsal decompression [21]. A dorsal midline approach to the neck was used to expose the arcus dorsalis of the atlas, as well as the spinous process of the axis. The cranial aspect of the spinous process of the axis was removed to expose the ligamentum flavum, which was removed through sharp dissection.

Postoperative assessment was performed in awake patients by using radiographs and a neurological examination at 1, 2, 3, 6, 12, 18 and 24 months, and then yearly thereafter. Radiographs were used to evaluate implant breakage, loosening, or displacement. Recovery was defined as postoperative improvement in neurological status and the ability to walk without pain. Dogs with preoperative neurological grades of 0–2 that could walk without ataxia and pain postoperatively were judged as recovered. Similarly, for dogs with preoperative neurological grades of 3–4 that showed no pain and could walk with mild ataxia or wobbling postoperatively were also judged as recovered.

Surgical complications (intraoperative, <1 month postoperative, or  $\geq$ 1 month postoperative) had been assessed during follow-up. Abnormalities in hemodynamic parameters during surgery were recorded as iatrogenic failures. Recorded postoperative complications included respiratory complications requiring ventilatory support, worsening of neurological status, and breakage, loosening, or displacement of the implants.

Statistical analyses were performed using statistical software (SPSS version 23.0, IBM Corp., Chicago IL, U.S.A.). The Mann-Whitney *U* test or the Student *t*-test were used for comparisons between the AOO and the non-AOO groups. Data are expressed as mean  $\pm$  standard deviation (SD). The significance level was set at  $P < 0.05$ .

Of the 41 dogs, 12 were in the AOO group and 29 were in the non-AOO group. The AOO group comprised seven Yorkshire terriers, three Chihuahuas, one toy poodle, and one mixed-breed dog. The non-AOO group comprised 10 Chihuahuas, nine toy poodles, four Yorkshire terriers, two miniature dachshunds, two Pomeranians, one cavalier King Charles spaniel, and one Japanese Chin. Detailed information regarding the sex, age, and body weight of the 41 dogs included in the study are summarized in Table 1. No significant differences were detected in age ( $P = 0.788$ ) or body weight ( $P = 0.113$ ).

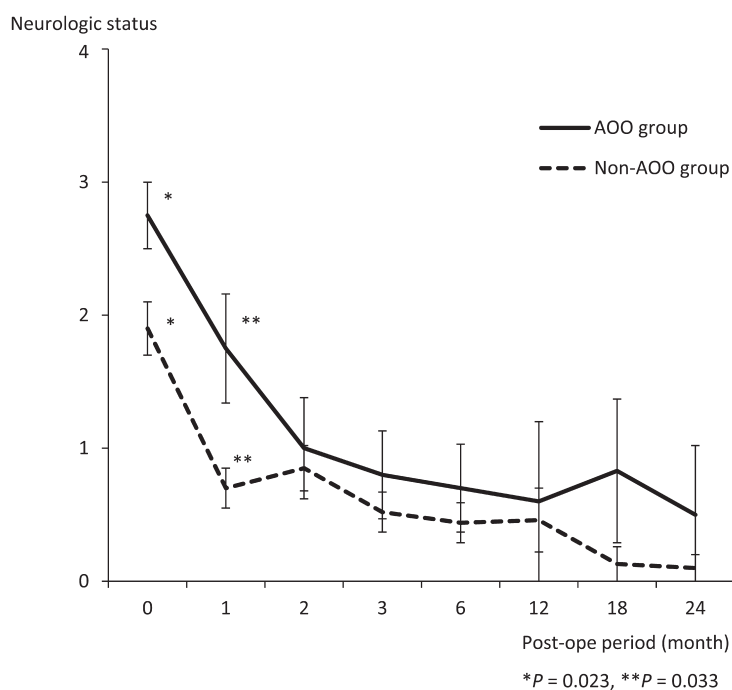
Preoperative neurological status in the AOO group was grade 2 in six patients, grade 3 in three patients, and grade 4 in three patients. In the non-AOO group, preoperative neurological status was grade 0 in three patients, grade 1 in six patients, grade 2 in 14 patients, grade 3 in three patients, and grade 4 in three patients. Of the three patients with a grade 0 status, one had been referred for a radioulnar fracture and two had been referred for medial patella luxation. In these three cases, AAI was suspected based on cervical radiographs, and MRI was used to confirm compression of the spinal cord by the odontoid process. Central canal enlargement or a high signal intensity in T2-weighted MR images of the spinal cord parenchyma at the atlantoaxial joint area were identified in four dogs (grade 2, one dog; grade 3, two dogs; grade 4, one dog) in the AOO group and 10 dogs (grade 2, six dogs; grade 3, two dogs; grade 4, two dogs) in the non-AOO group. Syringomyelia was observed in five of the 12 dogs in the AOO group and in seven of the 29 dogs in the non-AOO group. The incidence of central canal enlargement or high signal level in

**Table 2.** Results of ventral fixation of atlantoaxial joint in the AOO group

Grade (pre-ope)	Number of dogs			
	Total	Recovered	No improvement	Died
0	0	0	0	0
1	0	0	0	0
2	6	6	0	0
3	3	2	1	0
4	3	3	0	0
Total	12	11	1	0

**Table 3.** Results of ventral fixation of atlantoaxial joint in the non-AOO group

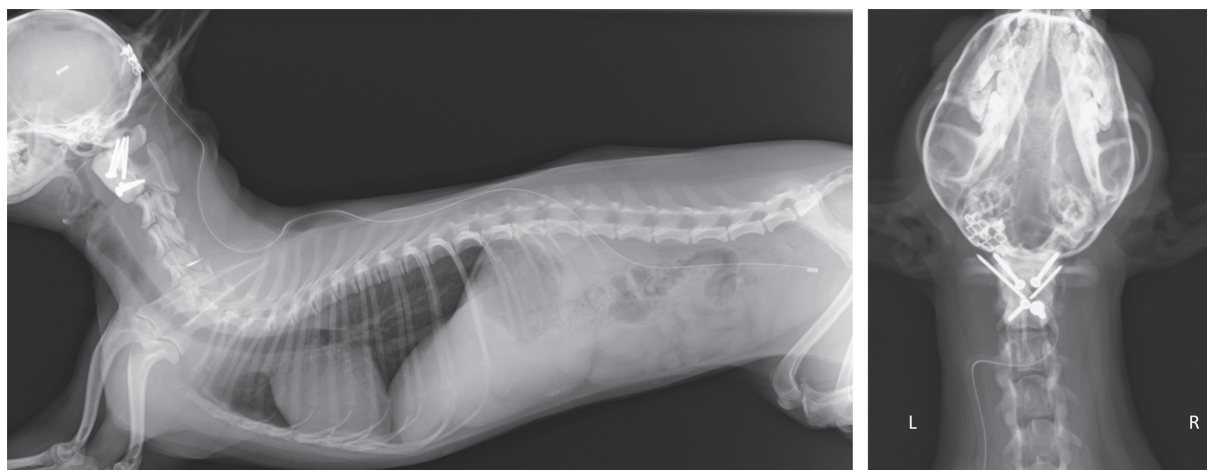Grade (pre-ope)	Number of dogs			
	Total	Recovered	No improvement	Died
0	3	3	0	0
1	6	6	0	0
2	14	12	2	0
3	3	2	0	1
4	3	2	0	1
Total	29	25	2	2



**Fig. 3.** Comparison of the neurological status of dogs in two groups: the atlantooccipital overlapping (AOO) group and the non-AOO group. The AOO group had significantly higher neurological scores before surgery and at 1 month after surgery. However, no significant differences were observed between the groups 2 months after surgery.

T2-weighted MR images of the spinal cord parenchyma at the atlantoaxial joint area ( $P=0.966$ ) and syringomyelia ( $P=0.387$ ) did not differ significantly between the groups. The time from the onset of clinical signs to surgery did not differ significantly between the groups ( $P=0.106$ ); in the AOO group, it was within 7 days for seven patients, 8–30 days for two patients, 31–180 days for two patients, and >180 days for one patient. In the non-AOO group, excluding the three grade-0 dogs, it was within 7 days for eight patients, 8–30 days for three patients, 31–180 days for 11 patients, and >180 days for four patients. The mean postoperative follow-up period was  $790 \pm 559$  days in the AOO group (187 to 2,078 days; median, 742 days) and  $509 \pm 349$  days, excluding two cases of death, in the non-AOO group (183 to 1,378 days; median, 397 days).

All patients underwent ventral fixation of the atlantoaxial joint. Seven dogs in the non-AOO group underwent dorsal decompression for DC after ventral fixation. No significant difference was observed in outcomes between the groups ( $P=0.788$ ); the recovery rate was 91.7% (11/12) in the AOO group and 86.2% (25/29) in the non-AOO group (Tables 2 and 3). The only patient in the AOO group that did not show improvement following surgery exhibited central canal enlargement and high signal intensity in T2-weighted MR images of the spinal cord parenchyma at the atlantoaxial joint area (preoperative and postoperative grade 3). Three of the four patients in the non-AOO group that did not show improvement following surgery exhibited central canal enlargement or high signal level in T2-weighted MR images of the spinal cord parenchyma at the atlantoaxial joint area (two patients, preoperative and postoperative grade 2; one patient, preoperative grade 4 and postoperative grade 5). A comparison of neurological status over time between the groups revealed that the AOO group had significantly higher neurological scores before surgery ( $P=0.024$ ) and 1 month after surgery ( $P=0.033$ ). However, no significant difference was detected between the groups at any time after 1 month (2 months post-operation,  $P=0.893$ ; 3 months post-operation,  $P=0.550$ ; 6 months post-operation,  $P=0.577$ ; 12 months post-operation,  $P=1.000$ ; 18 months post-operation,  $P=0.491$ ; 24 months post-operation,  $P=0.181$ ; Fig. 3).



**Fig. 4.** X-ray image (left: lateral view; right: dorsoventral view) of a dog that underwent a ventriculoperitoneal shunt after ventral stabilization of the atlantoaxial joint.

No dogs experienced intraoperative complications. Two dogs in the non-AOO group (one grade 3 and one grade 4) showed no neurological improvement within 10 days after surgery and died from respiratory failure. Three cases of implant breakage, loosening, or displacement occurred in each of the two groups. Breakage of the implant in the three dogs in the AOO group occurred 18 months or more after surgery. No further surgery was performed because of a lack of clinical signs or radiographic findings suggesting displacement or instability of the atlantoaxial joint. Two of the three dogs with implant breakage, loosening, or displacement in the non-AOO group developed implant-related complications within 3 months after surgery. These dogs underwent further surgery because clinical signs were consistent with recurrent instability of the atlantoaxial joint. The revision surgery involved removal of the existing implants and ventral fixation of the C-1-2-3 vertebral bodies [1]. Two dogs in the non-AOO group received a postoperative ventriculoperitoneal (VP) shunt (Fig. 4) [12].

The widespread use of MRI and CT in veterinary medicine has enabled preoperative diagnosis of various forms of CJA in patients with AAI. The underlying pathophysiology of these abnormalities is unclear and effective treatments have not been established. In most cases of AAI, ventral fixation of the atlantoaxial joint results in a favorable prognosis. However, some cases show no improvement or worsening postoperative neurological status or death, and concurrent CJA pathology is suspected to be involved. Cerda-Gonzalez *et al.* reported that AOO is a form of CJA that affects the clinical signs and prognosis of dogs with abnormalities at the junction of the head and neck [4]. The results of the present study suggest that dogs with AAI and AOO have a significantly worse preoperative neurologic status; however, ventral fixation of the atlantoaxial joint resulted in improved spinal cord function in many cases. This suggests that AAI exerts a considerable effect on the clinical signs of dogs with CJA, and that treatment for AAI should be a priority. The present study revealed that central canal enlargement or high signal levels in T2-weighted MR images of the spinal cord parenchyma at the atlantoaxial joint area affect the postoperative outcome of AAI, as indicated by the lack of post-operative improvement in most of the patients with these findings. AOO can result in the formation of a dural band caused by excessive motion of the atlas relative to the occipital bone [5]. AOO and AOI are related to dysplasia of the atlantooccipital joint [4]. In cases with concurrent AAI, stabilization of the atlantoaxial joint also has the potential to limit excessive mobility of the atlantooccipital joint.

Limitations of the present study include the fact that the maximum extension position was not used during imaging of the head and neck. The position of the head and neck during image acquisition has been recognized as possibly affecting the apparent extent of AOO [4]. However, the head and neck being overly extended during imaging incurs the risk of worsening neurological signs. Therefore, the patients were kept in the prone position with neutral extension for imaging. Consequently, undetected AOO may have been present in our non-AOO group. Seven dogs in the non-AOO group with DC required dorsal decompression and excision of the thickened ligamentum flavum. In the absence of AOO, bending and stretching of the head affect the atlantoaxial joint, and compensatory thickening of the ligamentum flavum occurs. By contrast, in cases with AAI and complicating AOO, bending and stretching of the head may be associated with excessive mobility of the atlantooccipital joint; therefore, the load might be shared by both the atlantooccipital and atlantoaxial joints.

Stabilization from the atlas to the third cervical vertebra in revision surgery for AAI produces strong fixation; however, the load on the caudal cervical vertebrae may increase. Two patients in the non-AOO group received a VP shunt after AAI stabilization, suggesting that complications other than CJA may cause ventricular dilatation.

In conclusion, we studied the outcomes of ventral fixation for the stabilization of AAI in small-breed dogs with and without concurrent AOO and our data suggest that the presence of AOO affects the clinical signs for dogs with AAI but does not directly affect the outcome of the surgical stabilization of AAI. In cases of AAI with other concurrent forms of CJA, the priority is to stabilize the atlantoaxial joint.

ACKNOWLEDGMENT. No third-party funding or support was received in connection with this study or the writing or publication of this manuscript. The authors declare that there are no conflicts of interest.

## REFERENCES

1. Bagley, R. S. 2005. Basics of treatment of important spinal cord diseases of dogs and cats. p 341. *In: Fundamentals of Veterinary Clinical Neurology*, 1st ed. (Bagley, R. S. ed.), Blackwell Publishing, Ames.
2. Beaver, D. P., Ellison, G. W., Lewis, D. D., Goring, R. L., Kubilis, P. S. and Barchard, C. 2000. Risk factors affecting the outcome of surgery for atlantoaxial subluxation in dogs: 46 cases (1978-1998). *J. Am. Vet. Med. Assoc.* **216**: 1104-1109. [[Medline](#)] [[CrossRef](#)]
3. Cerda-Gonzalez, S. and Dewey, C. W. 2010. Congenital diseases of the craniocervical junction in the dog. *Vet. Clin. North Am. Small Anim. Pract.* **40**: 121-141. [[Medline](#)] [[CrossRef](#)]
4. Cerda-Gonzalez, S., Dewey, C. W., Scrivani, P. V. and Kline, K. L. 2009. Imaging features of atlanto-occipital overlapping in dogs. *Vet. Radiol. Ultrasound* **50**: 264-268. [[Medline](#)] [[CrossRef](#)]
5. Cerda-Gonzalez, S., Olby, N. J., McCullough, S., Pease, A. P., Broadstone, R. and Osborne, J. A. 2009. Morphology of the caudal fossa in Cavalier King Charles Spaniels. *Vet. Radiol. Ultrasound* **50**: 37-46. [[Medline](#)] [[CrossRef](#)]
6. Denny, H. R., Gibbs, C. and Waterman, A. 1988. Atlanto-axial subluxation in the dog: a review of thirty cases and an evaluation of treatment by lag screw fixation. *J. Small Anim. Pract.* **29**: 37-47. [[CrossRef](#)]
7. Dewey, C. W., Marino, D. J. and Loughin, C. A. 2013. Craniocervical junction abnormalities in dogs. *N. Z. Vet. J.* **61**: 202-211. [[Medline](#)] [[CrossRef](#)]
8. Downey, R. S. 1967. An unusual cause of tetraplegia in a dog. *Can. Vet. J.* **8**: 216-217. [[Medline](#)]
9. Geary, J. C., Oliver, J. E. and Hoerlein, B. F. 1967. Atlanto axial subluxation in the canine. *J. Small Anim. Pract.* **8**: 577-582. [[Medline](#)] [[CrossRef](#)]
10. Hara, Y., Nezu, Y., Yasuda, H., Tuzuki, Y. and Tagawa, M. 2002. Ventral Vertebral Fusion Technique for the Dog with Atlantoaxial Subluxation. *Nihon Jui Masui Gekagaku Zasshi* **33**: 41-47.
11. Havig, M. E., Cornell, K. K., Hawthorne, J. C., McDonnell, J. J. and Selcer, B. A. 2005. Evaluation of nonsurgical treatment of atlantoaxial subluxation in dogs: 19 cases (1992-2001). *J. Am. Vet. Med. Assoc.* **227**: 257-262. [[Medline](#)] [[CrossRef](#)]
12. Hoerlein, B. F. and Gage, E. D. 1978. Hydrocephalus. pp. 733-760. *In: Canine Neurology*. 3rd ed. (Hoerlein, B. F. ed.), Saunders, Philadelphia.
13. Johnson, S. G. and Hulse, D. A. 1989. Odontoid dysplasia with atlantoaxial instability in a dog. *J. Am. Anim. Hosp. Assoc.* **25**: 400-404.
14. Knipe, M. F., Sturges, B. K., Vernau, K. M., Berry, W. L., Dickinson, P. J., Anor, S. and LeCouteur, R. A. 2002. Atlantoaxial instability in 17 dogs. *J. Vet. Intern. Med.* **16**: 368.
15. Ladds, P., Guffy, M., Blauch, B. and Splitter, G. 1971. Congenital odontoid process separation in two dogs. *J. Small Anim. Pract.* **12**: 463-471. [[Medline](#)] [[CrossRef](#)]
16. Marino, D. J., Loughin, C. A., Dewey, C. W., Marino, L. J., Sackman, J. J., Lesser, M. L. and Akerman, M. B. 2012. Morphometric features of the craniocervical junction region in dogs with suspected Chiari-like malformation determined by combined use of magnetic resonance imaging and computed tomography. *Am. J. Vet. Res.* **73**: 105-111. [[Medline](#)] [[CrossRef](#)]
17. McCarthy, R. J., Lewis, D. D. and Hosgood, G. 1995. Atlantoaxial luxation in dogs. *Compend. Contin. Educ. Pract. Vet.* **17**: 215-226.
18. McRae, D. L. and Barnum, A. S. 1953. Occipitalization of the atlas. *Am. J. Roentgenol. Radium Ther. Nucl. Med.* **70**: 23-46. [[Medline](#)]
19. Nakamura, N., Iwasaki, Y., Hida, K., Abe, H., Fujioka, Y. and Nagashima, K. 2000. Dural band pathology in syringomyelia with Chiari type I malformation. *Neuropathology* **20**: 38-43. [[Medline](#)] [[CrossRef](#)]
20. Parry, A. T., Upjohn, M. M., Schlegl, K., Kneissl, S. and Lamb, C. R. 2010. Computed tomography variations in morphology of the canine atlas in dogs with and without atlantoaxial subluxation. *Vet. Radiol. Ultrasound* **51**: 596-600. [[Medline](#)] [[CrossRef](#)]
21. Piermattei, D. L. 1993. Approach to cervical vertebral 1 and 2 through a dorsal incision. pp. 50-53. *In: An Atlas of Surgical Approaches to the Bones and Joints of the Dog and Cat*, 3rd ed. (Piermattei, D.L. ed.), Philadelphia: Saunders.
22. Sanders, S. G., Bagley, R. S. and Silver, G. M. 2000. Complications associated with ventral screws, pins and polymethylmethacrylate for the treatment of atlantoaxial instability in 8 dogs. *J. Vet. Intern. Med.* **14**: 339.
23. Schulz, K. S., Waldron, D. R. and Fahie, M. 1997. Application of ventral pins and polymethylmethacrylate for the management of atlantoaxial instability: results in nine dogs. *Vet. Surg.* **26**: 317-325. [[Medline](#)] [[CrossRef](#)]
24. Sharp, N. J. H. and Wheeler, S. J. 2005. Atlantoaxial subluxation. pp. 161-180. *In: Small Animal Spinal Disorders*, 2nd ed. (Sharp, N. J. H., Wheeler, S. J. ed.), Elsevier Mosby, Edinburgh.
25. Shores, A. and Tepper, L. C. 2007. A modified ventral approach to the atlantoaxial junction in the dog. *Vet. Surg.* **36**: 765-770. [[Medline](#)] [[CrossRef](#)]
26. Stalin, C., Gutierrez-Quintana, R., Faller, K., Guevar, J., Yeaman, C. and Penderis, J. 2015. A review of canine atlantoaxial joint subluxation. *Vet. Comp. Orthop. Traumatol.* **28**: 1-8. [[Medline](#)] [[CrossRef](#)]
27. Takagi, S., Kadosawa, T., Ohsaki, T., Hoshino, Y., Okumura, M. and Fujinaga, T. 2005. Hindbrain decompression in a dog with scoliosis associated with syringomyelia. *J. Am. Vet. Med. Assoc.* **226**: 1359-1363, 1347. [[Medline](#)] [[CrossRef](#)]
28. Thomas, W. B., Sorjonen, D. C. and Simpson, S. T. 1991. Surgical management of atlantoaxial subluxation in 23 dogs. *Vet. Surg.* **20**: 409-412. [[Medline](#)] [[CrossRef](#)]
29. Vermeersch, K., Van Ham, L., Caemaert, J., Tshamala, M., Taeymans, O., Bhatti, S. and Polis, I. 2004. Suboccipital craniectomy, dorsal laminectomy of C1, durotomy and dural graft placement as a treatment for syringohydromyelia with cerebellar tonsil herniation in Cavalier King Charles spaniels. *Vet. Surg.* **33**: 355-360. [[Medline](#)] [[CrossRef](#)]
30. Watson, A. G. and de Lahunta, A. 1989. Atlantoaxial subluxation and absence of transverse ligament of the atlas in a dog. *J. Am. Vet. Med. Assoc.* **195**: 235-237. [[Medline](#)]
31. Zaki, F. A. 1980. Odontoid process dysplasia in a dog. *J. Small Anim. Pract.* **21**: 227-234. [[Medline](#)] [[CrossRef](#)]