




OPEN ACCESS

Original research

Early gastric cancer detection in high-risk patients: a multicentre randomised controlled trial on the effect of second-generation narrow band imaging

Naohiro Yoshida ¹, Hisashi Doyama,¹ Tomonori Yano,² Takahiro Horimatsu,³ Noriya Uedo,⁴ Yoshinobu Yamamoto,⁵ Naomi Kakushima,⁶ Hiromitsu Kanzaki,⁷ Shinichiro Hori,⁸ Kenshi Yao,⁹ Ichiro Oda,¹⁰ Chikatoshi Katada,¹¹ Chizu Yokoi,¹² Ken Ohata,¹³ Kenichi Yoshimura,¹⁴ Hideki Ishikawa,¹⁵ Manabu Muto³

► Additional material is published online only. To view please visit the journal online (<http://dx.doi.org/10.1136/gutjnl-2019-319631>).

For numbered affiliations see end of article.

Correspondence to

Dr Manabu Muto, Therapeutic Oncology, Graduate School of Medicine, Kyoto University, Sakyo, Kyoto, Japan; mmuto@kuhp.kyoto-u.ac.jp

Received 10 August 2019

Revised 18 March 2020

Accepted 20 March 2020

Published Online First

2 April 2020

ABSTRACT

Objective Early detection of gastric cancer has been the topic of major efforts in high prevalence areas.

Whether advanced imaging methods, such as second-generation narrow band imaging (2G-NBI) can improve early detection, is unknown.

Design This open-label, randomised, controlled tandem trial was conducted in 13 hospitals. Patients at increased risk for gastric cancer were randomly assigned to primary white light imaging (WLI) followed by secondary 2G-NBI (WLI group: n=2258) and primary 2G-NBI followed by secondary WLI (2G-NBI group: n=2265) performed by the same examiner. Suspected early gastric cancer (EGC) lesions in both groups were biopsied. Primary endpoint was the rate of EGC patients in the primary examination. The main secondary endpoint was the positive predictive value (PPV) for EGC in suspicious lesions detected (primary examination).

Results EGCs were found in 44 (1.9%) and 53 (2.3%; p=0.412) patients in the WLI and 2G-NBI groups, respectively, during primary EGD. In a post hoc analysis, the overall rate of lesions detected at the second examination was 25% (n=36/145), with no significant differences between groups. PPV for EGC in suspicious lesions was 13.5% and 20.9% in the WLI (50/371 target lesions) and 2G-NBI groups (59/282 target lesions), respectively (p=0.015).

Conclusion The overall sensitivity of primary endoscopy for the detection of EGC in high-risk patients was only 75% and should be improved. 2G-NBI did not increase EGC detection rate over conventional WLI. The impact of a slightly better PPV of 2G-NBI has to be evaluated further.

Trial registration number UMIN000014503.

INTRODUCTION

Gastric cancer is relatively common worldwide, with over 1 000 000 new cases reported in 2018 and an estimated 783 000 deaths.¹ The prognosis for gastric cancer is generally poor, but detection at an early stage substantially improves the 5-year disease-specific survival rate (99.3% for mucosal cancer and 97.2% for submucosal cancer).² Hence, early detection is an ideal strategy for maximising gastric cancer survival rates. However, valid

Significance of this study

What is already known on this subject?

- Although endoscopy using white light imaging (WLI) is the current standard practice for detecting gastric cancer, WLI has remained difficult to detect early gastric cancer (EGC).
- While narrow band imaging (NBI) is useful to detect superficial squamous cell carcinoma of the head and neck and the oesophagus, it is unknown whether NBI improves EGC detection.

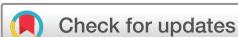What are the new findings?

- While second-generation NBI (2G-NBI) could detect more EGC compared with WLI in patients at high risk for gastric cancer, the difference was not statistically significant.
- The use of 2G-NBI provided higher positive predictive value than WLI.
- The sensitivity for detecting EGC was 77.6% and 72.5% in 2G-NBI and WLI, respectively.

How might it impact on clinical practice in the foreseeable future?

- The comparable detection rates of EGC suggested that 2G-NBI was equivalent to WLI in EGC detection.
- However, perfect detection of EGC remains difficult in current clinical practice, and this issue needs to be solved.

screening procedures for early gastric cancer (EGC) are lacking, even in high-incidence areas (Asia, Russia and South America). While the current standard practice for detecting gastric cancer is endoscopy using white light imaging (WLI),³⁻⁴ the sensitivity of WLI for detecting EGC is not satisfactory.³ Narrow band imaging (NBI) endoscopy is an innovative optical image-enhanced technology that better visualises surface structures and blood vessels than does WLI.⁵ For example, first-generation NBI (1G-NBI) improved the detection rate of superficial head and neck and oesophageal cancers relative to that of WLI.⁶ However, 1G-NBI images are often too dark in the stomach area, making them unsuitable for EGC screening. Second-generation NBI



© Author(s) (or their employer(s)) 2021. Re-use permitted under CC BY-NC. No commercial re-use. See rights and permissions. Published by BMJ.

To cite: Yoshida N, Doyama H, Yano T, *et al.* *Gut* 2021;**70**:67–75.

(2G-NBI) images are significantly brighter, with higher resolution. Thus, we hypothesised that 2G-NBI could be an effective screening method for detecting EGC.

The primary objective of this study was to investigate whether 2G-NBI detects significantly more EGCs than does WLI in patients at high risk for gastric cancer.

METHODS

Study design

This randomised, open-label, two-arm-parallel trial was conducted at 13 hospitals in Japan in accordance with the Declaration of Helsinki. The required sample size was amended 1 year after registration initiation (see below). The manuscript was prepared in accordance with the Consolidated Standards of Reporting Trials statement. All authors had access to the study data and have reviewed and approved the final manuscript.

Participants

We recruited patients at high risk for gastric cancer to maximise the number of lesions detected, allowing for a suitable evaluation of the efficacy of EGC screening. The reported incidence of synchronous or metachronous multiple gastric cancer is 6.7%–14.5% in patients with gastric neoplasm^{7–10} and 5.4%–7.7% in patients with oesophageal cancer.^{11–13} These incidence rates are higher than those of the general population.¹⁴ Therefore, we enrolled patients aged 20–85 years with either of the following: (1) a history of endoscopic resection for an oesophageal cancer or gastric neoplasm, (2) a current oesophageal cancer or gastric neoplasm or (3) a history of chemotherapy and/or radiation therapy for oesophageal cancer. The exclusion criteria were as follows: (1) previous gastrectomy or gastric tube reconstruction, (2) emergency endoscopy, (3) current use of antithrombotic agents, (4) a serious underlying disease and (5) participation in this study within the last 8 months. Written informed consent was obtained from all study participants.

Randomisation and masking

Patients were randomly assigned in a 1:1 ratio to the WLI group (primary WLI followed by secondary 2G-NBI) or the 2G-NBI group (primary 2G-NBI followed by secondary WLI). A centralised randomisation process was conducted using a computerised minimisation procedure on the Medical Research Support Web site (Kyoto, Japan). A minimisation method with a random component was used to balance the groups with respect to institution, age (<70 and ≥70 years) and indication of endoscopy (oesophageal cancer and gastric neoplasm). Masking of the study group allocations was not attempted for either the endoscopists or the patients.

Endoscopy and the NBI system

A 2G-NBI endoscopic system (EVIS LUCERA ELITE; Olympus Corporation, Tokyo, Japan) consisting of a light source (CLV-290SL/CLV-290), video processor (CV-290) and gastrointestinal videoscope (GIF-HQ290) was used for both WLI and 2G-NBI. The video processor settings for structure enhancement were type B, level 4 or 6 for WLI, and type B, level 8 for 2G-NBI. The GIF-HQ290 gastroscope has a dual focus function that allows endoscopists to switch between a normal-focus mode and a near-focus mode (45 times maximum) by pressing a button on the gastroscope.

The NBI system has a dedicated built-in narrow-bandwidth filter in its light source, with central wavelengths of 415 and 540 nm and a bandwidth of 30 nm.⁵ Since haemoglobin absorbs

this narrow-band light, the microvascular architecture of the mucosal surface can be easily visualised. 2G-NBI produces higher quality images than does 1G-NBI owing to the following features: a rotary NBI filter for double exposure; a dedicated xenon lamp to improve brightness; a signal processing system to reduce noise; and improved colour contrast (online supplementary figure S1). Users can switch between WLI and 2G-NBI by simply pushing a button on the gastroscope (online supplementary figure S2).

Endoscopic diagnosis criteria

An EGC is classified as a tumour confined to the mucosa or submucosa, regardless of lymph node metastasis.¹⁵ Newly detected suspicious lesions for EGC, identified by non-magnifying observation, were defined as 'target lesions'. Target lesions had at least one of the following endoscopic characteristics: (1) an area with an irregular margin; (2) an area with irregular discoloration; or (3) an area with an irregular surface (figure 1). Lesions with findings typical of advanced gastric cancer (eg, hardness and poor extensibility) were excluded as target lesions, as were pre-existing lesions. The criteria for a target lesion applied to both the WLI and 2G-NBI examinations.

Examination protocol

The examination protocol consisted of non-magnifying observation (primary WLI and secondary 2G-NBI, or primary 2G-NBI and secondary WLI), near-focus NBI observation and biopsy of the target lesion (online supplementary figure S3). Non-magnifying observation using the allocated procedure was initially performed to detect target lesions. After completing the primary examination of the entire stomach, a secondary examination was immediately performed by the same endoscopist for the detection of any missed target lesions. Both primary and secondary examinations were conducted to observe the whole stomach according to the systematic screening protocol for the stomach.¹⁶ There was no restriction on observation time in both WLI and 2G-NBI. If a target lesion was detected, a detailed near-focus NBI examination was immediately performed to differentiate between gastric cancer and non-cancer. All detected target lesions were ultimately biopsied, regardless of the diagnosis by near-focus NBI.

To maintain endoscopic quality control, all endoscopists in this study were Board-certified fellows of the Japan Gastroenterological Endoscopy Society or had equivalent qualifications. To minimise diagnostic variability, all participating endoscopists were trained using WLI and 2G-NBI endoscopic images of gastric lesions before the study began.

Pathological evaluation

Pathological diagnoses were made on biopsied tissue or resected specimens obtained during endoscopic resection or surgical removal. If biopsied tissues and resected specimens were both available, the latter was used for the final diagnosis. A lesion was diagnosed as a focal gastric cancer if the biopsy-based diagnosis was gastric cancer and the resected specimen-based diagnosis was non-cancer. Differentiation between gastric cancer and non-cancer was based on the revised Vienna classification¹⁷: category 4 (mucosal high-grade neoplasia) and category 5 (submucosal invasion by carcinoma) tumours were diagnosed as gastric cancers, whereas category 1–3 tumours were diagnosed as non-cancers.

Outcomes

The primary endpoint was the detection rate of EGC, which was defined as the proportion of patients with newly detected

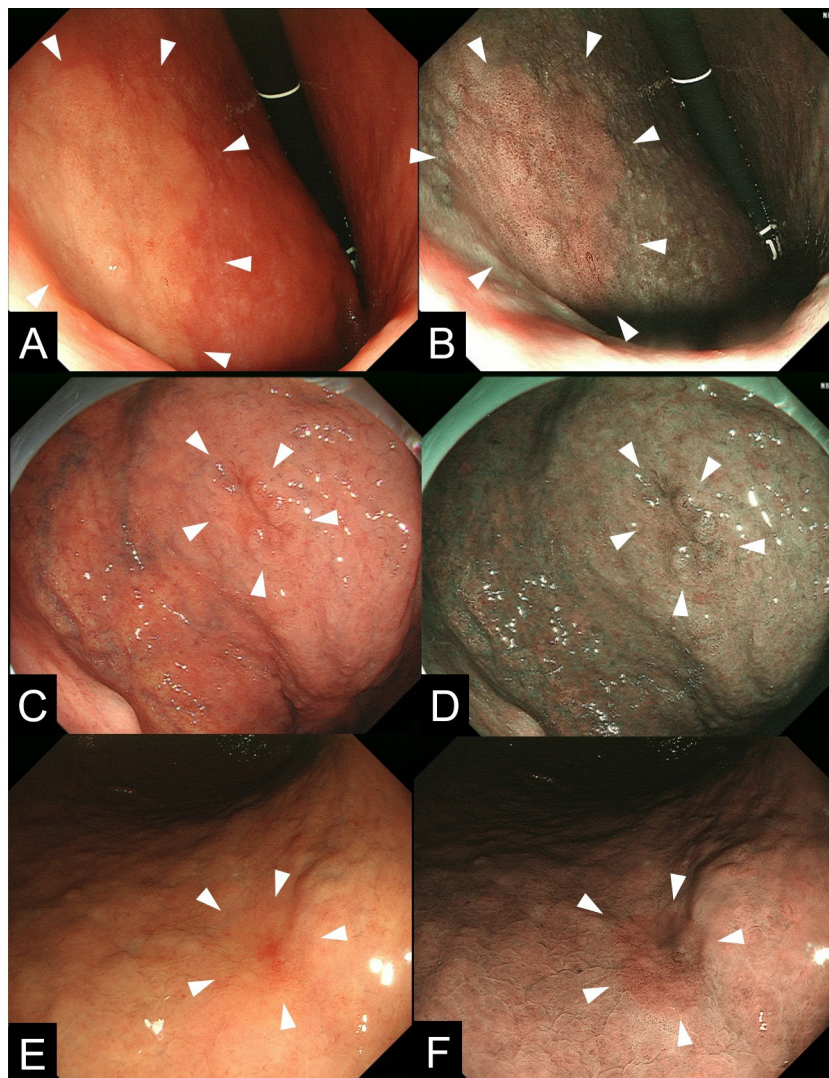


Figure 1 Representative images of target lesions. (A and B) A slightly elevated lesion in the middle third of the stomach is shown (arrowheads). The final histopathological diagnosis was well-differentiated adenocarcinoma, confined to the mucosa. (A) On white light imaging (WLI), the lesion appears as a whitish area with irregular margins and an irregular surface. (B) On second-generation narrow band imaging (2G-NBI), the lesion appears as a brownish area with irregular margins and an irregular surface. (C and D) A depressed lesion in the upper third of the stomach is shown (arrowheads). The final histopathological diagnosis was well-differentiated adenocarcinoma, confined to the mucosa. (C) On WLI, the lesion appears as a reddish area with irregular margins and an irregular surface. (D) On 2G-NBI, the lesion appears as a brownish area with irregular margins and an irregular surface. (E, F) A flat lesion in the upper third of the stomach is shown (arrowheads). The final histopathological diagnosis was moderately differentiated adenocarcinoma, confined to the mucosa. (E) On WLI, the lesion appears as a reddish area with irregular discoloration. (F) On 2G-NBI, the lesion appears as a brownish area with irregular discoloration.

EGC in the primary examination. The secondary endpoints were positive predictive value (PPV), observation time, characteristics of missed EGCs and adverse events. Observation time was measured from the passing of the endoscope through the gastro-oesophageal junction until the completion of the primary examination, including the time required to remove the gastric mucus. A missed EGC was defined as an EGC that was detected in the secondary but not primary examination. Each cancer was classified according to the Japanese Classification of Gastric Carcinoma,¹⁵ including tumour location and macroscopic and histological subtype.

Sample size

Our previous study showed that the detection rate of small depressed gastric cancers by WLI was 3.0%.¹⁸ In the present study, most participants were supposed to be similar to those

in the previous study, and there were no limitations on size or macroscopic types for target EGC lesions. Therefore, we predicted the detection rate of EGC by WLI to increase to 5%. Since no data have been published previously regarding the detection rate of EGC by NBI, we expected that 2G-NBI would increase the detection rate by at least 3% compared with the detection rate by WLI, resulting in a prediction of 8%. As such, the necessary sample size was initially calculated as 2200 patients, with 1100 patients per group, to achieve 80% power with a two-sided alpha of 5%.

In October 2015, 1 year after the beginning of enrolment, the data centre added up the number of EGC from the data that masked the assignment results, according to the predefined study monitoring/review process. This process revealed that the overall detection rate was 2.1% among 1097 patients enrolled at that time. Since the overall detection rate was about one-third

of the initial estimation, the detection rate of each group was reduced by one-third of the initial estimation to 1.5% in the WLI group and 2.7% in the 2G-NBI group (2.1% overall). Although the detection rate became small, we still considered this difference to be valuable because a number of patients would be affected by the results of this study. That is to say, over 1 million new gastric cancer cases were recorded in 2018,¹ and majority of them were estimated to belong to the gastric cancer high-risk group, which corresponded to the analysis target of this study. The revised sample size requirement was 4520 patients, with 2260 patients per group. This sample size was sufficient to achieve the predetermined 80% power with a two-sided alpha of 5%. This adjustment, intended to maintain a balance between clinical significance and study feasibility, was approved by the Institutional Review Boards of all participating institutions.

Statistical analysis

The EGC detection rate and the secondary endpoints (with the exception of observation time) were analysed in the intent-to-treat population, defined as all randomised patients who agreed to participate in this study. Cases excluded after randomisation were counted as not having any target lesion. Differences in proportions between groups were evaluated using Fisher's exact test. Comparisons of continuous data were performed using the t-test. All p values were two sided, with an alpha of 5% as the significance level. Continuous variables are expressed as means and SD. All statistical analyses were performed using JMP V.14.

RESULTS

Group characteristics

Between September 2014 and September 2017, 4,575 patients were assessed for study eligibility (figure 2). Fifty-two patients refused to participate (46 patients before randomisation, six patients after randomisation). The remaining 4523 patients were randomly assigned to the WLI group (2258 patients, primary WLI followed by secondary 2G-NBI) or the 2G-NBI group (2265 patients, primary 2G-NBI followed by secondary WLI). After randomisation, 51 patients were excluded: 21 patients who had inadequate preparation; 15 patients who violated the study protocol; 4 patients who had intragastric haemorrhage; 4

Table 1 Baseline patient characteristics*

| Characteristic | WLI group (n=2258) | 2G-NBI group (n=2265) |
|--|--------------------|-----------------------|
| Age, year [†] | 70.6±7.5 | 70.6±7.5 |
| Male sex, n (%) | 1753 (77.6) | 1774 (78.3) |
| Indication, n (%) | | |
| Current oesophageal cancer | 12 (0.5) | 10 (0.4) |
| History of oesophageal cancer | 373 (16.5) | 378 (16.7) |
| Current gastric neoplasm [‡] | 68 (3.0) | 81 (3.6) |
| History of gastric neoplasm [‡] | 1805 (80.0) | 1796 (79.3) |

*There were no significant differences between the two groups.

[†]Mean±SD.

[‡]Gastric neoplasms included gastric cancers and gastric adenomas.

WLI, white light imaging; 2G-NBI, second-generation narrow band imaging.

patients who had oesophageal stenosis; and 7 patients who had other reasons.

A total of 2234 and 2238 patients underwent examination in the WLI group and 2G-NBI group, respectively. The baseline characteristics of the two groups were well balanced, as summarised in table 1. In both groups, approximately 80% of patients underwent endoscopic examination for surveillance after endoscopic resection for a gastric neoplasm.

Outcomes

Table 2 shows the details of the target lesions found in the primary and secondary examinations. New EGCs were detected in 97 patients (2.1%) during the primary examination. The EGC detection rate by primary WLI and 2G-NBI was 1.9% (44/2258 patients) and 2.3% (53/2265 patients), respectively (p=0.412). Two synchronous EGCs were detected in four patients via primary WLI and six patients via primary 2G-NBI. Three synchronous EGCs were detected in one patient via primary WLI.

Primary WLI detected 371 target lesions, and primary 2G-NBI detected 282 target lesions, 50 and 59 of which were EGCs, respectively. Accordingly, the PPV for diagnosing EGC was significantly greater for 2G-NBI than for WLI (20.9% and

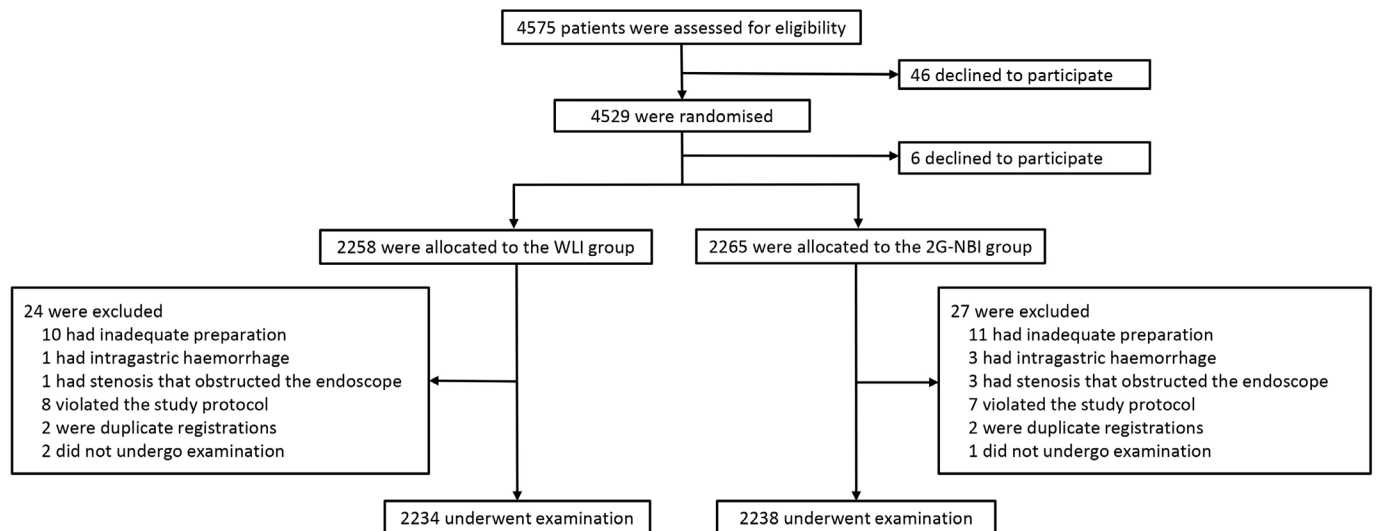


Figure 2 Enrolment and randomisation of patients. The detection rate of early gastric cancer (the primary endpoint) and the positive predictive value for early gastric cancer (a secondary endpoint) were determined in the intent-to-treat population. Observation time (a secondary endpoint) was evaluated among all patients who underwent the examination. 2G-NBI, second-generation narrow band imaging; WLI, white light imaging.

Table 2 Diagnoses of the target lesions and observation times in each group

| Outcome | WLI group (n=2258) | | 2G-NBI group (n=2265) | | P value (primary WLI vs primary 2G-NBI) |
|---|-----------------------|------------------|--------------------------|---------------|---|
| | Primary WLI | Secondary 2G-NBI | Primary 2G-NBI | Secondary WLI | |
| Patients with EGC, n (%) | 44 (1.9) | 19 (0.8) | 53 (2.3) | 17 (0.8) | 0.412 |
| Patients with a target lesion, n (%) | 308 (13.8) | 114 (5.0) | 251 (11.2) | 124 (5.5) | |
| Target lesion, n | 371 | 118 | 282 | 132 | |
| EGC*, n (%) | 50 (13.5) | 19 (16.1) | 59 (20.9) | 17 (12.9) | |
| Others*, n (%) | | | | | |
| Low-grade adenoma | 17 (4.6) | 7 (5.9) | 20 (7.1) | 2 (1.6) | |
| Advanced gastric cancer | 0 (0) | 0 (0) | 1 (0.4) | 0 (0) | |
| Negative for neoplasia | 287 (77.4) | 90 (76.3) | 195 (69.1) | 107 (81.1) | |
| Indefinite for neoplasia | 1 (0.3) | 0 (0) | 1 (0.4) | 1 (0.8) | |
| Not biopsied | 16 (4.3) | 2 (1.7) | 6 (2.1) | 5 (3.8) | |
| Positive predictive value, % | 13.5 | 16.1 | 20.9 | 12.9 | 0.015 |
| Observation time†, seconds | 233±92 | – | 254±104 | – | <0.001 |

*The common denominator of this set of values is the number of target lesions.

†Observation time was measured in the patients who completed the primary examination: 2234 in the WLI group and 2238 in the 2G-NBI group. Values are expressed as means±SD. An en dash represents no data collected.

WLI, white light imaging; 2G-NBI, second-generation narrow band imaging; EGC, early gastric cancer.

13.5%, respectively; $p=0.015$). Some of the remaining lesions were neoplastic; primary WLI detected 17 low-grade adenomas, while primary 2G-NBI detected 20 low-grade adenomas plus one advanced gastric cancer. Other detected lesions were non-neoplastic: primary WLI detected 246 focal gastritis, 27 intestinal metaplasia, 5 gastric ulcers, 5 hyperplastic polyps and 4 fundic gland polyps, while primary 2G-NBI detected 167 focal gastritis, 26 intestinal metaplasia, 1 fundic gland polyp and 1 xanthoma. There was one lesion in each primary examination whose final pathological diagnosis was undetermined despite re-examination. EGC diagnostic performance by non-magnified examination for patients was as follows: sensitivity and specificity were 80.0% and 88.0%, respectively, in WLI, and 76.8% and 91.0%, respectively, in 2G-NBI.

Among all patients who completed the primary examination, the mean observation times for primary WLI and primary 2G-NBI were 233 (range: 34–715) and 254 (range: 37–902) s, respectively ($p<0.001$). Among patients without target lesions, they were 223 (range, 34–613) and 244 (range, 37–902) s, respectively ($p<0.001$).

Across all non-magnifying examinations (primary WLI, primary 2G-NBI, secondary WLI and secondary 2G-NBI) 145 EGCs were detected. The characteristics of these tumours are summarised in table 3. The 109 EGCs detected in the primary examination did not differ significantly between the WLI and 2G-NBI groups with respect to tumour location, macroscopic type or histological classification. Among the EGCs in the WLI group, 65 were endoscopically resected, 1 was surgically resected and 3 were untreated. Among the EGCs in the 2G-NBI group, the corresponding numbers were 65 (including three focal gastric cancers), 2 and 6. There were no significant differences in tumour size or tumour depth, as defined by pathological

findings, between the groups. Primary WLI failed to detect 19 (27.5%) EGCs, and 2G-NBI failed to detect 17 (22.4%). The characteristics of the missed EGCs were similar, with no significant differences between the groups.

The only adverse event observed in this study was bleeding from a target lesion after biopsy in the 2G-NBI group, which required haemostatic therapy.

An additional subanalysis of indication of endoscopy (oesophageal cancer and gastric neoplasm) was also conducted. The oesophageal cancer group, the EGC detection rates of primary WLI and 2G-NBI were 0.8% and 0.5% ($p=0.686$), respectively. In the gastric neoplasm group, the EGC detection rates of primary WLI and 2G-NBI were 2.2% and 2.7% ($p=0.342$), respectively (online supplementary table S1).

DISCUSSION

Endoscopic screening has been reported to reduce gastric cancer mortality in high-risk countries.¹⁹ Furthermore, an earlier detection is crucial, because most patients with EGC can be cured by endoscopic resection,^{20 21} with positive impacts on their quality of life and on the medical economy.^{22 23} However, conventional WLI has limited ability to detect EGC, with a sensitivity of 65.7%, as reported in an Asian screening programme.³ 1G-NBI has proven useful for detecting superficial squamous cell carcinoma of the head and neck and the oesophagus.⁶ However, the brightness of 1G-NBI is insufficient for EGC detection, while it is sufficient for distinguishing between cancerous lesions and non-cancerous lesions by using magnifying endoscopy.^{18 24 25} Owing to development of the NBI system, we were able to compare real-time EGC detection capabilities between WLI and 2G-NBI among patients at high risk for gastric cancer.

Table 3 Characteristics of the detected early gastric cancers

| Characteristic of the detected EGC | WLI group | | | | 2G-NBI group | | | | P value (primary WLI vs primary 2G-NBI) | P value (secondary WLI vs secondary 2G-NBI) |
|--|--------------------------------|--------|-------------------------------------|--------|-----------------------------------|--------|----------------------------------|--------|---|---|
| | Detected by primary WLI (n=50) | | Detected by secondary 2G-NBI (n=19) | | Detected by primary 2G-NBI (n=59) | | Detected by secondary WLI (n=17) | | | |
| Tumour location*, n (%) | | | | | | | | | 1 | 0.913 |
| Upper third | 12 | (24.0) | 5 | (26.3) | 15 | (25.4) | 6 | (35.3) | | |
| Anterior wall | 3 | | 0 | | 5 | | 1 | | | |
| Lesser curvature | 2 | | 0 | | 2 | | 1 | | | |
| Posterior wall | 5 | | 3 | | 5 | | 1 | | | |
| Greater curvature | 2 | | 2 | | 3 | | 3 | | | |
| Middle third | 23 | (46.0) | 8 | (42.1) | 26 | (44.1) | 7 | (41.2) | | |
| Anterior wall | 5 | | 1 | | 6 | | 1 | | | |
| Lesser curvature | 9 | | 2 | | 7 | | 2 | | | |
| Posterior wall | 6 | | 0 | | 7 | | 1 | | | |
| Greater curvature | 3 | | 5 | | 6 | | 3 | | | |
| Lower third | 15 | (30.0) | 6 | (31.6) | 18 | (30.5) | 4 | (23.5) | | |
| Anterior wall | 3 | | 2 | | 0 | | 0 | | | |
| Lesser curvature | 5 | | 2 | | 6 | | 1 | | | |
| Posterior wall | 2 | | 1 | | 5 | | 0 | | | |
| Greater curvature | 5 | | 1 | | 7 | | 3 | | | |
| Tumour macroscopic type*, n (%) | | | | | | | | | 1 | 0.408 |
| 0-I | 2 | (4.0) | 0 | (0) | 2 | (3.4) | 0 | (0) | | |
| 0-IIa | 10 | (20.0) | 5 | (26.3) | 12 | (20.3) | 2 | (11.8) | | |
| 0-IIb | 1 | (2.0) | 0 | (0) | 1 | (1.7) | 0 | (0) | | |
| 0-IIc | 37 | (74.0) | 14 | (73.7) | 44 | (74.6) | 15 | (88.2) | | |
| Tumour histological classification* | | | | | | | | | 0.059 | 0.605 |
| High-grade adenoma | 0 | (0) | 0 | (0) | 5 | (8.5) | 0 | (0) | | |
| Well-differentiated tubular AC | 43 | (86.0) | 16 | (84.2) | 41 | (69.5) | 15 | (88.2) | | |
| Moderately differentiated AC | 5 | (10.0) | 3 | (15.8) | 4 | (6.8) | 1 | (5.9) | | |
| Poorly differentiated AC, solid type | 0 | (0) | 0 | (0) | 1 | (1.7) | 1 | (5.9) | | |
| Poorly differentiated AC, non-solid type | 0 | (0) | 0 | (0) | 1 | (1.7) | 0 | (0) | | |
| Signet-ring cell carcinoma | 2 | (4.0) | 0 | (0) | 3 | (5.1) | 0 | (0) | | |
| Others† | 0 | (0) | 0 | (0) | 4 | (6.8) | 0 | (0) | | |
| Resected EGC, n (%) | 47 | (94.0) | 19 | (100) | 51 | (86.4) | 16 | (94.1) | | |
| Tumour size‡, mm | 11.9±8.9 | | 13.3±8.4 | | 14.5±9.8 | | 12.5±7.5 | | 0.183 | 0.766 |
| Tumour depth§, n (%) | | | | | | | | | 0.777 | 1 |

Continued

Table 3 Continued

| Characteristic of the detected EGC | WLI group | | 2G-NBI group | | | | P value (primary WLI vs primary 2G-NBI) | P value (secondary WLI vs secondary 2G-NBI) |
|------------------------------------|--------------------------------|-------------------------------------|-----------------------------------|----------------------------------|--|--|---|---|
| | Detected by primary WLI (n=50) | Detected by secondary 2G-NBI (n=19) | Detected by primary 2G-NBI (n=59) | Detected by secondary WLI (n=17) | | | | |
| Mucosa | 41 (87.2) | 17 (89.5) | 43 (84.3) | 15 (93.8) | | | | |
| Submucosa | 6 (12.8) | 2 (10.5) | 8 (15.7) | 1 (6.3) | | | | |

*Tumour location, macroscopic type and histological classification were classified according to the Japanese Classification of Gastric Carcinoma.¹⁴

†Others included a squamous cell carcinoma, a carcinoid tumour, an endocrine carcinoma and a carcinoma with lymphoid stroma.

‡Tumour size was analysed in the resected EGCs. Values are expressed as means±SD.

§Tumour depth was analysed in the resected EGCs.

WLI, white light imaging; 2G-NBI, second-generation narrow band imaging; EGC, early gastric cancer; AC, adenocarcinoma.

Although the detection rate of 2G-NBI was slightly higher than that of WLI (2.3% vs 1.9%), we were unable to demonstrate the expected superiority of 2G-NBI. However, this result suggested that 2G-NBI was equivalent to WLI in EGC detection. There are two possible explanations for our inability to show positive results. First, all participating endoscopists had extensive experience and adequate skills for EGC detection using WLI. As a result, they could detect EGC using WLI at a higher rate than initially expected. Second, the period to enrich experience in the use of non-magnified 2G-NBI was probably not enough, even for experts, because the detection rate of EGC by 2G-NBI was lower than initially expected.

2G-NBI had a significantly better PPV than did WLI. PPV is a critical indicator of screening efficiency, and a sufficiently high PPV can reduce unnecessary biopsies and the associated risks of bleeding. Bleeding may especially be of concern to patients undergoing antithrombotic treatment. Although several guidelines regard biopsy as a low-risk procedure for such patients,^{26–28} the number of biopsies should be minimised if antithrombotics have not been withdrawn.²⁶ As an added benefit, fewer biopsies reduce undue medical costs and the burden on pathologists. However, for clinical utility, further improvements would be needed in 2G-NBI despite its high PPV than WLI, and an enrichment in experience through widespread use of non-magnifying 2G-NBI may provide a solution.

The high PPV of 2G-NBI may reflect an improved visualisation of the mucosal characteristics. When we observed a target lesion, we determined whether it had findings suspicious for EGC. In such cases, 2G-NBI enabled detailed observation of the lesion by enhancing the contrast between blood vessels and nonvascular structures. This advantage likely contributed to the superior accuracy of EGC diagnosis by 2G-NBI versus WLI. Regarding magnifying endoscopy, a previous randomised controlled trial demonstrated that the PPV of magnifying endoscopy with NBI was higher than that of WLI (57.1% vs 13.8%).¹⁸ Because magnifying endoscopy requires an advanced observation technique and a special endoscopy system, the threshold is too high for many endoscopists to perform the technique. Accordingly, it is a major benefit that the PPV can be increased, even in the non-magnified setting. In addition to clinical use, the images obtained using 2G-NBI may support the future progress of artificial intelligence in gastric cancer diagnosis, as the development of artificial intelligence typically requires detailed imaging.

The observation time of 2G-NBI was longer than that of WLI. However, despite statistical significance, the difference was only 20s, which may be considered clinically acceptable. Reasons for the prolonged examination time of 2G-NBI might include its better visualisation, which increases the amount of endoscopic information needed to be processed.

Primary WLI and 2G-NBI overlooked 27.5% and 22.4% of EGCs, respectively. There were no differences in tumour characteristics among the missed EGC lesions. These missing rates were higher than the 9.4% that was reported in a systematic review analysing data from 1968 to 2012.²⁹ We considered that this might have been caused by the change in characteristics of EGC. Widespread implementation of *Helicobacter pylori* eradication was reported to make the diagnosis of gastric cancer difficult because of morphological changes that lead to a flat or depressed appearance.³⁰ Advancements in conventional endoscopy preceding this study might also be a factor, because gastric cancers targeted for following endoscopy necessarily become too small and flat to detect. The result of this study shows that even for highly experienced endoscopists, perfect detection of EGC remains difficult in current clinical practice. To reduce the number of missed EGCs and thus improve screening sensitivity, two observations, one by WLI and one by 2G-NBI, may be recommended.

Some guidelines recommend image-enhanced endoscopy for detecting precancerous gastric lesions.^{31–32} Our findings are in agreement with these reports, as 2G-NBI detected a higher percentage of low-grade adenomas, which are precancerous lesions, than did WLI (90.9% and 70.8%, respectively).

In addition to NBI, autofluorescence imaging (AFI) and blue laser imaging (BLI) are also classified as image-enhanced endoscopy³³ and have been discussed for their potential to improve detection of EGC. AFI is a diagnostic technique based on differences in natural tissue fluorescence emissions provided by endogenous molecules. In the detection of gastric neoplasia, AFI alone is generally not regarded as highly beneficial, due to the large percentage of false positives.³⁴ The development concept of BLI was analogous to that of NBI, although BLI uses two monochromatic lasers instead of xenon light. A randomised controlled trial on EGC detection using BLI showed that BLI had higher sensitivity than that of WLI (93% vs 50%, $p < 0.001$).³⁵ A potential explanation for these positive findings for BLI might be related to the difference in used wavelength. Because the primary endpoint and patient background were different from those in our study, a direct comparison between 2G-NBI and BLI could not be made and may be warranted in the future.

Our study has several limitations. First, the actual EGC detection rate of each modality was lower than the initial assumption, whereas this rate was quite higher than that of the general population.¹⁴ This might have been caused by patient factors, such as widespread implementation of *H. pylori* eradication, and that most of the concomitant EGC might have been detected during previous endoscopic resections. These might also cause the high missing rate. The screening for such patients will become the issue to be solved, in the future of the gastric cancer high-risk region. Second, it was open label, as it is impossible to blind the endoscopist to the

endoscopy modality. Therefore, we cannot exclude observer bias. Third, the analysis of the characteristics of missed EGCs was not sufficiently powered owing to the small number of EGCs detected. Finally, it is unclear whether our results can be extended to patients with a low risk for gastric cancer.

Conclusions

Taken together, our analysis indicates that 2G-NBI did not show improved detection of EGC than WLI in patients at high risk for gastric cancer. However, the 2G-NBI showed a better cancer diagnosis potential that needs further investigations. An incomplete sensitivity of current endoscopy in detecting EGC is still an issue that need to be solved.

Author affiliations

¹Department of Gastroenterology, Ishikawa Prefectural Central Hospital, Ishikawa, Japan

²Department of Gastroenterology and Endoscopy, National Cancer Center Hospital East, Chiba, Japan

³Department of Therapeutic Oncology, Graduate School of Medicine, Kyoto University, Kyoto, Japan

⁴Department of Gastrointestinal Oncology, Osaka International Cancer Institute, Osaka, Japan

⁵Department of Gastrointestinal Oncology, Hyogo Cancer Center, Hyogo, Japan

⁶Department of Endoscopy, Shizuoka Cancer Center, Shizuoka, Japan

⁷Department of Gastroenterology and Hepatology, Okayama University Graduate School of Medicine, Dentistry and Pharmaceutical Sciences, Okayama, Japan

⁸Department of Endoscopy, National Hospital Organization Shikoku Cancer Center, Ehime, Japan

⁹Department of Endoscopy, Fukuoka University Chikushi Hospital, Fukuoka, Japan

¹⁰Department of Endoscopy, National Cancer Center Hospital, Tokyo, Japan

¹¹Department of Gastroenterology, Kitasato University School of Medicine, Kanagawa, Japan

¹²Department of Gastroenterology, National Center for Global Health and Medicine, Tokyo, Japan

¹³Department of Gastroenterology, NTT Medical Center Tokyo, Tokyo, Japan

¹⁴Innovative Clinical Research Center, Kanazawa University Hospital, Ishikawa, Japan

¹⁵Department of Molecular-Targeting Cancer Prevention, Kyoto Prefectural University of Medicine, Kyoto, Japan

Acknowledgements We would like to thank all the investigators who cooperated in recruiting patients at 13 participating institutions, and Eri Okuda, who supported data management at the Medical Research Support (Osaka, Japan). We would like to thank Editage (www.editage.jp) for the English language review.

Contributors NY: study concept and design; acquisition of data; analysis and interpretation of data; drafting of the manuscript; critical revision of the manuscript for important intellectual content; final approval of the article; and study supervision. MM: study concept and design; acquisition of data; analysis and interpretation of data; drafting of the manuscript; critical revision of the manuscript for important intellectual content; final approval of the article; study supervision and obtaining of funding. HD and NU: study concept and design; acquisition of data; analysis and interpretation of data; drafting of the manuscript; critical revision of the manuscript for important intellectual content; and final approval of the article. TY, TH, YY, NK, HK, SH, KensY, IO, CK, CY, and KO: study concept and design; acquisition of data; analysis and interpretation of data; and final approval of the article. KeniY and HI: study concept and design; analysis and interpretation of data; statistical analysis; and final approval of the article.

Funding The Olympus Corporation provided partial funding for this study. This study was funded by joint research funds supplied by Kyoto University and the Olympus Corporation. Conflicts of interest exist between Kyoto University, but not the other participating institutions, and the Olympus Corporation.

Disclaimer The funding source had no role in the conduct of the study; the collection, management, analysis or interpretation of the data; or in the preparation, review or approval of the manuscript.

Competing interests MM received grants from Olympus during the study period. TY received personal fees and non-financial support from Olympus, outside this study.

Patient and public involvement Patients and/or the public were not involved in the design, or conduct, or reporting, or dissemination plans of this research.

Patient consent for publication Not required.

Provenance and peer review Not commissioned; externally peer reviewed.

Data availability statement Data are available on reasonable request. The data that support the findings of this study have been deposited in UMIN (<https://www.umin.ac.jp/icdr/index.html>), and the data are available from the corresponding author, MM, on reasonable request.

Open access This is an open access article distributed in accordance with the Creative Commons Attribution Non Commercial (CC BY-NC 4.0) license, which permits others to distribute, remix, adapt, build upon this work non-commercially, and license their derivative works on different terms, provided the original work is properly cited, appropriate credit is given, any changes made indicated, and the use is non-commercial. See: <http://creativecommons.org/licenses/by-nc/4.0/>.

ORCID iD

Naohiro Yoshida <http://orcid.org/0000-0002-7867-8490>

REFERENCES

- Bray F, Ferlay J, Soerjomataram I, *et al*. Global cancer statistics 2018: GLOBOCAN estimates of incidence and mortality worldwide for 36 cancers in 185 countries. *CA Cancer J Clin* 2018;68:394–424.
- Katai H, Ishikawa T, Akazawa K, *et al*. Five-Year survival analysis of surgically resected gastric cancer cases in Japan: a retrospective analysis of more than 100,000 patients from the nationwide registry of the Japanese gastric cancer association (2001–2007). *Gastric Cancer* 2018;21:144–54.
- Choi KS, Jun JK, Park E-C, *et al*. Performance of different gastric cancer screening methods in Korea: a population-based study. *PLoS One* 2012;7:e50041.
- Hamashima C. Benefits and harms of endoscopic screening for gastric cancer. *World J Gastroenterol* 2016;22:6385–92.
- Gono K, Obi T, Yamaguchi M, *et al*. Appearance of enhanced tissue features in narrow-band endoscopic imaging. *J Biomed Opt* 2004;9:568–77.
- Muto M, Minashi K, Yano T, *et al*. Early detection of superficial squamous cell carcinoma in the head and neck region and esophagus by narrow band imaging: a multicenter randomized controlled trial. *J Clin Oncol* 2010;28:1566–72.
- Nakajima T, Oda I, Gotoda T, *et al*. Metachronous gastric cancers after endoscopic resection: how effective is annual endoscopic surveillance? *Gastric Cancer* 2006;9:93–8.
- Kato M, Nishida T, Yamamoto K, *et al*. Scheduled endoscopic surveillance controls secondary cancer after curative endoscopic resection for early gastric cancer: a multicentre retrospective cohort study by Osaka university ESD Study Group. *Gut* 2013;62:1425–32.
- Jang MY, Cho JW, Oh WG, *et al*. Clinicopathological characteristics of synchronous and metachronous gastric neoplasms after endoscopic submucosal dissection. *Korean J Intern Med* 2013;28:687–93.
- Ławnczak M, Gawin A, Jaroszewicz-Heigelmann H, *et al*. Synchronous and metachronous neoplasms in gastric cancer patients: a 23-year study. *World J Gastroenterol* 2014;20:7480.
- Shibuya H, Wakita T, Nakagawa T, *et al*. The relation between an esophageal cancer and associated cancers in adjacent organs. *Cancer* 1995;76:101–5.
- Natsugoe S, Matsumoto M, Okumura H, *et al*. Multiple primary carcinomas with esophageal squamous cell cancer: clinicopathologic outcome. *World J Surg* 2005;29:46–9.
- Masuda M, Kuwano H, Okumura M, *et al*. Thoracic and cardiovascular surgery in Japan during 2012. *Gen Thorac Cardiovasc Surg* 2014;62:734–64.
- Cancer Registry and Statistics. Cancer information service, National cancer center, Japan, 2019. Available: https://ganjoho.jp/reg_stat/statistics/dll/index.html [Accessed 20 Oct 2019].
- Japanese Gastric Cancer Association. Japanese classification of gastric carcinoma: 3rd English edition. *Gastric Cancer* 2011;14:101–12.
- Yao K. The endoscopic diagnosis of early gastric cancer. *Ann Gastroenterol Q Publ Hell Soc Gastroenterol* 2013;26:11–22.
- Dixon MF. Gastrointestinal epithelial neoplasia: Vienna revisited. *Gut* 2002;51:130–1.
- Ezoe Y, Muto M, Uedo N, *et al*. Magnifying narrowband imaging is more accurate than conventional white-light imaging in diagnosis of gastric mucosal cancer. *Gastroenterology* 2011;141:2017–25.
- Zhang X, Li M, Chen S, *et al*. Endoscopic screening in Asian countries is associated with reduced gastric cancer mortality: a meta-analysis and systematic review. *Gastroenterology* 2018;155:347–54.
- Ono H, Yao K, Fujishiro M, *et al*. Guidelines for endoscopic submucosal dissection and endoscopic mucosal resection for early gastric cancer. *Dig Endosc* 2016;28:3–15.
- Hasuike N, Ono H, Boku N, *et al*. A non-randomized confirmatory trial of an expanded indication for endoscopic submucosal dissection for intestinal-type gastric cancer (cT1a): the Japan clinical Oncology Group study (JCOG0607). *Gastric Cancer* 2018;21:114–23.
- Kim Y, Kim YW, Choi IJ, *et al*. Cost comparison between surgical treatments and endoscopic submucosal dissection in patients with early gastric cancer in Korea. *Gut Liver* 2015;9:174–80.
- Libânio D, Braga V, Ferraz S, *et al*. Prospective comparative study of endoscopic submucosal dissection and gastrectomy for early neoplastic lesions including patients' perspectives. *Endoscopy* 2019;51:30–9.

- 24 Yao K, Anagnostopoulos GK, Ragunath K. Magnifying endoscopy for diagnosing and delineating early gastric cancer. *Endoscopy* 2009;41:462–7.
- 25 Nagahama T, Yao K, Maki S, *et al.* Usefulness of magnifying endoscopy with narrow-band imaging for determining the horizontal extent of early gastric cancer when there is an unclear margin by chromoendoscopy (with video). *Gastrointest Endosc* 2011;74:1259–67.
- 26 Kato M, Uedo N, Hokimoto S, *et al.* Guidelines for Gastroenterological Endoscopy in Patients Undergoing Antithrombotic Treatment: 2017 Appendix on Anticoagulants Including Direct Oral Anticoagulants. *Dig Endosc* 2018;30:433–40.
- 27 Veitch AM, Vanbiervliet G, Gershlick AH, *et al.* Endoscopy in patients on antiplatelet or anticoagulant therapy, including direct oral anticoagulants: British Society of gastroenterology (Bsg) and European Society of gastrointestinal endoscopy (ESGE) guidelines. *Gut* 2016;65:374–89.
- 28 , Acosta RD, Abraham NS, *et al.* ASGE Standards of Practice Committee. The management of antithrombotic agents for patients undergoing Gi endoscopy. *Gastrointest Endosc* 2016;83:3–16.
- 29 Pimenta-Melo AR, Monteiro-Soares M, Libânio D, *et al.* Missing rate for gastric cancer during upper gastrointestinal endoscopy. *Eur J Gastroenterol Hepatol* 2016;28:1041–9.
- 30 Kobayashi M, Sato Y, Terai S. Endoscopic surveillance of gastric cancers after *Helicobacter pylori* eradication. *World J Gastroenterol* 2015;21:10553.
- 31 Banks M, Graham D, Jansen M, *et al.* British Society of gastroenterology guidelines on the diagnosis and management of patients at risk of gastric adenocarcinoma. *Gut* 2019;68:1545–75.
- 32 Pimentel-Nunes P, Libânio D, Marcos-Pinto R, *et al.* Management of epithelial precancerous conditions and lesions in the stomach (maps II): European Society of gastrointestinal endoscopy (ESGE), European Helicobacter and microbiota Study Group (EHMSG), European Society of pathology (ESP), and Sociedade Portuguesa de Endoscopia Digestiva (SPED) guideline update 2019. *Endoscopy* 2019;51:365–88.
- 33 Tajiri H, Niwa H. Proposal for a consensus terminology in endoscopy: how should different endoscopic imaging techniques be grouped and defined? *Endoscopy* 2008;40:775–8.
- 34 Kato M, Kaise M, Yonezawa J, *et al.* Autofluorescence endoscopy versus conventional white light endoscopy for the detection of superficial gastric neoplasia: a prospective comparative study. *Endoscopy* 2007;39:937–41.
- 35 Dohi O, Yagi N, Naito Y, *et al.* Blue laser imaging-bright improves the real-time detection rate of early gastric cancer: a randomized controlled study. *Gastrointest Endosc* 2019;89:47–57.