

Fusion

Complications with axial presacral lumbar interbody fusion: A 5-year postmarketing surveillance experience

Mukund I. Gundanna, MD ^a, Larry E. Miller, PhD ^{b,c}, Jon E. Block, PhD ^{c,*}

^a Brazos Spine, Bryan, TX

^b Miller Scientific Consulting, Inc, Biltmore Lake, NC

^c Jon E. Block, Ph.D., Inc, San Francisco, CA

Abstract

Background: Open and minimally invasive lumbar fusion procedures have inherent procedural risks, with posterior and transforaminal approaches resulting in significant soft-tissue injury and the anterior approach endangering organs and major blood vessels. An alternative lumbar fusion technique uses a small paracoccygeal incision and a presacral approach to the L5-S1 intervertebral space, which avoids critical structures and may result in a favorable safety profile versus open and other minimally invasive fusion techniques. The purpose of this study was to evaluate complications associated with axial interbody lumbar fusion procedures using the Axial Lumbar Interbody Fusion (AxiaLIF) System (TranS1, Wilmington, North Carolina) in the postmarketing period.

Methods: Between March 2005 and March 2010, 9,152 patients underwent interbody fusion with the AxiaLIF System through an axial presacral approach. A single-level L5-S1 fusion was performed in 8,034 patients (88%), and a 2-level (L4-S1) fusion was used in 1,118 (12%). A predefined database was designed to record device- or procedure-related complaints via spontaneous reporting. The complications that were recorded included bowel injury, superficial wound and systemic infections, transient intraoperative hypotension, migration, subsidence, presacral hematoma, sacral fracture, vascular injury, nerve injury, and ureter injury.

Results: Complications were reported in 120 of 9,152 patients (1.3%). The most commonly reported complications were bowel injury (n = 59, 0.6%) and transient intraoperative hypotension (n = 20, 0.2%). The overall complication rate was similar between single-level (n = 102, 1.3%) and 2-level (n = 18, 1.6%) fusion procedures, with no significant differences noted for any single complication.

Conclusions: The 5-year postmarketing surveillance experience with the AxiaLIF System suggests that axial interbody lumbar fusion through the presacral approach is associated with a low incidence of complications. The overall complication rates observed in our evaluation compare favorably with those reported in trials of open and minimally invasive lumbar fusion surgery.

© 2011 SAS - The International Society for the Advancement of Spine Surgery. Published by Elsevier Inc. All rights reserved.

Keywords: AxiaLIF; Fusion; Lumbar; Minimally invasive; Presacral

Conservative treatments for low-back pain have marginal efficacy, and definitive operative correction is often necessary when these measures fail, as evidenced by over 100,000 lumbar fusion surgeries performed in the United States annually.¹ Regardless of the surgical approach, open lumbar fusion procedures have inherent procedural risks. Posterior and transforaminal approaches result in significant soft-tissue injury, and the anterior approach endangers organs and major blood vessels. Minimally invasive ap-

proaches have been used for lumbar fusion procedures for over a decade.^{2,3} A growing body of evidence suggests that minimally invasive lumbar fusion and open lumbar fusion result in similar clinical outcomes, with the former yielding advantages such as smaller incisions, less soft-tissue trauma, and quicker return to normal activities.⁴ Nonetheless, standard minimally invasive lumbar fusion techniques still use the same anatomic approach and theoretically place the same structures at risk for iatrogenic injury.

An alternative, minimally invasive lumbar fusion device, the Axial Lumbar Interbody Fusion (AxiaLIF) System (TranS1, Wilmington, North Carolina), uses a small paracoccygeal incision and a presacral approach to the L5-S1 intervertebral space, which is a distinctly different anatomic pathway compared with any other surgical approach. This procedure entirely avoids critical neurovascular and musculo-

This study was supported, in part, by TranS1 (Wilmington, North Carolina). TranS1 provided the authors with access to their complaint-reporting database.

* Corresponding author: Jon E. Block, PhD, 2210 Jackson Street, Suite 401, San Francisco, CA 94115; Tel: 415-775-7947; Fax: 415-928-0765.

E-mail address: jonblock@jonblockphd.com

ligamentous structures and may offer procedural safety advantages versus open and other minimally invasive fusion techniques. The AxiaLIF System received marketing clearance from the US Food and Drug Administration in December 2004 for treatment of single-level fusion,⁵ and the AxiaLIF 2-Level System for 2-level fusion was cleared in April 2008.⁶ During the 5-year postmarketing experience, over 9,000 minimally invasive fusion procedures have been performed with this device. The purpose of this study was to evaluate complications associated with interbody fusion procedures using this system during the postmarketing period.

Methods

Between March 2005 and March 2010, 9,152 patients underwent axial interbody lumbar fusion with the system. A single-level L5-S1 fusion was performed in 8,034 patients (88%) and a 2-level (L4-S1) fusion was used in 1,118 (12%).

The axial interbody lumbar fusion procedure has been described in detail previously (Fig. 1).⁷ In brief, the single-level procedure begins by creation of a 2-cm longitudinal incision at the level of the paracoccygeal notch under fluoroscopy. A blunt cannulated dissector is advanced through the presacral space and docked onto the sacrum in the desired location for screw entry. A stout guide pin is then introduced through the dissector into the sacrum and advanced into the disc space. A series of dilators are advanced over the guide pin, and a working cannula is anchored to the sacrum. A cannulated drill is then passed over the guide pin, and a trans-sacral portal is created in the L5-S1 disc space. Nitinol cutters are used to perform debulking of the nucleus pulposus and to decorticate the superior and inferior endplates, which provides a cancellous osteogenic bed to aid in the promotion of bony fusion. Tissue extractors are used to remove the diseased disc material, preparing the disc for bone grafting. Autologous bone and bone graft extenders and/or bone morphogenetic protein are inserted into the disc space. After bone graft placement, the guide pin may be replaced and advanced into the inferior endplate of L5. A twist drill is used to create a channel through the vertebral body of L5 but without violation of the superior endplate of L5 or the L4-5 disc space. The guide pin is then advanced to the proximal end of the L5 drill hole. The cannula that was docked in the sacrum is removed, and a larger cannula that can accommodate the axial rod is inserted and advanced over the guidewire until flush against the anterior sacral face, where it is secured to the sacrum with a K-wire. A variety of lengths are available in the rod-shaped titanium alloy AxiaLIF System. In addition, by using a different thread pitch in the S1 section of the axial rod as compared with the L5 section, one can achieve distraction of the disc space. There are 3 choices of differential pitches, depending on how much disc space distraction is desired (Fig. 2). The AxiaLIF System is then placed over the guide pin and advanced through the sacrum into L5, to the proximal extent of the drilling. Additional graft material may be inserted by

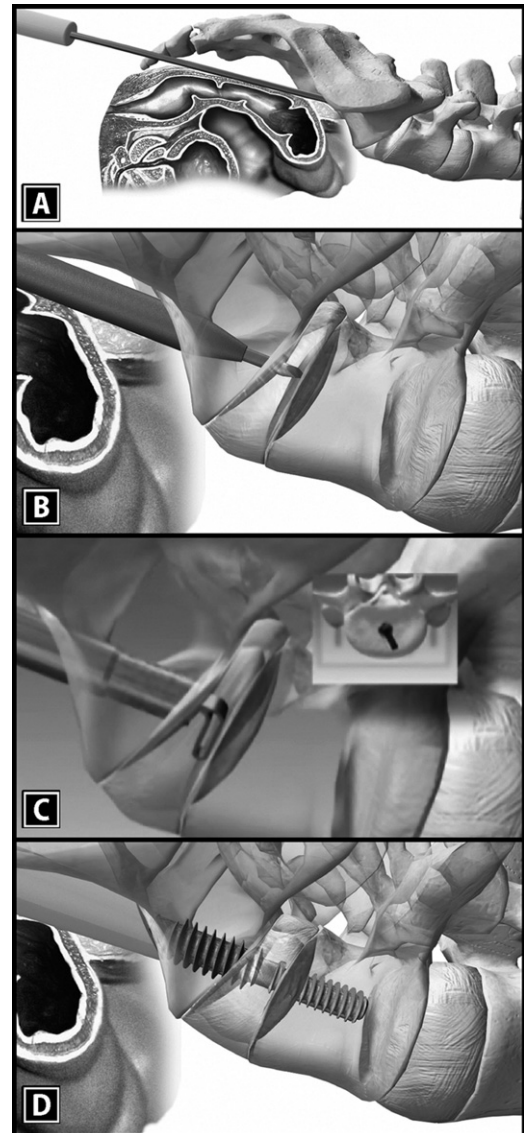


Fig. 1. Axial presacral interbody fusion procedure. Guide pin in presacral space docked on the sacrum (A). Dilator and guide pin advanced into the L5-S1 interspace (B). Nitinol cutters debulking disc material and preparing the endplates for fusion (C). It should be noted that the arc of the cutter can be rotated 360° (inset). Finally, the rod is implanted, distracting the interspace and providing L5-S1 stabilization with placement of bone graft (D).

syringe into the disc space through the central rod portals. In most cases placement of pedicle or facet screws was used to provide supplemental fixation.

The 2-level version of the AxiaLIF System follows similar procedural steps as with the single-level procedure with minor modifications. It requires additional steps after grafting of the L5-S1 disc space to allow for access, decortication, and grafting of the L4-5 disc space. In addition, the 2-level rod is a modular 2-piece rod that can be built according to desired lengths for each segment.

A database was developed to record complaints definitely or possibly related to the device or procedure through a spontaneous reporting mechanism. The complications that

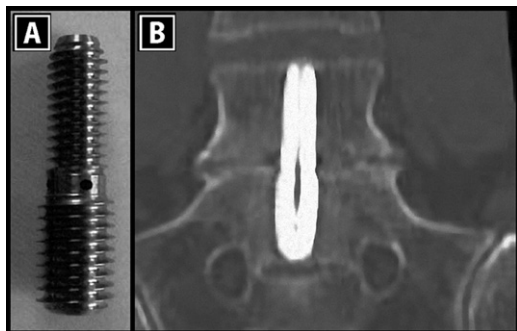


Fig. 2. AxialLIF rod device with differential thread pitch to provide interspace distraction during implantation (A). Radiographic image of rod implanted properly in L5-S1 disc space (B).

were recorded included bowel injury, superficial wound and systemic infections, intraoperative hypotension, migration, subsidence, presacral hematoma, sacral fracture, vascular injury, nerve injury, and ureter injury. Complication data were collected through established complaint reporting as part of ongoing voluntary postmarketing surveillance.

Several procedures were implemented to encourage complication reporting. A representative of TranS1 was present during every case and discussed each completed case with the treating physician. The complaint-reporting system requires every agent (employee and nonemployee) to report any complaint to TranS1 within 24 hours of first notice. In addition, relevant publications were reviewed, and potential complaints were identified. Each complaint was internally investigated by a cross-functional team to determine the root cause and recorded in the database. The version of the database used to develop this article was from June 2010. Therefore the follow-up period ranges from 3 months to 5 years 3 months.

Statistical methods

Complications were reported by use of counts and frequencies with 95% confidence intervals. We used the χ^2 test

with Yates' correction for continuity to compare complication incidences between single-level and 2-level procedures.

Results

Complications were reported in 120 of 9,152 patients (1.3%) (Table 1). The median time from the index operative procedure to the report of the complication was 5 days (mean, 33 days; range, 0–511 days). Overall, 54% of complications occurred within 5 days of surgery, 63% within 10 days, 75% within 31 days, and 90% within 90 days.

The most commonly reported complication was bowel injury (n = 59, 0.6%), of which 29 were high rectal injuries, 14 were low rectal injuries, and 16 were injuries of an unreported location. The median time from surgery to detection of bowel injury was 3 days (mean, 4 days; range, 0–48 days), with 77% of these patients requiring colostomy. Of the 59 reported bowel injuries, surgeon error or deviation was noted in 25 cases (42%).

Transient intraoperative hypotension was reported in 0.2% of patients (n = 20). No adverse sequelae were associated with these hypotensive episodes. All other complications had an incidence of 0.1% or lower, including 4 reports of subsidence at a mean of 62 days (range, 17–90 days) after treatment.

The overall complication rate was similar (P = .43) between single-level (n = 102, 1.3%) and 2-level (n = 18, 1.6%) fusion procedures, with no significant differences noted for any single complication. All complications were successfully treated and resolved with no further sequelae.

Discussion

The 5-year postmarketing surveillance experience with the AxialLIF System suggests that minimally invasive axial interbody lumbar fusion through the presacral approach is associated with a low risk of complications. This technique has an advantage of sparing the posterior musculature, ligaments, and neural elements that are encountered during

Table 1
Complications with lumbar fusion using AxialLIF system

Complication	All patients (N = 9,152)	Single level (n = 8,034)	Two level (n = 1,118)	P value*
No. of complications	123	103	20	
Patients with ≥1 complication	120 (1.3%)	102 (1.3%)	18 (1.6%)	.43
Bowel injury	59 (0.6%)	50 (0.6%)	9 (0.8%)	.61
Hypotension	20 (0.2%)	18 (0.2%)	2 (0.2%)	.96
Presacral hematoma	9 (0.1%)	7 (0.1%)	2 (0.2%)	.68
Sacral fracture	7 (0.1%)	5 (0.1%)	2 (0.2%)	.46
Vascular injury	6 (0.1%)	5 (0.1%)	1 (0.1%)	.77
Systemic infection	6 (0.1%)	6 (0.1%)	0 (—)	.77
Migration	5 (0.1%)	4 (0.1%)	1 (0.1%)	.60
Subsidence	4 (<0.1%)	3 (<0.1%)	1 (0.1%)	.99
Nerve injury	3 (<0.1%)	2 (<0.1%)	1 (0.1%)	.81
Superficial wound infection	3 (<0.1%)	2 (<0.1%)	1 (0.1%)	.81
Ureter injury	1 (<0.1%)	1 (<0.1%)	0 (—)	.25

* Single level versus 2 level.

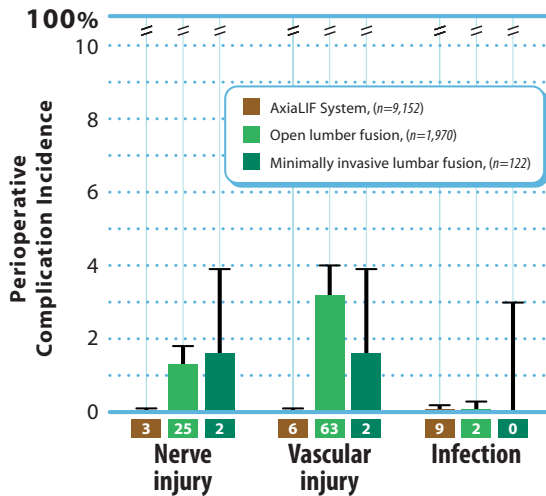


Fig. 3. Complication rates with AxiaLIF System, open lumbar fusion, and minimally invasive lumbar fusion. Complication rates with open lumbar fusion were calculated by pooling outcomes from 6 Food and Drug Administration–regulated trials ($n = 1,970$) using open lumbar fusion for degenerative disc disease as a control.^{8–13} Complication rates with minimally invasive lumbar fusion were calculated by pooling outcomes from 4 selected clinical trials ($n = 122$).^{14–17} Values represent mean \pm 95% confidence interval.

posterior approaches, as well as avoiding dissection and retraction of major vessels and the intra-abdominal viscera as with anterior approaches. The complication incidences observed in this study compare favorably with those reported in 6 Food and Drug Administration–regulated trials using open lumbar fusion for degenerative disc disease as a control.^{8–13} For example, complication incidences from these trials range from 0% to 2.0% for nerve injury, from 1.5% to 8.8% for vascular injury, and from 0% to 1.3% for infection. Several studies of minimally invasive lumbar fusion procedures have reported similarly low complication rates.^{14–17} Overall, the risk of complications with open lumbar fusion, minimally invasive lumbar fusion, and minimally invasive axial interbody lumbar fusion appears to be similar (Fig. 3).

Minimally invasive axial interbody lumbar fusion through a presacral approach mandates that spine surgeons become intimately familiar with presacral anatomy, especially considering that the entire procedure is conducted under fluoroscopy with no direct visualization of the disc space.¹⁸ Of particular importance is avoidance of iatrogenic large bowel injury, which can be accomplished with appropriate preoperative patient preparation and meticulous surgical technique. Preoperative imaging should be carefully reviewed with special attention given to perirectal fat pad thickness, identification of the rectum–sacrum interface, potential aberrant vasculature, and anticipated trajectory. Preoperative patient preparation includes mechanical bowel cleansing to enhance rectal pliability during blunt dissection and to lower contamination risk in the event of bowel injury. Use of broad-spectrum intravenous antibiotics before the procedure further lowers contamination risk. During the

procedure, placement of a Foley catheter in the rectum helps to define the interface of the rectal wall and sacrum under fluoroscopy. A careful initial incision followed by gentle blunt dissection with the finger allows for safe and accurate entry into the presacral area. Postoperatively, endoscopic evaluation of the rectum and sigmoid colon helps to exclude the possibility of bowel injury.

In our study identified factors that may have contributed to bowel injury included the following: lack of preoperative magnetic resonance imaging to the level of the coccyx, reducing the ability to detect sacral adhesions of the bowel; no use of the fixation wire that attaches the tubular retractor to the sacral face, allowing entrapment of tissue between the surgical instruments and the sacral face; use of a hammer to advance instrumentation when resistance is felt; inadequate use of intraoperative fluoroscopy; lack of preoperative bowel preparation; incorrect location and/or size of the incision; no use of finger sweep; and undertaking surgery despite the presence of known contraindications such as bowel disease.

Nonetheless, suspected bowel injury was reported in only 1 of every 155 cases in this study, which suggests that safe device introduction to the L5–S1 disc space can be successfully accomplished with most procedures using the AxiaLIF System. Prompt identification and treatment of bowel injuries are paramount to improve patient outcome. Identification of low rectal injuries mandates hospital admission, intravenous antibiotics, and bowel rest (no food or drink) with serial imaging. High rectal injuries are potentially more serious, and treatment decisions are based primarily on the presence or absence of systemic complications. Patients with no systemic complications may be managed with observation, bowel rest, and intravenous antibiotics, although surgical repair may be indicated in some cases. However, patients with high rectal injury who present with fever and sepsis may also require pelvic drainage and a diverting stoma to achieve symptom resolution.

Intraoperative hypotension was reported in 20 patients. All of these patients were treated at hospitals that used continuous (as opposed to intermittent) intraoperative blood pressure monitoring. Hypotensive episodes were managed with observation or, in some cases, with fluid and epinephrine administration. No patient had complications as a result of intraoperative hypotension, and therefore the clinical significance of these events is minimal.

Appropriate patient selection is crucial to minimize risk of complications. Use of the AxiaLIF System is limited to anterior supplemental fixation of the lumbar spine at L5–S1 (the 2-level variation for L4–S1) in conjunction with legally marketed posterior fixation systems. The AxiaLIF System is not intended to treat severe scoliosis, severe spondylolisthesis, tumor, or trauma. Contraindications for use include coagulopathy, bowel disease, pregnancy, and sacral agenesis. The system should be not used with facet screws when spinal stenosis correction requires removal of significant portions of the lamina or any portion of the facets.

Although fusion rates were not reported in this series, previous studies of axial interbody lumbar fusion suggest that it provides discernible improvements in patient-reported outcomes and high fusion rates.^{19,20} For example, Aryan et al¹⁹ followed 35 patients with degenerative disc disease as the primary diagnosis for 18 months after axial interbody lumbar fusion. At the last follow-up visit, 91% of patients (32 of 35) had radiographic evidence of stable L5-S1 interbody implant placement and fusion. Similarly, Stippler et al²⁰ reported that 92% of patients (33 of 36) undergoing axial interbody lumbar fusion had a significant improvement or complete resolution of low-back pain at final follow-up, with 31 cases (86%) showing a solid fusion radiographically. Another limitation of this study was the spontaneous complication-reporting mechanism, which may underestimate the true incidence of complications.²¹ However, given the comprehensive surveillance program used for this study, the occurrence of serious complications such as bowel perforation requiring surgical correction would most likely come to clinical attention and be reported.

Overall, the 5-year postmarketing surveillance experience with the minimally invasive AxiaLIF presacral fusion system suggests that acceptably low complication rates are observed when the device is used in real-world situations.

Acknowledgments

The authors thank Mr Randy Asher for graphical assistance.

References

1. Deyo RA, Gray DT, Kreuter W, Mirza S, Martin BI. United States trends in lumbar fusion surgery for degenerative conditions. *Spine (Phila Pa 1976)* 2005;30:1441–1445, discussion 1446–47.
2. Mayer HM. A new microsurgical technique for minimally invasive anterior lumbar interbody fusion. *Spine (Phila Pa 1976)* 1997;22:691–699, discussion 700.
3. Regan JJ, Yuan H, McAfee PC. Laparoscopic fusion of the lumbar spine: minimally invasive spine surgery. A prospective multicenter study evaluating open and laparoscopic lumbar fusion. *Spine (Phila Pa 1976)* 1999;24:402–411.
4. Wang J, Zhou Y, Zhang ZF, Li CQ, Zheng WJ, Liu J. Comparison of one-level minimally invasive and open transforaminal lumbar interbody fusion in degenerative and isthmic spondylolisthesis grades I and 2. *Eur Spine J* 2010;19:1780–4.
5. Food and Drug Administration. 510(k) Summary: TranS1 Axial Fixation System. Silver Spring (MD): Food and Drug Administration; 2004.
6. Food and Drug Administration. 510(k) Summary: TranS1 AxiaLIF II System. Silver Spring (MD): Food and Drug Administration; 2008.
7. Marotta N, Cosar M, Pimenta L, Khoo LT. A novel minimally invasive presacral approach and instrumentation technique for anterior L5-S1 intervertebral discectomy and fusion: technical description and case presentations. *Neurosurg Focus* 2006;20:E9.
8. Food and Drug Administration. Summary of safety and effectiveness: BAK Interbody Fusion System with Instrumentation. Silver Spring (MD): Food and Drug Administration; 1996.
9. Food and Drug Administration. Summary of safety and effectiveness: Ray Threaded Fusion Cage (TFC) with Instrumentation. Silver Spring (MD): Food and Drug Administration; 1996.
10. Food and Drug Administration. Summary of safety and effectiveness: INTER FIX Threaded Fusion Device. Silver Spring (MD): Food and Drug Administration; 1999.
11. Food and Drug Administration. Summary of safety and effectiveness: InFUSE Bone Graft/LT-CAGE Lumbar Tapered Fusion Device. Silver Spring (MD): Food and Drug Administration; 2002.
12. Food and Drug Administration. Summary of safety and effectiveness: PRODISC-L Total Disc Replacement. Silver Spring (MD): Food and Drug Administration; 2006.
13. Food and Drug Administration. Summary of safety and effectiveness: CHARITE Artificial Disc. Silver Spring (MD): Food and Drug Administration; 2004.
14. Chung SK, Lee SH, Lim SR, Kim DY, Jang JS, Nam KS, Lee HY. Comparative study of laparoscopic L5-S1 fusion versus open mini-ALIF, with a minimum 2-year follow-up. *Eur Spine J* 2003;12:613–7.
15. Geerdes BP, Geukers CW, van Erp WF. Laparoscopic spinal fusion of L4-L5 and L5-S1. *Surg Endosc* 2001;15:1308–12.
16. Schizas C, Tzinieris N, Tziridis E, Kosmopoulos V. Minimally invasive versus open transforaminal lumbar interbody fusion: evaluating initial experience. *Int Orthop* 2009;33:1683–8.
17. Schwender JD, Holly LT, Rouben DP, Foley KT. Minimally invasive transforaminal lumbar interbody fusion (TLIF): technical feasibility and initial results. *J Spinal Disord Tech* 2005;18(Suppl):S1–6.
18. Nowitzke AM. Assessment of the learning curve for lumbar microendoscopic discectomy. *Neurosurgery* 2005;56:755–62, discussion 755–62.
19. Aryan HE, Newman CB, Gold JJ, Acosta FL Jr, Coover C, Ames CP. Percutaneous axial lumbar interbody fusion (AxiaLIF) of the L5-S1 segment: initial clinical and radiographic experience. *Minim Invasive Neurosurg* 2008;51:225–30.
20. Stippler M, Turka M, Gerszten PC. Outcomes after percutaneous TranS1 AxiaLIF L5-S1 interbody fusion for intractable lower back pain. *Internet J Spine Surg* 2009;5:1–12.
21. McNeil JJ, Grabsch EA, McDonald MM. Postmarketing surveillance: strengths and limitations. The flucloxacillin-dicloxacillin story. *Med J Aust* 1999;170:270–3.