

BRIEF REPORT

Infantile Fibrosarcoma With *NTRK3–ETV6* Fusion Successfully Treated With the Tropomyosin-Related Kinase Inhibitor LOXO-101

Ramamoorthy Nagasubramanian, MD,^{1*} Julie Wei, MD,¹ Paul Gordon, MD,¹ Jeff C. Rastatter, MD,² Michael C. Cox, Pharm.D., MHSc,³ and Alberto Pappo, MD⁴

Infantile fibrosarcoma (IFS) is a rare pediatric cancer typically presenting in the first 2 years of life. Surgical resection is usually curative and chemotherapy is active against gross residual disease. However, when recurrences occur, therapeutic options are limited. We report a case of refractory IFS with constitutive activation of the tropomyosin-related kinase (TRK) signaling pathway from an ETS variant gene 6–neurotrophin 3 receptor gene (*ETV6–NTRK3*) gene fusion. The

patient enrolled in a pediatric Phase 1 trial of LOXO-101, an experimental, highly selective inhibitor of TRK. The patient experienced a rapid, radiographic response, demonstrating the potential for LOXO-101 to provide benefit for IFS harboring NTRK gene fusions. *Pediatr Blood Cancer* 2016;63:1468–1470. © 2016 The Authors. *Pediatric Blood & Cancer*, published by Wiley Periodicals, Inc.

Key words: ETV6–NTRK3; gene fusion; infantile fibrosarcoma; LOXO-101; tropomyosin-related kinase (TRK)

INTRODUCTION

Infantile fibrosarcoma (IFS) is a rare myofibroblastic/fibroblastic tumor, often arising in the extremities, that most commonly affects patients in the first 2 years of life.[1] Despite similarities with adult-type fibrosarcoma, pediatric IFS has a more favorable clinical course and is nearly always characterized by a t(12;15)(p13;q25) translocation.[2–4] This translocation fuses the ETS variant gene 6 (*ETV6*) in chromosome 12 with the neurotrophin 3 receptor gene (*NTRK3*) kinase domain, resulting in activation of multiple signaling cascades including the ras protein (RAS) and phosphatidylinositol 3-kinase–protein kinase B (PI3K–AKT) pathways.[5] Although surgery and chemotherapy can be very effective in treating this disease, a small number of patients develop chemorefractory disease and ultimately die from local or distant complications of their disease.[3,4]

LOXO-101 is an ATP-competitive oral inhibitor of the tropomyosin-related kinase (TRK) family of receptor kinases (TRKA, B, and C), with low nanomolar 50% inhibitory concentrations against all three isoforms, and 1,000-fold or greater selectivity relative to other kinases. Previous work has demonstrated the preclinical activity of LOXO-101 in a cell line model, which harbors an *ETV6–NTRK3* fusion.[6]

In this case study, we report the first pediatric patient with IFS and an *ETV6–NTRK3* fusion treated with a selective TRK inhibitor, LOXO-101.

MATERIALS AND METHODS

A multicenter pediatric phase 1 dose-escalation study in patients with advanced solid or primary central nervous system tumors was initiated in December 2015 (ClinicalTrials.gov Identifier: NCT02637687) to evaluate the safety and tolerability of LOXO-101. Eligibility criteria included the age of 1–21 years regardless of the presence of a known TRK alteration, as well as those patients aged 1 month of age or greater with a known NTRK fusion and a diagnosis of IFS or congenital mesoblastic nephroma. An oral liquid formulation of LOXO-101 was developed for patients unable to swallow capsules. Simcyp® Pediatric Simulation modeling (CERTARA, Princeton, NJ) was utilized

to establish a pharmacokinetic approach for dosing that takes into account patient age, ontogeny of the clearance pathways that eliminate LOXO-101, and body surface area. The pediatric dose selected for the initial cohort was predicted to equal the exposure achieved in adult patients taking a dose of 100 mg twice a day, the recommended Phase 2 adult dose. Cycles are measured in 28-day increments with continuous dosing. Response assessments by appropriate imaging modalities are scheduled every 8 weeks. Patients continue on therapy until evidence of disease progression or intolerable toxicity.

RESULTS

An otherwise healthy female was born with a large, vascular, right-sided neck mass extending to the face that was initially diagnosed and treated as a rapidly involuting congenital hemangioma. At 6 months of age, the mass grew rapidly and surgical

This is an open access article under the terms of the Creative Commons Attribution-NonCommercial-NoDerivs License, which permits use and distribution in any medium, provided the original work is properly cited, the use is non-commercial and no modifications or adaptations are made.

Abbreviations: ETV6, ETS variant gene 6; IFS, infantile fibrosarcoma; MRI, magnetic resonance imaging; NTRK3, neurotrophin 3 receptor gene; TRK, tropomyosin-related kinase

¹Nemours Children's Hospital, Orlando, Florida; ²Department of Otolaryngology – Head and Neck Surgery, Northwestern University Feinberg School of Medicine, Chicago, Illinois; ³Loxo Oncology Inc., South San Francisco, California; ⁴St. Jude Children's Research Hospital, Memphis, Tennessee

Grant sponsor: Loxo Oncology, Inc.

Conflict of interest: Michael C. Cox, Pharm.D., MHSc, is an employee and stock holder of Loxo Oncology, Inc. All other authors have no conflict of interest to declare.

*Correspondence to: Ramamoorthy Nagasubramanian, Nemours Children's Hospital, 13535 Nemours Parkway, Orlando, FL 32827. E-mail: rnagasub@nemours.org

Received 9 March 2016; Accepted 27 March 2016

excision/debulking revealed the diagnosis of IFS confirmed by an ETV6 translocation by FISH. Within the first 7 days postoperatively, the tumor rapidly progressed, encroaching the oral cavity. Chemotherapy with vincristine, actinomycin-D, and cyclophosphamide was initiated but the patient experienced disease progression during cycle 1. A new chemotherapy regimen composed of ifosfamide and doxorubicin (ID) was started concurrently with debulking surgery and a tracheostomy was performed for oropharyngeal obstruction. Two additional courses of ID and four courses of ifosfamide and etoposide had minimal impact on the tumor. The tumor progressed to involve the base of the skull, mastoids, and cervical vasculature. Gross surgical resection was performed in October 2015 by a team of multidisciplinary surgeons but clear surgical margins could not be achieved.

Five weeks following surgical resection, magnetic resonance imaging (MRI) of the brain and neck showed a 20 mm × 19 mm × 18 mm hyperenhancing mass involving the skull base of the middle cranial fossa, just anterior and inferior to the inner ear structures (Figs. 1A and 1B). Further chemotherapy was determined to be futile due to lack of response to all standard regimens. Repeat surgical resection was deemed not possible. Therapeutic radiotherapy was possible, but based on the age of the patient and location of the disease, it was expected to produce devastating long-term sequelae.

In December 2015, at the age of 16 months, the patient enrolled in the Phase 1 pediatric study of the oral, selective TRK inhibitor LOXO-101. The parents noted improved engagement and playfulness throughout Cycle 1. At the end of cycle 1 (day 28), an MRI of the brain and neck showed a significant interval reduction in the size and enhancement of the mass by more than 90% from baseline (Figs. 1C and 1D). Repeat scans at the end of Cycle 2 confirmed the size reduction and showed continued decrease in enhancement, confirming partial response (Figs. 1E and 1F). During the preparation of this manuscript, the patient remained under observation in Cycle 5 of dosing with a confirmed partial response by RECIST.[7] During the first two cycles, the patient experienced fever and PCR-confirmed influenza A (considered not related) but no adverse events related to LOXO-101.

DISCUSSION

We report a pediatric patient with refractory IFS with a confirmed *ETV6–NTRK3* fusion that responded to LOXO-101, a highly selective pan-TRK inhibitor currently in clinical development. Cancers with chromosomal translocation that result in fusion kinases have historically demonstrated oncogene addiction behavior and dramatic responses to relevant drug inhibitors.[8,9] Fusion kinases involving Abelson murine leukemia viral oncogene homolog 1 (*ABL*), anaplastic lymphoma kinase (*ALK*), and ROS proto-oncogene 1 (*ROS1*) have identified populations that benefit from targeted drugs that are approved by U.S. Food and Drug Administration. The development of these inhibitors for other fusions and specifically for pediatric patients has likely lagged behind adult development because of the limited availability of comprehensive genomic profiling of rare pediatric tumors and the generally favorable outcomes of pediatric cancer patients with conventional modalities such as surgery and cytotoxic chemotherapy.

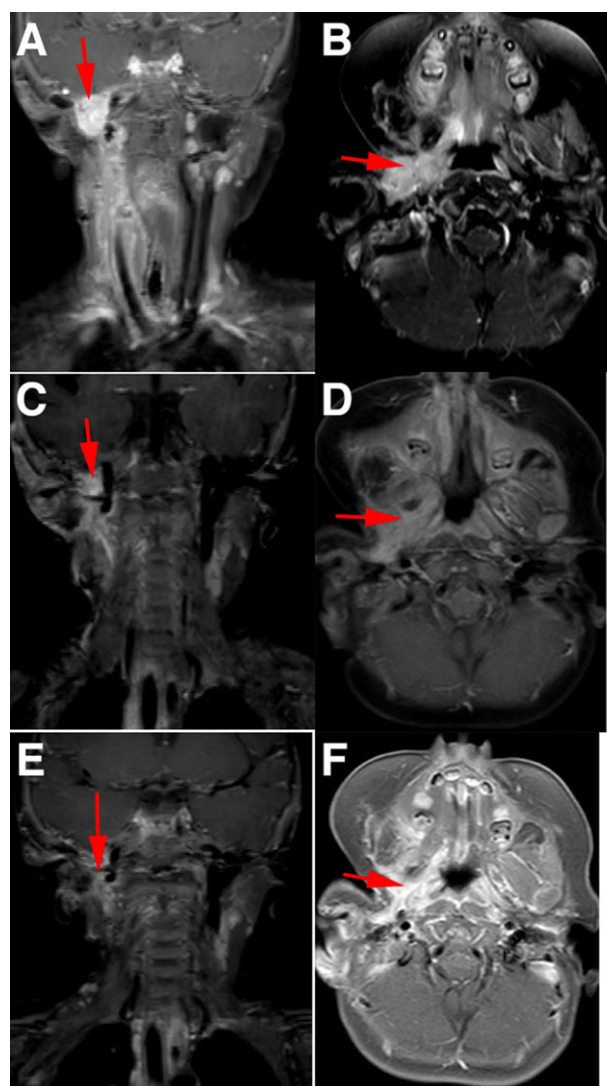


Fig. 1. Magnetic resonance imaging (MRI) of baseline disease assessment of the (A) neck and (B) oral cavity, with areas of interested highlighted with red arrows. Magnetic resonance imaging demonstrating >90% reduction in tumor masses of the (C) neck and (D) oral cavity following completion of the first month of therapy. Confirmation of the tumor response and decreased enhancement demonstrated by MRI of the (E) neck and (F) oral cavity following the second month of therapy.

Since 1998, IFS,[10] cellular subtype congenital mesoblastic nephroma,[11] and secretory breast cancer [12] have all been shown to harbor the *ETV6–NTRK3* fusion. Since the mainstream adoption of next-generation sequencing tools, a growing body of literature has supported the hypothesis that NTRK fusions cause tumorigenesis through the constitutive activation of downstream growth and proliferative pathways.[6,13] NTRK fusions have been recently reported in a variety of pediatric oncologic diseases such as diffuse intrinsic pontine glioma and nonbrainstem high-grade gliomas,[14] pediatric papillary thyroid cancer,[15] spitzoid melanoma,[16] Ph-like acute lymphoblastic leukemia,[17] undifferentiated sarcoma,[18] soft tissue schwannoma,[6] and spindle cell sarcomas.[19]

While the majority of patients with IFS have an *ETV6-NTRK3* fusion and are responsive to surgery and/or chemotherapy, a small number of patients are unusually difficult to treat.[4] Wong and colleagues have recently described a case of an *ETV6-NTRK3* fusion negative and chemotherapy-refractive IFS found to harbor a lamin a/c-neurotrophic tyrosine kinase receptor type 1 (*LMNA-NTRK1*) gene fusion.[20] These two cases serve as helpful reminders that genomic profiling can aid in the morphologic diagnosis of selected pediatric sarcomas, and that actionable, therapeutically useful information may emerge from a molecular diagnosis. As Hong and colleagues have previously shown, a TRK-targeted therapy such as LOXO-101 seems to have efficacy without regard to histologic diagnosis or fusion construct partners.[21]

The radiologic tumor regression and clinical response seen in this patient with an *ETV6-NTRK3* fusion positive IFS provide further clinical validation not only of this molecular target in oncology but also for NTRK fusions as drivers of clinical disease. This case report supports the clinical development of selective TRK inhibitors such as LOXO-101 in pediatric patients with an NTRK fusion. This case report underscores the potential promise of targeted therapies in pediatric populations when compelling oncogenic drivers can be identified and potent investigational inhibitors are available. Their role in the neoadjuvant, adjuvant, and metastatic settings as well as safety in inhibiting TRK in infants deserves further clinical investigation.

ACKNOWLEDGMENTS

The authors would like to acknowledge Dawn Seward, ARNP; Kristen Gibbs, RN, BSN; and Heather Franceschini from Nemours Children's Hospital; and Jennifer Low, MD, PhD; Steve Smith; Mark Reynolds; and Lia Donahue from Loxo Oncology, Inc. for their help. This study is supported and funded by Loxo Oncology, Inc., Stamford, CT.

REFERENCES

1. Chung EB, Enzinger FM. Infantile fibrosarcoma. *Cancer* 1976;38:729–739.
2. Loh ML, Ahn P, Perez-Atayde AR, Gebhardt MC, Shamberger RC, Grier HE. Treatment of infantile fibrosarcoma with chemotherapy and surgery: Results from the Dana-Farber Cancer Institute and Children's Hospital, Boston. *J Pediatr Hematol Oncol* 2002;24:722–726.

3. Orbach D, Brennan B, De Paoli A, Gallego S, Mudry P, Francotte N, van Noesel M, Kelsey A, Alaggio R, Ranchere D, De Salvo GL, Casanova M, Bergeron C, Merks JH, Jenney M, Stevens MC, Bisogno G, Ferrari A. Conservative strategy in infantile fibrosarcoma is possible: The European paediatric Soft tissue sarcoma Study Group experience. *Eur J Cancer* 2016;57:1–9.
4. Orbach D, Rey A, Cecchetto G, Oberlin O, Casanova M, Thebaud E, Scopinaro M, Bisogno G, Carli M, Ferrari A. Infantile fibrosarcoma: Management based on the European experience. *J Clin Oncol* 2010;28:318–323.
5. Lannon CL, Sorensen PH. *ETV6-NTRK3*: A chimeric protein tyrosine kinase with transformation activity in multiple cell lineages. *Semin Cancer Biol* 2005;15:215–223.
6. Doebele RC, Davis LE, Vaishnavi A, Le AT, Estrada-Bernal A, Keysar S, Jimeno A, Varella-Garcia M, Aisner DL, Li Y, Stephens PJ, Morosini D, Tuch BB, Fernandes M, Nanda N, Low JA. An oncogenic NTRK fusion in a patient with soft-tissue sarcoma with response to the tropomyosin-related kinase inhibitor LOXO-101. *Cancer Discov* 2015;5:1049–1057.
7. Eisenhauer EA, Therasse P, Bogaerts J, Schwartz LH, Sargent D, Ford R, Dancy J, Arbuck S, Gwyther S, Mooney M, Rubinstein L, Shankar L, Dodd L, Kaplan R, Lacombe D, Verweij J. New response evaluation criteria in solid tumours: Revised RECIST guideline (version 1.1). *Eur J Cancer* 2009;45:228–247.
8. Weinstein IB. Cancer. Addiction to oncogenes—The Achilles heel of cancer. *Science* 2002;297:63–64.
9. Shaw AT, Hsu PP, Awad MM, Engelman JA. Tyrosine kinase gene rearrangements in epithelial malignancies. *Nat Rev Cancer* 2013;13:772–787.
10. Knezevic SR, McFadden DE, Tao W, Lim JF, Sorensen PH. A novel *ETV6-NTRK3* gene fusion in congenital fibrosarcoma. *Nat Genet* 1998;18:184–187.
11. Knezevic SR, Garnett MJ, Pysker TJ, Beckwith JB, Grundy PE, Sorensen PH. *ETV6-NTRK3* gene fusions and trisomy 11 establish a histogenetic link between mesoblastic nephroma and congenital fibrosarcoma. *Cancer Res* 1998;58:5046–5048.
12. Makretsov N, He M, Hayes M, Chia S, Horsman DE, Sorensen PHB, Huntsman DG. A fluorescence in situ hybridization study of *ETV6-NTRK3* fusion gene in secretory breast carcinoma. *Genes Chromosomes Cancer* 2004;40:152–157.
13. Rubin JB, Segal RA. Growth, survival and migration: The Trk to cancer. *Cancer Treat Res* 2003;115:1–18.
14. Wu G, Diaz AK, Paugh BS, Rankin SL, Ju B, Li Y, Zhu X, Qu C, Chen X, Zhang J, Easton J, Edmonson M, Ma X, Lu C, Nagahawatte P, Hedlund E, Rusch M, Pounds S, Lin T, Onar-Thomas A, et al. The genomic landscape of diffuse intrinsic pontine glioma and pediatric non-brainstem high-grade glioma. *Nat Genet* 2014;46:444–450.
15. Prasad ML, Vyas M, Horne MJ, Virk RK, Morotti R, Liu Z, Tallini G, Nikiforova MN, Christison-Lagay ER, Udelsman R, Dinauer CA, Nikiforov YE. NTRK fusion oncogenes in pediatric papillary thyroid carcinoma in northeast United States. *Cancer* 2016;122:1097–1107.
16. Wu G, Barnhill RL, Lee S, Li Y, Shao Y, Easton J, Dalton J, Zhang J, Pappo A, Bahrami A. The landscape of fusion transcripts in spitzoid melanoma and biologically indeterminate spitzoid tumors by RNA sequencing. *Mod Pathol* 2016;29:359–369.
17. Roberts KG, Li Y, Payne-Turner D, Harvey RC, Yang YL, Pei D, McCastlain K, Ding L, Lu C, Song G, Ma J, Beckwith J, Rusch M, Chen SC, Easton J, Cheng J, Boggs K, Santiago-Morales N, Iacobucci I, Fulton RS, et al. Targetable kinase-activating lesions in Ph-like acute lymphoblastic leukemia. *N Engl J Med* 2014;371:1005–1015.
18. Harris MH, DuBois SG, Glade Bender JL, Kim A, Crompton BD, Parker E, Dumont IP, Hong AL, Guo D, Church A, Stegmaier K, Roberts CW, Shusterman S, London WB, MacConaill LE, Lindeman NI, Diller L, Rodriguez-Galindo C, Janeway KA. Multicenter feasibility study of tumor molecular profiling to inform therapeutic decisions in advanced pediatric solid tumors: The Individualized Cancer Therapy (iCat) Study. *JAMA Oncol* 2016. doi: 10.1001/jamaoncol.2015.5689.
19. Haller F, Knopf J, Ackermann A, Bieg M, Kleinheinz K, Schlesner M, Moskalev EA, Will R, Satir AA, Abdelmagid IE, Giedl J, Carbon R, Rompel O, Hartmann A, Wiemann S, Metzler M, Agaimy A. Paediatric and adult soft tissue sarcomas with NTRK1 gene fusions: A subset of spindle cell sarcomas unified by a prominent myopericytic/haemangiopericytic pattern. *J Pathol* 2016;238:700–710.
20. Wong V, Pavlick D, Brennan T, Yelensky R, Crawford J, Ross JS, Miller VA, Malicki D, Stephens PJ, Ali SM, Ahn H. Evaluation of a congenital infantile fibrosarcoma by comprehensive genomic profiling reveals an *LMNA-NTRK1* gene fusion responsive to Crizotinib. *J Natl Cancer Inst* 2016;108:djv307. doi: 10.1093/jnci/djv307
21. Hong DS, Brose MS, Doebele RC, Shaw AT, Dowlati A, Bauer TM, Farago AF, Estrada-Bernal A, Lee AT, Cox MC, Nanda N, Low JA, Burris HA. Abstract PR13: Clinical safety and activity from a phase 1 study of LOXO-101, a selective TRKA/B/C inhibitor, in solid-tumor patients with NTRK gene fusions. *Mol Cancer Ther* 2015;14(12 Suppl 2):PR13.