

Case Report

Nephrotic syndrome associated with immune thrombocytopenia revealing Kimura's disease in a non-Asian male

Nicolas Noel¹, Véronique Meignin², Sophie Rosenstingl³, Pierre Ronco¹ and Jean-Jacques Boffa¹

¹Department of Nephrology, AP-HP, Hôpital Tenon, F-75020, ²Department of Pathology, AP-HP, Hôpital Saint-Louis, Paris and ³Department of Internal Medicine, Hôpital de Coulommiers, Coulommiers, France

Correspondence and offprint requests to: Jean-Jacques Boffa; E-mail: jean-jacques.boffa@tnn.aphp.fr

Abstract

We report the case of a young Caucasian man presenting with diffuse oedema and nephrotic syndrome. Clinical examination revealed multiple lymphadenopathies. Histological examination was consistent with the diagnosis of Kimura's disease. A renal biopsy showed focal segmental glomerulosclerosis. Immune thrombocytopenia and signs of humoral autoimmunity were discovered. Corticosteroid treatment induced remission of nephrotic syndrome but relapses occurred 12 and 18 months after onset of treatment while the patient was receiving 20 mg prednisone once a day. To our knowledge, this is the first case of Kimura's disease and nephrotic syndrome associated with B-cell autoreactivity.

Keywords: immune thrombocytopenia; Kimura's disease; nephrotic syndrome

Background

Kimura's disease is a rare benign haematological disorder, involving subcutaneous tissue, predominantly in the head and neck region and frequently associated with painless lymphadenopathies. The disease is endemic in Asia, but rare and sporadic in the rest of the world. It can be associated with eosinophilia and increased total serum immunoglobulin E (IgE) concentration [1]. Renal manifestations include membranous glomerulopathy [2], mesangioproliferative glomerulonephritis [3], minimal change disease [4] and focal segmental glomerulosclerosis [5]. The aetiology is unknown, but several reports suggest a T-cell disorder or an immunoallergic reaction. So far, there is no clue to a B-cell disorder.

We report the case of a young Caucasian man presenting with the nephrotic syndrome, Kimura's disease, hyper IgE and immune thrombocytopenia with signs of humoral autoimmunity.

Case report

A 29-year-old Caucasian man was referred for nephrotic syndrome. In the last 2 months, he had received treatment with amoxicilline clavulanate and prednisone (1 mg/kg/day during 5 days) for common acquired pneumonia. The blood pressure was 120/60 mmHg. Clinical examination revealed anasarca and cervical and inguinal lymphadenopathies.

The urinary protein excretion was 12 g/day, with selective albuminuria. There was no haematuria. The plasma albumin level was 6 g/L, and renal function was normal. Leukocyte count was normal, including eosinophils and haemoglobin level (153 g/L). The platelet count was 55 G/L. HIV and HCV tests were negative, and HBV serology showed a vaccinal profile. CMV, parvovirus B19, HTLV1 serologies were negative, and EBV tests showed past infection, without replication. Antinuclear antibodies were positive (1/500). Anti-DNA, anti-ECT, anti-glomerular basement membrane and anti-neutrophil cytoplasmic antibodies were negative. Complement components were normal [C3 1.17 g/L (N, 0.8–1.4 g/L), C4 0.24 g/L (N, 0.16–0.38 g/L)]. Bone-marrow aspirate showed a slight hypereosinophilia (3%) and the presence of megakaryocytic lineage, which confirmed peripheral immune thrombocytopenia (ITP). Total plasmatic IgE concentration was dramatically increased (3900 UI/mL, N <20).

CT-scan showed centimetric lombo-aortic and inguinal lymphadenopathies and hepatosplenomegaly. A 18-fluorodeoxy-glucose positron emission tomography (FDG-PET) was negative.

The biopsy of the submandibular mass revealed a 30 mm diameter lymphadenopathy. Histologic analysis and immunohistochemistry (CD3, CD5, CD10, CD15, CD30, CD20, EMA, EBV-LMP, BCL2) excluded tumoral proliferation. We found a preserved nodal architecture with hyperplastic follicles (figure not shown), many eosinophilic infiltrates and vascular hyperplasia consistent with Kimura disease (Figure 1). Immunophenotyping of blood lymphocytes was normal. No clonal T-cell rearrangement was found, neither in the peripheral blood lymphocytes nor in the lymph node.

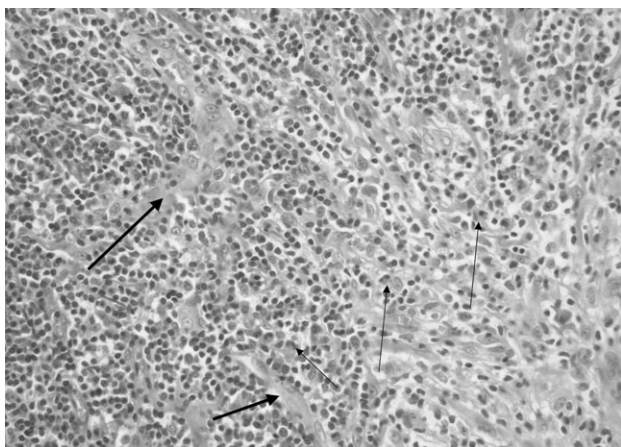


Fig. 1. Lymph node: paracortical zone showing interfollicular infiltrates with many eosinophils (thin arrow) mixed with small lymphocytes. There was also vascular hyperplasia (large arrow) ($\times 400$).

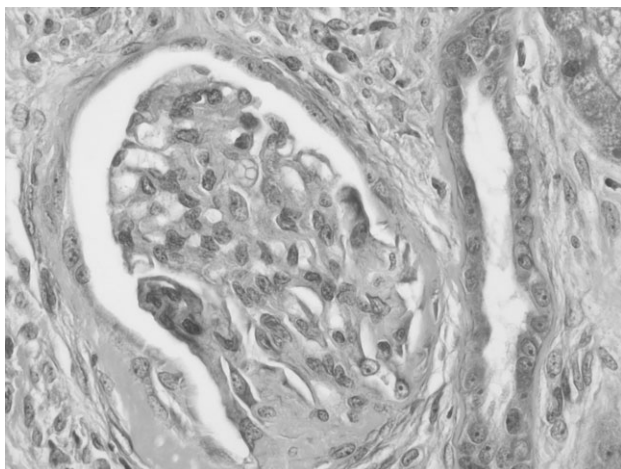


Fig. 2. Renal biopsy showing focal segmental glomerulosclerosis (hilar type).

The renal biopsy specimen contained 18 glomeruli, and revealed segmental glomerular sclerosis in two of them (Figure 2). There was no mesangial proliferation, nor evidence of capillary basement membrane thickening or membranous spikes. Tubules and interstitium were normal. Immunofluorescence was negative.

A diagnosis of Kimura's disease associated with focal segmental glomerulosclerosis (FSGS) and immune thrombocytopenia was retained.

The patient was treated with oral corticosteroids (prednisone, 1 mg/kg/day), associated with an ACE inhibitor (ramipril). After 1 month of treatment, while the nephrotic syndrome was in remission, antinuclear antibodies increased (1/1600), and anti-DNA antibodies appeared (IgG: 175 UI/L; N <10 UI/L). Complement component C4 decreased to 0.10 g/L, whereas C3 remained in the normal range (0.85 g/L). There were no SLE-like manifestations except ITP. Autoantibodies and complement concentration normalized lastingly in a few months.

Steroid dose was progressively tapered. The nephrotic syndrome relapsed twice, 12 and 18 months after the on-

set of steroid therapy when he was still receiving 20 mg prednisone per day. Mycophenolate mofetil 1 g twice per day was added after the first relapse. Nephrotic syndrome remission was acquired 4 weeks later. The second relapse was concomitant of an upper respiratory viral infection. So far, the patient has no sign of malignant lymphoproliferative disorder, and no systemic autoimmune disease.

Discussion

Kimura's disease is a rare haematological disorder of unknown origin, occurring in young men of Asian origin. Pathological features include preserved lymph node architecture, proliferative germinal centres, eosinophilic infiltration and postcapillary venule proliferation [1], which all were present in our case. Eosinophilia and elevated levels of total IgE are common. Although peripheral eosinophilia was absent, most likely because of recent steroid treatment, our patient still had a slight medullar eosinophilia (3%).

Kimura's disease should not be confused with angiolymphoid hyperplasia with eosinophilia (ALHE) [1]. This currently presents as a head or neck soft tissue swelling, with eosinophilic infiltrates and vascular proliferation. It occurs predominantly in Caucasian women and is rarely associated with increased IgE levels. No renal involvement has been described with ALHE. Other differential diagnosis include angioimmunoblastic T-cell lymphoma, Castleman's disease, parasitic lymphadenitis and drug-related hypersensitivity lymphadenopathy. These disorders were excluded on medical history, biological and histological findings.

Kidney involvement in Kimura's disease is not uncommon. A total of 12–16% of the patients present with proteinuria, and 59–78% of them have the nephrotic syndrome [2,6]. The skin or lymph node lesions may precede the renal manifestations, or occur simultaneously or months later, but they are usually close in time, suggesting a pathogenic link between Kimura's disease and the renal manifestations.

Aetiology of Kimura's disease is still unknown. An immunohistochemical study performed on 21 mass lesions [1] failed to disclose any infectious agent and clonal proliferation. No clonal rearrangement of T-cell receptor and Ig heavy chain genes was found [7]. Eosinophilia and high IgE levels point to a Th2 cell disturbance with hypersensitivity-type reaction. Nakahara *et al.* [8] found high IL-5 levels and IL-5/IFN- γ ratio, while Katagiri *et al.* [9] showed increased IL-4, IL-5 and IL-13 mRNA expression in mononuclear cells, suggesting a role of Th2 cytokines in the pathogenesis of Kimura's disease. In minimal change disease (MCD) also, there seems to be a Th2 polarization [10] that suggests that in Kimura's disease-related MCD and FSGS, the Th2 imbalance may play an important role. However, this Th2 dominance is controversial [11].

In our patient, immune thrombocytopenia and elevated antinuclear antibodies suggested B-cell autoreactivity. The association of Kimura's disease with autoimmune manifestations seems unusual. Although Kimura's disease is not primarily a B-cell disorder, it is conceivable that the Th2 imbalance may be associated with the production of autoantibodies in some patients. Thus, efficacy of rituximab in some case of recurrent FSGS [12] may point to a role

of B-cell disturbance in the pathogenesis of the nephrotic syndrome.

Treatment of Kimura's disease consists in surgical resection of the lymph node, but recurrence may occur over time. Additional medical therapies, such as radiation or corticosteroids, have been used with good clinical response, but relapses are common when steroids are withdrawn [8].

In summary, we present here the first case of Kimura's disease with FSGS, immune thrombocytopenia and signs of B-cell autoreactivity in a non-Asian adult man. Further investigation of such cases may help to understand the pathogenesis of nephrotic syndrome.

Acknowledgements. The authors thank Prochore Kamgang (Department of Nephrology, Hôpital Tenon, France) and Patrice Callard (Department of Pathology, Hôpital Tenon, France) for helpful contribution and discussion about kidney biopsy.

Conflict of interest statement. None declared.

References

1. Chen H, Thompson LD, Aguilera NS *et al.* Kimura disease: a clinicopathologic study of 21 cases. *Am J Surg Pathol* 2004; 28: 505–513
2. Yamada A, Mitsuhashi K, Miyakawa Y *et al.* Membranous glomerulonephritis associated with eosinophilic lymphfolliculosis of the skin (Kimura's disease): report of a case and review of the literature. *Clin Nephrol* 1982; 18: 211–215
3. Whelan TV, Maher JF, Kragel P *et al.* Nephrotic syndrome associated with Kimura's disease. *Am J Kidney Dis* 1988; 11: 353–356
4. Sud K, Saha T, Das A *et al.* Kimura's disease and minimal-change nephrotic syndrome. *Nephrol Dial Transplant* 1996; 11: 1349–1351
5. Romao JE, Saldanha LB, Ianez LE *et al.* Recurrence of focal segmental glomerulosclerosis associated with Kimura's disease after kidney transplantation. *Am J Kidney Dis* 1998; 31: E3
6. Matsuda O, Makiguchi K, Ishibashi K *et al.* Long-term effects of steroid treatment on nephrotic syndrome associated with Kimura's disease and a review of the literature. *Clin Nephrol* 1992; 37: 119–123
7. Abuel-Haija M, Hurford MT. Kimura disease. *Arch Pathol Lab Med* 2007; 131: 650–651
8. Nakahara C, Wada T, Kusakari J *et al.* Steroid-sensitive nephrotic syndrome associated with Kimura disease. *Pediatr Nephrol (Berlin, Germany)* 2000; 14: 482–485
9. Katagiri K, Itami S, Hatano Y *et al.* *In vivo* expression of IL-4, IL-5, IL-13 and IFN-gamma mRNAs in peripheral blood mononuclear cells and effect of cyclosporin A in a patient with Kimura's disease. *Br J Dermatol* 1997; 137: 972–977
10. Sahali D, Pawlak A, Valanciute A *et al.* A novel approach to investigation of the pathogenesis of active minimal-change nephrotic syndrome using subtracted cDNA library screening. *J Am Soc Nephrol* 2002; 13: 1238–1247
11. Araya CE, Wasserfall CH, Brusko TM *et al.* A case of unfulfilled expectations. Cytokines in idiopathic minimal lesion nephrotic syndrome. *Pediatr Nephrol (Berlin, Germany)* 2006; 21: 603–610
12. Pescovitz MD, Book BK, Sidner RA. Resolution of recurrent focal segmental glomerulosclerosis proteinuria after rituximab treatment. *N Engl J Med* 2006; 354: 1961–1963

Received for publication: 19.5.09; Accepted in revised form: 8.7.09