

Access this article online

Quick Response Code:



Website:

www.e-tjo.org

DOI:

10.4103/tjo.tjo\_27\_22

# Fibrous dysplasia: A rare cause of optic neuropathy

Sepideh Lotfi Sadigh<sup>1\*</sup>, Serdar Özer<sup>2</sup>, Elif G. Bulut<sup>3</sup>, Güliz F. Yavaş<sup>1</sup>

## Abstract:

Fibrous dysplasia (FD) is a progressive and benign osteodystrophic disease where cranial bones are most commonly affected. In this case report, we present a 27-year-old patient with previous diagnosis of FD who was referred to our clinic with sudden loss of visual acuity and color discrimination. Examination of the right eye was normal, whereas visual acuity on the left eye was 6/9 and color vision (CV) with Ishihara test plates was 9/12. The visual field (VF) demonstrated a peripheral concentric defect on the left eye. As visual acuity in the left eye decreased to 6/30 and computed tomography imaging of the brain and orbit showed optic nerve compression by immature bony structures, optic nerve decompression was recommended with the diagnosis of compressive optic neuropathy. Endoscopic transnasal orbital and optic canal decompression was performed. At the postoperative course, visual acuity on the left eye turned to 6/6, CV was 12/12, and VF improved markedly. In subjects with craniofacial FD, a multidisciplinary approach is important. If there is evidence of compressive optic neuropathy, surgery should be performed.

## Keywords:

Craniofacial fibrous dysplasia, decompression, optic nerve, vision

## Introduction

Fibrous dysplasia (FD) is a rare, benign, and slow progressive osteodystrophic disease characterized by the replacement of normal bone by immature and abnormal fibro-osseous tissue.<sup>[1,2]</sup> The incidence and prevalence of FD are reported as 5%–7% of all benign bone tumors. The abnormality of bones develops during skeletal formation. Clinical manifestation may occur at any age, without gender preference. Common sites of skeletal involvement are long bones, ribs, craniofacial bones, and pelvis.<sup>[3,4]</sup>

In craniofacial FD, common sites of lesions manifest without respect to suture lines and can be either monostotic or polyostotic.<sup>[3]</sup> Ocular manifestations are uncommon but can involve any orbital bone resulting in localized sequelae, including epiphora, proptosis, motor and/or sensory cranial nerve dysfunction,

and even optic atrophy with vision or visual field (VF) loss. Medical follow-up and surgical intervention are the options according to the severity of the disease.<sup>[5]</sup>

This case report assesses the necessity of early surgical intervention in a symptomatic patient and evaluates the management in such cases.

## Case Report

A 27-year-old man was presented with sudden visual loss and a difference in the perception of the red color for 1 month. He also experienced intermittent, retro-orbital headaches. One month ago, he was examined by a neurologist, and according to computed tomography (CT) image sections, optic canal narrowing was apparent and optic nerve was compressed. The patient was referred to our clinic for further evaluation and possible treatment. He had a history of left-sided frontal bulging and left proptosis since about age 13, which was evaluated

This is an open access journal, and articles are distributed under the terms of the Creative Commons Attribution-NonCommercial-ShareAlike 4.0 License, which allows others to remix, tweak, and build upon the work non-commercially, as long as appropriate credit is given and the new creations are licensed under the identical terms.

For reprints contact: WKHLRPMedknow\_reprints@wolterskluwer.com

**How to cite this article:** Sadigh SL, Özer S, Bulut EG, Yavaş GF. Fibrous dysplasia: A rare cause of optic neuropathy. Taiwan J Ophthalmol 2022;12:364-9.

<sup>1</sup>Department of Ophthalmology, Hacettepe University Faculty of Medicine, Ankara, Turkey, <sup>2</sup>Department of Otorhinolaryngology, Hacettepe University Faculty of Medicine, Ankara, Turkey, <sup>3</sup>Department of Radiology, Hacettepe University Faculty of Medicine, Ankara, Turkey

### \*Address for correspondence:

Dr. Sepideh Lotfi Sadigh, Hacettepe University Hospital, Department of Ophthalmology, Faculty of Medicine, 06230 Altındağ, Ankara, Turkey. E-mail: sepideh.lotfisa@gmail.com

Submission: 28-02-2022  
Accepted: 26-04-2022  
Published: 01-08-2022

by different medical centers. The patient was followed by neurology and neurosurgery services with the diagnosis of FD and was under observation by control imaging [Figure 1].

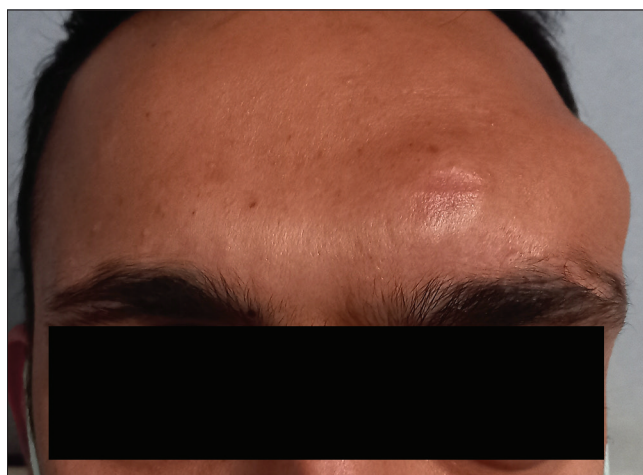Written consent form was taken from the patient according to publish this case report.

### Clinical findings

The best-corrected visual acuity (BCVA) measured by the Snellen chart was 6/6 in the right eye and 6/10 in the left eye. Light reflex (LR) was normal in both eyes, although relative afferent pupillary defect (RAPD) was present in the left eye. Pupils appeared to be within physiologic limits in light and dark. He identified correctly 12/12 Ishihara color test plates using the right eye and 9/12 using the left eye. There was no evidence of ptosis, although the left eye was proptotic and dystopic inferotemporally. In the Hertel exophthalmometer, at a base of 115 mm, measurements were 19 mm in the right eye and 24 mm in the left eye. VF examination by Humphrey VF testing (30-2) resulted in peripheral constriction in the left eye [Figure 2a].

The measurement of intraocular pressure by the Goldmann applanation tonometer was 13 mmHg in the right eye and 15 mmHg in the left eye. Slit-lamp examination of the anterior segment was unremarkable in both eyes. Dilated fundus examination was normal except 0.5 cup-to-disc ratio in the right eye and 0.6 cup-to-disc ratio in the left eye. The evaluation of the macula and retinal nerve fiber layer (RNFL) by optical coherence tomography (OCT) was normal in both eyes [Figure 3a].

Preoperative CT scan images of the brain and orbits demonstrated extensive, ground-glass, minimal heterogeneous changes in bones that were consistent



**Figure 1:** Left-sided frontal bulging. Craniofacial fibrous dysplasia could involve numerous bones of the face and skull

with FD involving the sphenoid bone on the left side [Figure 4a]. The lesion involved left posterior ethmoid and ethmoid sinuses. The left orbit was involved circumferentially except the inferior wall of the orbit. Furthermore, a large component of FD was located posteriorly along the medial aspect of the left orbit and compressed the left optic nerve inferiorly and medially. As progressive visual loss up to 6/30 in the left eye was seen at follow-up, emergent optic nerve decompression was recommended with the diagnosis of compressive optic neuropathy. Informed consent was taken for left-sided optic nerve decompression surgery. Endoscopic orbital and optic canal decompression was performed by ENT surgeons, and due to the pathological affirmation of FD, a specimen was obtained and the diagnosis of FD was confirmed pathologically. Please check abbreviations in Table-1.

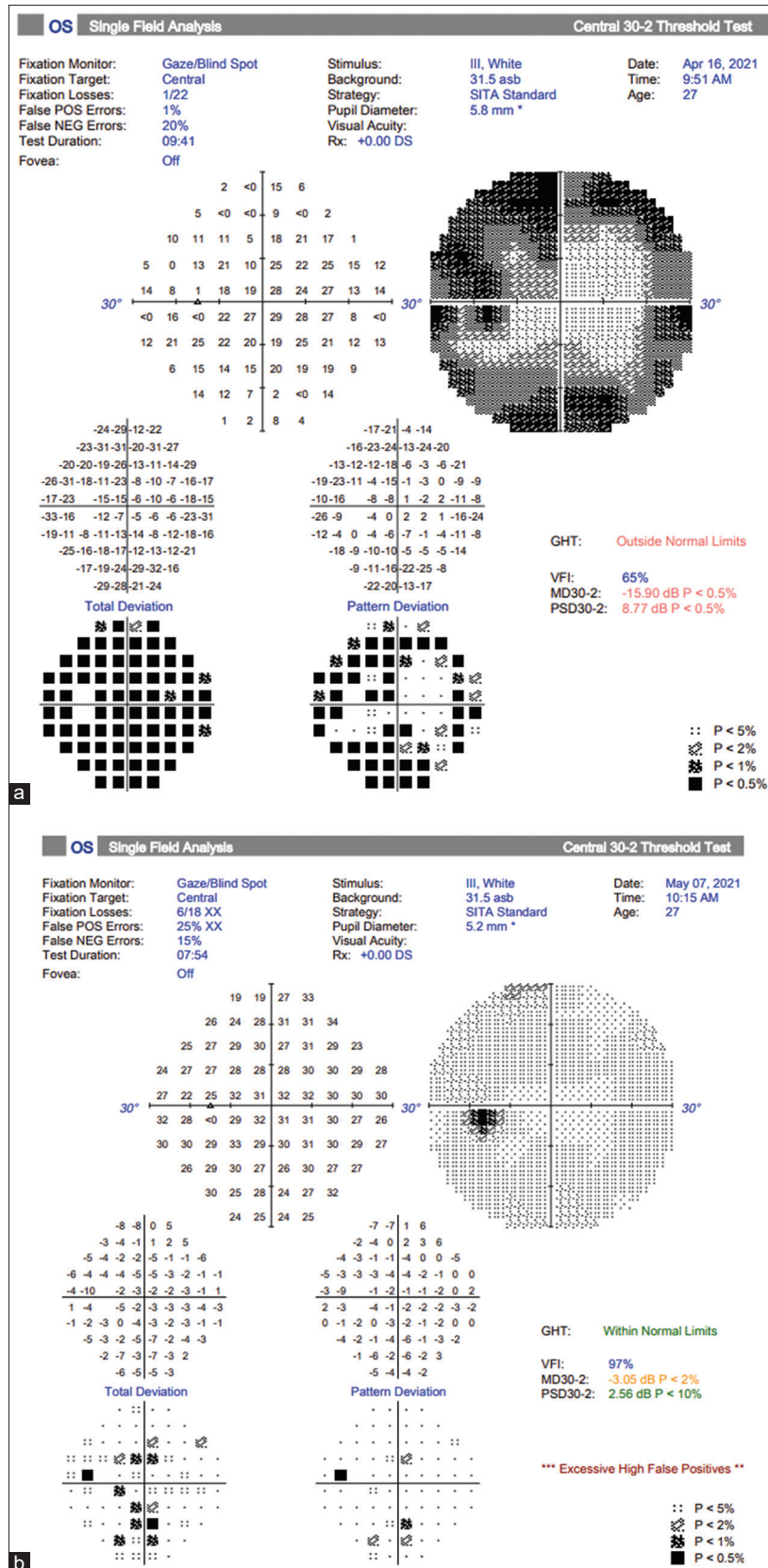
### Postoperative course

Postoperative ophthalmologic evaluation resulted in significant improvement in clinical findings [Table 2]. BCVA was 6/6 in the right eye and 6/7 in the left eye on the postoperative 2<sup>nd</sup> day. LR was normal and RAPD was not seen. Color vision (CV) was found 12/12 in both eyes. VF testing revealed significant improvement [Figure 2b]. Anterior segment and dilated fundus examinations were unremarkable. Postoperative RNFL finding of the left eye was normal [Figure 3b]. Postsurgical CT scan imaging was also performed [Figure 4b]. Optic nerve decompression was shown by arrowhead in [Figure 4 b-c].

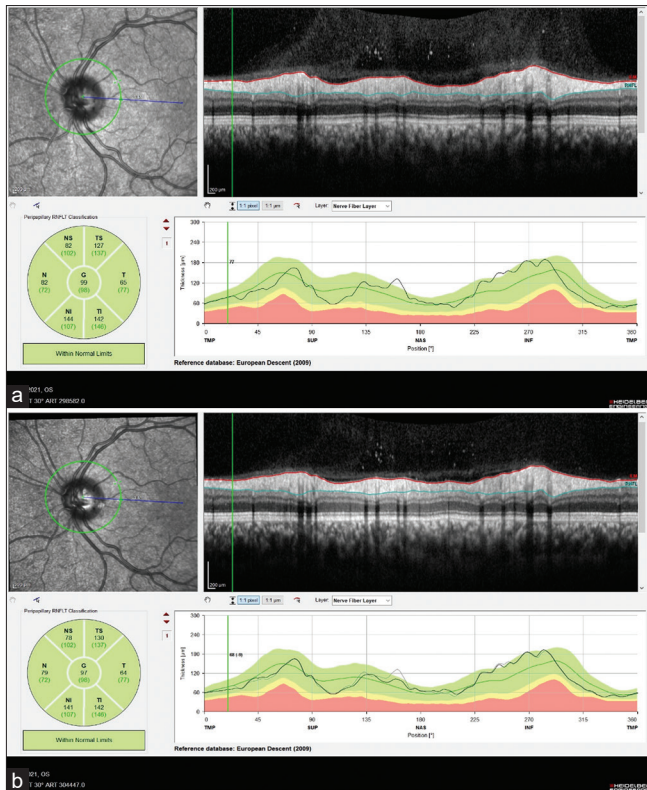
### Discussion

FD is a benign, slow-growing bone disorder, which can involve one bone (monostotic) or multiple bones (polyostotic). Common sites of skeletal involvement are long bones, ribs, craniofacial bones, and the pelvis.<sup>[4]</sup> FD usually becomes apparent during the first three decades of life, with approximately 60% of polyostotic FD patients becoming symptomatic before age 10 years.<sup>[1-3,6]</sup> However, presentation in adulthood is also common.<sup>[5,7]</sup> Gender distribution of FD has been variably reported but is equal.<sup>[2,7]</sup> Ocular problems occur in 20%–35% of patients with craniofacial FD.<sup>[8]</sup> Our case was a 27-year-old male with craniofacial FD and compressive optic neuropathy.

Ocular manifestations of FD can be evaluated clinically in two types, including primary and secondary processes. Primary orbital osseous involvement of the frontal, sphenoid, and ethmoid regions may present with proptosis, dystopia, hypertelorism or rarely with diplopia, extraocular muscle palsies, epiphora, trigeminal neuralgia, headache, periorbital and retro-orbital pain as was presented in our case, and visual loss.<sup>[2,5,6,9,10]</sup> Secondary ocular complications of



**Figure 2:** (a) Preoperative visual field (30-2). Visual field of the left eye indicated the peripheral concentric defect. (b) Postoperative visual field (30-2). This test was performed 1 month after surgical procedure and revealed significant improvement and complete regression of peripheral defect



**Figure 3:** (a) Preoperative RNFL. Despite clinical manifestations of optic neuropathy in this patient, RNFL was in normal limits. (b) Postoperative RNFL. The result indicated no change in RNFL. RNFL = Retinal nerve fiber layer

**Table 1: List of abbreviations**

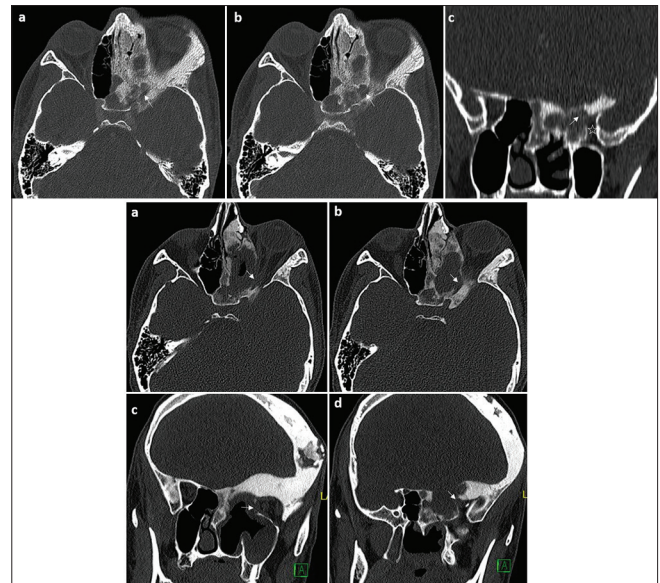
Abbreviation	Definition
FD	Fibrous dysplasia
CT	Computed tomography
BCVA	Best-corrected visual acuity
LR	Light reflex
RAPD	Relative afferent pupillary defect
VF	Visual field
OCT	Optical coherence tomography
RNFL	Retinal nerve fiber layer
CV	Color vision
MD	Mean deviation
VA	Visual acuity

**Table 2: Postoperative follow-up visit results for the left eye**

Duration since operation	BCVA (postoperative)	CV (Ishihara)	Humphrey perimetry MD (dB)	VF defect
Week 1	6/7	12/12	-15.90	Peripheric constriction
Month 1	6/6	12/12	-3.05	Within
Month 3	6/6	12/12	-1.85	normal limits

CV=Color vision, VF=Visual field, MD=Mean deviation, VA=Visual acuity, BCVA=Best-corrected VA

FD include mucocele, aneurysmal bone cyst formation, and less commonly malignant transformation, which have been observed, especially in polyostotic FD and



**Figure 4:** (a) Preoperative CT-scans. (a) FD involving most of the facial bones and skull. Optic canals are narrowed but patent. (b and c) Expansile bone lesions in the left frontal bone, left sphenoid bones, ethmoid bone, and body of the sphenoid bone with marked narrowing and deformity of the left optic canal, causing left-sided vision loss (arrows). (b) Postoperative CT scans. Left-sided optic nerve decompression was performed; follow-up CT confirmed an enlarged optic canal. CT = Computerized tomography, FD = Fibrous dysplasia

McCune–Albright syndrome.<sup>[2,4,11,12]</sup> The most common neurologic and neuro-ophthalmologic complication of craniofacial FD is visual loss and hearing impairment.<sup>[13,14]</sup> Visual impairment includes loss of CV, peripheral and central field defects, and the presence of RAPD besides reduced VA. The etiology of vision loss in patients with craniofacial FD is the result of progressive the optic nerve compression because of immature bone tissue expansion into the optic canal.<sup>[2,9,10,14,15]</sup> However, Lee *et al.* revealed that the optic canal narrowing due to FD results in the optic canal encasement and prophylactic decompression of the optic nerve has not been indicated on the basis of CT scan images. Diagnostic image results do not necessarily have a clinical association with vision loss.<sup>[16]</sup> Our case was diagnosed at the age of 10; however, visual impairment symptoms were apparent 17 years later.

According to different studies, the etiology of visual impairment in FD has been shown to be related with traction on the optic nerve, spontaneous hemorrhage, and external compression of the optic canal by a separate cystic lesion, such as a mucocele.<sup>[9,12,14,17,18]</sup> In our case, decrease in VA and color discrimination was thought to be related to the optic nerve compression by growing of bone lesions through the optic canal.

The most useful imaging technique to demonstrate the characteristics of FD is CT scanning.<sup>[19]</sup> Localization and edge of the cortical lesion can be evaluated with more details than is depicted on magnetic resonance images.<sup>[1]</sup>

The confirmation of the FD diagnosis is possible by obtaining a biopsy if the site is low risk and accessible. Dysplastic osseous lesions of FD can be relatively vascular, and the risk of biopsy in this case is bleeding. If the lesion is located in the cranial base and/or asymptomatic, biopsy may not be necessary.<sup>[6]</sup> According to the guidelines, history, clinical examination, and the radiographic imaging results are foundations of making the diagnosis in this disorder.<sup>[6]</sup> In our case, history, clinical examination, and CT scans resulted in FD characteristics and biopsy was not performed to verify the diagnosis before referring to our clinic; however, during surgical intervention in our center, the specimen was obtained and the diagnosis of FD was confirmed pathologically.

The evaluation and management of FD patients need multidisciplinary involvement and proper specialists, such as neurosurgeons, craniofacial surgeons, oral and maxillofacial surgeons, otolaryngologists, and neuro-ophthalmologists.<sup>[13]</sup> According to the current literature, there has been a controversial approach to optic nerve encasement due to craniofacial FD.<sup>[2,13,19,20]</sup> Our patient was under observation for about 17 years with annual physical examination and CT scanning. When he started to complain of visual symptoms, he was referred to our center. As a result of a multidisciplinary meeting, surgery was the decision.

Prophylactic optic nerve decompression surgery in patients with optic nerve encasement, regardless of visual impairment, has been recommended by some surgeons to prevent visual complications.<sup>[9,21,22]</sup> A meta-analysis by Amit *et al.* reported a relative risk of 4.89 (95% confidence interval, 2.26–10.59) for the optic nerve dysfunction after prophylactic surgery.<sup>[20]</sup> In addition, the immature abnormal bone tissue tends to grow back in most cases.<sup>[6]</sup> Lots of recent studies recommend not performing prophylactic decompression in asymptomatic patients.<sup>[7,14,16,17,20]</sup> Tan *et al.* revealed that while the optic nerve decompression should not be performed in patients without visual loss, it may be performed as a procedure secondary to excision of lesion in the anterior skull base during the same operation in such patients.<sup>[17]</sup> A recent meta-analysis performed by Amit *et al.* showed the results of the published cases of the optic nerve decompression surgery and reported that prophylactic surgery was not indicated in asymptomatic patients.<sup>[20]</sup>

Patients with the diagnosis of craniofacial FD with or without involvement of the optic canal on CT imaging should undergo detailed ophthalmologic examination at the baseline and follow-up visits every year which include VA, CV, contrast sensitivity, LR, RAPD, ocular movements, proptosis (by exophthalmometry), dystopia,

hypertelorism, tear duct and punctum examination, VF, and dilated fundus examination. The diagnosis of optic neuropathy should be reserved for those with a VF defect or if 2 of the 3 examinations (contrast sensitivity, CV, and fundus examination) are abnormal.<sup>[6]</sup> To evaluate the thickness of RNFL, OCT is a useful modality. OCT can be used as a diagnostic modality and also can be helpful in children and the postoperative recovery periods to assess the optic nerve recovery and predict visual outcomes.<sup>[6]</sup>

Besides serial clinical ophthalmologic examination in a conservative approach, radiologic follow-up with CT scans is a crucial component of patient management to evaluate progression of the disease.<sup>[9,20]</sup>

The optic nerve decompression surgery has its own risks, commonly including poor visual outcomes in 5%–33% of cases<sup>[9,16,18]</sup> and postoperative blindness.<sup>[16,18]</sup> Both of the mentioned postoperative complications can be the result of optic nerve damage due to vibratory or thermal damage of instruments, optic nerve edema, optic nerve sheath hematoma and ophthalmic artery occlusion, hemorrhage, or vascular spasm.<sup>[9,18]</sup> We did not see any complication in our case.

Classic surgical approaches for optic nerve decompression are transcranial and transfacial approaches. Endoscopic approaches have many superiorities in comparison with traditional external approaches including shorter recovery time, decrease in morbidity ratio, and lack of diplopia. In our case, surgery was performed by endoscopic approach without any complication by an ENT surgeon.

Our case demonstrates the need for a specialized multidisciplinary approach in the care of patients with craniofacial FD. Immediate referral for surgical evaluation should be made once there is evidence of optic neuropathy. Ophthalmologically, VA, CV, LR, RAPD, and VF are the most important parts of the examination in follow-up sessions. OCT and RNFL are not sensitive tools for the detection of early signs of compressive optic neuropathy in such patients. As mentioned in our case, preoperative and postoperative OCT and RNFL findings were normal, while the clinical findings obviously demonstrated optic neuropathy. Periodic annual follow-up is essential in monitoring for recurrence and malignant transformation.

### Declaration of patient consent

The authors certify that they have obtained all appropriate patient consent forms. In the form, the patient has given his consent for images and other clinical information to be reported in the journal. The patient understands that name and initials will not be published and due efforts will be made to conceal his identity, but anonymity cannot be guaranteed.

## Financial support and sponsorship

Nil.

## Conflicts of interest

Prof. Güliz F. Yavaş, an editorial board member at *Taiwan Journal of Ophthalmology*, had no role in the peer review process of or decision to publish this article. The other authors declared no conflicts of interest in writing this paper.

## References

1. Rootman J, Kemp E, Lapointe JS. Orbital tumors originating in bone. In: Rootman J, editor. *Diseases of the Orbit: A Multidisciplinary Approach*. Philadelphia: JB Lippincott; 1988. p. 354-79.
2. Chung EM, Murphey MD, Specht CS, Cube R, Smirniotopoulos JG. From the archives of the AFIP. Pediatric orbit tumors and tumorlike lesions: Osseous lesions of the orbit. *Radiographics* 2008;28:1193-214.
3. Katz BJ, Nerad JA. Ophthalmic manifestations of fibrous dysplasia: A disease of children and adults. *Ophthalmology* 1998;105:2207-15.
4. DiCaprio MR, Enneking WF. Fibrous dysplasia. Pathophysiology, evaluation, and treatment. *J Bone Joint Surg Am* 2005;87:1848-64.
5. Bibby K, McFadzean R. Fibrous dysplasia of the orbit. *Br J Ophthalmol* 1994;78:266-70.
6. Lee JS, FitzGibbon EJ, Chen YR, Kim HJ, Lustig LR, Akintoye SO, *et al*. Clinical guidelines for the management of craniofacial fibrous dysplasia. *Orphanet J Rare Dis* 2012;7 Suppl 1:S2.
7. Selva D, White VA, O'Connell JX, Rootman J. Primary bone tumors of the orbit. *Surv Ophthalmol* 2004;49:328-42.
8. Cutler CM, Lee JS, Butman JA, FitzGibbon EJ, Kelly MH, Brillante BA, *et al*. Long-term outcome of optic nerve encasement and optic nerve decompression in patients with fibrous dysplasia: Risk factors for blindness and safety of observation. *Neurosurgery* 2006;59:1011-7.
9. Ricalde P, Horswell BB. Craniofacial fibrous dysplasia of the fronto-orbital region: A case series and literature review. *J Oral Maxillofac Surg* 2001;59:157-67.
10. Sammut SJ, Kandasamy J, Newman W, Sinha A, Ross J, Blair JC, *et al*. Relief of severe retro-orbital pain and vision improvement after optic-nerve decompression in polyostotic fibrous dysplasia: Case report and review of the literature. *Childs Nerv Syst* 2008;24:515-20.
11. Riddle ND, Bui MM. Fibrous dysplasia. *Arch Pathol Lab Med* 2013;137:134-8.
12. Liakos GM, Walker CB, Carruth JA. Ocular complications in craniofacial fibrous dysplasia. *Br J Ophthalmol* 1979;63:611-6.
13. Cai M, Ma L, Xu G, Gruen P, Li J, Yang M, *et al*. Clinical and radiological observation in a surgical series of 36 cases of fibrous dysplasia of the skull. *Clin Neurol Neurosurg* 2012;114:254-9.
14. Michael CB, Lee AG, Patrinely JR, Stal S, Blacklock JB. Visual loss associated with fibrous dysplasia of the anterior skull base. Case report and review of the literature. *J Neurosurg* 2000;92:350-4.
15. Sassin JF, Rosenberg RN. Neurological complications of fibrous dysplasia of the skull. *Arch Neurol* 1968;18:363-9.
16. Lee JS, FitzGibbon E, Butman JA, Dufresne CR, Kushner H, Wientroub S, *et al*. Normal vision despite narrowing of the optic canal in fibrous dysplasia. *N Engl J Med* 2002;347:1670-6.
17. Tan YC, Yu CC, Chang CN, Ma L, Chen YR. Optic nerve compression in craniofacial fibrous dysplasia: The role and indications for decompression. *Plast Reconstr Surg* 2007;120:1957-62.
18. Abe T, Satoh K, Wada A. Optic nerve decompression for orbitofrontal fibrous dysplasia: Recent development of surgical technique and equipment. *Skull Base* 2006;16:145-55.
19. Tabrizi R, Ozkan BT. Craniofacial fibrous dysplasia of orbit. *J Craniofac Surg* 2008;19:1532-7.
20. Amit M, Collins MT, FitzGibbon EJ, Butman JA, Fliss DM, Gil Z. Surgery versus watchful waiting in patients with craniofacial fibrous dysplasia – A meta-analysis. *PLoS One* 2011;6:e25179.
21. Papay FA, Morales L Jr., Flaharty P, Smith SJ, Anderson R, Walker JM, *et al*. Optic nerve decompression in cranial base fibrous dysplasia. *J Craniofac Surg* 1995;6:5-10.
22. Moore AT, Buncic JR, Munro IR. Fibrous dysplasia of the orbit in childhood. Clinical features and management. *Ophthalmology* 1985;92:12-20.