



Case report

Myocarditis with tremelimumab plus durvalumab combination therapy for endometrial cancer: A case report

Syed S. Mahmood^a, Carol L. Chen^{b,c}, Natalie Shapnik^d, Udhay Krishnan^{a,c}, Harsimran S. Singh^{a,c}, Vicky Makker^{c,d,*}

^a Cardiology Division, New York Presbyterian Hospital, Weill Cornell Medical Center, New York, NY, United States

^b Cardiology Service, Department of Medicine, Memorial Sloan Kettering Cancer Center, New York, NY, United States

^c Department of Medicine, Weill Cornell Medical College, New York, NY, United States

^d Gynecologic Medical Oncology Service, Department of Medicine, Memorial Sloan Kettering Cancer Center, New York, NY, United States

ARTICLE INFO

Keywords:

Endometrial cancer
Durvalumab
Tremelimumab
Immune-mediated myocarditis
Cardio-oncology
Myositis

ABSTRACT

Background: Fulminant myocarditis has been reported in patients treated with immune checkpoint inhibitors. We present the first described case of acute immune-mediated myocarditis and myositis associated with durvalumab plus tremelimumab combination therapy. The patient was undergoing treatment for advanced endometrial cancer.

Case presentation: A 75-year-old Caucasian female presented with difficulty ambulating due to neck protraction, imbalance, and increased shortness of breath with exertion 3 weeks after her first durvalumab and tremelimumab administration for advanced endometrial cancer. While the patient's initial laboratory data showed an acute transaminitis and elevated creatine phosphokinase (CPK), consistent with myositis, she developed complete heart block and ventricular dysfunction, with elevated troponins. Endomyocardial biopsy confirmed a diagnosis of immune-mediated myocarditis. She was treated with high-dose steroids and mycophenolate mofetil, which led to eventual native conduction and left ventricular ejection fraction recovery. Upon discharge, she was titrated off of steroids over 8 weeks and her mycophenolate was subsequently stopped. A follow-up computed tomography scan revealed progression of metastatic disease. The patient remains alive using supplemental oxygen 3 months after admission.

Conclusions: Durvalumab plus tremelimumab combination therapy can lead to fulminant immune-mediated myocarditis. This patient's myocarditis was amenable to treatment with high-dose intravenous steroids and mycophenolate.

1. Introduction

Endometrial cancer is the most common gynecologic malignancy in the United States, with approximately 63,230 newly diagnosed cases and 11,350 associated deaths expected in 2018 (Siegel et al., 2018). From 1987 to 2008, there was a 50% increase in the incidence of endometrial cancer, with an approximate 300% increase in the number of associated deaths (Calle et al., 2003; National Cancer Institute, 2018). Although there are many chemotherapeutic and targeted therapies approved for ovarian, fallopian tube and primary peritoneal cancers, since the 1971 approval of megestrol acetate for the palliative treatment of advanced endometrial cancer, only pembrolizumab has been Food and Drug Administration approved for high microsatellite instability (MSI-H) or mismatch repair deficient (dMMR) endometrial

cancer. As a result, there has been an ever-growing focus on the development of novel therapies to treat advanced endometrial cancer.

Immune checkpoint inhibitors (i.e., monoclonal antibodies targeting cytotoxic T lymphocyte-associated antigen 4 [CTLA-4], programmed cell death 1 [PD-1], and its ligand [PD-L1]) have revolutionized treatment in a myriad of malignancies previously associated with poor prognosis. Immunotherapy has been aggressively explored in endometrial cancer (NCT03367741, NCT02982486, NCT03241745, NCT02899793, NCT03310567, NCT02630823, and NCT02501096). Over the past several years, cases of myocarditis and fatal heart failure have been reported in patients with cancer treated with immune checkpoint inhibition (ICI), both as single agents and in combinations (Heinzerling et al., 2016; Johnson et al., 2016). Here, we present the first described case of acute immune-mediated myocarditis and

* Corresponding author at: Gynecologic Medical Oncologic Service, Department of Medicine, Memorial Sloan Kettering Cancer Center, 1275 York Avenue, New York, NY 10065, United States.

E-mail address: makkerv@mskcc.org (V. Makker).

<https://doi.org/10.1016/j.gore.2018.05.014>

Received 27 April 2018; Accepted 29 May 2018

Available online 01 June 2018

2352-5789/© 2018 The Authors. Published by Elsevier Inc. This is an open access article under the CC BY-NC-ND license

(<http://creativecommons.org/licenses/by-nc-nd/4.0/>).

myositis associated with durvalumab plus tremelimumab combination therapy. Of note, the patient was undergoing treatment for advanced endometrial cancer.

2. Case presentation

A 75-year-old Caucasian woman presented with vaginal spotting. An endometrial biopsy revealed serous carcinoma. She underwent a robotically assisted radical hysterectomy, bilateral pelvic and aortic lymph node dissection, and omentectomy. Pathology revealed a stage IIIC2 serous carcinoma of the endometrium with one positive right aortic lymph node. DNA mismatch repair proteins were retained on immunohistochemistry. She received intravaginal radiation therapy followed by carboplatin area under the curve (AUC) 5 and paclitaxel.

After a 6-month remission, she was found to have newly metastatic disease, with bilateral pulmonary nodules, a hepatic lesion, and lymphadenopathy. She was enrolled on a randomized phase 2 trial comparing the PD-L1 inhibitor durvalumab alone versus durvalumab plus the CTLA-4 inhibitor tremelimumab for advanced endometrial cancer. She was randomized to the combination arm and received her first cycle of durvalumab 1500 mg flat dose and tremelimumab 75 mg flat dose. On Cycle 1 Day 1, she reported minimal side effects, only grade 1 skin pruritus.

Nearly 4 weeks after initiating immunotherapy, she presented with a 5-day history of difficulty ambulating due to neck weakness, imbalance, and progressive dyspnea on exertion. She was afebrile, with stable vital signs. She had no cardiac risk factors and denied any other cardiac symptoms. Her physical exam was normal; however, a chest radiograph demonstrated scattered interstitial opacities possibly due to pneumonitis and not an infectious or inflammatory process. Initial laboratory data were notable for newly developed transaminitis (aspartate transaminase [AST] 308/alanine transaminase [ALT] 252) and an elevated creatine phosphokinase (CPK) level to 5158 U/L (normal, < 140). Intravenous methylprednisolone at 1 mg/kg was started immediately for suspected pneumonitis and myositis. A CT of her chest ruled out pneumonitis, instead confirming bi-basilar consolidations and numerous metastases to lungs, liver, and bone.

Thirty-six hours later, her dyspnea had worsened, now requiring 6 L of nasal cannula (NC). She was found to be newly bradycardic (40 bpm), and an electrocardiogram (ECG) showed new complete heart block (Fig. 1A) with junctional escape rhythm, and at other times, accelerated idioventricular escape rhythm. She was transferred to the intensive care unit (ICU), where a transvenous pacer (TVP) was placed. Her troponin I, checked for the first time at this point, was elevated to 5 ng/mL (normal, < 0.02 ng/mL; Fig. 2). A bedside transthoracic echocardiogram (TTE) showed 54% left ventricular ejection fraction (EF), with regional areas of hypokinesis. Over the next 12 h, despite an escalated intravenous methylprednisolone dose to 10 mg/kg and the addition of mycophenolate mofetil 1000 mg oral twice daily, her troponin I rose to 6.7 ng/mL. She continued to alternate between

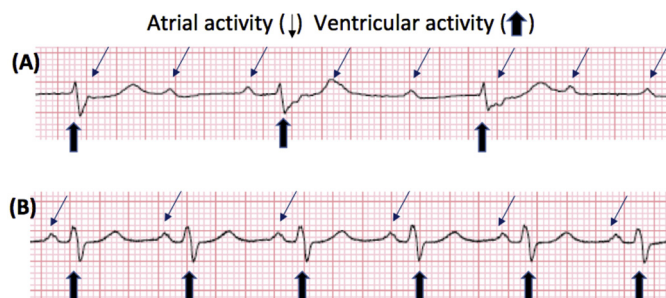


Fig. 1. (A) Electrocardiogram (ECG) with complete heart block showing atrial activity dissociated from ventricular activity. (B) ECG with resolution of heart block with synchronized atrial and ventricular activity.

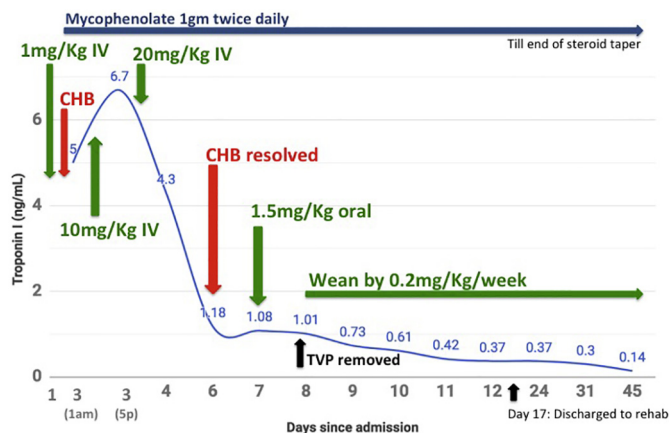


Fig. 2. Time course of complete heart block occurrence, troponin elevation, and initiation of mycophenolate mofetil and high-dose steroids. CHB, complete heart block; TVP, transvenous pacemaker.

intermittent intrinsic normal sinus rhythm at 80 bpm, and requiring pacing via TVP. The patient was then placed on 1000 mg (20 mg/kg) daily intravenous methylprednisolone (high dose) for presumed myocarditis secondary to ICI therapy, similar to the established treatment for acute rejection in orthotopic heart transplant patients. Emergent cardiac catheterization and endomyocardial biopsy were performed later that day and revealed non-obstructive coronary disease and lymphohistiocytic myocarditis (Fig. 3) with occasional eosinophils.

Twelve hours after the initiation of 1000 mg intravenous methylprednisolone, her troponin I levels began to drop, steadily declining over the subsequent weeks (Fig. 2). She required intermittent pacing for 2 days while receiving high-dose methylprednisolone, after which she returned to sinus rhythm (Fig. 1B). High-dose methylprednisolone was discontinued after 3 days, and she was started on 1.5 mg/kg prednisone, with a plan for tapering by 10 mg (0.2 mg/Kg) per week, and weekly troponin measurements for myocarditis recurrence surveillance. She was continued on mycophenolate 1000 mg twice daily, with a plan to discontinue the medication after completing her prednisone taper. She had a persistent 2 L NC oxygen requirement, attributed to her increased metastatic pulmonary cancer burden, which did not improve with diuresis. A TTE after pacing discontinuation demonstrated an abnormally low EF of 35%; she was started on enalapril for heart failure, which had to be discontinued due to low blood pressure. A repeat TTE 2 months after her presentation showed an improved EF of 59%. Despite these improvements, she still requires oxygen by NC and is unable

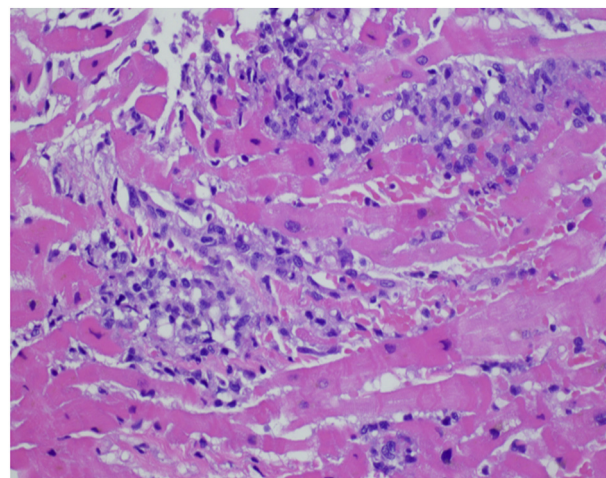


Fig. 3. Hematoxylin and eosin stain of right ventricular endomyocardial biopsy showing lymphohistiocytic infiltration with occasional eosinophils.

to independently perform daily activities.

3. Discussion

Immune checkpoint receptors on both T cells and non-immune-related cells such as those of the myocardium play a key role in the maintenance of self tolerance; their therapeutic blockade can alter immunological tolerance (Lichtman, 2013; Rodig et al., 2003), resulting in autoimmune or inflammatory immune-mediated adverse events (AEs). Non-cardiac side effects of ICI are typically limited to grade ≤ 3 AEs treatable with low-dose steroids (Postow et al., 2018). Myocarditis associated with ICI, however, can be fulminant (Mahmood et al., 2018). More data are needed to establish the incidence of ICI-associated myocarditis. In a multi-center registry of ICI-associated myocarditis, the prevalence at one institution was 1%, with half of these patients experiencing major adverse cardiovascular events (MACEs) of grade 4 or 5 severity (Boutros et al., 2016). In a Bristol-Myers Squibb safety database, 18 drug-related severe AEs of myocarditis (0.09% of the database) were noted (Eigentler et al., 2016; Costa et al., 2017), which is likely an underestimate, as myocarditis was not initially recognized as an AE of ICI. Combination therapy of an anti-CTLA-4 agent with either an anti-PD1 or anti-PD-L1 agent has been associated with an increased rate of myocarditis (Johnson et al., 2016), as well as non-cardiac immune-mediated AEs, resulting in discontinuation of treatment in almost 40% of treated patients (Mahmood et al., 2018).

ICI is an important advancement in the treatment of metastatic malignancies, and clinicians should have the ability to recognize and manage the AEs associated with this treatment approach, as well as with strategies to help patients tolerate cardiac AEs (Johnson et al., 2016). The median time to presentation of myocarditis is 34–65 days after initiation of treatment (Mahmood et al., 2018). Four of 5 cases of ICI-associated myocarditis occur within the first 3 months of starting therapy (Larkin et al., 2015; Postow et al., 2015) and a troponin T of ≥ 1.5 ng/mL is associated with a four-fold increase of cardiovascular death, cardiogenic shock, cardiac arrest, and hemodynamically significant complete heart block (Brahmer et al., 2018). Although data are lacking, experience-based algorithms for myocarditis surveillance have proposed checking troponin with every infusion (if dosed every 3 weeks) or with every other infusion (if fortnightly dosed) for the first 3 months of treatment (Mahmood et al., 2018; Escudier et al., 2017). TTE does not appear to be an effective surveillance tool, as more than half of ICI-associated myocarditis cases present with a normal EF (Mahmood et al., 2018). Patients with suspected ICI-associated myocarditis (i.e., presenting with symptoms of shortness of breath, chest pain, orthopnea, paroxysmal nocturnal dyspnea or fatigue) should have troponin measured and promptly referred to cardio-oncology or cardiology if warranted. Current registry data have relied upon cardiac magnetic resonance imaging or endomyocardial biopsy to establish a myocarditis diagnosis (Mahmood et al., 2018). In the event of hemodynamic instability or conduction abnormality, patients should be transferred to a cardiac ICU (Mahmood et al., 2018; Brahmer et al., 2018).

Recent data suggest ICI-associated myocarditis is amenable to treatment with immunosuppression (Mahmood et al., 2018). Higher mg/kg dosing of intravenous methylprednisolone is associated with a lower rate of major adverse cardiovascular events (2 mg/kg vs 0.8 mg/kg, $p = 0.04$ for non-MACE vs MACE, respectively). There was a non-significant trend towards less MACE when methylprednisolone is started promptly on admission for myocarditis (18 h vs 27 h, $p = 0.12$ for non-MACE vs MACE, respectively). Data on the use of other immunosuppressive agents such as mycophenolate, infliximab, and anti-thymoglobulin are lacking.

This is the first described case of durvalumab and tremelimumab-associated myocarditis and myositis. This AE occurred after the initial dose and progressed rapidly. Myocarditis was accompanied by other immune-related AEs and responded to high-dose steroids and

mycophenolate. Left ventricular dysfunction was not the initial symptom, and cardiac symptoms were not prominent early on. Vigilance on the part of the treating oncologist and close monitoring for immune-related cardiac events is imperative, as the mortality associated with cardiac AEs is high. However, prompt initiation of high-dose intravenous methylprednisolone is associated with improved cardiac outcomes (Mahmood et al., 2018; Escudier et al., 2017).

4. Conclusions

Although myocarditis is a serious AE of ICI therapy, the cardiotoxicity is treatable with high-dose immunosuppression, as seen in our case report. ICI is an important advancement in cancer therapy, and this case report provides insight into the management of cardiac AEs associated with cancer therapy.

Consent

According to our institutional policies, this case report has obtained Institutional Review Board exemption.

Conflict of interest statement

The authors have no conflicts of interest to declare.

Funding

Drs. Chen and Makker are supported in part by the NIH/NCI MSK Cancer Center Support Grant P30CA008748.

Author contributions

Manuscript writing: SS Mahmood, CL Chen, V Makker.

Analysis of data: SS Mahmood, CL Chen, V Makker.

Creation/acquisition of figures: N Shapnik, U Krishnan, HS Singh.

Manuscript review and critique: SS Mahmood, CL Chen, N Shapnik, U Krishnan, HS Singh, V Makker.

Final approval of manuscript: SS Mahmood, CL Chen, N Shapnik, U Krishnan, HS Singh, V Makker.

Funding

Drs. Chen and Makker are supported in part by the NIH/NCI MSK Cancer Center Support Grant P30CA008748.

References

- Boutros, C., Tarhini, A., Routier, E., et al., 2016. Safety profiles of anti-CTLA-4 and anti-PD-1 antibodies alone and in combination. *Nat. Rev. Clin. Oncol.* 13, 473–486.
- Brahmer, J.R., Lacchetti, C., Schneider, B.J., et al., 2018 Feb 14. Management of immune-related adverse events in patients treated with immune checkpoint inhibitor therapy: American Society of Clinical Oncology Clinical Practice Guideline. *J. Clin. Oncol.* 1714–1768. JCO2017776385. <https://doi.org/10.1200/JCO.2017.77.6385>.
- Calle, E.E., Rodriguez, C., Walker-Thurmond, K., Thun, M.J., 2003. Overweight, obesity, and mortality from cancer in a prospectively studied cohort of US adults. *N. Engl. J. Med.* 348, 1625–1638.
- Costa, R., Carneiro, B.A., Agulnik, M., et al., 2017. Toxicity profile of approved anti-PD-1 monoclonal antibodies in solid tumors: a systematic review and meta-analysis of randomized clinical trials. *Oncotarget* 8, 8910–8920.
- Eigentler, T.K., Hassel, J.C., Berking, C., et al., 2016. Diagnosis, monitoring and management of immune-related adverse drug reactions of anti-PD-1 antibody therapy. *Cancer Treat. Rev.* 45, 7–18.
- Escudier, M., Cautela, J., Malissen, N., et al., 2017. Clinical features, management, and outcomes of immune checkpoint inhibitor-related cardiotoxicity. *Circulation* 136, 2085–2087.
- Heinzerling, L., Ott, P.A., Hodi, F.S., et al., 2016. Cardiotoxicity associated with CTLA4 and PD1 blocking immunotherapy. *J. Immunother.* Cancer 4, 50.
- Johnson, D.B., Balko, J.M., Compton, M.L., et al., 2016. Fulminant myocarditis with combination immune checkpoint blockade. *New Engl. J. Med.* 375, 1749–1755.
- Larkin, J., Chiarion-Sileni, V., Gonzalez, R., et al., 2015. Combined nivolumab and ipilimumab or monotherapy in untreated melanoma. *New Engl. J. Med.* 373, 23–34.

- Lichtman, A.H., 2013. The heart of the matter: protection of the myocardium from T cells. *J. Autoimmun.* 45, 90–96.
- Mahmood, S.S., Fradley, M.G., Cohen, J.V., et al., 2018. Myocarditis in patients treated with immune checkpoint inhibitors. *J. Am. Coll. Cardiol.* 71, 1755–1764.
- National Cancer Institute, 2018. Drugs Approved for Endometrial Cancer. American Cancer Society.
- Postow, M.A., Chesney, J., Pavlick, A.C., et al., 2015. Nivolumab and ipilimumab versus ipilimumab in untreated melanoma. *New Engl. J. Med.* 372, 2006–2017.
- Postow, M.A., Sidlow, R., Hellmann, M.D., 2018. Immune-related adverse events associated with immune checkpoint blockade. *New Engl J Med* 378, 158–168.
- Rodig, N., Ryan, T., Allen, J.A., et al., 2003. Endothelial expression of PD-L1 and PD-L2 down-regulates CD8+ T cell activation and cytotoxicity. *Eur. J. Immunol.* 33, 3117–3126.
- Siegel, R.L., Miller, K.D., Jemal, A., 2018. Cancer statistics, 2018. *CA Cancer J. Clin.* 68, 7–30.