



Since January 2020 Elsevier has created a COVID-19 resource centre with free information in English and Mandarin on the novel coronavirus COVID-19. The COVID-19 resource centre is hosted on Elsevier Connect, the company's public news and information website.

Elsevier hereby grants permission to make all its COVID-19-related research that is available on the COVID-19 resource centre - including this research content - immediately available in PubMed Central and other publicly funded repositories, such as the WHO COVID database with rights for unrestricted research re-use and analyses in any form or by any means with acknowledgement of the original source. These permissions are granted for free by Elsevier for as long as the COVID-19 resource centre remains active.

Case report

Chronic, eventually fatal, Kawasaki-like disease in an adult with spondylarthropathy responding to IVIG therapy

Elise Soltner^a, Antoine Neel^b, Mourad Tiab^c, Stéphane Varin^d, Grégoire Cormier^d,
Hervé Maisonneuve^c, Yves Maugars^a, Gilles Tanguy^d,
Mohamed Hamidou^a, Jean-Marie Berthelot^{a,*}

^a Rheumatology unit, CHU de Nantes, 1, place Alexis, 44093 Nantes cedex 01, France

^b Internal Medicine unit, CHU de Nantes, 44093 Nantes cedex 01, France

^c Internal Medicine unit, centre hospitalier de La Roche-sur-Yon, Les Oudairies, 85000 La Roche-sur-Yon, France

^d Rheumatology unit, centre hospitalier de La Roche-sur-Yon, Les Oudairies, 85000 La Roche-sur-Yon, France

Accepted 19 January 2009

Available online 21 May 2009

Abstract

We report on an unusual case of a 40-year-old Caucasian male displaying severe Kawasaki-like symptoms. The disease lasted for seven years before diffuse coronary aneurysms occurred, leading to the patient's death, despite ongoing treatment by intravenous immunoglobulins (IVIGs). The patient had also been suffering from a disabling inflammation of the spine, which was reported to have started at the onset of the disorder. Whereas neither NSAIDs, nor high doses corticosteroids, or anti-TNF drugs had a clear effect, the clinical features of spinal inflammation were highly sensitive to IVIGs, and were attributed definitively to HLA-B27-negative axial spondylarthropathy after bone scan and magnetic resonance imaging disclosed typical enthesitis of both heels and bilateral sacroiliitis.

© 2009 Société française de rhumatologie. Published by Elsevier Masson SAS. All rights reserved.

Keywords: Kawasaki; Kawasaki's; Adult onset; Coronary aneurysms; Spondylarthropathy; Ankylosing spondylitis; Enthesis; Sacroiliitis; Back pain; IgIV; Anti-TNF; Chelitis; Desquamation; Conjunctivitis; Fever

1. Introduction

Kawasaki disease is a rare multi-systemic form of vasculitis, affecting mostly young children. It rarely occurs in adults. Indeed, less than a hundred cases have been reported [1,2]. Moreover, Kawasaki disease usually evolves as an acute disorder, and has not been associated thus far with clinical or imaging features suggestive of spondylarthropathy. We report on an unusual case of a 40-year-old Caucasian male displaying severe Kawasaki-like symptoms. The disease lasted for seven years before diffuse coronary aneurysms occurred, leading to the patient's death, despite ongoing treatment by intravenous IVIGs. The patient had also been suffering from a disabling inflammation of the spine, which was reported to have started at the onset of the disorder. The clinical features of spinal inflammation were highly

sensitive to IVIGs, and were attributed definitively to HLA-B27-negative axial spondylarthropathy after bone scan and magnetic resonance imaging disclosed typical enthesitis of both heels and bilateral sacroiliitis.

2. Case report

The patient was a farmer with no previous medical history. He began to suffer from painful migrating arthralgia in August 1998; this was associated with tarsal pain, heel enthesitis, and inflammatory back pain (pain of the lower back, occurring mainly during the second part of the night, and associated with a long lasting morning stiffness, partly relieved by daily exercise). The disorder followed a remitting-relapsing course. The patient was treated with sulfasalazine for four months, despite the absence of the HLA-B27 gene; however, this treatment was ineffective.

The patient exhibited various conditions within six months: high grade fever (39 °C to 40 °C), fatigue, CRP over 400 mg/l, bilateral conjunctival hyperemia, hepatosplenomegaly, axillary

* Corresponding author.

E-mail address: jeanmarie.berthelot@chu-nantes.fr (J.-M. Berthelot).

lymph node enlargement (two nodes were painful and necrotic), and edema at the extremities. He also began to complain from recurrent cheilitis, palmar and plantar erythema, and pharyngitis. Reactive arthritis was initially suspected, but this diagnosis was called into question after a failure of steroids (up to 100 mg prednisone a day), NSAIDs and methotrexate.

Although gammaglobulin levels were normal, a trial of pooled IVIGs (Tegeline®, LFB laboratories) (400 mg/kg per day every five to six weeks) was proposed (March 1999). This treatment induced a significant improvement that lasted several weeks. Clinical features (including severe inflammatory back pain) relapsed one month after each immunoglobulin infusion, throughout the following 5-year period.

Infliximab and then etanercept were introduced from July 2004 to August 2005, to try and decrease the need for IVIG, but this had no effect on how often IVIG infusions were required. Anakinra was then prescribed at a daily dose of 100 mg for six weeks, but this was also ineffective. Indeed, his condition worsened as a result of this treatment. Various conditions appeared: spiking fever, transient interstitial pneumonitis, transient proteinuria, severe synovitis of the knees and ankles, sensori-neural deafness and confusion (not explained by encephalic MRI and cerebrospinal fluid examination), together with a flare-up of features typical of Kawasaki disease, particularly an infected pharynx together with strawberry tongue, severe cheilitis (Fig. S1; see the supplementary material associated with this article online), cervical lymphadenopathy, and desquamation of the feet and hands which had started per-ungually (Fig. S2). These symptoms quickly improved after another infusion of 400 mg/kg IVIG.

The echocardiographs were still normal, including cardiac enzyme levels, electrocardiograms, and thallium 201 cardiac scintigraphy. All searches for an underlying infection remained negative: blood cultures, cultures of broncho-alveolar fluid, polymerase chain reaction for coronaviruses on nasal and pharyngeal smears, serological tests for CMV, HHV6, HHV8, parvovirus, *Cryptococcus*, *Aspergillus* and *Legionella*. Tests for ANCA, ANA, and cryoglobulins were also negative.

A positron emission tomography (PET) scan was carried out, but proved unhelpful. Indeed, this examination showed no uptake, in the spine, pelvic girdle, heels, heart and kidneys, despite ongoing inflammatory pain in the back and a chronic elevation of C-reactive protein levels (from 60 to 300 mg/l). The patient was then discharged. However, after two further infusions of IVIG, the patient reported another bout of inflammatory pain in the heels, sacroiliac areas and along the entire spine, associated with a polymorphous rash (without vasculitis on biopsy) and severe conjunctivitis. The CRP value was still very high (373 mg/l). A strong uptake of the radionuclide in the patient's heels and feet (Fig. 1) was evident on the bone scan, and an MRI scan confirmed enthesitis of the Achilles tendon insertion in both heels, as well as definite inflammation of the sacroiliac joints. Gastric and sigmoid endoscopies were unremarkable, with no features to suggest Whipple's disease. Indeed, macrophage infiltration, or periodic acid-Schiff (PAS)-positive macrophages were not observed in the intestinal mucosa.

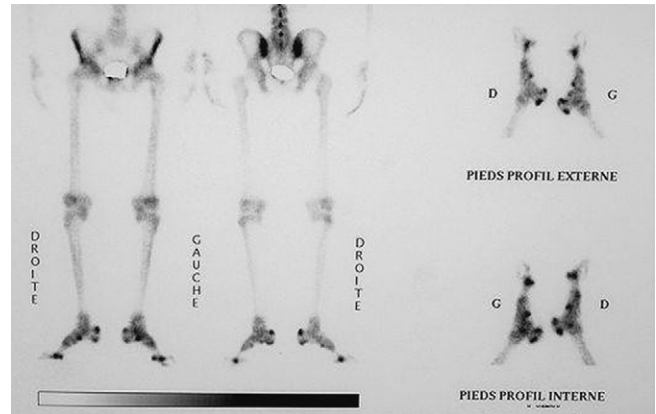


Fig. 1. Bone scan showing a significant uptake in heels and feet, linked to polyenthesitis on MRI.

As IVIGs had become less effective over the last six months, a coronarography was carried out to search for silent aneurysms in heart arteries. This examination showed diffuse aneurysms in coronary arteries, and renal arteriography also identified several micro-aneurysms in both kidneys. Rituximab (500 mg every two weeks for three weeks) was ineffective. As the hemodynamic status of the patient worsened, thalidomide was discussed. However, nephritic syndrome was observed and heart failure finally led to the patient's death, despite a final infusion of IGIV and the use of cyclophosphamide intravenous.

3. Discussion

This rare case is informative for several reasons. First, Kawasaki disease in adults has often been described as a “one-shot disease”, only lasting for several months [1,2]. Our patient died seven years after contracting Kawasaki disease; the symptoms were ongoing during this period and required more than fifty IVIG infusions. This diagnosis was based on the presence (at least during one examination) of the whole set of criteria for this condition:

- fever for five days or more;
- bilateral conjunctival injection without exudate;
- polymorphous exanthem;
- changes to lips and mouth, together with strawberry tongue, and redness of the pharyngeal mucosa;
- desquamation of the skin of hands and feet;
- cervical lymphadenopathy [3].

Pooled IVIGs (Tegeline®, LFB laboratories) (400 mg/kg per day every five to six weeks), prescribed initially in March 1999, induced a significant improvement that lasted for several weeks on more than 50 occasions [4,5]. Angiography showed diffuse aneurysms in coronary arteries, one month before the patient's death. However, clinical features (including severe inflammatory back pain) relapsed one month after each immunoglobulin infusion, throughout the five-year period. This is an unusual phenomenon in Kawasaki disease, which is most often a short-lived disorder [1,2]. Thus, this case should perhaps be classified

as a Kawasaki-like disorder. Coronary aneurysms developed very late, as troponin levels, electrocardiograms, and thallium scintigraphy of the heart were still normal four months before the patient's death. Thus, the patient may have had a combination of a chronic Kawasaki-like disease and acute polyarteritis nodosa.

This Kawasaki-like disease was associated, at the onset, with disabling inflammatory back and buttock pain, and was associated with heel pain and transient but extensive synovitis of the knees and ankles. Imaging was not consistent with the diagnosis of HLA-B27-negative spondylarthropathy (including TEP-scan), until the bone scan. The MRI scan clearly confirmed the presence of severe enthesitis in both heels and bilateral sacroiliitis, two months before the patient's death. This had not been described previously, but transient sacroiliitis has been reported once in a self-limiting association of symptoms suggestive of Kawasaki disease in a young (23-year-old) Spanish male [6].

This spondylarthropathy was significantly improved by IVIGs, whereas NSAIDs, high dose corticosteroids, and anti-TNF drugs had no clear effect. Improvements in spondylarthropathy-like disorders by IVIGs have not been previously reported. However, as neither uveitis, nor inflammatory disorder of the digestive tract or psoriasis could be identified, this type of rheumatism may somewhat differ from classic HLA-B27-positive ankylosing spondylitis. Accordingly, the use of IVIGs should not be advocated, based on this single case, in treating other forms of spondylarthropathy that do not respond to TNF-blockers.

The simultaneous occurrence and change in Kawasaki and spondylarthropathy features, together with their particular responses to IVIGs during the first six years (contrasting with poor efficacy of TNF-blockers), suggest closely related pathogenesis for the two processes. Also, a better understanding of Kawasaki disease physiopathology may reveal unexpected mechanisms that also lead to chronic inflammatory pain of the back, sacroiliac, and heels, observed in most spondylarthropathies. The clearance of a so far unrecognized pathogen that might have triggered spondylarthropathy and Kawasaki disease could be one explanation [7]. However, extensive searches for other pathogens were negative in our patient, including PCR analyses for coronaviruses [8], despite the presence of hepatosplenomegaly and lymph node enlargement (complicated twice by a painful lymph node necrosis).

This unusual case highlights that Kawasaki disease should not be discounted in adult patients with features suggestive of spondylarthropathy. Indeed, conjunctival hyperemia may be confused with uveitis, Kawasaki eruptions with atypical psoriasis (which are likely [9]), distal edema with edema associated with some peripheral spondylarthropathy [10], and fever with systemic manifestations sometimes observed in patients with ankylosing spondylitis [11], reactive arthritis, or crippling infections linked to unusual germs, including *Tropheryma whipplei* [12].

Appendix A. Supplementary data

Supplementary material (Fig. S1, S2) associated with this article can be found at <http://www.sciencedirect.com>, at doi:10.1016/j.jbspin.2009.01.006.

References

- [1] Sève P, Stankovic K, Smail A, et al. Adult Kawasaki disease: Report of two cases and literature review. *Semin Arthritis Rheum* 2005;34:785–92.
- [2] Sève P, Bui-Xuan C, Charhon A, et al. La maladie de Kawasaki de l'adulte. *Rev Med Interne* 2003;24:577–84.
- [3] Newburger JW, Takahashi M, Gerber MA, et al. Diagnosis, treatment, and long-term management of Kawasaki disease: A statement for health professionals from the Committee on Rheumatic Fever, Endocarditis, and Kawasaki disease, Council on cardiovascular disease in the young. *American Heart Association. Pediatrics* 2004;114:1708–33.
- [4] Newburger JW, Takahashi M, Burn JC, et al. The treatment of Kawasaki syndrome with intravenous gamma globulin. *N Engl J Med* 1986;315:341–7.
- [5] Wolff AE, Hansen KE, Zakowski L. Acute Kawasaki disease: Not just for kids. *J Gen Intern Med* 2007;22:681–4.
- [6] Herrero JB, Ornia N, Serrano O, et al. Kawasaki's syndrome in the adult and bilateral sacroiliitis. *Med Intern* 1995;12:549–55.
- [7] Rowley AH, Shulman ST. New developments in the search for the etiologic agent of Kawasaki disease. *Curr Opin Pediatr* 2007;19:71–4.
- [8] Esper F, Shapiro ED, Weibel C, et al. Association between a novel human coronavirus and Kawasaki disease. *J Infect Dis* 2005;191:499–502.
- [9] Mizuno Y, Suga Y, Muramatsu S, et al. Psoriasiform and palmoplantar pustular lesions induced after Kawasaki disease. *Int J Dermatol* 2006;45:1080–2.
- [10] Cantini F, Salvarani C, Olivieri I, et al. Remitting seronegative symmetrical synovitis with pitting oedema (RS3PE) syndrome: A prospective follow up and magnetic resonance imaging study. *Ann Rheum Dis* 1999;58:230–6.
- [11] Arlet JB, Gentelle S, Grasland A, et al. Febrile form of ankylosing spondylitis. *Rev Med Interne* 2002;23:81–4.
- [12] Várkonyi C, Bubán T, Szakáll S, et al. Fever of unknown origin with seronegative spondylarthropathy: An atypical manifestation of Whipple's disease. *Ann Rheum Dis* 2002;61:377–8.