

# Progressive electrical remodeling in apical hypertrophic cardiomyopathy leading to implantable cardioverter-defibrillator sensing failure during ventricular fibrillation



Blake E. Fleeman, MD, Boaz Avitall, MD, PhD, FHRS

*From the University of Illinois Chicago, Chicago, Illinois.*

## Introduction

Although there is a paucity of randomized trials evaluating outcomes after primary-prevention implantable cardioverter-defibrillator (ICD) placement for patients with hypertrophic cardiomyopathy, guidelines recommend ICD placement for certain patients with the disease.<sup>1</sup> Apical hypertrophic cardiomyopathy (AHCM) is one pattern of disease manifestation with unique characteristics.<sup>2</sup> Hypertrophy involves predominantly the apex of the left ventricle and at times the right ventricle. Whereas some have suggested a benign course of disease in cases of AHCM,<sup>3</sup> there are a few reports of patients developing sustained ventricular arrhythmias and sudden cardiac death.<sup>4–7</sup> We present a case of ventricular fibrillation (VF) and ICD failure because of sensing failure and subsequent ICD manipulation in a patient with AHCM. This case brings to light longitudinal changes in the hypertrophic tissues, electrical changes during VF, and the need for interval testing to ensure proper device function in the setting of tissue remodeling over time.

## Case report

A 59-year-old male skier with an athletic lifestyle with known AHCM suffered an out-of-hospital VF arrest. Nine years prior to the VF arrest, he had undergone ICD implantation for primary prevention of sudden cardiac death. His past medical history included isthmus-dependent flutter with successful cavotricuspid isthmus ablation; paroxysmal atrial fibrillation; and Addison disease. He had no known history of sustained ventricular arrhythmias and no family history of sudden cardiac death. At the initial presentation 12 years prior to the event, the electrocardiogram (ECG) showed V<sub>4</sub> R wave of 55 mm (5.5 mV), QRS width of 96 msec, and 5 mm precordial ST depression with deeply

**KEYWORDS** Apical hypertrophic cardiomyopathy; Hypertrophic cardiomyopathy; Ventricular fibrillation; ICD; Sensing failure; Devices (Heart Rhythm Case Reports 2017;3:43–48)

**Address reprint requests and correspondence:** Dr Boaz Avitall, 840 S Wood St, Suite 920 S, Chicago, IL 60612-7323. E-mail address: bavitall@uic.edu.

inverted T waves measuring 20 mm (2 mV), the pattern often seen in AHCM.<sup>7,8</sup> Transthoracic echocardiography showed severe left ventricular apical hypertrophy (13 mm thickness of the septum and posterior walls, but 23 mm at the apex) without any apical aneurysm (Figure 1A).

He underwent implantation of a Guidant ICD at age 50. Coil and sensing lead were placed in the right ventricular (RV) apex, with an R wave of 11 mV, impedance of 800 ohms, and pacing threshold of 1 volt. Active fixation lead was placed in the right atrial appendage with a P wave of 2.6 mV, impedance of 956 ohms, and pacing threshold of 1.2 volts. Defibrillator testing was performed, with 21 J from his device converting him to normal sinus rhythm with impedance of 43 ohms. There appeared to be proper detection with no undersensing.

After 4 years of regular follow-up and no shocks, the patient returned for generator change secondary to battery depletion. He had a new generator (Boston Scientific TELIGEN IS-1/DF-1-DR) implanted and connected to his previously placed leads. Testing at that time revealed that the RV apical lead had an R wave of 16.6 mV, impedance of 458 ohms, pacing threshold 0.8 volts. Following the generator change, the patient again underwent defibrillation testing (DFT). Initially there was failure to sense owing to fallout and the patient received external defibrillation at 250 J. The device was tested again with increased sensitivity to 0.5 mV. After VF induction, 31 J from the device converted the patient cleanly to normal sinus rhythm with impedance of 39 ohms. As measured by the RV lead, the maximal peak-to-peak amplitude of the VF was 15 mV. It is worth noting that on careful review of the electrograms there are a few instances of undersensed low-amplitude fractionated activity, but the fractionated activity appeared to be of a low burden of the total activity and did not interfere with the device's recognition of VF.

The patient did well for years with no ICD therapy and routine follow-up. Unfortunately, he suffered an out-of-hospital arrest 5 years after his generator change, at age 59. Civilians found him unresponsive and cardiopulmonary resuscitation was initiated. Emergency medical services arrived and administered 2 external shocks for VF, with

## KEY TEACHING POINTS

- Apical hypertrophy is a unique disease with important considerations for device optimization. Progressive V<sub>4</sub> R-wave reduction and ST-segment normalization are likely markers of scarring of the hypertrophic apical tissues impacting implantable cardioverter-defibrillator sensing during ventricular fibrillation.
- An implantable cardioverter-defibrillator sensing lead should be placed in normal tissues once electrocardiogram changes are noted and low-amplitude fractionated activity is recorded during defibrillation testing. Routine defibrillation testing every 2–3 years in patients with atypical anatomy should be considered.
- Good R-wave sensing in sinus may not necessarily indicate reliable sensing during ventricular fibrillation in patients with abnormal anatomy.

return of spontaneous circulation. After induced hypothermia per standard protocol, he regained total neurologic function by 1 month. At this time, the ECG showed V<sub>4</sub> R wave of 20 mm, QRS width 106 msec, no ST-segment depression, and T wave now upright (Figure 1B).

The ICD data during the arrest was analyzed and showed baseline R wave of 15 mV while in sinus, which was similar to prearrest measurements. Nonetheless, the device shows development of ventricular tachycardia that quickly degenerated into very fine VF. Shortly after VF onset, the maximal peak-to-peak amplitude was approximately 13 mV. Within 3.5 seconds the activity became highly fractionated, with segments of much lower amplitude consistently less than 3 mV (minimal <1 mV) and detection gaps of 443 msec, leading to counter resetting and failure to shock (Figure 2). Eventually the device administered a 41 J shock at approximately 6 minutes into the episode, with brief return of sinus rhythm followed by rapid recurrence of VF. Following another ineffective shock by his device, he received external defibrillation by Emergency Medical Services. In total, he experienced approximately 11 minutes of VF as recorded by his device.

After clinical improvement, the patient underwent electrophysiology study with defibrillator testing. Our hypothesis was that progressive apical fibrosis had contributed to undersensing of VF by his apical lead, and our hope was to identify the optimal location of an alternative sensing lead. A quadripolar and a duodeca catheter were placed to simultaneously record the apex and mid and high septum. During induced VF the apex exhibited marked fractionated activity with maximal amplitude of 1.5 mV with a transition to organized, higher-amplitude signal at the upper septum of

4.2 mV as measured by the catheters (Figure 3A and B). Based on these data we placed an active-fixation sense/pace lead with an 11-mm separation (BSC RELIANCE) at the mid RV septum as noted in the posteroanterior chest radiograph image (Figure 3C).

Following connection of the new sensing lead to the ICD (BSC Incepta IS-1/DF-1 DR), testing showed an R wave of 15.4 mV, impedance of 808 ohms, and pacing threshold of 1.6 volts at 0.5 msec. In DFT, he underwent successful conversion from VF to sinus rhythm with 21 J ICD shock with no undersensing. VF maximal peak-to-peak amplitude as measured by the device was 13.5 mV with markedly less fractionated activity as compared to that measured previously by the apical lead.

The patient's 47 ECGs taken over 12 years leading to the arrest showed progressive reduction of the V<sub>4</sub> R-wave amplitude and normalization of ST strain pattern (R wave –37%, ST –96% reduction; correlation of 0.59 and 0.91, respectively) (Figure 1B).

## Discussion

This case has a number of interesting implications. It is possible that progression of fibrosis in AHCM can interfere with proper function of sensing leads over time. Compared with other forms of hypertrophic cardiomyopathy, the apical variant tends to have faster progression of fibrosis in the hypertrophied areas of myocardium, as evaluated by extent of late-gadolinium enhancement on cardiac magnetic resonance imaging over time.<sup>9</sup> Our patient is unable to undergo optimal cardiac magnetic resonance imaging of his apex owing to the presence of the ICD lead interfering with the image acquisition, though we suspect that progression of apical scarring and fibrosis occurred, as evidenced by his progressive ECG changes. High QRS amplitude and giant negative T waves in precordial leads, particularly V<sub>4</sub>, are commonly seen in AHCM.<sup>9</sup> The dynamic changes in the patient's ECG morphology likely represents composite tissue remodeling, which caused rapid disorganization during VF, low amplitude, and device undersensing. Interestingly, though this affected detection of electrical activity during VF, R-wave amplitude and sensing was normal during sinus rhythm, as measured by his device.

## Conclusion

In an era where DFT is not consistently done, this case supports consideration of routine DFT in patients with hypertrophic cardiomyopathy. In our patient, although the R wave was consistently measured to be adequate during prior testing, undersensing caused device failure. An early sign of impending failure may have been present during his follow-up DFT at the time of generator change in 2010, when initial DFT failed and adjustment in device sensitivity was required. Additionally, the dynamic changes in his ECG as detailed above may have been another sign of the anatomic changes. It is possible that these ECG changes in patients with AHCM will provide a



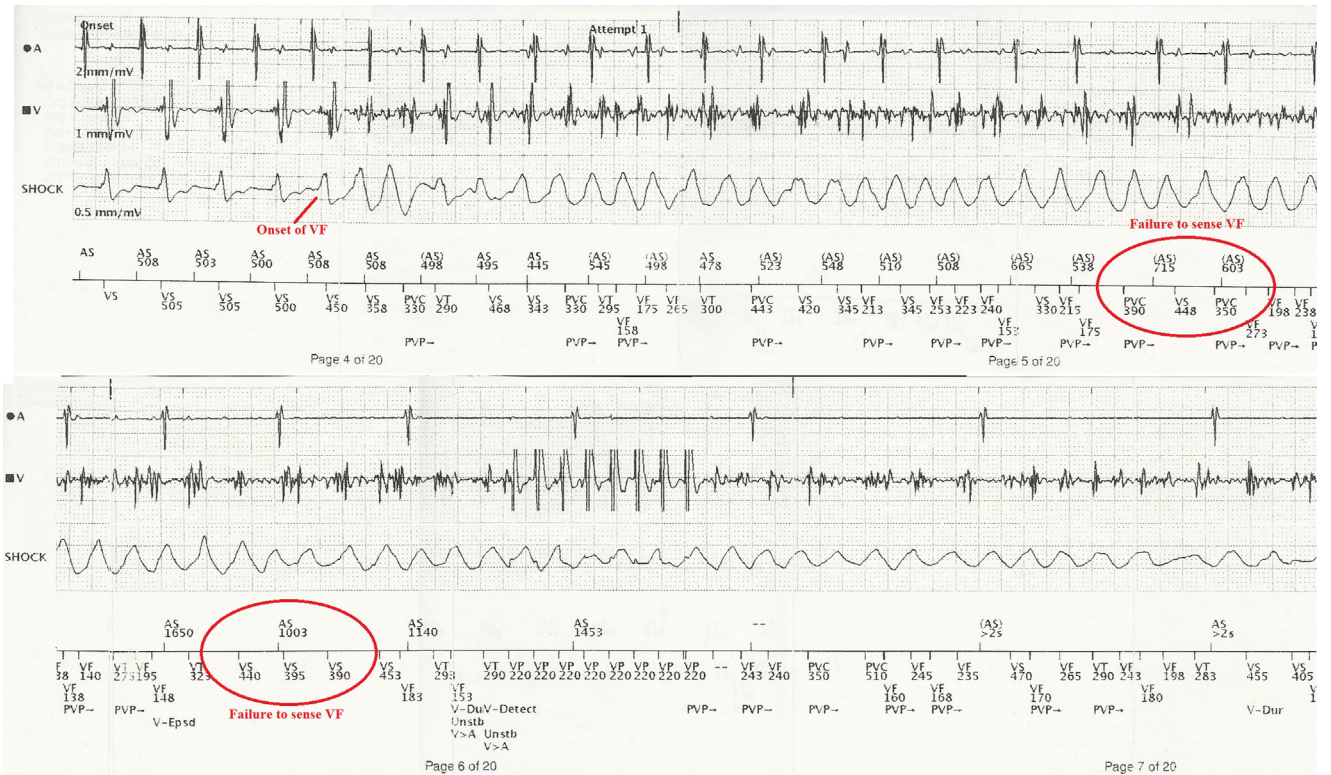
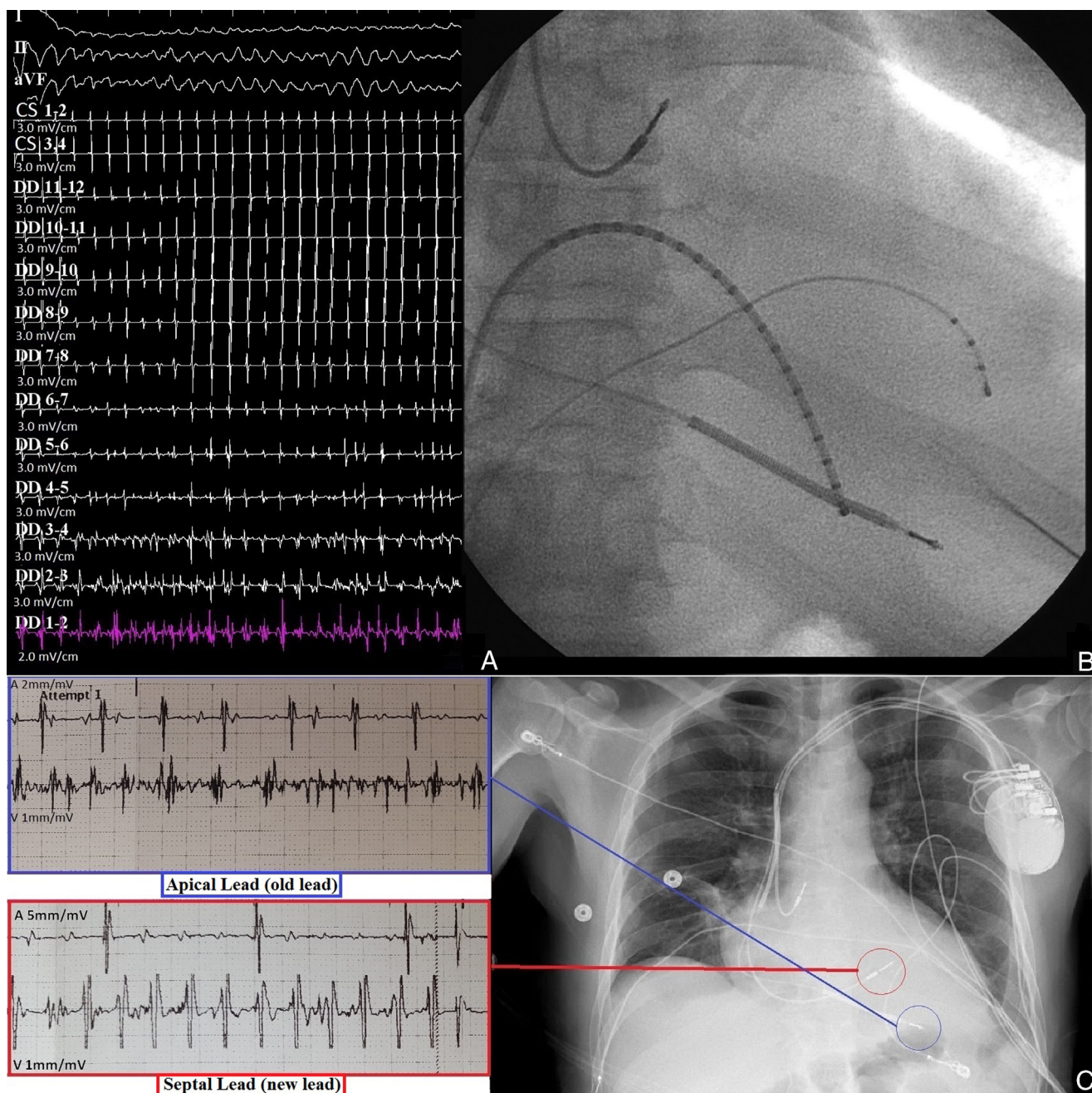


Figure 2 Electrogram as recorded by the device at the onset of ventricular fibrillation (VF) demonstrates failure to sense VF.



**Figure 3** A: Electrograms prior to placing the right ventricular (RV) septal lead. B: Catheter placement is shown with a 20-pole mapping catheter in the right ventricle that has been advanced as distally as possible to approximate sensing at the apical lead and a 4-pole mapping catheter to approximate the high septal activity. The apical activity (DD1–2) is fractionated, low-amplitude signal during ventricular fibrillation (VF). However, the same activity is discrete and high-amplitude at the basilar RV septum. C: New RV septal lead with associated electrogram during induced VF with cleaner signal (red) as compared to the old lead (blue), also with activity during VF.

cardiomyopathy as well. Follow-up DFT testing should be considered in all such patients.

Despite excellent R-wave sensing during sinus rhythm, the amplitude in VF rapidly deteriorated and became fractionated, resulting in undersensing. The assumption that high-voltage ventricular sensing in sinus will imply reliable sensing in VF is not appropriate with this anatomy. Clearly, more data would be useful in defining optimal device treatment for patients with AHCM.

### References

1. Zipes D, Camm A, Borggreffe M, Buxton A, Chairman B, Fromer M, Gregoratos G, Klein G, Moss A, Myerburg R, Priori S, Quinones M. ACC/AHA/ESC 2006 guidelines for management of patients with ventricular arrhythmias and the prevention of sudden cardiac death: a report of the American College of Cardiology/American Heart Association Task Force and the European Society of Cardiology Committee for Practice Guidelines (Writing Committee to Develop Guidelines for Management of Patients With Ventricular Arrhythmias and the Prevention of Sudden Cardiac Death). *J Am Coll Cardiol* 2006;48:e247.
2. Yusuf S, Bathina J, Banchs J, Mouhayar E, Daher I. Apical hypertrophic cardiomyopathy. *World J Cardiol* 2011;3:256–259.

3. Eriksson MJ, Sonnenberg B, Woo A, Rakowski P, Parker TG, Wigle ED, Rakowski H. Long-term outcome in patients with apical hypertrophic cardiomyopathy. *J Am Coll Cardiol* 2002;39:638–645.
4. Klarich KW, Attenhofer Jost CH, Binder J, Connolly HM, Scott CH, Freeman WK, Ackerman MJ, Nishimura RA, Tajik AJ, Ommen SR. Risk of death in long-term follow-up of patients with apical hypertrophic cardiomyopathy. *Am J Cardiol* 2013;111:1784–1791.
5. Ridjab D, Koch M, Zabel M, Schultheiss HP, Morguet AJ. Cardiac arrest and ventricular tachycardia in Japanese-type apical hypertrophic cardiomyopathy. *Cardiology* 2007;107:81–86.
6. Okishige K, Sasano T, Yano K, Azegami K, Suzuki K, Itoh K. Serious arrhythmias in patients with apical hypertrophic cardiomyopathy. *Intern Med* 2001;40:396–402.
7. Chung T, Yiannikas J, Freedman SB, Kritharides L. Unusual features of apical hypertrophic cardiomyopathy. *Am J Cardiol* 2010;105:879–883.
8. Webb J, Sasson Z, Rakowski H, Liu P, Wigle ED. Apical hypertrophic cardiomyopathy: clinical follow-up and diagnostic correlates. *J Am Coll Cardiol* 1990;15:83–90.
9. Todiere G, Aquaro GD, Piaggi P, Formisano F, Barison A, Masci PG, Strata E, Bacigalup L, Marzilli M, Pingitore A, Lombardi M. Progression of myocardial fibrosis assessed with cardiac magnetic resonance in hypertrophic cardiomyopathy. *Am J Cardiol* 2012;60:922–930.