

Expression of p53 protein and ki-67 antigen in oral premalignant lesions and oral squamous cell carcinomas: An immunohistochemical study

Departments of Oral and Maxillofacial Surgery, Maitri College of Dentistry and Research Centre, Durg, India

S. Humayun, V. Ram Prasad

ABSTRACT

Aim: To study expression of p53 protein and ki-67 antigen in normal, non-dysplastic, dysplastic, premalignant and malignant lesions of the oral mucosa. **Materials and Methods:** The standard immunohistochemical method along with MIB-1 and DO-7; DAKO antibodies was used to study the expression of p53 and ki-67 in paraffin-embedded tissue specimens. **Results:** All samples studied showed positive staining for p53 and ki-67. Only one case each from leukoplakia and oral squamous cell carcinoma (OSCC) groups showed negative staining for ki-67. The staining was confined to basal layer in most of the cases except OSCC in which it was seen in all layers. The intensity of staining was moderate to intense. The percentage of p53-positive cells in normal mucosa was 15-25% which was increased to 95% in malignant mucosa. Statistical analysis revealed that the expression of p53 and ki-67 increases as normal oral mucosa becomes dysplastic and undergoes malignant transformation. **Conclusion:** These results emphasize the potential use of p53 protein and ki-67 antigen as markers of malignant transformation and carcinogenesis in oral premalignant lesions, conditions and OSCC, respectively; and in future they may serve as prognostic tools in the early detection of malignant transformation in oral premalignant lesions and conditions.

Key words: Immunohistochemistry, ki-67 antigen, oral leukoplakia, oral submucous fibrosis, p53 protein

Address for correspondence:

Dr. S. Humayun,
H.No.10-2-283/A/2, 1st Floor,
Near Shantinagar Police Quarters,
Vijayanagar Colony,
Hyderabad- 500057, Andhra
Pradesh, India
E-mail: drshumayun@yahoo.com

INTRODUCTION

Oral cancer is the most common cancer and constitutes a major health problem in developing countries, representing the leading cause of death. Although representing 2–4% of the malignancies in the West, this carcinoma accounts for almost 40% of all cancers

in the Indian subcontinent.^[1] A key factor in the lack of improvement in prognosis over the years is the fact that a significant proportion of oral squamous cell carcinoma (OSCC) are not diagnosed or treated until they reach an advanced stage. The prognosis for patients with OSCC that is treated early is much better, with 5-year survival rates as high as 80%.^[1] In addition; the quality of life also improves after early treatment.

A significant proportion of OSCC develop from premalignant lesions such as leukoplakia and oral submucous fibrosis (OSMF). Histological examination of tissue remains the gold standard for diagnosis and identification of malignant oral lesions. Molecular level changes in the lesion occur before clinical and

Access this article online	
Quick Response Code: 	Website: www.njms.in
	DOI: 10.4103/0975-5950.85852

histopathological changes.^[1] Identification of high-risk oral premalignant lesions and intervention at premalignant stages could constitute one of the keys in reducing the mortality, morbidity and cost of treatment associated with OSCC.

Leukoplakia is a common lesion of the oral mucosa, which is defined as a white patch or plaque that cannot be characterized clinically or pathologically as any other disease. The percentage of leukoplakias that progress to invasive SCC is accepted to be directly related to the severity of the dysplastic changes and it ranges from 5 to 43%.^[2]

OSMF is a high-risk precancerous condition characterized by changes in the connective tissue fibers of the lamina propria and deeper parts leading to stiffness of the mucosa and restricted mouth opening. OSMF has been reported almost exclusively among Indians and Asians. Malignant transformation rates as high as 7.6% over a 10-year period have been reported.^[3]

The etiology of premalignant lesions is generally accepted to be multifactorial, with tobacco and alcohol being reported as important cofactors in transition from premalignancy to malignancy. Consumption of tobacco and betel quid (*betel leaf-coated with slaked lime and wrapped around areca nut plus some spicy ingredients*) can cause genetic and molecular alterations in clinically distinct oral premalignant lesions and conditions.^[3]

Molecular biological markers have been suggested to be of value in the diagnosis and prognostic evaluation of precancerous lesions. Markers of proliferation, epithelial differentiation and genomic markers could potentially be good candidates for improving the prognostic evaluation of precursors of oral cancer. As yet, one or panel of molecular markers has not been determined that allows for a prognostic prediction of oral precancer. However, these new markers could be considered complementary to conventional prognostic evaluation.^[4]

P53 protein

P53 is the name of the tumor suppressor gene located on short arm (p) of chromosome 17, as well as the protein encoded by this gene (*TP53*). The p53 protein consists of 393 amino acids and comprises four regions with different functions.^[5]

The normal p53 protein (called wild type) has a very short half life therefore can be hard to detect in normal tissues. However, the protein can remain in the tissues longer due to mutations, or a defect in the degradation pathway or by binding to other proteins.^[5] The physiological function of p53 protein is that of

preventing accumulation of genetic damage in cells either by allowing for repair of the damage before cell division or by causing death of the cell. The mutant p53 protein is normally not active, thus leading to the loss of the tumor suppressor function of the protein.^[4] The most common p53 alteration is a point mutation confined primarily to exons 5 to 8. The alterations of p53 impair the ability of the cells to repair and undergo apoptosis in response to DNA damage which will lead to uncontrolled cell growth.^[6]

Ki-67 antigen

Ki-67 is a cell cycle associated human nuclear protein present in peri-chromosomal region, the expression of which strictly associated with cell proliferation and which is widely used in pathology as a *proliferation marker* to measure the growth fraction of cells in human tumors.^[7]

The estimated half life of ki-67 antigen is 60-90 minutes. The ki-67 antigen starts to be expressed in the S phase, progressively increasing through S and G2 phases and reaching a plateau at mitosis. After cell division, the cells return to G1 with a stock of ki-67 antigen, whose level decreases rapidly during this phase.^[2,8]

The purpose of this study was to investigate the expression of p53 protein and ki-67 antigen in normal oral mucosa, OSMF, oral leukoplakia with or without dysplasia and OSCC using immunohistochemistry, and to clarify the correlation of the expression of these cell cycle regulatory proteins and clinico-pathological factors.

MATERIALS AND METHODS

Sample collection and preparation

The samples were collected from 14 cases reported to the Department of Oral and Maxillofacial Surgery, Government Dental College and Hospital, Hyderabad, which consisted of four patients with OSCC, four patients with oral leukoplakia, four patients with OSMF and two patients with normal oral mucosa as controls.

Demographic details were recorded for all patients and included age, sex and personal history about alcohol consumption, tobacco chewing or smoking and other chewing habits. The age of the patients ranged from 18 to 75 years (mean age, 40.5 years). Among all 14 patients, 13 were male and only 1 was female. Tobacco or betel quid or both chewing habits were present in all patients except one case with leukoplakia. Normal controls were selected based on no history of alcohol, tobacco or betel quid use.

Both premalignant lesions and conditions were selected based on the absence of any invasive OSCC. All patients were healthy with no systemic disease except two cases (one had renal calculi and the other had systemic hypertension). The patients with disseminated disease, loco-regional recurrence, other serious illness, or with poor general condition were not included in the present study. All patients were from medium socioeconomic group except three cases of oral cancer who belonged to low socioeconomic group. A detailed clinical, radiological and histopathological data for each patient was also recorded.

All the 14 patients were subjected to incisional biopsy and the soft tissue specimens were routinely fixed in 10% formalin (24-48 hours) and processed in the laboratory, in Pathology Department, Krishna Institute of Medical Sciences, Secunderabad. For all cases the clinical diagnosis was confirmed histopathologically after hematoxylin and eosin staining of archival specimens.

OSCC specimens were histologically graded as well differentiated (four cases), moderately differentiated, and poorly differentiated SCCs according to the differentiation of cells and the resemblance of neoplastic cells to that of epithelial cells. Excluding dysplastic features, the premalignant lesions (leukoplakia) were histologically classified into proliferative (one case) (*hyperplastic*) and non-proliferative (three cases) (*hyperkeratosis*) subtypes based on the presence of basal cell hyperplasia, proliferation and elongation of rete pegs, and thickening of entire epithelium.^[9] The premalignant condition (OSMF) cases were clinically graded as grade II (four cases) based on extent of mouth opening and palpable fibrous bands. The normal controls were taken from buccal mucosa of age-matched healthy individuals without any deleterious chewing habit.

Tissues showing dysplastic features limited to basal and supra basal layers were graded as mild dysplasia (four cases), involving basal layer till the mid portion of the spinous layer as moderate dysplasia and alterations from basal layer to a level above the mid-portion of the spinous layer as severe dysplasia.^[10]

Immunohistochemistry

1. The tissue sections were cut to 3-4 μ thickness on APES (3-amino propyl triethoxy silane) coated slides and the slides were marked.
2. The slides were left in hot air oven at 65°C for 30 minutes and later dipped and deparaffinized in xylene for 10 minutes (three changes).
3. Then slides were rehydrated through graded alcohols (two changes) and running tap water.
4. The slides were not allowed to dry at any point.
5. Antigen retrieval was performed by placing the slides

in citrate buffer at 95°C for 5 minutes (4-5 times).

6. Then the slides were cooled to room temperature and next steps of staining were performed in a humid chamber.
7. After washing the slides with wash buffer (PBS, phosphate buffer solution), peroxide block (0.3% hydrogen peroxide in methanol) was applied for 10 minutes.
8. Then power block (supplied by the manufacturer) is applied for 10 minutes and primary antibody [monoclonal mouse anti ki-67 antibody (MIB-1) for ki-67 and antihuman p53 protein (DO-7; DAKO) for p53] was added and incubated for 10-30 minutes.
9. Again the slides were washed and super enhancer (secondary antibody) was applied for 30 minutes.
10. Then poly HRP (horse radish peroxidase enzyme polymer) reagent was applied for 30 minutes and the slides were washed in wash buffer for 5 minutes (two times).
11. Di-acetyl bromo acetic acid (DAB) was added to the slide for 3-4 minutes and washed with buffer.
12. The slides were dipped in Mayor's hematoxylin for less than a minute and washed in running tap water.
13. Finally the slides were dehydrated in ascending grades of alcohol and then to xylene and mounted with diphenylene phthalate xylene.

Evaluation of staining

The intensity of immunohistochemical staining was graded based on subjective evaluation of color exhibited (brown color) by antigen, antibody and chromogen complex as: negative (-, no color), mild (+, light brown color), moderate (++, dark brown color) or intense (+++, very dark brown color). The distribution of staining was graded as confined only to basal layer, both basal and supra basal layers, and all layers of the epithelium. Only nuclear staining of epithelial cells was observed, and the nuclei with clear brown color, regardless of staining intensity, were regarded as positive. The pattern of expression was also analyzed semi quantitatively by counting the number of positive cells per 100 basal or parabasal cells and was recorded as percentage. The percentage of positive cells was scored as: 0 = 0-5%; 2 = 6-25%; 4 = 26-60%; 6 = 61-99%. The area with maximum number of positive cells was considered in each section.^[9] Known positive immunostaining slides were used as positive controls.

All the samples histopathologically and immunohistochemically studied were categorized into four groups such as normal oral mucosa (normal control) group, OSMF group, oral leukoplakia group and OSCC group. The parameters used to analyze the expression of both p53 protein and ki-67 antigen are: 1) pattern or distribution of expression in the epithelial layers; 2) intensity of staining in each slide; 3) the percentage of positive cells or labeling index (LI).

Statistical analysis

The percentage of positive cells or the LI for each slide in each group was calculated by dividing the number of positive cells by the total number of cells counted in the slide.

Mean LI and standard deviation was calculated for all groups using descriptive analysis. As the scores were not continuous variables, statistical analysis was done using non-parametric methods.

The Kruskal Wallis one-way ANOVA test was done to find out if there is any significant difference of mean LI between the groups for each antibody. In addition to one way ANOVA, pair wise comparison of LI of p53 between the groups were made using Mann-Whitney *U* test.

LIs of p53 and ki-67 for all groups were compared to find out relationship if any by using Spearman rank correlation test. χ^2 test was used to find out if there is any association between pattern or distribution, LI and intensity of staining for each antibody between the groups. *P*-value was considered significant where it was less than 0.05.

RESULTS

The results of immunohistochemical analysis of p53 and ki-67 expression are summarized in Table 1. The expression of each protein in each group is analyzed and interpreted as follows:

P-53

Normal oral mucosa

Staining was nuclear and was confined to the basal layer of cells [Figure 1]. The intensity of staining was moderate and intense in 2 cases respectively. The mean

LI was 20 with a standard deviation of 5.77.

Oral submucous fibrosis

All OSMF cases showed only basal layer expression and intense (+++) nuclear staining was seen in all cases except one which has moderate intensity (++) [Figure 2]. The LI of this group ranges from 80 to 95%. The mean LI was 90 with a standard deviation of 7.07 and this is very high than normal control group (20 ± 5.77).

Oral leukoplakia

Staining was nuclear and all leukoplakia cases had mild dysplastic features with only basal layer expression of p53 except one slide which has supra basal expression [Figure 3]. All the slides were stained moderately (++) except the proliferative type which was stained intense (+++). The LI ranges from 55 to 95%. The mean LI was 75 with a standard deviation of 16.83 [Table 2].

OSCC

All cases showed staining in all layers of epithelium [Figure 4]. The intensity ranged from moderate (++) to intense (+++). Two cases were stained moderate and the other two stained intense. The LI ranged from 40 to 95%. The mean LI was 66.25 with a standard deviation of 25.62 [Table 2]. The mean LIs of pathological groups were very high than the normal control group [Table 2].

Table 2: Comparison of four groups with respect to labeling index of p53 by Kruskal Wallis one-way ANOVA test

Summary	Normal mucosa	OSF	LKP	OSCC
Means	20.00	90.00	75.00	66.25
Std.Dev. (SD)	5.77	7.07	16.83	25.62
Kruskal wallis test	10.1374			
<i>P</i> -value	0.0175*			

*Significant at 5% level of significance (*P*<0.05): OSF = Oral submucous fibrosis, LKP = Leukoplakia, OSCC = Oral squamous cell carcinoma

Table 1: IHC staining details of p53 and ki-67 in all groups

Case	Group	Age / Sex	Personal habits	P 53			KI-67		
				Pattern of expression	Intensity of staining	Percent-age of positive cells (LI)	Pattern of expression	Intensity of staining	Percent-age of positive cells (LI)
1	Normal control	25/M	No	Basal	Moderate	25	Basal	Intense	50
2	Normal control	32/M	No	Basal	Intense	15	Basal	Intense	10
3	OSF	41/M	BQ + G + A	Basal	Intense	90	Basal	Intense	15
4	OSF	28/M	BQ + S	Basal	Intense	95	Basal	Intense	80
5	OSF	23/M	G + T + A	Basal	Moderate	80	Basal	Intense	95
6	OSF	31/M	G + A + S	Basal	Intense	95	Basal	Intense	25
7	LKP	46/M	No	Basal and Supra basal	Moderate	80	Basal	Mild	3
8	LKP	45/M	BQ + S	Basal	Intense	95	Basal	Intense	95
9	LKP	25/M	BQ	Basal	Moderate	70	Negative	Negative	Nil
10	LKP	18/M	BQ + G	Basal	Moderate	55	Basal	Moderate	45
11	OSCC	58/M	BQ + A	All layers	Moderate	40	Negative	Negative	Nil
12	OSCC	60/F	BQ + G	All layers	Moderate	50	Basal and supra basal	Intense	20
13	OSCC	60/M	G + A	All layers	Intense	80	All layers	Intense	30
14	OSCC	75/M	BQ + S	All layers	Intense	95	All layers	Intense	50

BQ: betel quid chewing; G: gutkha chewing; A: alcohol consumption; T: tobacco chewing and S: smoking habit

The Kruskal Wallis one-way ANOVA test showed that there was a significant difference of mean LI (P -value 0.0175) between the groups (normal, OSF, leukoplakia and OSCC) [Table 2].

Mann-Whitney U test showed a significant mean LI difference (P -value 0.02) when normal mucosa group compared with other groups, but no significant mean LI difference was observed when OSMF, leukoplakia and OSCC groups compared with each other (P -value 0.19 and 0.56) [Table 3].

χ^2 test showed significant staining pattern relationship (P -value 0.0043) and LI relationship (P -value 0.0033) between the four groups, but no significant relationship was found in the staining intensity among all groups (P -value 0.57) [Table 4-6].

KI-67

All samples showed positive staining with variable number of positive cells except two cases, one each from leukoplakia and OSCC groups.

Normal oral mucosa

Staining was intense and was seen only in the basal layer of cells [Figure 5]. The mean LI for this group was 30 with a standard deviation of 23.09 [Table 7].

Oral submucous fibrosis

These cases showed only basal layer expression and intense (+++) nuclear staining [Figure 6]. The LI ranges from 15 to 95%. The mean LI was 53.75 with a standard deviation of 39.66 [Table 7].

Oral leukoplakia

Only three cases showed basal expression [Table 8]. One case in this group showed negative expression for ki-67. The staining intensity ranged from mild (+) to intense (+++) and the LI ranged from 3 to 45%. The mean LI was 35.75 with a standard deviation of 44.52 [Figure 7].

OSCC

Only three cases positive staining for ki-67 antibody. One case was negative for ki-67 antibody. The staining intensity was intense (+++) in all positive cases [Table 9]. The pattern of expression was basal and suprabasal in one case and the rest of two cases exhibited positive cells in all layers [Figure 8]. The LI ranged from 20 to 50%. The mean LI was 25 with a standard deviation of 20.82.

When all the four groups were compared for mean LI (ki-67) by the Kruskal Wallis one-way ANOVA test there was no statistically significant mean difference

Table 3: Pairwise comparison of four groups with respect to labeling index of p53 by Mann-Whitney U test

Group	Mean %	U -value	Z -value	P -value
Normal mucosa	20.00	0.0000	-2.3094	0.0209*
OSF	90.00			
Normal mucosa	20.00	0.0000	-2.3094	0.0209*
LKP	75.00			
Normal mucosa	20.00	0.0000	-2.3094	0.0209*
OSCC	66.25			
OSF	90.00	3.5000	-1.2990	0.1939
LKP	75.00			
OSF	90.00	3.5000	-1.2990	0.1939
OSCC	66.25			
LKP	75.00	6.0000	-0.5774	0.5637
OSCC	66.25			

*Significant at 5% level of significance ($P < 0.05$); OSF = Oral submucous fibrosis, LKP = Leukoplakia, OSCC = Oral squamous cell carcinoma

Table 4: Comparison of four groups with respect to labeling index of ki-67 by Kruskal Wallis one-way ANOVA test

Summary	Normal mucosa	OSF	LKP	OSCC
Means	30.00	53.75	35.75	25.00
Std.Dev. (SD)	23.09	39.66	44.52	20.82
Kruskal wallis test	1.4208			
P -value	0.7007			

OSF = Oral submucous fibrosis, LKP = Leukoplakia, OSCC = Oral squamous cell carcinoma

Table 5: Distribution of cases according to groups and pattern of staining for p53 antibody

Staining	Normal mucosa	OSF	LKP	OSCC	Total
Basal only	2	4	3	0	9
Basal and para basal	0	0	1	0	1
All layers	0	0	0	4	4
Total	2	4	4	4	14

$\chi^2 = 18.9090, P = 0.0043, *$

*Significant at 5% level of significance ($P < 0.05$); OSF = Oral submucous fibrosis, LKP = Leukoplakia, OSCC = Oral squamous cell carcinoma

Table 6: Distribution of cases according to groups and intensity of staining (p53)

Intensity	Normal mucosa	OSF	LKP	OSCC	Total
Mild	0	0	0	0	0
Moderate	1	1	3	2	7
Intense	1	3	1	2	7
Total	2	4	4	4	14

$\chi^2 = 2.0000, P = 0.5724, NS$

OSF = Oral submucous fibrosis, LKP = Leukoplakia, OSCC = Oral squamous cell carcinoma

Table 7: Distribution of cases according to groups and labeling index of p53

Staining	Normal mucosa	OSF	LKP	OSCC	Total
6-25%	2	0	0	0	2
26-60%	0	0	1	2	3
61-99%	0	4	3	2	9
Total	2	4	4	4	14

$\chi^2 = 19.5560, df = 6, P = 0.0033, *$

*Significant at 5% level of significance ($P < 0.05$); OSF = Oral submucous fibrosis, LKP = Leukoplakia, OSCC = Oral squamous cell carcinoma

(P -value 0.70) between the groups (normal, OSF, leukoplakia and OSCC).

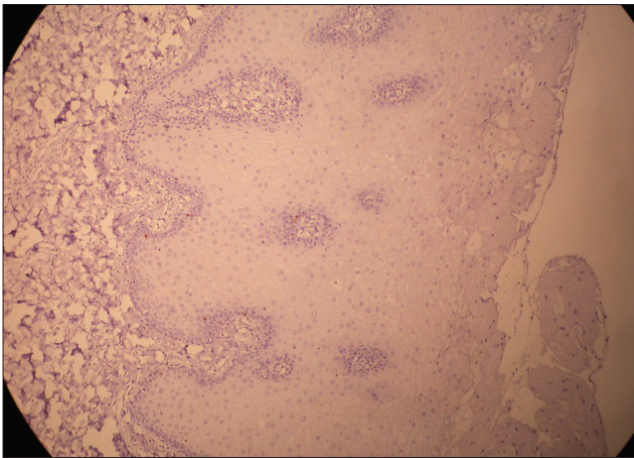


Figure 1: Immunohistochemical expression of p53 in normal oral mucosa

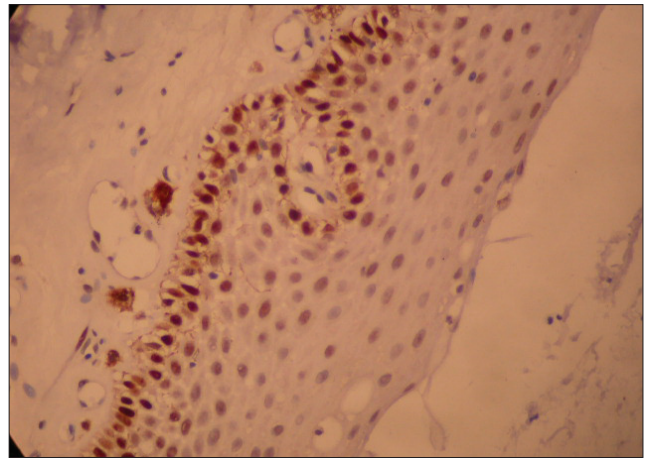


Figure 2: Immunohistochemical expression of p53 in oral submucous fibrosis

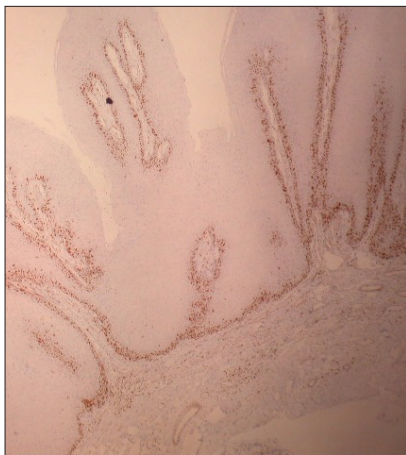


Figure 3: Immunohistochemical expression of p53 in oral leukoplakia

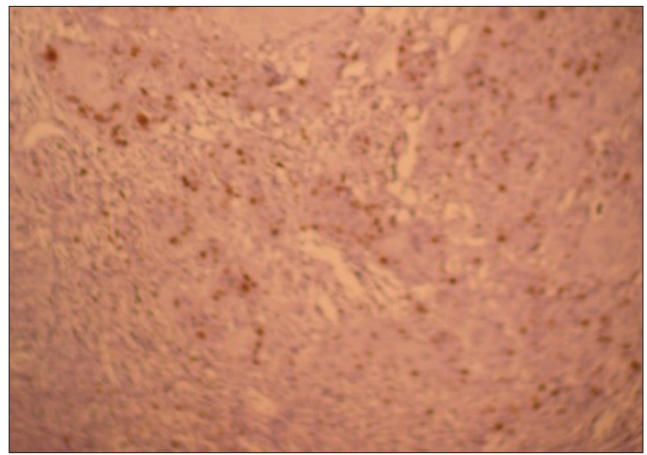


Figure 4: Pattern of expression of p53 in oral squamous cell carcinoma

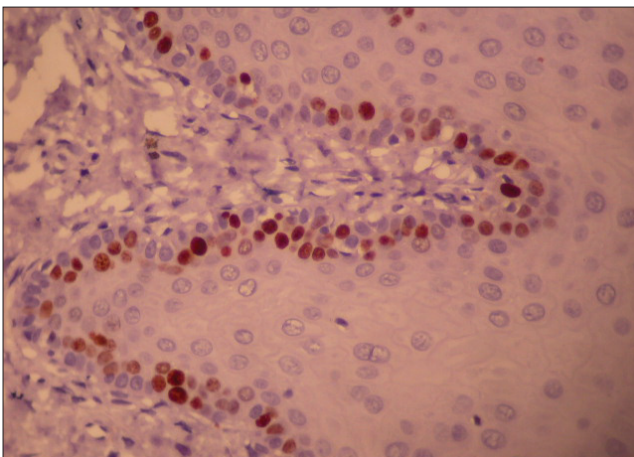


Figure 5: Immunohistochemical expression of ki-67 in normal oral mucosa

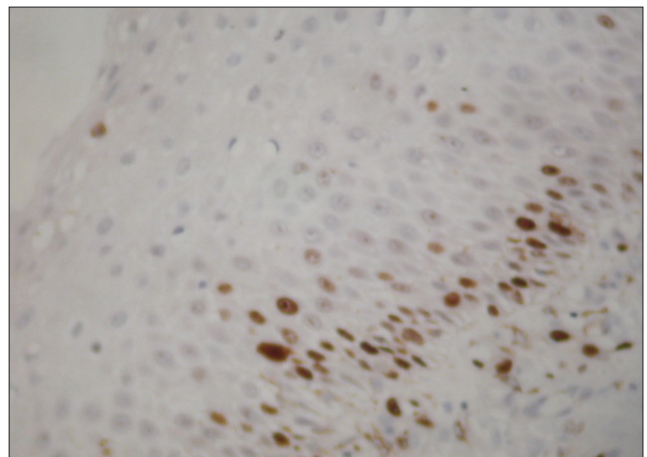


Figure 6: Immunohistochemical expression of ki-67 in oral submucous fibrosis

χ^2 test showed significant staining pattern relationship (P -value 0.04) and LI relationship (P -value 0.021) between the four groups, but no significant relationship was found in the staining intensity among all groups (P -value 0.35) [Table 8-10].

When the percentage of positive cells (LI) for p53 and ki-67 are compared between all four groups by Spearman rank correlation test positive but statistically non-significant relationship was observed [Table 11].

Table 8: Distribution of cases according to groups and pattern of staining for ki-67 antibody

Staining	Normal mucosa	OSF	LKP	OSCC	Total
Negative	0	0	1	1	2
Basal	2	4	3	0	9
Basal + Para basal	0	0	0	1	1
All layers	0	0	0	2	2
Total	2	4	4	4	14

$\chi^2 = 17.6080$ df = 9 $P = 0.04005^*$

*Significant at 5% level of significance ($P < 0.05$); OSF = Oral submucous fibrosis, LKP = Leukoplakia, OSCC = Oral squamous cell carcinoma

Table 9: Distribution of cases according to groups and intensity of staining (ki-67)

Intensity	Normal mucosa	OSF	LKP	OSCC	Total
Negative	0	0	1	1	2
Mild	0	0	1	0	1
Moderate	0	0	1	0	1
Intense	2	4	1	3	10
Total	2	4	4	4	14

$\chi^2 = 10.0001$, $P = 0.3505$, NS

OSF = Oral submucous fibrosis, LKP = Leukoplakia, OSCC = Oral squamous cell carcinoma

Table 10: Distribution of cases according to groups and labeling index of ki-67

Staining	Normal mucosa	OSF	LKP	OSCC	Total
0-5%	0	0	2	1	3
6-25%	2	2	0	1	5
26-60%	0	0	1	2	3
61-99%	0	2	1	0	3
Total	2	4	4	4	14

$\chi^2 = 19.5240$, $P = 0.0211^*$

*Significant at 5% level of significance ($P < 0.05$); OSF = Oral submucous fibrosis, LKP = Leukoplakia, OSCC = Oral squamous cell carcinoma

Table 11: Correlation between percentage of positive cells (labeling index) of p53 and ki-67

Variable	Percentage of positive cells (LI) for KI-67		
	Spearman rank correlation	t-value	p-level
Percentage of positive cells (LI) for P53	0.4121	1.6924	0.1126

DISCUSSION

Mutations in the p53 gene are the most common genetic changes observed in OSCCs. These mutations lead to uncontrolled cell proliferation, resulting in further genetic abnormalities and finally in malignancy. Therefore, the nature of the p53 gene and the proliferative status of a cell are closely linked and the loss of this linkage is one of the main causes of tumor formation and is considered to be an early event in this process. To analyze the proliferative status of a cell or tissue Ki-67 marker is reliable and widely used. It recognizes a proliferation-related nuclear antigen present at all phases of cell cycle except G_0 .^[9]

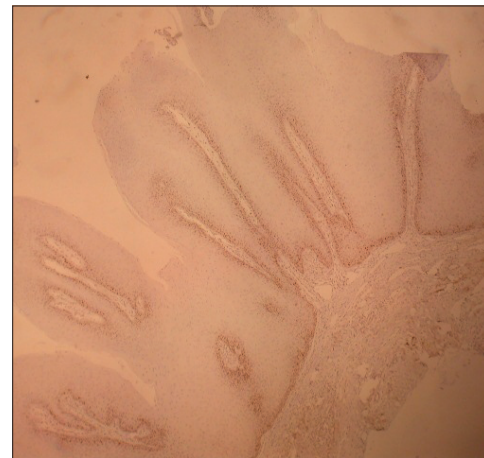

Figure 7: Immunohistochemical expression of ki-67 in oral leukoplakia

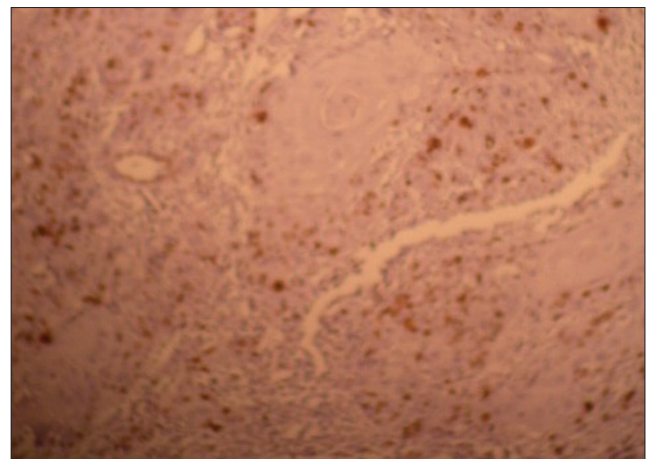


Figure 8: Pattern of expression of ki-67 in oral squamous cell carcinoma

In the present study all the normal control tissues (oral mucosa) unrelated to any deleterious chewing habit exhibited positive p53 expression at the basal layer in consistent with other studies.^[3,11,12] The possible explanation is that genotoxic stress, caused by a physical, chemical or microbiological agent that commonly acts in the oral cavity, may lead to p53 accumulation in these epithelial cells for physiological response.^[3] The other possibility for this positive expression may be defect in the degradation pathway or binding of p53 protein to other proteins such as certain DNA virus-encoded proteins.^[5]

All the samples of normal mucosa showed positive staining with ki-67 in basal layer of epithelium similar to p53; this could be due to the physiological proliferative activity in the basal cell layer. The mean LI of ki-67 (30.0 ± 23.09) is higher than p53 (20.0 ± 5.77) as one sample of normal mucosa showed high ki-67 expression which could be due to high proliferative activity in the basal layer secondary to chronic irritation or any physical stress.

In this study, males were more affected with the premalignant and malignant lesions than females because traditionally males are more likely to display oral habits such as tobacco smoking and betel quid chewing. It was found that oral premalignant lesions affected more commonly younger patients (mean age-31.5) and OSCC developed in older individuals (mean age-63.25) which was also confirmed by previous studies. Most of the cases in this study exhibited dysplastic and neoplastic lesions on buccal mucosa as the common site which is more or less related with the habit of tucking the betel quid into the buccal area while chewing. The strong relation found between the combination of betel quid chewing and smoking habit in leukoplakia and betel quid or gutkha chewing in OSMF are considered to play a critical role in the initiation, progression and immunological aspects of the development of oral premalignant lesions and conditions.

The present study revealed that the p53 expression in premalignant lesions and conditions was significantly associated with the personal habits. Increased p53-positive cells were detected in patients with both betel quid chewing and smoking habits which is in contrary to the study of Yan *et al.*,^[13] which revealed that Taiwanese patients without a betel quid chewing habit had a higher rate of p53 over expression than heavy chewers.

In OSMF cases, p53 expression although limited to basal layer, was very high when compared to normal control group which is consistent with the study of Win SS *et al.*^[3] This indicates the possibility of mutations in p53 gene in the development and progression of OSMF. The most common culprit, areca nut products have a high copper content, which suggest a copper-mediated etiopathogenic mechanism for genetic aberration found in OSMF by means of binding with p53 gene.^[3,14]

All the leukoplakia samples showed moderate p53 expression in the basal layer similar to OSMF group except one case which expressed even in supra basal layer also. Cruz IB *et al.*,^[15] in their study observed that 86% of premalignant lesions that showed p53 expression above the basal layer developed into SCC. They stated that p53 expression above the basal cell layer is an early event in oral carcinogenesis.

Huang WX *et al.*,^[16] in their study observed that there is a significant predilection for basal and supra basal staining pattern with the progression of lesion towards malignancy compared to strictly basal layer staining in the normal mucosa. The above reports and the present study suggest that the expression of p53 above the basal layer could be an early event in oral carcinogenesis and

an indicator of developing carcinoma. The results of p53 expression in oral leukoplakia of the present study are comparable with the other studies.^[15-18] Hence, the present study suggests that the expression pattern of p53 is significant in predicting the malignant transformation of oral premalignant lesions and conditions.

In the present study, 2 cases of OSMF showed high LI of ki-67 whereas the other two cases expressed low which is indicative of high and low proliferative activity in the OSMF epithelium, respectively. Among all leukoplakia cases one case of proliferative type highly expressed ki-67 marker which was correlating with clinical features.

The results of the present study in OSMF and leukoplakia groups showed positive correlation between p53 mutations and proliferative activity (ki-67 expression) of the basal layer only in two samples each from both groups but inverse relation was observed in two samples of OSMF group. Hence, it was difficult to completely analyze the relation between p53 and ki-67 expression in OSMF and leukoplakia groups and further studies may be required using large samples.

OSCC samples of this study showed moderate to high p53 expression with a mean LI of 66.25 ± 25.62 which is higher than normal mucosa (20.0 ± 5.77). When all the three pathological groups were compared with normal mucosa by Mann-Whitney *U* test a significant mean difference in p53 LI was observed which indicates increased expression of p53 as normal mucosa becomes dysplastic and undergoes malignant transformation and this is supported by other reports such as the study of Kannan *et al.*^[9] The LI of p53 expression for normal mucosa samples, leukoplakia and OSCC were comparable with the studies of Abbas *et al.*,^[19] Girod *et al.*^[20] and Kannan *et al.*^[9]

The present study observed that mutant p53 gene is a common event in the development of OSCC which is consistent with the report of Langdon JD *et al.*^[21] The previous studies on p53 expression in oral premalignant lesions and OSCC showed a range of positivity of 35-90% and this finding is also observed in the present study (40-95%). The mean LI of ki-67 expression in four samples of well differentiated OSCC of this study was low (28 ± 20.82) and this is consistent with the study of Fabricio *et al.*^[22] which revealed that immunohistochemical assessment of ki-67 showed scarce immunoreactive tumor cells (20 ± 3.2) in well-differentiated OSCC, while the samples of patients from moderately to poorly differentiated OSCC expressed high number of ki-67-positive cells i.e., 47 ± 6.3 and 60.3 ± 2.8 , respectively. Hence, the present study suggests that the ki-67 expression in OSCC is significant and useful in predicting histologic grade of differentiation and prognosis of the lesion.

In OSCC group of the present study the localization or pattern of expression of p53 and ki-67 markers was in general agreement with each other; however, the mean LI of ki-67 is less than p53, this may be because of negative expression of ki-67 in one sample or due to the selective expression of ki-67 in the late G1, S, M and G2 phases of the proliferating cells which was also observed in the study of Kuratomi *et al.*^[23]

A positive and non-significant correlation was observed between LI of p53 and ki-67 which indicates that there is increase or decrease in p53 LI with increase or decrease of ki-67 LI in oral premalignant lesions and OSCC.

In conclusion, the significant correlation between progression of oral epithelium from normal to neoplasia and increased expression of these antigens suggest that they may be useful biomarkers of malignant transformation in oral precancerous lesions and conditions and may serve as intermediate points for cancer prevention programmes. However, further immunohistochemical studies on large samples identifying p53, ki-67 and other associated proteins in premalignant lesions along with the mutational analysis are necessary to predict more specifically the development and malignant transformation of these oral lesions.

REFERENCES

- Mehrotra R, Gupta A, Singh M, Ibrahim R. Application of cytology and molecular biology in diagnosing premalignant or malignant oral lesions. *Mol Cancer* 2006;5:11.
- Liu SC, Klein-Szanto AJ. Markers of proliferation in normal and leukoplakic oral epithelia. *Oral Oncol* 2000;36:145-51.
- Win SS, Niishioka M, Myint BA, Takagi M. Assessment of p53 protein expression in leukoplakia, oral submucous fibrosis and oral lichen planus in Myanmar patients. *Oral Med Pathol* 2005;10:15-21.
- Reibel J. Prognosis of oral pre-malignant lesions: Significance of clinical, histopathological, and molecular biological characteristics. *Crit Rev Oral Biol Med* 2003;14:47-62.
- Nylander K, Dabelsteen E, Hall PA. The p53 molecule and its prognostic role in squamous cell carcinomas of the head and neck. *J Oral Pathol Med* 2000;29:413-25.
- Kuriakose MA, Sharan R. Oral cancer prevention. *Oral Maxillofac Surg Clin North Am* 2006;18:493-511.
- Schlüter C, Duchrow M, Wohlenberg C, Becker MH, Key G, Flad HD, *et al.* The cell proliferation-associated antigen of antibody Ki-67: a very large, ubiquitous nuclear protein with numerous repeated elements, representing a new kind of cell cycle-maintaining proteins. *J Cell Biol* 1993;123:513-22.
- Meer S, Galpin JS, Altini M, Coleman H, Ali H. Proliferating cell nuclear antigen and Ki67 immunoreactivity in ameloblastomas. *Oral Surg Oral Med Oral Pathol Oral Radiol Endod* 2003;95:213-21.
- Kannan S, Chandran GJ, Pillai KR, Mathew B, Sujathan K, Nalinakumary KR, *et al.* Expression of p53 in leukoplakia and squamous cell carcinoma of the oral mucosa: Correlation with expression of Ki67. *Clin Mol Pathol* 1996;49:M170-5.
- Neville BW, Douglas D, Allen CM. *Epithelial Pathology – Leukoplakia, Oral sub mucous fibrosis*. 2nd ed. Text Book of Oral and Maxillofacial Pathology 2002:343.
- Piattelli A, Rubini C, Fioroni M, Iezzi G, Santinelli A. Prevalence of p53, bcl-2, and Ki67 immunoreactivity and of apoptosis in normal oral epithelium and in premalignant and malignant lesions of the oral cavity. *J Oral Maxillofac Surg* 2002;60:532-40.
- Takeda T, Sugihara K, Hirayama Y, Hirano M, Tanuma JI, Semba I. Immunohistochemical evaluation of Ki-67, p63, CK-19 and p53 expression in oral epithelial dysplasias. *J Oral Pathol Med* 2006;35:369-75.
- Yan JJ, Tzeng CC, Jin YT. Overexpression of p53 protein in squamous cell carcinoma of buccal mucosa and tongue in Taiwan: An immunohistochemical and clinicopathological study. *J Oral Pathol Med* 1996;25:55-9.
- Hazarey VK, Erlewad DM, Mundhe KA, Ughade SN. Oral submucous fibrosis: Study of 1000 cases from central India. *J Oral Pathol Med* 2007;36:12-7.
- Cruz IB, Snijders PJ, Meijer CJ, Braakhuis BJ, Snow GB, Walboomers JM, *et al.* p53 expression above the basal cell layer in oral mucosa is an early event of malignant transformation and has predictive value for developing oral squamous cell carcinoma. *J Pathol* 1998;184:360-8.
- Huang WY, Coltrera M, Schubert M, Morton T, Truelove E. Histopathological evaluation of PCNA and p53 in oral epithelial hyperplasias and oral pre-malignant lesions. *Oral Surg Oral Med Oral Pathol Oral Radiol Endod* 1994;78:748-54.
- Mogi S, Kikegawa A, Hirano Y. The abnormal expression of p53 protein is a predictive prognostic marker in oral leukoplakia. *Asian J Oral Maxillofac Surg* 2003;15:44-50.
- Zhao J, Guo B, Ma SC, Zhou XD. [Expression of p53 and ki-67 genes in epithelial dysplasia from old oral mucosa and clinical significance]. *Sichuan Da Xue Xue Bao Yi Xue Ban* 2005;36:689-91.
- Abbas NF, Labib El-Sharkawy S, Abbas EA, Abdel Monem El-Shaer M. Immunohistochemical study of p53 and angiogenesis in benign and preneoplastic oral lesions and oral squamous cell carcinoma. *Oral Surg Oral Med Oral Pathol Oral Radiol Endod* 2007;103:385-90.
- Girod SC, Pfeiffer P, Ries J, Pape HD. Proliferative activity and loss of function of tumour suppressor genes as 'biomarkers' in diagnosis and prognosis of benign and preneoplastic oral lesions and oral squamous cell carcinoma. *Br J Oral Maxillofac Surg* 1998;36:252-60.
- Langdon JD, Patridge M. Expression of tumor suppressor gene p53 in oral cancer. *Br J Oral Maxillofac Surg* 1992;30:214-20.
- Vieira FL, Vieira BJ, Guimaraes MA, Aarestrup FM. Cellular profile of the peritumoral inflammatory infiltrate in squamous cell carcinoma of oral mucosa: Correlation with the expression of Ki-67 and histologic grading. *BMC Oral Health* 2008;8:25.
- Kuratomi K, Yano H, Tsuneoka M, Sakamoto K, Kusukawa J, Kojiro M. Immunohistochemical expression of p53 and Ki67 proteins in human primary gingival squamous cell carcinoma. *Kurume Med J* 2006;53:71-8.

How to cite this article: Humayun S, Prasad VR. Expression of p53 protein and ki-67 antigen in oral premalignant lesions and oral squamous cell carcinomas: An immunohistochemical study. *Natl J Maxillofac Surg* 2011;2:38-46.

Source of Support: Nil. **Conflict of Interest:** None declared.