

Original Article

Characteristic Height Growth Pattern in Patients with Pseudohypoparathyroidism: Comparison between Type 1a and Type 1b

Kaori Kinoshita¹, Masanori Minagawa^{1, 2}, Michiko Anzai¹, Yumiko Sato¹, Itsuro Kazukawa¹,
Kyoko Shimohashi^{1, 3}, Setsuo Ota³ and Yoichi Kohno^{1, 2}

¹Department of Pediatrics, ²Environmental Health Science Project for Future Generations, Graduate School of Medicine, Chiba University, Chiba, Japan

³Department of Pediatrics, Teikyo University Chiba Medical Center, Ichihara, Japan

Abstract. Pseudohypoparathyroidism (PHP) is a metabolic disorder characterized by organ resistance to the action of parathyroid hormone. PHP type 1 is subclassified into two apparent disorders, type 1a (PHP1a) and type 1b (PHP1b). Patients with PHP1a show Albright hereditary osteodystrophy including short stature. Patients with PHP1b have no such skeletal defects, however, literature regarding the growth of PHP1b is not currently available. We evaluated growth charts of PHP patients, including four PHP1a patients and six PHP1b patients. Growth patterns were different between PHP type 1a and 1b. Adult height was abnormally low in all PHP1a patients. The growth pattern of PHP1a was characterized by mild growth impairment in the prepubertal period, a blunted growth spurt and premature cessation of the growth spurt. The adult height of male PHP1b was slightly lower than average. An early growth spurt was observed only in male patients with PHP1b and it may reduce the adult height of male patients with PHP1b. This warrants further investigation into the growth and pubertal development of PHP1b patients.

Key words: growth, height, pseudohypoparathyroidism, puberty

Pseudohypoparathyroidism (PHP) is a metabolic disorder characterized by organ resistance to the action of PTH (1). Patients with PHP type 1 lack cAMP response to PTH and can be subclassified into two apparently distinct disorders based on the presence and absence of several important clinical characteristics.

Patients with PHP type 1a (PHP1a) show a somatic phenotype termed Albright's hereditary osteodystrophy (AHO), characterized by a round face, short stocky physique, brachydactyly, subcutaneous ossification, and mental retardation. Patients with PHP type 1b (PHP1b) don't have such skeletal and developmental defects, and recent reports suggest that the loss of a maternal allele specific to CpG methylation in the transcriptional regulatory region of the *GNAS1* gene may cause tissue-specific decrease in the G α protein (2).

Short stature is one of the features of PHP1a.

Received: January 5, 2006

Accepted: October 31, 2006

Correspondence: Dr. Masanori Minagawa, Department of Pediatrics, Graduate School of Medicine, Chiba University, 1-8-1 Inohana, Chuo-ku, Chiba 260-8670, Japan

E-mail: minagawa@faculty.chiba-u.jp

In PHP1a patients, early puberty and advanced bone maturation cause a blunted growth spurt and result in short stature (3).

Hormone resistance in PHP1b has been considered to limit PTH (1), however, recent studies have provided evidence of a predominantly maternal origin of the $Gs\alpha$ transcripts in endocrinal organs, such as the thyroid, gonad and pituitary (4, 5). The $Gs\alpha$ protein level may be decreased in the pituitary gland of the patients with PHP1b. The growth of PHP1b is considered to be normal, however, no literature describing the growth of PHP1b is currently available. In this study, we analyzed the growth record of PHP cases and compared the growth patterns of PHP1a and PHP1b.

Subjects and Methods

Thirteen patients with PHP type 1 visited the Department of Pediatrics at Chiba University Hospital between 1995 and 2004. The diagnosis of PHP was based on the following criteria: (1) the presence of hypocalcemia (serum calcium less than 8.5 mg/dl) with elevated serum PTH levels (above twice the upper normal limit); (2) normal renal function (normal levels of serum urea nitrogen and creatinine); (3) lack of urinary cAMP response to exogenous PTH infusion (less than 10-fold increase). All patients were treated with vitamin D. Four cases with PHP1a (2 males and 2 females) and six cases with PHP1b (3 males and 3 females) who reached adult height were enrolled in this study (Table 1), and three patients who didn't reach adult height (growth velocity <2 cm per 12 mo at the time of this study) were excluded. The diagnosis of PHP1a was based on the presence of either brachydactyly or heterotopic ossification in the soft tissue. The diagnosis of PHP1b was based on the absence of these features of AHO. All cases with PHP1b were sporadic. The clinical diagnosis of PHP1b was confirmed by the methylation-specific Southern blot analysis,

according to previously described methods (2) (data not shown). All cases with PHP1a had subclinical hypothyroidism and received levothyroxine supplementation to maintain normal TSH levels. We observed poor GH response in provocative tests in Cases 1, 9 and 10 in this study. No patient received growth hormone treatment. Cases 1 and 4 were siblings and their mother had pseudopseudohypoparathyroidism (PPHP). The growth records were studied retrospectively.

Results

Table 1 shows the height and height SD score (SDS) of PHP cases at the age of diagnosis and in adulthood. The adult heights of all PHP1a cases were less than -2.0 SD and those of all PHP1b cases were within the normal range (> -2.0 SD). Although the adult heights of female cases with PHP1b were completely normal, (ranging between -0.21 and $+0.08$ SD), those of male cases with PHP1b were relatively low, (ranging between -0.74 and -1.74 SD). In PHP1a cases the adult height SDS was obviously lower than the height SDS at diagnosis, and similar trends were observed in PHP1b cases.

Figure 1 shows the growth charts of male PHP1a cases. Early growth cessation resulted in abnormally reduced adult height. Although Case 2 lacks informative data for prepubertal growth, Case 1 had mild growth reduction in the prepubertal period. Figure 2 shows the growth charts of female PHP1a cases. Reduced growth velocity in childhood and a blunted growth spurt caused abnormally reduced adult height. Taking these findings together, at least three out of four cases with PHP1a showed progressive deviation from the standard curve because of the reduction in growth velocity in childhood. Figure 3 shows the growth charts of male PHP1b cases. Prepubertal growth showed a normal pattern, however, a relatively early growth spurt was observed in Cases 6 and 7 and resulted in mildly

Table 1 The heights of the cases with PHP at diagnosis and in adulthood

| Case | Diagnosis | Sex | Diagnosis | | | Adult | | |
|------|-----------|--------|------------|--------|------------|-------------|--------|------------|
| | | | Age | Height | Height SDS | Age | Height | Height SDS |
| 1 | PHP1a | Male | 5 yr 10 mo | 108.8 | -0.72 | 26 yr 3 mo | 155.7 | -2.6 |
| 2 | PHP1a | Male | 8 yr 4 mo | NA* | NA* | 22 yr 4 mo | 157.7 | -2.26 |
| 3 | PHP1a | Female | 3 yr 7 mo | 96.3 | +0.03 | 25 yr 5 mo | 143.0 | -2.85 |
| 4 | PHP1a | Female | 10 yr 3 mo | 126.0 | -2.10 | 33 yr 0 mo | 144.4 | -2.58 |
| 5 | PHP1b | Male | 14 yr 2 mo | 163.3 | -0.06 | 28 yr 0 mo | 166.5 | -0.74 |
| 6 | PHP1b | Male | 6 yr 5 mo | 113.0 | -0.63 | 19 yr 3 mo | 160.7 | -1.74 |
| 7 | PHP1b | Male | 4 yr 7 mo | 106.2 | +0.52 | 21 yr 5 mo | 163.3 | -1.29 |
| 8 | PHP1b | Female | 10 yr 0 mo | 136.5 | -0.06 | 35 yr 11 mo | 157.0 | -0.21 |
| 9 | PHP1b | Female | 6 yr 9 mo | 119.3 | +0.40 | 27 yr 6 mo | 158.5 | +0.08 |
| 10 | PHP1b | Female | 8 yr 9 mo | 131.6 | +0.28 | 18 yr 8 mo | 157.8 | -0.06 |

*The height at age 11 yr 11 mo was 146.2 cm (height SDS: -0.31). NA, not applicable.

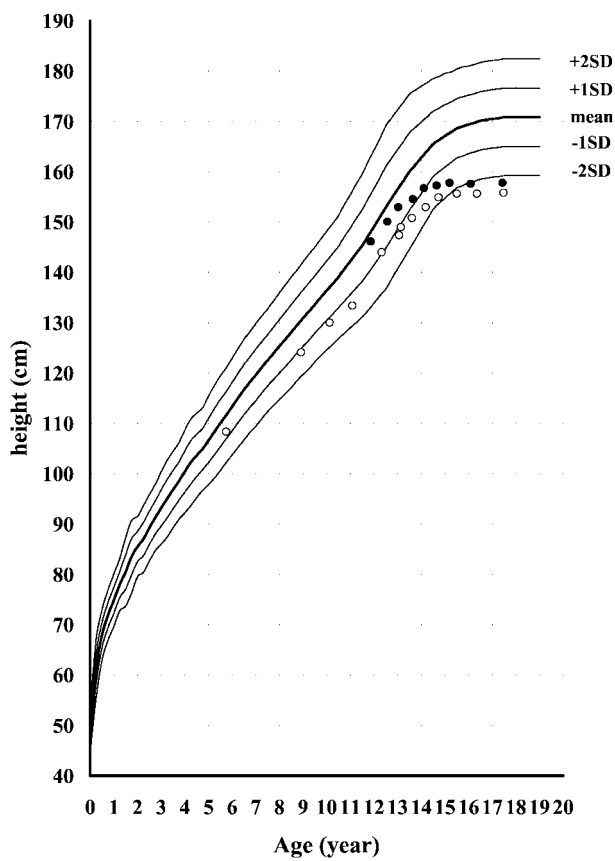


Fig. 1 Growth charts of male PHP1a cases. Open circles and closed circles indicate the heights of Cases 1 and 2, respectively.

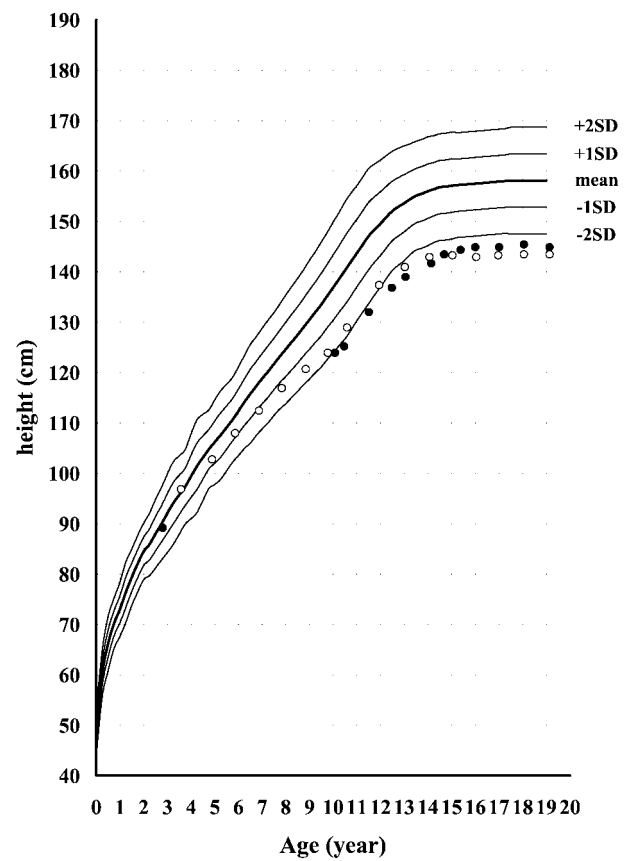


Fig. 2 Growth charts of female PHP1a cases. Open circles and closed circles indicate the heights of Cases 3 and 4, respectively.

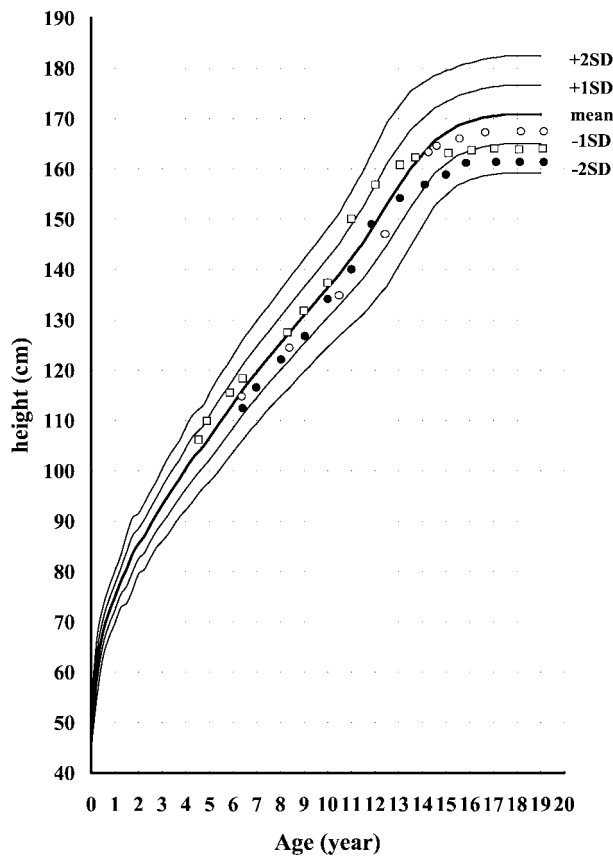


Fig. 3 Growth charts of male PHP1b cases. Open circles, closed circles and open squares indicate the heights of Cases 5, 6 and 7, respectively.

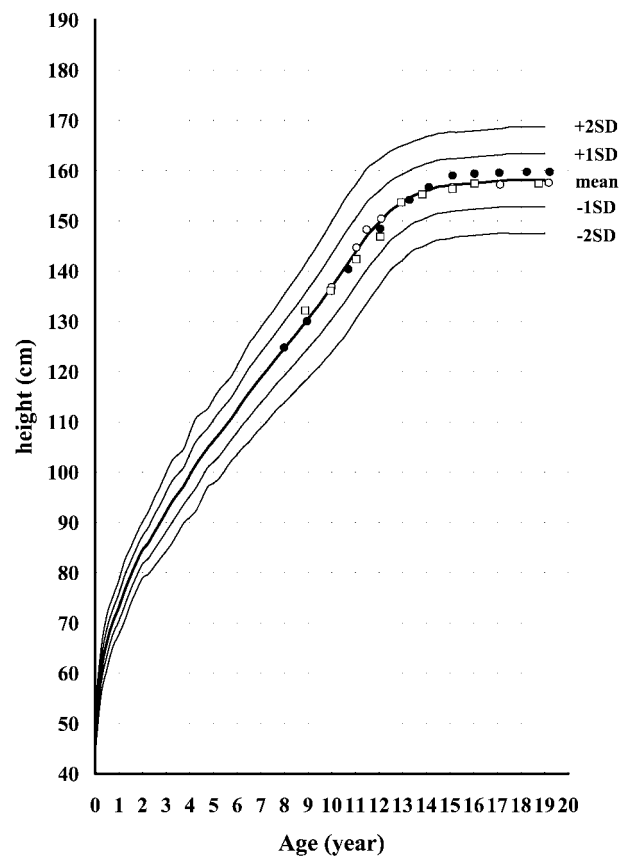


Fig. 4 Growth charts of female PHP1b cases. Open circles, closed circles and open squares indicate the height of Cases 8, 9 and 10, respectively.

reduced adult height. Figure 4 shows the growth charts of female PHP1b cases and all show completely normal growth patterns. We compared their adult heights with their mid-parental heights. Cases 2 and 3 (sporadic PHP1a) were very much shorter than their mid-parental heights (-18.3 and -15.5 cm compared with their mid-parental heights). All the male PHP1b cases had shorter adult height than their mid-parental height (-8.8 to 0 cm) but female PHP1b cases had almost the same height as their mid-parental height (-2.3 to $+3.0$ cm).

Discussion

We evaluated growth charts of PHP patients and analyzed the differences between PHP1a and PHP1b. Short stature is considered to be one of the features of AHO, however, in most cases with PHP1a, short stature was not evident in childhood; it developed in adolescence and was evident in adults in this study. Cases of PHP1a had quite specific growth patterns and the adult height of PHP1a cases may be affected by at least three factors: GH status, the severity of bone disease caused by heterozygous loss-of-function mutation of the *GNAS1* gene, and onset and progression of sexual maturation.

Secretion of GH requires binding of GHRH to specific receptors on pituitary somatotrophs that are coupled via Gs to activation of adenylyl cyclase. GH deficiency in PHP1a occurs in about 70% of cases (6, 7), but the relevancy of GH deficiency on adult height in PHP1a is unknown at present. Patients with PPHP, although not displaying any endocrine abnormality, are characterized by short stature as are their relatives with PHP1a; therefore, a crucial role for GH deficiency in the determination of short stature in these patients seems unlikely (1). Germain-Lee *et al.* reported that among PHP1a patients GH deficient adults were shorter than GH sufficient adults, although GH deficient children are not shorter than GH sufficient children (6). In our study, patients with PHP1a, except for Case 2 who didn't have a growth record before the age of 11 yr 11 mo, showed increasing deviation from the mean height with age during prepubertal growth. GH deficiency may partially contribute to prepubertal growth reduction in PHP1a patients.

The expression of the *GNAS1* gene is biallelic in most tissues; however, genomic imprinting occurs in particular tissues (2, 4, 5). The inactivating mutations of the *GNAS1* gene on the paternal allele have no effect on hormone resistance. Maternal allele dominant or exclusive expression has been reported in human endocrine organs including the pituitary, thyroid, and ovarian cells (4, 5). Although this imprinting mechanism is not well understood, differentially methylated regions in the regulatory sequences of the *GNAS1* gene is reported to be necessary for maternal allele specific expression of Gs α protein (2). The methylation of cytokine residues of CpGs in the exon 1A (also referred to as exon A/B) region upstream of the *GNAS1* gene is critical but not sufficient for the expression of Gs α protein in imprinted tissues. Loss of this methylation on the maternal allele (i.e., both alleles are demethylated) is associated with PHP1b. In this context, the Gs α protein level

may be decreased in the pituitary gland of patients with PHP1b although GH status in PHP1b has not been reported in the literature. We observed poor GH response in provocative tests in some cases in this study, but the growth charts of all PHP1b cases showed normal growth patterns in the prepubertal period. In this study, we found no evident relationship between GH secretion and growth patterns in PHP1b patients. GH status and growth patterns in PHP1b must be studied in large numbers of patients to determine whether or not GH deficiency affects the growth of PHP1b.

The bone age of patients with AHO is advanced 2 to 3 yr in the majority of patients with PHP1a (8). Unfortunately, we were not able to present the data related to bone maturation in this study because the availability of hand X-rays was insufficient. Reduced height gain and premature cessation of growth after the beginning of the growth spurt in PHP1a in our study were concordant with previous studies (3, 8). Active Gs α protein is reduced in bone cells with AHO because both paternally and maternally inherited inactivating mutations in *GNAS1* cause AHO. Genomic imprinting is not shown in bone cells, therefore, the amount of active Gs α protein in bone cells of PHP1b patients must be normal. Haploinsufficiency of the *GNAS1* gene may be responsible for the advanced bone maturation and poor growth potential in the growth spurt because reduced height gain and premature cessation of growth after the beginning of the growth spurt was not observed in the PHP1b patients.

PHP1a patients often have reproductive dysfunction because of partial resistance to gonadotropins (9). One report suggests that early puberty and advanced bone maturation cause the blunted growth spurt in PHP1a (3), however, the growth pattern of PHP1a cases in this study was not suggestive of early puberty in PHP1a. Early puberty in PHP1a seems to be unlikely because of these facts, but further

investigation is required. More interestingly, PHP1b males showed an early growth spurt in this study. This observation must be confirmed with larger numbers of patients. It is very important that in such studies the diagnosis of PHP1b must be based on the molecular analysis because some PHP1a patients with mutations in $Gs\alpha$ often lack physical features of AHO. Early puberty might cause the early growth spurt in PHP1b males. The reason why PHP1b females showed a completely normal growth pattern which was different from PHP1b males is unclear. A possible explanation for this sex difference is that cell-specific imprinting of *GNAS1* expression may affect the maturation of the hypothalamic-pituitary-gonadal axis in different ways between males and females.

Conclusion

The growth pattern was different between PHP types 1a and 1b. The growth of PHP1a cases was characterized by mild growth impairment in the prepubertal period, a blunted growth spurt and premature cessation of the growth spurt. An early growth spurt was observed only in male patients with PHP1b, and it may reduce the adult height of male patients with PHP1b. This warrants further investigation into the growth and pubertal development of PHP1b patients.

Acknowledgement

This article was partly supported by a grant from the Japanese Ministry of Health, Labour and Welfare.

References

1. Levine MA. Hypoparathyroidism and Pseudohypoparathyroidism. In: DeGroot LJ, Jameson JL, editors. *Endocrinology* 5 th ed. Philadelphia: Elsevier Saunders; 2005. p. 1611–36.
2. Liu J, Litman D, Rosenberg MJ, Yu S, Biesecker LG, Weinstein LS. A *GNAS1* imprinting defect in pseudohypoparathyroidism type IB. *J Clin Invest* 2000;106:1167–74.
3. de Wijin EM, Steendijk R. Growth and maturation in pseudo-hypoparathyroidism: a longitudinal study in 5 patients. *Acta Endocrinol* 1982;101:223-6.
4. Mantovani G, Ballare E, Giammona E, Beck-Peccoz P, Spada A. The $Gs\alpha$ gene: predominant maternal origin of transcription in human thyroid gland and gonads. *J Clin Endocrinol Metab* 2002;87:4736–40.
5. Hayward BE, Barlier A, Korbonits M, Grossman AB, Jacquet P, Enjalbert A, *et al.* Imprinting of the $Gs\alpha$ gene *GNAS1* in the pathogenesis of acromegaly. *J Clin Invest* 2001;107:R31–6.
6. Germain-Lee EL, Groman J, Crane JL, Jan de Beur SM, Levine MA. Growth hormone deficiency in pseudohypoparathyroidism type 1a: another manifestation of multihormone resistance. *J Clin Endocrinol Metab* 2003;88:4059–69.
7. Mantovani G, Maghnie M, Weber G, De Menis E, Brunelli V, Cappa M, *et al.* Growth hormone-releasing hormone resistance in pseudohypoparathyroidism type 1a: new evidence for imprinting of the $Gs\alpha$ gene. *J Clin Endocrinol Metab* 2003;88:4070–4.
8. Fitch N. Albright's hereditary osteodystrophy: a review. *Am J Med Genet* 1982;11:11–29.
9. Namnoum AB, Merriam GR, Moses AM, Levine MA. Reproductive dysfunction in women with Albright's hereditary osteodystrophy. *J Clin Endocrinol Metab* 1998;83:824–9.