

## Validity of the Specialized Columnar Epithelium as a Diagnostic Criterion of the Short Segment Barrett's Esophagus

Young-Tae Bak, M.D., Gil Man Jung, M.D., Jong Eun Yeon, M.D., Jae Seon Kim, M.D., Kwan Soo Byun, M.D., Jin Ho Kim, M.D., Jong Guk Kim, M.D., Chang Hong Lee, M.D., Han Kyeom Kim, M.D.\* and Nam Hee Won, M.D.\*

*Division of Gastroenterology and Department of Pathology\*, Korea University College of Medicine, Seoul, Korea*

**Objective :** *In areas where intestinal metaplasia of the stomach is highly prevalent, diagnosing Barrett's esophagus solely by the presence of specialized columnar epithelium in the distal esophagus may lead to many false positive diagnoses. The aim of this study was to test the validity of the specialized columnar epithelium as a diagnostic criterion of the short segment Barrett's esophagus in Korea.*

**Methods :** *During routine gastroscopy, the length of columnar-lined esophagus was measured and biopsy samples were taken from the mucosa immediately distal to the squamocolumnar junction. Under light microscopy, alcian blue-positive cells were identified.*

**Results :** *Prevalence of the specialized columnar epithelium in cases without the columnar-lined esophagus and with the short segment columnar-lined esophagus was 57.1% and 31.2%, respectively ( $P=0.0281$ ). The specialized columnar epithelium is frequently seen around the cardia in Koreans with or without the columnar-lined esophagus.*

**Conclusions :** *Simple presence of the specialized columnar epithelium is not a valid criterion for a diagnosis of Barrett's esophagus. We propose that both the short segment Barrett's esophagus and the goblet cell metaplasia of the cardia might be grouped together under a title of "the specialized columnar epithelium around the gastroesophageal junction" as a potential preceding condition of adenocarcinoma around the cardia.*

**Key words :** *Barrett's esophagus, columnar-lined esophagus, gastroesophageal junction, goblet cells, intestinal metaplasia, specialized columnar epithelium.*

### INTRODUCTION

There is a substantial confusion regarding the diagnostic criterion of Barrett's esophagus (BE). According to many authors, the recent definition of BE is specialized

columnar epithelium (SCE) of the esophageal mucosa, and the length of columnar-lined esophagus (CLE) became not a significant diagnostic criterion any more<sup>1)</sup>. This definition was derived from an assumption that SCE is not normally seen just below the squamocolumnar junction<sup>2)</sup> and a finding that not only the long segment BE but also short segment BE is associated with adenocarcinoma of the esophagus and gastric cardia<sup>3)</sup>. But this definition remains to be validated in areas like

---

Address reprint requests to : Young-Tae Bak, M.D.,  
Division of Gastroenterology, Korea University Guro Hos-  
pital, 80 Guro-dong, Guro-gu, Seoul 152-703, Korea.

Korea where intestinal metaplasia of the stomach is quite prevalent<sup>4)</sup>, because such definition may lead to a false positive diagnosis of BE in case of eccentric squamocolumnar junction. Including goblet cell metaplasia of the "stomach" into BE does not seem to make sense.

In the present study, we investigated the prevalence of SCE on the lower esophagus and gastric cardia in Koreans to elucidate whether SCE can be used as a valid diagnostic criterion of the short segment BE.

## METHODS

Cases were recruited from the patients undergoing routine upper gastrointestinal endoscopy due to various indications. Those undergoing urgent endoscopies, with bleeding tendency, with hepatic cirrhosis or who could not give consent were excluded.

Before endoscopy, patients were questioned for symptoms of gastroesophageal reflux disease such as heartburn, chest pain and regurgitation. During endoscopy while a patient was in a shallow breathing without retching or peristaltic contractions, gastroesophageal junction and squamocolumnar junction were identified. Gastroesophageal junction was defined as the point at which the tubular distal esophagus flared to become a sack-like stomach<sup>5)</sup>. For patients with hiatus hernia, gastroesophageal junction was defined as the proximal margin of the gastric folds in the hiatal pouch<sup>5)</sup>. Length of CLE was measured as the distance from the most upper margin of CLE to the gastroesophageal junction. Short segment was defined as CLE of 0.5 to 2.9 cm in length. When the squamocolumnar junction was at the same level or within 0.4 cm of the gastroesophageal junction, the case was regarded as having no CLE. Seventy-seven consecutive cases with short segment CLE (M:F 64:13, mean age 44.4 yrs) were included and the results were compared with those from twenty-eight control cases without CLE (M:F 16:12, mean age 53.4 yrs).

Four quadrant biopsy samples were taken from the columnar epithelium immediately adjacent to the squamous epithelium. In cases with small isolated island(s) or tongue-like projection(s) of CLE, only two to three biopsy samples could be taken from those areas. H&E-alcian blue (pH 2.5) staining was done by means of standard techniques. If alcian blue-positive cells were found microscopically, they were divided into goblet cells and non-goblet cells, and graded from (+) to (++++) according

to the proportion of the alcian blue-positive cells from total columnar cells on low power microscopic field, lower than 25%, 25-49%, 50-74%, and 75% or higher, respectively.

<sup>2</sup> test was done to compare the results between groups of different lengths of CLE using StatView II (v. 1.03, Abacus Concepts, U.S.A.) for statistical significance at  $P < 0.05$ .

## RESULTS

Prevalence of symptoms suggesting possible presence of gastroesophageal reflux disease was not significantly different between those without CLE (14.3%) and with short segment CLE (28.6%) and among those with different lengths of CLE (Table 1).

**Table 1. Lengths of columnar-lined esophagus (CLE) and prevalence of gastroesophageal reflux (GER) symptoms.**

Lengths of CLE, cm (n)	GER symptoms, n (%)
no CLE (28)	4 (14.3)
with CLE (77)	22 (28.6)
0.5-0.9 (29)	7 (24.1)
1.0-1.4 (30)	9 (30.0)
1.5-1.9 (7)	3 (42.9)
2.0-2.9 (11)	3 (27.3)

SCE was found at the gastroesophageal junction in 16 (57.1%) of 28 cases who did not have any endoscopically apparent CLE (Table 2, Fig. 1).

The prevalence of SCE in cases who had CLE was 31.2% and was significantly lower than that in cases without CLE ( $P=0.0281$ , Table 2). But the prevalence and grade of SCE in cases who had CLE was not different according to the lengths of CLE (Table 2, Fig. 1).

Alcian blue-positive non-goblet columnar cells without goblet cell metaplasia were found at squamocolumnar junction in 25.0% and 44.2% of cases without and with CLE, respectively (Table 2).

68.9% and 24.7% of cases who had short segment CLE had no goblet cell metaplasia and no alcian blue-positive cells at all, respectively (Table 2).

## DISCUSSION

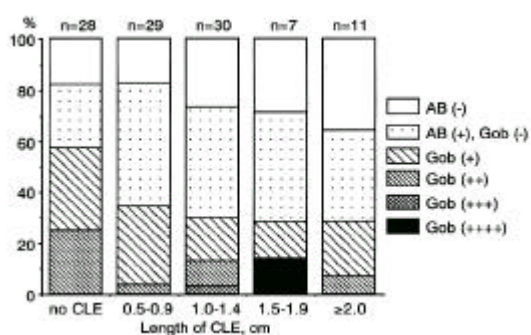
Incidence of adenocarcinoma of the lower esophagus and gastric cardia is rising<sup>6,7)</sup>. But the exact reason of

VALIDITY OF THE SPECIALIZED COLUMNAR EPITHELIUM AS A DIAGNOSTIC CRITERION OF THE SHORT SEGMENT BARRETT'S ESOPHAGUS

**Table 2.** Lengths of columnar-lined esophagus (CLE) and prevalence of alcian blue (AB)-positive cells, n (%).

Length of CLE, cm	AB-positive		AB-negative	Total
	Goblet cells	Non-goblet cells		
no CLE	16 (57.1)	7 (25.0)	5 (17.9)	28
with CLE	24 (31.2)*	34 (44.2)	19 (24.7)	77
0.5-0.9	10 (34.5)	14 (48.3)	5 (17.2)	29
1.0-1.4	9 (30.0)	13 (43.3)	8 (26.6)	30
1.5-1.9	2 (28.6)	3 (42.9)	2 (28.6)	7
2.0-2.9	3 (27.3)	4 (36.4)	4 (36.4)	11

\* P=0.0281 vs. no CLE



**Fig. 1.** Prevalence and grade of alcian blue (AB)-positive goblet (Gob) cells and non-goblet cells according to the lengths of columnar-lined esophagus (CLE).

this trend is still unclear. BE is known to be a major recognized risk factor for esophageal adenocarcinoma. SCE is the most common and distinctive type of columnar epithelium found in BE<sup>8-10</sup>, and adenocarcinoma in BE is associated primarily with SCE<sup>9-12</sup>. Although endoscopic examination can usually distinguish columnar epithelium from squamous epithelium on the esophagus, the types of columnar epithelium cannot be differentiated on endoscopic appearance alone. The distinction between SCE and gastric type columnar epithelium can be made only by histology. Gastric type columnar epithelium may normally line a short segment of the distal esophagus, circumferentially or eccentrically<sup>13, 14</sup>. Therefore, endoscopic diagnosis of BE is usually made when columnar epithelium extends well above the gastroesophageal junction. The operational meaning of "well above" varies according to different authors, ranging from at least 2 cm to more than 5 cm<sup>2, 14, 15</sup>. By these criteria, short segments of SCE in the distal esophagus

are not recognized as abnormal. But such segments appear to be clinically important according to the reports describing adenocarcinomas at the gastroesophageal junction arising from short segment BE<sup>3, 12, 16, 17</sup>.

Concepts regarding the diagnostic criteria of BE have changed much over the past four decades, creating confusion<sup>1</sup>. According to many authors, the recent definition of BE is SCE of the esophageal mucosa, and the length of CLE is no longer a diagnostic criterion. This definition was derived from an assumption that SCE is not normally seen at the gastroesophageal junction<sup>2</sup> and a finding that not only the long segment BE but also short segment BE is associated with adenocarcinoma of the esophagus<sup>3, 16</sup>. But if the intestinal metaplasia of the stomach, especially of the gastric cardia, is quite prevalent, the goblet cell metaplasia of the "gastric" mucosa in case of eccentric Z-line cannot be differentiated from the true short segment BE by histological examination alone. This will lead to many false positive diagnosis of BE and thus the currently accepted definition and descriptions about BE need to be revised.

We could find that as much as 57.1% of Korean patients undergoing routine gastroscopy had SCE at their gastroesophageal junctions although they did not have any apparent endoscopic CLE, thus, having no BE. The prevalence of SCE at gastroesophageal junction in this study was much higher than that of other reports from other countries<sup>5, 18</sup>, but was very close to the reported prevalence (56.6%) of intestinal metaplasia of the stomach in Korea<sup>4</sup>. According to this finding, the simple presence of a short segment of SCE on the distal esophagus should not automatically lead to the diagnosis of BE, especially in those areas with a high prevalence of intestinal metaplasia of the stomach.

It may be technically very difficult (or practically

impossible) to differentiate the short segment BE from the intestinal metaplasia of the cardia. The location of gastroesophageal junction may change during the same examination and/or between examinations. Therefore, length of CLE may vary from time to time<sup>19)</sup>. We cannot expect any clinical significance from separating the two conditions. Both conditions may not be significantly different in the aspect of being potential premalignant conditions of adenocarcinoma around the gastroesophageal junction<sup>20)</sup> and also in their therapeutic options<sup>21)</sup>. Therefore, both conditions may better be grouped together under a title of "the SCE around the gastroesophageal junction" as a potential premalignant condition of adenocarcinoma around the cardia rather than to be separated into two different entities.

BE has been known to be associated with severe gastroesophageal reflux disease and a high risk for malignant transformation requiring strict treatment for reflux and surveillance program for early detection of cancer<sup>22)</sup>. However, many patients with SCE around the gastroesophageal junction have little evidence of having gastroesophageal reflux disease, and their exact risk for malignancy is not clear yet<sup>1)</sup>. Therefore, a new program for surveillance to detect cancers and interventional strategy to regress these lesions and to prevent the malignant transformation needs to be developed.

If only SCE is clinically important, the clinical significance of the CLE in those, comprising as much as two thirds of the cases with short segment CLE in this study, who have the short segment CLE without goblet cells needs to be studied. The significance of alcian blue-positive non-goblet cells is also not clear yet and remains to be further investigated<sup>23, 24)</sup>.

In conclusion, 1) SCE is frequently seen around the cardia in Koreans with or without CLE, 2) in areas like Korea where the intestinal metaplasia of the stomach is quite prevalent, the simple presence of SCE is not a valid criterion to diagnose BE, and 3) we propose to group both short segment BE and SCE of the cardia together under a title of "the SCE around the gastroesophageal junction" as a potential preceding condition of adenocarcinoma around the cardia.

#### ACKNOWLEDGEMENT

Presented at Digestive Disease Week, 1996, in San Francisco, California, U.S.A.

#### REFERENCES

1. Spechler SJ, Goyal RK. *The columnar-lined esophagus, intestinal metaplasia, and Norman Barrett*. *Gastroenterology* 1996; 110:614-621.
2. Dent J, Bremner CG, Collen MJ, Haggitt RC, Spechler SJ Barrett's esophagus. In: *Working Party Reports of the World Congresses of Gastroenterology*. Melbourne: Blackwell Scientific, 1990:17-26.
3. Hamilton SR, Smith RRL, Cameron JL. *Prevalence and characteristics of Barrett esophagus in patients with adenocarcinoma of the esophagus or esophagogastric junction*. *Hum Pathol* 1988; 19:942-948.
4. Yoon CM, Rew JS, Park KS, Bom HS, Park IC, Yang DH, Cho JK. *Subtypes of intestinal metaplasia in endoscopic biopsies of various gastric diseases*. *Kor J Gastroenterol* 1987; 19:13-17.
5. Spechler SJ, Zerogian JM, Antonioli DA, Wang HH, Goyal RK. *Prevalence of metaplasia at the gastroesophageal junction*. *Lancet* 1994; 344:1533-1536.
6. Lund O, Hasenkam JM, Aagaard MT, Kimose HH. *Time-related changes in characteristics of prognostic significance in carcinomas of the esophagus and cardia*. *Br J Surg* 1989; 76:1301-1307.
7. Blot WJ, Devesa SS, Kneller RW, Fraumeni JF, Jr. *Rising incidence of adenocarcinoma of the esophagus and gastric cardia*. *JAMA* 1991; 265:1287-1289.
8. Paull A, Trier JS, Dalton D, Camp RC, Loeb P, Goyal RK. *The histologic spectrum of Barrett's esophagus*. *N Engl J Med* 1976; 295:476-480.
9. Spechler SJ, Goyal RK. *Barrett's esophagus*. *N Engl J Med* 1986; 315:362-371.
10. Das KM, Prasad I, Garla S, Amenta PS. *Detection of a shared colon epithelial epitope on Barrett's epithelium by a novel monoclonal antibody*. *Ann Intern Med* 1994; 120:753-756.
11. Haggitt RC. *Adenocarcinoma in Barrett's esophagus: a new epidemic?* *Hum Pathol* 1992; 23:475-476.
12. Cameron AJ, Lomboy CT, Pera M, Carpenter HA. *Adenocarcinoma of the esophagogastric junction and Barrett's esophagus*. *Gastroenterology* 1995; 109:1541-1546.
13. Goyal RK, Glancy JJ, Spiro HM. *Lower esophageal ring*. *N Engl J Med* 1970; 282:1298-1305.
14. McClave SA, Boyce HW, Jr, Gottfried MR. *Early diagnosis of columnar-lined esophagus: a new endoscopic criterion*. *Gastrointest Endosc* 1987; 33:413-416.
15. Rothery GA, Patterson JE, Stoddard CJ, Day DW. *Historical and histochemical changes in the columnar lined (Barrett's) esophagus*. *Gut* 1986; 27:1062-1068.
16. Schnell TG, Sontag SJ, Chejfec G. *Adenocarcinoma arising in tongues or short segments of Barrett's esophagus*. *Dig Dis Sci* 1992; 37:137-143.
17. Clark GW, Smyrk TC, Burdiles P, Hoefl SF, Peters JH, Kiyabu M, Hinder RA, Bremner CG, DeMeester TR. *Is*

VALIDITY OF THE SPECIALIZED COLUMNAR EPITHELIUM AS A DIAGNOSTIC CRITERION OF  
THE SHORT SEGMENT BARRETT'S ESOPHAGUS

- Barrett's metaplasia the source of adenocarcinomas of the cardia?* Arch Surg 1994;129:609-614.
18. Spechler SJ, Zeroogian JM, Wang HH, Antonioli DA, Goyal RK. *The frequency of specialized intestinal metaplasia at the squamo-columnar junction varies with the extent of columnar epithelium lining the esophagus [Abstract].* Gastroenterology 1995;108:A224.
19. Kim SL, Waring JP, Spechler SJ, Sampliner RE, Doos WG, Krol WF, Willford WO, *The Department of Veterans Affairs Gastroesophageal Reflux Study Group. Diagnostic inconsistencies in Barrett's esophagus.* Gastroenterology 1994;107:945-949.
20. Kalish RJ, Clancy PE, Orringer MB, Appelman HD. *Clinical, epidemiologic, and morphologic comparison between adenocarcinomas arising in Barrett's esophageal mucosa and in the cardia.* Gastroenterology 1984;86:461-467.
21. Wakh TN, Noonan N, Hollywood D, Kelly A, Keeling N, Hennessy TPJ. *A comparison of multimodal therapy and surgery for esophageal adenocarcinoma.* N Engl J Med 1996;335:462-467.
22. Provenzale D, Kemp JA, Arora S, Wong JB. *A guide for surveillance of patients with Barrett's esophagus.* Am J Gastroenterol 1994;89:670-680.
23. Haggitt RC. *Barrett's esophagus, dysplasia, and adenocarcinoma.* Hum Pathol 1994;25:982-993.
24. Offner FA, Weinstein WM, Lewin KJ. *Columnar, non-goblet cell metaplasia: a neglected feature in the diagnosis of Barrett's esophagus [Abstract].* Gastroenterology 1995;108:A180.
-