



Systemic Review: Neurological Deficits following Ventriculoperitoneal Shunt (VPS) Insertion

Rana Moshref¹ Rafaah Ahmed Algethmi¹

¹Department of Neuroscience, King Faisal Specialist Hospital and Research Centre, Jeddah, Saudi Arabia

Asian J Neurosurg 2023;18:444–453.

Address for correspondence Rana Moshref, MBBS, Neuroscience Department, King Faisal Specialist Hospital and Research Center, 2865 Al Shoubasi, Ar Rawdah, Jeddah 23431 6688, Saudi Arabia (e-mail: ranamoshref@gmail.com).

Abstract

A reduction in fluid absorption or an obstruction of normal outflow is a common cause of hydrocephalus. It typically requires medical attention, which frequently entails the placement of a ventriculoperitoneal shunt (VPS) to lower intracranial pressure. We intend to list the few, documented examples of neurological impairments resulting from the installation of a VPS in this systematic study. Two search engines (PubMed and Cochrane) were used to conduct a systematic review from 1975 to December 12, 2021. The following search terms were employed: neurological deficits or neurological injury or palsies or thalamus or tract or longitudinal fasciculus or somatotropy or fasciculus or hearing loss or hemisensory or cortico AND ventriculoperitoneal shunt or VPS AND hydrocephalus. The inclusion criteria included VPS, neurological deficits, and human participants. The exclusion criteria included ventriculoarterial shunt, lumboperitoneal shunt, nonhuman subjects, and infection. Twenty trials in total, including a total of 25 patients, were included. There were 17 case report studies. A total of 35/785 patients (4.46%) experienced neurological impairments. In 9/25 (36%) of shunt cases had one of the three recognized causes: trapped fourth ventricle, dandy walker, or syringomyelia. Most of the patients developed VI, VII nerve palsies 11/25 (44%) followed by weakness, cerebellar symptoms, and VI nerve palsy. The brainstem was seen to be the most often injured structure (15/25; 60%), followed by deep brain structures (thalamus, basal ganglia, and white matter tracts; 20%). Even though ventriculoperitoneal shunting is a routine and straightforward treatment, issues can still arise. Although rare, there have been reports of cranial nerve impairments, therefore care should be taken.

Keywords

- ▶ neurological deficits
- ▶ palsies
- ▶ ventriculoperitoneal shunt
- ▶ VPS
- ▶ tract

article published online
September 22, 2023

DOI <https://doi.org/10.1055/s-0043-1771329>.
ISSN 2248-9614.

© 2023. Asian Congress of Neurological Surgeons. All rights reserved.

This is an open access article published by Thieme under the terms of the Creative Commons Attribution-NonDerivative-NonCommercial-License, permitting copying and reproduction so long as the original work is given appropriate credit. Contents may not be used for commercial purposes, or adapted, remixed, transformed or built upon. (<https://creativecommons.org/licenses/by-nc-nd/4.0/>)

Thieme Medical and Scientific Publishers Pvt. Ltd., A-12, 2nd Floor, Sector 2, Noida-201301 UP, India

Introduction

A reduction in fluid absorption or obstruction of normal outflow is a common cause of hydrocephalus. It typically requires medical attention, which frequently entails the placement of a ventriculoperitoneal shunt (VPS).¹

VPS-related complications are widely prevalent, and several shunt revisions are nearly always required over the course of a patient's lifespan. Shunt failure can be caused by a variety of factors, including blockage and pseudocyst formation,² as well as, reported in the literature, by shunt overdrainage (slit ventricles,³ malposition,⁴ and rarely abdominal perforation after placement⁵).

One of the most frequent side effects of the VPS is infection and bleeding. Although they are uncommon consequences, neurological impairments and cranial nerve palsies have been documented in numerous case reports. We intend to list the few, documented examples of neurological impairments resulting from the installation of a VPS in this systematic study.

Methods

The study was conducted following the Preferred Reporting Items for Systematic Reviews and Meta-Analyses (PRISMA) guidelines.⁶ Two separate researchers performed a systematic review in the years 1975 to December 12, 2021 in the two search engines PubMed and Cochrane. Participants were limited to only humans. The following search terms were employed: neurological deficits or neurological injury or palsies or thalamus or tract or longitudinal fasciculus or somatotropy or fasciculus or hearing loss or hemisensory or cortico AND ventriculoperitoneal shunt or VPS AND hydrocephalus. The inclusion criteria included VPS, neurological deficits, and human participants. The exclusion criteria included ventriculoarterial shunt, lumboperitoneal shunt, nonhuman subjects, and infection.

The search strategy for human studies revealed 1,184 studies. After duplicated studies were removed from the primary survey, 1,176 studies were screened by title and abstract. A total of 26 studies were included in the secondary survey. The inclusion criteria in the secondary survey were met by 16 articles, cross-reference added 4 more studies making a total of 20 studies (PRISMA chart, ► Fig. 1).

Results

There were 25 patients included in a total of 20 studies (► Table 1). There were 17 case report studies. Thirty-five of 785 patients (4.46%) experienced neurological impairments. The majority of the patients were adults, and their ages spanned from premature birth to 90 years. The known causes for shunting were trapped 4th ventricle/dandy walker/syringomyelia 9/25 (36%), followed by posttumor resection/posthemorrhage 7/25 (28%), normal pressure hydrocephalus 5/25 (20%), and infection 4/25 (16%).

Most of the patients developed VI and VII nerve palsies 11/25 (44%), followed by weakness, cerebellar symptoms,

and VI nerve palsy. It is noticed that the common structures to be injured were brainstem 15/25 (60%), followed by deep structures of the brain (thalamus, basal ganglia, and white matter tracts) 5/25 (20%). The timing of the deficits was unclear. Supratentorial shunts were placed in 13/25 (52%), whereas posterior fossa shunts were placed in 9/25 (36%), while in 3/25 participants (12%) shunts were not placed.

Most of the follow-up period was not reported; however, it ranged from 4 to 208 weeks. Revision of shunt occurred in 9/25 (36%) patients. As a result, about two-thirds of the study participants experienced improvement.

Discussion

A large study of 10 years' period with enrolment of nearly 450 participants, identified techniques of posterior VPS insertion including ways to improve catheter insertion accuracy and minimizing complications. The ideal ventricular catheter placement was achieved in 98% of cases; no adjustments were required. Less than 1% of patients ($n = 4$) who underwent surgery later on experienced new neurological impairments, two of which were brought on by intraparenchymal hemorrhages and the other two by improperly inserted catheters that led to transient neurological abnormalities.⁷

Numerous research has shown that a VPS can cause unexpected insults because of direct injury to the basal ganglia,⁸ corticospinal tract and limbic system,⁹ discontinuation and injury of the cingulum,¹⁰ corticoreticular pathway and corticospinal tract,¹¹ thalamocingulate tract,¹² corticoreticulospinal tract,¹³ and superior longitudinal fasciculus.¹⁴

Although occurrence of cranial nerve palsies is uncommon, it is reported in youngsters.¹⁵ Low motor neuron facial nerve palsies have only rarely been reported to arise after VPS in three individuals¹⁶⁻¹⁸ and one after an isolated fourth ventricular shunt.¹⁹ In two cases, both facial and abducens nerve palsies were caused by VPS implantation. By inserting a high-pressure valve in one case and retraction of the catheter a few centimeters in the other, both patients experienced full recovery.¹⁵ In addition to facial and abducens nerve palsies, unilateral trochlear nerve palsies following shunt placement have also been documented, with two case reports improving after strabismus surgery.²⁰ Additionally, due to a misplaced catheter, bilateral trochlear nerve palsy has been documented in a case report.²¹

A small study was conducted back in July 1989 that studied 12 patients with fourth ventricular shunts. The study showed that two-thirds of the patients developed new cranial nerve dysfunction because of direct injury to the floor of the fourth ventricle, causing intracystic hemorrhage. One patient had a catheter tip in the brainstem and did not develop neurological deficits.²² Another study showed lower prevalence because of its large sample size. According to the study, 2.5% of the kids had isolated fourth ventricles, and of them, 2% had symptoms and needed posterior fossa shunting. As a result of a fourth ventricle that resembled a slit due to brainstem irritation from the fourth ventricular catheter, 1% (0.007%) of participants in this study experienced new

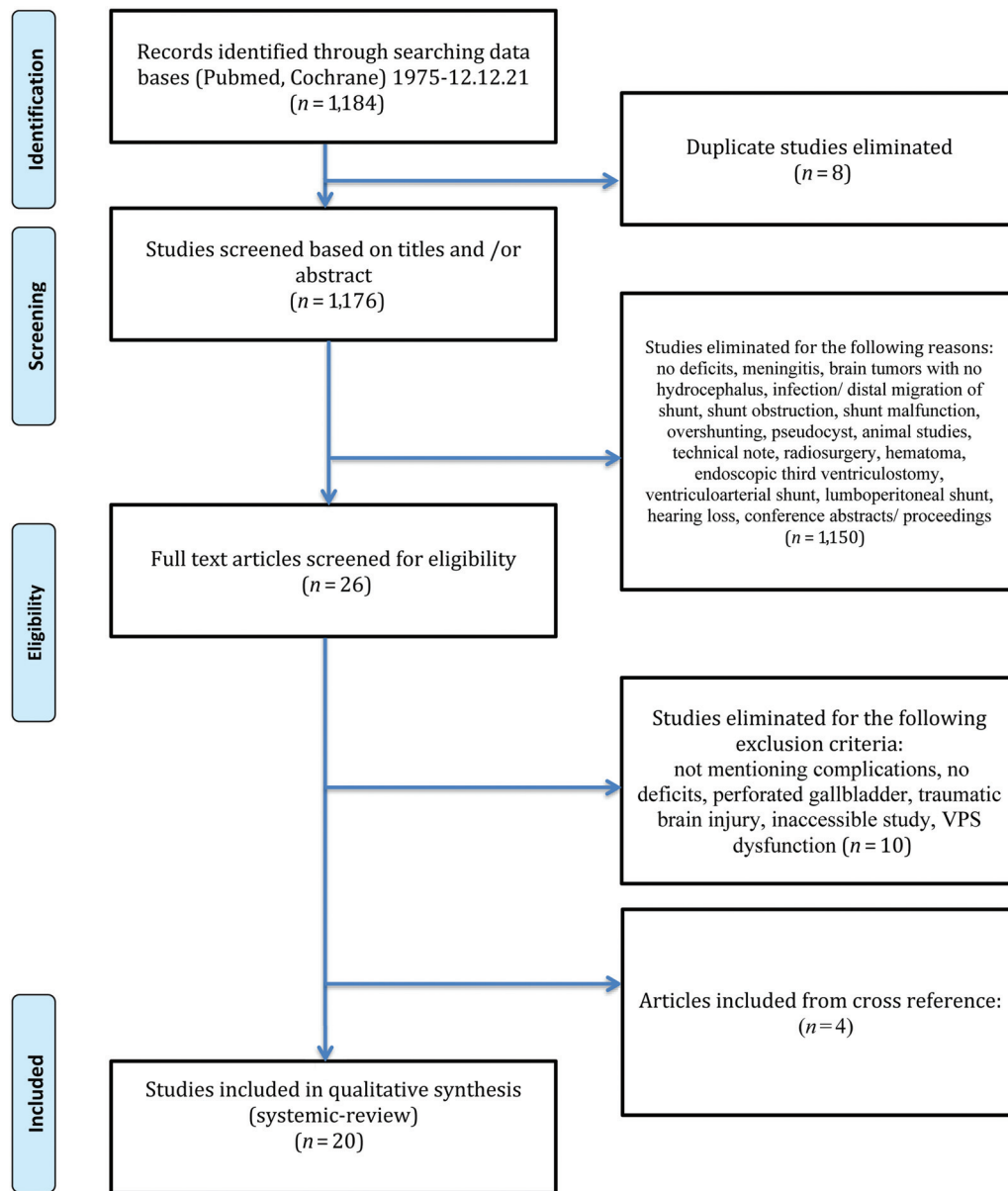


Fig. 1 Preferred Reporting Items for Systematic Reviews and Meta-Analyses (PRISMA) chart showing studies that show neurological dysfunction after ventriculoperitoneal shunt (VPS) insertion.

impairments in cranial nerves.²³ If damage is done, it will result in long-term paralysis of the sixth, seventh, tenth, and twelfth cranial nerves.²⁴ This is demonstrated in the case of a patient who experienced complete unilateral sixth nerve paralysis as a result of catheter insertion at the level of the pontomedullary junction, as shown by magnetic resonance imaging (MRI), and who recovered full function after the catheter was repositioned using endoscopy.²⁵

To diagnose the underlying cause of neurological deficits, it is recommended to do diffusion tensor tractography to visualize three-dimensional reconstruction of neural tracts on brain MRI.^{12,14} Treatment is typically case-by-case, and if brainstem nuclei were damaged, it typically entails reducing the catheter and switching the valve to a programmable one that shows resolution of impairments.²³

Conclusion

Even though ventriculoperitoneal shunting is a routine and straightforward treatment, issues can still arise. Although rare, there have been reports of cranial nerve impairments, therefore care should be taken.

Authors' Contributions

R.M. contributed to the idealization of the manuscript, drafting of the article, writing, reviewing and editing of the manuscript, systemic analysis and results, and supervision of the research. R.A. contributed to the writing of the manuscript.

Conflict of Interest

None declared.

Table 1 Cases illustrating neurological deficits after insertion of VPS

Author and publication date	Title	Type of study	Number of patients with complication	Number of patients who developed deficits	Participant (years and gender: female, F, male, M)	Known case/medical history	Deficits	Injury structure	Timing of deficits (weeks after last shunt placement)	Shunt	Follow-up (wk)	Shunt revision after neurological deficits (number, procedure)	Resolution (no. and deficits)
Lee et al, 1995	Complications of fourth-ventricular shunts	Prospective cohort	12	5	3 y M	Trapped 4th ventricle, VP shunt multiple revisions	VI, VII palsies, dysarthria, ataxia	Cannulation, brainstem injury	Not mentioned	None	208	No treatment	No, diplopia
					23 y F	Dandy walker cyst, VP and PF multiple revisions	No deficits	Intracystic bleeding from hemorrhage during cannulation	Not mentioned	Suboccipital craniotomy and PFS revision	4	1, shunt revision	Death (1 month later, sepsis)
					32 y F	Dandy walker cyst, VP and PF multiple revisions	VI, VII palsies, hoarseness, hemiparesis, swallowing difficulties	Catheter in brainstem, cyst collapse	Not mentioned	Suboccipital craniotomy and PFS revision	208	1, shunt revision	Unchanged, permanent deficits, in rehabilitation
					8 mo F	Trapped 4th ventricle, VA and PF	No deficits	Catheter in pons	Not mentioned	None	52	None	Death (1 year later)
					18 y M	Dandy walker cyst, VA and PF multirevisions	VI, VII palsies	Cannulation brainstem injury	Not mentioned	None	208	None	No, diplopia
Eder et al, 1997	Complications after shunting isolated IV ventricles	Prospective cohort	292	7	< 16 y and 4 premature gestational age 27-32 weeks (3 IVH and meningitis 2-6 months pseudomonas <i>Escherichia coli</i> pneumococcus, 1 pseudomonas meningitis at 6 months)	IVH, meningitis	Isolated IV ventricle (2 asymptomatic developed cerebellar signs at 6 and 12 months, 5 symptomatic posterior fossa signs ataxia diplopia nystagmus)	Not mentioned	24, 52	PFS	104	7, shortening of catheter 1 cm and replacement of valve	5/7 improved, 2/7 patients new deficits right VI, VII palsy (1 and 6 wk)
Pang et al, 2005	Progressive cranial nerve palsy following shunt placement in an isolated fourth ventricle: case report	CR	1	1	10 y M	Dilated 4th ventricle, syringomyelia (right side weakness and gait spasticity)	VI, VII, IX, XII palsies	Catheter shifted backward in the 4th ventricular floor	8	4th ventricle shunt	6	0, lysis of basal cistern adhesions	Yes

(Continued)

Table 1 (Continued)

Author and publication date	Title	Type of study	Number of patients with complication	Number of patients who developed deficits	Participant (years and gender: female, F, male, M)	Known case/ medical history	Deficits	Injury structure	Timing of deficits (weeks after last shunt placement)	Shunt	Follow-up (wk)	Shunt revision after neurological deficits (number, procedure)	Resolution (no. and deficits)
Alakandy et al, 2008	Hemichorea, an unusual complication of ventriculoperitoneal shunt	CR	1	1	24 y M	Obstructive hydrocephalus secondary to meningococcal meningitis and aqueductal stenosis, then 7 years later (insertion new shunt because of fracture of distal shunt and migration, proximal catheter)	Chorioform movement in left side	Catheter in right basal ganglia with tip in 3rd ventricle	2	Right VPS	Not mentioned	1. shunt removed	Yes
Gold et al, 2008	Brain injury due to ventricular shunt placement delineated by diffusion tensor imaging (DTI) tractography	CR	1	1	14 y M	1st shunt inserted at 5 years for aqueductal stenosis, then revised 9 year developed left hemiparesis then resolved in few weeks	Severe behavioral disorder (child onset bipolar disorder)	Injury to corticospinal tract (transverse right coronal radiata, posterior limb of internal capsule) and limbic system (thalamus, asymmetric volume of mammillary body, hippocampus, for mix, amygdala)	135	VPS	Not mentioned	0	Yes
Pandey et al, 2008	Acquired isolated unilateral nerve palsy after ventriculoperitoneal shunt surgery	CR	2	2	20 y F, 16 y M	Obstructive hydrocephalus for tubercular meningitis, solitary pontine tuberculoma extending to cisterna pontis	IV nerve palsy	Catheter abutting temporal horn of lateral ventricle	Not mentioned	Left parietal VPS	52	0	Yes, with strabismus surgery

Table 1 (Continued)

Author and publication date	Title	Type of study	Number of patients with complication	Number of patients who developed deficits	Participant (years and gender: female, F, male, M)	Known case/medical history	Deficits	Injury structure	Timing of deficits (weeks after last shunt placement)	Shunt	Follow-up (wk)	Shunt revision after neurological deficits (number, procedure)	Resolution (no. and deficits)
Torrez-Corzo et al, 2009	Endoscopic management of brainstem injury due to ventriculoperitoneal shunt placement	CR	1	1	20 y M	Complex hydrocephalus and trapped 4th ventricle	Double vision, VI nerve palsy	Catheter in dorsal brainstem at level of pontomedullary junction	Not mentioned	PFS	0.5	1. endoscopic reposition of catheter, aqueductoplasty	Yes
Giesemann et al, 2012	Bilateral trochlear nerve palsy subsequent to ventriculoperitoneal shunting of normal pressure hydrocephalus	CR	1	1	82 y M	Normal pressure hydrocephalus	Bilateral IV nerve palsy	Catheter too deep traversing 3rd ventricle, penetrating midbrain tectum in midline	Not mentioned	Frontal VPS	Not mentioned	0	No as patient refused treatment
Kwon and Jang, 2012	Cingulum injury by ventriculoperitoneal shunt	CR	1	1	69 y F	Hydrocephalus 20 days postclipping of posterior communicating cerebral artery	Not mentioned	Discontinuation of left cingulum above body of corpus callosum	Not mentioned	Left frontal VPS	Not mentioned	Not mentioned	Not mentioned
Ramdasi et al, 2015	Lower motor neuron facial palsy after ventriculoperitoneal shunt surgery	CR	1	1	40 y F	Pseudomeningocele after marsupialization of symptomatic retrocerebellar cyst and decompression of foramen magnum	Low motor neuron facial palsy grade 5 House and Brackmann	Injury to facial nerve distal to origin of chorda tympani	Not mentioned	Right parietal VPS	12	0	Partial improvement, weakness grade I/II with prednisolone

(Continued)

Table 1 (Continued)

Author and publication date	Title	Type of study	Number of patients with complication	Number of patients who developed deficits	Participant (years and gender: female, F, male, M)	Known case/medical history	Deficits	Injury structure	Timing of deficits (weeks after last shunt placement)	Shunt	Follow-up (wk)	Shunt revision after neurological deficits (number, procedure)	Resolution (no. and deficits)
Simonin et al, 2015	Cranial nerve palsies after shunting of an isolated fourth ventricle	CR	2	2	42 y F	Hydrocephalus after left petroclival meningioma shunted then ventriculitis then removed, then ventriculostomy done and left VPS done, years later isolated 4th ventricle enlargement	Bilateral VI VII palsies, unsteadiness	Overdrainage	Not mentioned	Right PFS	12	1, valve adjustment	Yes
					18 y M	Hydrocephalus 3 weeks after excision of right cerebellar hemorrhage due to ruptured AVM and suboccipital craniectomy	Unsteadiness, bilateral VI, VII palsies	Displacement of cerebellar tonsils (Chiari-like picture)	Not mentioned	2 shunts PFS with Y connector	Not mentioned	Multiple for infection, last one withdrawal of catheter 8 mm	Improvement
Jang and Seo, 2015	Injury of corticoreticular pathway and corticospinal tract caused by ventriculo-peritoneal shunting	CR	1	1	70 y F	Normal pressure hydrocephalus	Left hemiparesis and gait difficulties	Hemorrhage and discontinuation in right corona radiata, degeneration to right midbrain, anterior portion of right corticospinal tract and corticoreticular	Not mentioned	Right parietal VPS	4	Not mentioned	Not mentioned

Table 1 (Continued)

Author and publication date	Title	Type of study	Number of patients with complication	Number of patients who developed deficits	Participant (years and gender: female, F, male, M)	Known case/medical history	Deficits	Injury structure	Timing of deficits (weeks after last shunt placement)	Shunt	Follow-up (wk)	Shunt revision after neurological deficits (number, procedure)	Resolution (no. and deficits)
Jang and Seo, 2016	Injury of the thalamo-cingulate tract in the Papez circuit by ventriculo-peritoneal shunt: a case report	CR	1	1	74 y F	Normal pressure hydrocephalus	Change in cognition	Tip in anterior thalamus, injury to right thalamo-cingulate tract	Not mentioned	Right parietal VPS	2	Not mentioned	Not mentioned
Jang and Kwon, 2018	Injury of leg somatoprop of corticospinal tract at corona radiata by ventriculo-peritoneal shunt: a case report	CR	1	1	45 y F	Hydrocephalus following traumatic intercerebral hematoma	Weakness in left leg	Left corticospinal tract injury in posterior portion	Not mentioned	Right parietal VPS	24	Not mentioned	No
Kumaria et al, 2018	Recurrent Bell's palsy following ventriculo-peritoneal shunt insertion: an unusual case to face	CR	1	1	15 y M	Hydrocephalus secondarily to tectal plate glioma	Lower right motor neuron facial weakness House and Brackmann 3	Not mentioned	Not mentioned	Right parietal VPS	1	0	Yes, with steroid
Jang and Lee, 2018	Injury of the superior longitudinal fasciculus by ventriculo-peritoneal shunt: a diffusion tensor tractography study	CR	1	1	82 y F	Normal pressure hydrocephalus	Low cognition	Right upper portion of anterior thalamus and right superior longitudinal fasciculus	Not mentioned	Right parietal VPS	2	Not mentioned	Not mentioned

(Continued)

Table 1 (Continued)

Author and publication date	Title	Type of study	Number of patients with complication	Number of patients who developed deficits	Participant (years and gender: female, F, male, M)	Known case/medical history	Deficits	Injury structure	Timing of deficits (weeks after last shunt placement)	Shunt	Follow-up (wk)	Shunt revision after neurological deficits (number, procedure)	Resolution (no. and deficits)
Khayat et al, 2019 ⁵⁶	Surgical management of isolated fourth ventricular hydrocephalus associated with injury to the Guillain-Mollaret triangle	CR	1	1	45 y F	Communicating hydrocephalus after cerebral abscess, subtotal resection of ependymoma (grade 3) and radiation	Palatal myoclonus, hand incoordination, bilateral foot numbness, progressive ataxia	Hypertrophic degeneration of inferior olivary nuclei bilaterally	Not mentioned	Right parietal VPS	24	2, insertion of lateral transcerebellar trajectory by programmable valve for isolated 4th ventricle (worsening of symptoms), 4th ventricular shunt (improvement)	Yes
Zanaty et al, 2019	Methods and devices for posterior ventriculo-peritoneal shunt placement surgery: 25 years of iterative refinement	Retrospective cohort	468	4	Range 11–90 y	Not mentioned	Not mentioned	2 intraparenchymal hemorrhage, 2 poor catheter placement	Not mentioned	PFS	24	Not mentioned	Yes
Golpayegani et al, 2020	Peripheral facial nerve palsy following ventriculo-peritoneal shunting in an infant	CR	1	1	1.6 y M	Hydrocephalus secondary to suprasellar mass (optic pathway glioma)	Right peripheral facial nerve palsy House and Brackmann 5	Soft tissue swelling in right mastoid extratemporal	Not mentioned	Right frontal VPS	24	0	Yes, with steroid
Yilmaz et al, 2020	Peripheral facial nerve palsy after ventriculo-peritoneal shunt surgery: an anatomical perspective	CR	1	1	75 y M	Normal pressure hydrocephalus	Peripheral facial nerve palsy House Brackmann 4	Injury to facial nerve trunk during tunneling, edema in extratemporal right facial nerve	Not mentioned	PFS	4	0	Yes, with steroid

Abbreviations: AVM, arteriovenous malformation; CR, case report; IVH, intraventricular hemorrhage; PF, posterior fossa; PFS, posterior fossa shunt; USG, ultrasound guidance; VS, ventriculoatrial; VPS, ventriculo-peritoneal shunt.

References

- 1 Shakeri M, Vahedi P, Lotfinia I. A review of hydrocephalus: history, etiologies, diagnosis, and treatment. *Neurosurg Q* 2008;18(03): 216–220
- 2 Paff M, Alexandru-Abrams D, Muhonen M, Loudon W. Ventriculoperitoneal shunt complications: a review. *Interdiscip Neurosurg* 2018;13:66–70
- 3 Ros B, Iglesias S, Martín Á, Carrasco A, Ibáñez G, Arráez MA. Shunt overdrainage syndrome: review of the literature. *Neurosurg Rev* 2018;41(04):969–981
- 4 Hayhurst C, Beems T, Jenkinson MD, et al. Effect of electromagnetic-navigated shunt placement on failure rates: a prospective multicenter study. *J Neurosurg* 2010;113(06):1273–1278
- 5 Bourm K, Pfeifer C, Zarchan A. Small bowel perforation: a rare complication of ventriculoperitoneal shunt placement. *J Radiol Case Rep* 2016;10(06):30–35
- 6 Moher D, Liberati A, Tetzlaff J, Altman DG, PRISMA Group. Preferred Reporting Items for Systematic Reviews and Meta-Analyses: the PRISMA statement. *J Clin Epidemiol* 2009;62(10): 1006–1012
- 7 Zanaty M, Roa JA, Piscopo AJ, Kritikos ME, Teferi N, Howard MA III. Methods and devices for posterior ventriculoperitoneal shunt placement surgery: 25 years of iterative refinement. *World Neurosurg* 2019;129:514–521.e3
- 8 Alakandy LM, Iyer RV, Golash A. Hemichorea, an unusual complication of ventriculoperitoneal shunt. *J Clin Neurosci* 2008;15(05): 599–601
- 9 Gold MM, Shifteh K, Valdborg S, Lombard J, Lipton ML. Brain injury due to ventricular shunt placement delineated by diffusion tensor imaging (DTI) tractography. *Neurologist* 2008;14 (04):252–254
- 10 Kwon HG, Jang SH. Cingulum injury by ventriculoperitoneal shunt. *Eur Neurol* 2012;67(01):63–64
- 11 Jang SH, Seo JP. Injury of corticoreticular pathway and corticospinal tract caused by ventriculoperitoneal shunting. *Neural Regen Res* 2015;10(11):1874–1875
- 12 Jang SH, Seo JP. Injury of the thalamocingulate tract in the Papez circuit by ventriculoperitoneal shunt: a case report. *Int J Stroke* 2016;11(01):NP20–NP21
- 13 Jang SH, Kwon Y. Injury of leg somatotopy of corticospinal tract at corona radiata by ventriculoperitoneal shunt: a case report. *Medicine (Baltimore)* 2018;97(10):e9983
- 14 Jang SH, Lee HD. Injury of the superior longitudinal fasciculus by ventriculoperitoneal shunt: a diffusion tensor tractography study. *Neural Regen Res* 2018;13(07):1288–1289
- 15 Simonin A, Levivier M, Bloch J, Messerer M. Cranial nerve palsies after shunting of an isolated fourth ventricle. *BMJ Case Rep* 2015. Doi: bcr2015209592
- 16 Ramdasi RV, Rangarajan V, Mahore A. Lower motor neuron facial palsy after ventriculoperitoneal shunt surgery. *BMJ Case Rep* 2015. Doi: bcr2014206938
- 17 Golpayegani M, Habibi Z, Rabbani Anari M, Nejat F. Peripheral facial nerve palsy following ventriculoperitoneal shunting in an infant. *Childs Nerv Syst* 2020;36(01):209–212
- 18 Kumaria A, Hammitt TC, Sitaraman M, D'Aquino DA, Macarthur DC. Recurrent Bell's palsy following ventriculoperitoneal shunt insertion: an unusual case to face. *Br J Neurosurg* 2018;32(03): 295–296
- 19 Yilmaz MO, Rakici IT, Karaoglu AC, Solmaz B. Peripheral facial nerve palsy after ventriculoperitoneal shunt surgery: an anatomical perspective. *Turk Neurosurg* 2020;30(05):780–783
- 20 Pandey PK, Dadeya S, Amar A, Vats P, Singh A. Acquired isolated unilateral fourth nerve palsy after ventriculoperitoneal shunt surgery. *J AAPOS* 2008;12(06):618–620
- 21 Giesemann AM, Capelle HH, Winter R, Krauss JK. Bilateral trochlear nerve palsy subsequent to ventriculoperitoneal shunting of normal pressure hydrocephalus. *Br J Neurosurg* 2012;26(01): 110–112
- 22 Lee M, Leahu D, Weiner HL, Abbott R, Wisoff JH, Epstein FJ. Complications of fourth-ventricular shunts. *Pediatr Neurosurg* 1995;22(06):309–313, discussion 314
- 23 Eder HG, Leber KA, Gruber W. Complications after shunting isolated IV ventricles. *Childs Nerv Syst* 1997;13(01):13–16
- 24 Pang D, Zwienerberg-Lee M, Smith M, Zovickian J. Progressive cranial nerve palsy following shunt placement in an isolated fourth ventricle: case report. *J Neurosurg* 2005;102(03):326–331
- 25 Torrez-Corzo J, Rodriguez-Della Vecchia R, Chalita-Williams JC, Rangel-Castilla L. Endoscopic management of brainstem injury due to ventriculoperitoneal shunt placement. *Childs Nerv Syst* 2009;25(05):627–630
- 26 Khayat HA, Al-Saadi T, Panet-Raymond V, Diaz RJ. Surgical Management of Isolated Fourth Ventricular Hydrocephalus Associated with Injury to the Guillain-Mollaret Triangle. *World Neurosurg* 2019;122:71–76. Doi: 10.1016/j.wneu.2018.10.091