

Effectiveness of percutaneous cement injection on proximal junctional failure after posterior lumbar interbody fusion

Preliminary study

Jong Geol Do, MD^a, Jong Won Kwon, MD, PhD^b, Sang Jun Kim, MD, PhD^{c,*}

Abstract

Proximal junctional failure (PJF) is the greatest challenge after posterior lumbar interbody fusion (PLIF). The aim of this study was to evaluate the effectiveness of percutaneous cement injection (PCI) for PJF after PLIF patients requiring surgical revision.

In this retrospective clinical study, we reviewed 7 patients requiring surgical revision for PJF after PLIF with 18 months follow-up. They received PCI at the collapsed vertebral body and supra-adjacent vertebra, with or without intervertebral disc intervention. The outcome measures were radiographic findings and revision surgery. Two different radiographic parameters (wedging rate (%) of the fractured vertebral body and local kyphosis angle) were used, and were performed before and immediately after PCI, and 18 month after the PCI.

In our study, we showed that 5 of 7 patients who experienced PJF after PLIF did not receive any revision surgery after PCI. Immediately after cement injection, the anterior wedging rate (%) and the local kyphosis angle were significantly improved ($P = .018$, $P = .028$). The anterior wedging rates (%) and local kyphosis angle, at pre-PCI, immediate after PCI, and at final follow-up, were not significantly different between the non-revision surgery and revision surgery groups.

Five of 7 patients who experienced PJF after PLIF did not receive revision surgery after PCI. Considering that general anesthesia and open surgery are high-risk procedures for geriatric patients, our results suggest that non-surgical PCI could be a viable alternative treatment option for PJF.

SMC2017-01-011-001. Retrospectively registered 18 January 2017.

Abbreviations: PCI = percutaneous cement injection, PJF = proximal junctional failure, PLIF = posterior lumbar interbody fusion.

Keywords: lumbar interbody fusion, percutaneous cement injection, proximal junctional failure, vertebral fracture

1. Introduction

Posterior lumbar interbody fusion (PLIF) using pedicle screws in thoracolumbar spinal fusion surgery is often performed in cases of lumbar spondylolisthesis, spinal instability, and laminectomy for degenerative disc disease that is intractable to conservative treatment.^[1]

Several complications of PLIF have been described including intraoperative neurologic injury, dural tears, and infection. One major complication of PLIF is proximal junctional failure (PJF), and the incidence of which after PLIF was reported to be 5.6%.^[2,3] Increased junctional stress causes failure of soft tissues and ligaments, bones, and the bone implant interface; patients with PJF

Editor: Eric Bush.

This work was supported by the ICT R&D program of IITP/MSIP (B0101-17-1081, Development of ICT based software platform and service technologies for medical 3D printing applications) and by a grant of the Korea Health Technology R&D Project through the Korea Health Industry Development Institute (KHIDI), funded by the Ministry of Health & Welfare, Republic of Korea (grant number: HI16C1104).

This study protocol was approved by our Institutional Review Board. Informed consent was waived by the board due to retrospective study design. However, the patients that 'Case 4' and 'Case 7' gave written consent for their case details. All procedures performed in studies involving human participants were in accordance with the ethical standards of the institutional and/or national research committee and with the 1964 Helsinki Declaration and its later amendments or comparable ethical standards.

The patients that 'Case 4' and 'Case 7' gave written consent for their case details to be published.

The datasets generated and analyzed during this study are not publicly available due protection of privacy and medical confidentiality private but are available from the corresponding author on reasonable request and permission request of the patients.

The authors have no conflicts of interest to disclose.

^a Department of Physical and Rehabilitation Medicine, Kangbuk Samsung Hospital, ^b Department of Radiology, Samsung Medical Center, Sungkyunkwan University School of Medicine, ^c Seoul Jun Rehabilitation Clinic, Seoul Jun Rehabilitation Research Center, Seoul, Republic of Korea.

* Correspondence: Sang Jun Kim, Seoul Jun Rehabilitation Clinic, Seoul Jun Rehabilitation, Research Center, 2606 Nambusoonghwan-ro, Seocho-gu, Seoul 06737, Republic of Korea (e-mail: catedral.sjk@gmail.com).

Copyright © 2020 the Author(s). Published by Wolters Kluwer Health, Inc.

This is an open access article distributed under the terms of the Creative Commons Attribution-Non Commercial License 4.0 (CCBY-NC), where it is permissible to download, share, remix, transform, and buildup the work provided it is properly cited. The work cannot be used commercially without permission from the journal.

How to cite this article: Do JG, Kwon JW, Kim SJ. Effectiveness of percutaneous cement injection on proximal junctional failure after posterior lumbar interbody fusion: Preliminary study. *Medicine* 2020;99:2(e18682).

Received: 25 June 2019 / Received in final form: 4 December 2019 / Accepted: 7 December 2019

<http://dx.doi.org/10.1097/MD.00000000000018682>

experience severe pain, neurologic deficits, and ambulatory difficulties.^[4–6] PJJF is considered one of the most common reasons for revision surgery. Importantly, revision surgery for PJJF after PLIF may cause perioperative complications and impose an economic burden. Theologis et al reported that revision operations for PJJF after long thoracolumbar fusions are associated with an average direct cost of 55,547 USD per case.^[7] Hart et al estimated an average cost of 77,432 USD for revision surgery after PJJF.^[8]

Considering the severity of the complications, several methods have been introduced for the prevention of PJJF after PLIF. Preventive cement augmentation is a popular method to increase screw fixation strength. Aydogan et al reported that pedicle screw fixation, augmented by vertebroplasty in segments proximal and distal to the instrumented segments, could be a good alternative method for fixation and fusion, while also preventing proximal and distal junctional fractures.^[9] Kebaish et al reported that prophylactic percutaneous vertebroplasty at the upper instrumented level and its supra-adjacent vertebra reduced the incidence of junctional fractures after long posterior spinal instrumentation in an axially loaded cadaveric model.^[10] Recently, percutaneous vertebroplasty was used to enhance pullout resistance in pedicle screw-by-screw augmentation.^[11,12] However, there have been few reports exploring the use of percutaneous cement injection (PCI) to block the progression of vertebra collapse and to relieve symptoms of PJJF after PLIF.

Based on previous reports, and considering the perioperative complications and economic burden associated with revision surgery, we believe that PCI in the fractured vertebra body and/or intervertebral disc could be therapeutic strategy alternative to revision surgery for PJJF after PLIF. Therefore, the aim of our study was to evaluate the effectiveness of PCI for PJJF in PLIF patients requiring surgical revision.

2. Methods

2.1. Patients

We retrospectively reviewed 7 cases in which surgical revision was required for PJJF after PLIF, but PCI was performed instead of revision surgery, from October 2010 to August 2015. The causes of PLIF included degenerative spinal stenosis in 3 patients and spinal stenosis with degenerative spine scoliosis in 4 patients. We defined PJJF as vertebral fracture of the upper instrumented vertebrae and/or instrumented vertebrae, with compatible clinical symptoms such as mechanical low back pain with bony tenderness at the failure area and neurologic symptoms. Revision surgery was considered necessary in all cases because the patients complained of severe low back pain with bony tenderness at the failure area, which was not controlled conservatively with physiotherapy and pain medication. Patients received PCI at the collapsed vertebral body and supra-adjacent vertebra, with or without intervertebral disc intervention, instead of revision surgery after discussion with orthopedic surgeons and provision of patient consent. None of the patients took steroid medication during the study period. In this study, “discoplasty” and “vertebroplasty” were collectively referred to as “percutaneous cement injection”.

2.2. Percutaneous cement injection

Each procedure was performed using biplane digital subtraction angiography (Allura Xper FD 20/10; Philips, Best, Netherlands). In the angiography room, all patients were positioned prone on the table, and were conscious under local anesthesia with 1%

lidocaine. After anesthesia of the intervertebral disc with localized anesthetics under fluoroscopic control, a skin incision was made and a 13-gauge trocar needle (Osteo-site; Cook, Bloomington, IN, USA) was inserted into the disc space. Under lateral projection control, the needle was adjusted to the appropriate depth. After placement of the needle into the anterior middle portion of the intervertebral disc under fluoroscopic control, liquid and powder polymethylmethacrylate (DePuy International, Leeds, UK) were mixed and injected carefully under biplane fluoroscopic control. The flow of cement was monitored during the procedure to avoid leakage posteriorly into the spinal canal and laterally into the extraforaminal space. The volume of cement required during PCI was determined by the filling images and the degree of resistance to the cement injection. Injection of cement was stopped in the event of cement leakage into the epidural space. Prior to needle withdrawal, the material was allowed to fully cure to avoid dragging cement into the soft tissues.

In cases of cement injection into the vertebral body via an inserted screw, an 11- or 13-gauge trocar needle was inserted into the fractured portion of the vertebral body using a transpedicular (for lumbar) or parapedicular (for thoracic) approach, without touching the pedicle screws (Fig. 1).

2.3. Evaluation of radiographic findings

In this study, 2 different radiographic parameters (wedging rate (%) of the fractured vertebral body and local kyphosis angle) were used, as in the previous study. The wedging rate (%) was measured by comparing the anterior and posterior distances of the fractured vertebral body. The local kyphosis angle was defined as the angle between 1 level above and 1 level below the fractured vertebra (Fig. 2).^[13] All radiographic measurements were performed by 1 specialist radiologist with experience of more than 10,000 PCI procedures. Radiological measurements were performed before and immediately after PCI, and were also repeated 18 months after the PCI.

2.4. Group classification

Patients who underwent revision surgery, because their pain was not reduced by PCI or recurred, were as assigned to the revision surgery group. Patients who did not undergo revision surgery after the PCI within 18 months were assigned the non-revision surgery group.

2.5. Statistical analyses

The Wilcoxon signed rank test with *Bonferroni* correction for multiple comparisons was performed to determine the anterior wedging rate and local kyphosis angle before, immediately after, and 18 months after PCI. Comparison between groups was performed using a Mann–Whitney *U* test for continuous variables and Fisher exact test for categorical variables. SPSS (version 23.0, IBM Corp., Chicago, IL, USA) was used for the statistical analysis and a *P*-value less than .05 was considered clinically significant.

This study protocol was approved by our Institutional Review Board. Informed consent was waived by the board due to retrospective study design. However, the patients that “Case 4” and “Case 7” gave written consent for their case details. There were no commercial conflicts of interest related to this study.

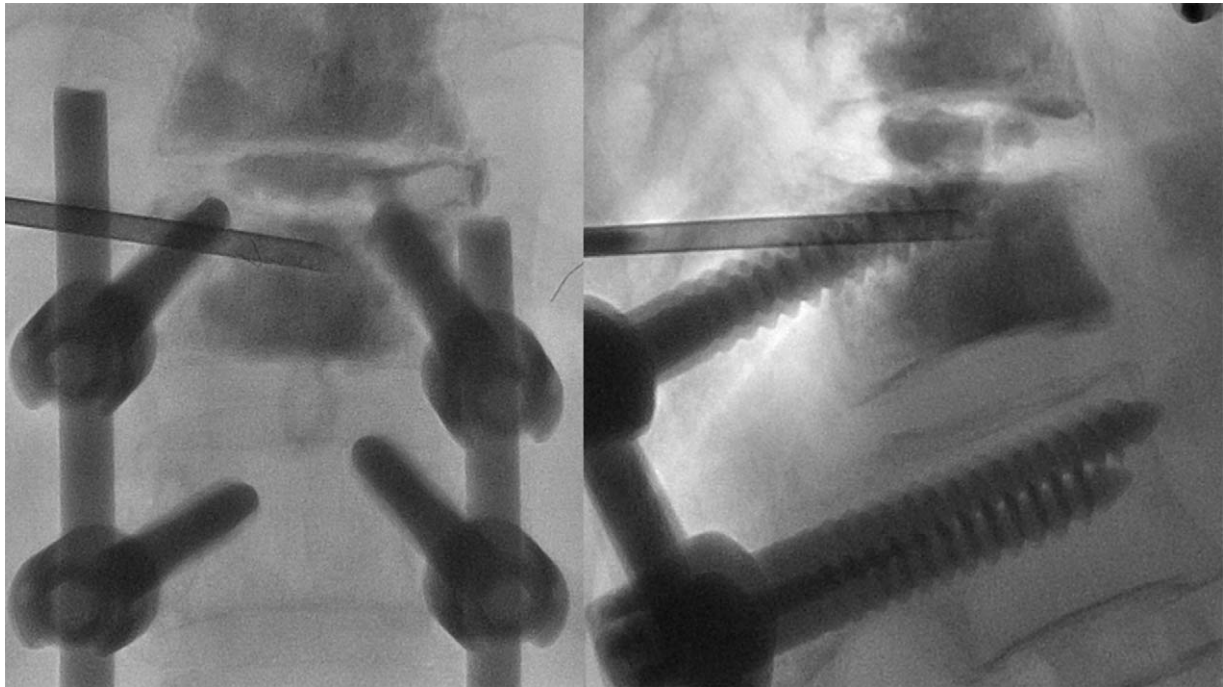


Figure 1. Percutaneous cement injection was performed by inserting a trocar needle into the fractured portion of lumbar vertebra through a transpedicular approach.

3. Results

Seven patients received PCI (all women, aged 73.0 ± 3.6 years). Except for 1 patient, PJF occurred within 6 months after PLIF. PJF occurred in 1 case due to trauma. Four of 7 patients

underwent anterior and posterior approaches upon initial PLIF (Table 1). All patients were treated with PCI within 2 months of symptom onset. The amount of cement used in the procedure was 10.4 ± 1.5 ml (range, 8.0 to 12.0 ml). The injection site and

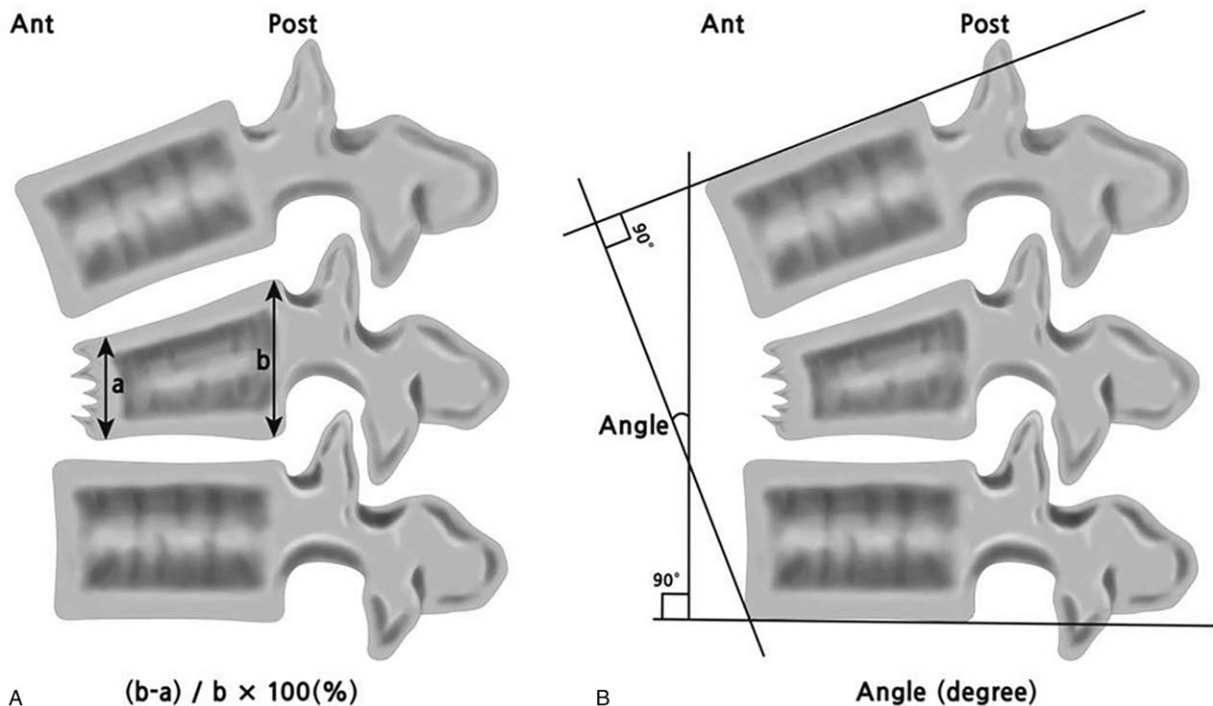


Figure 2. Two different radiographic parameters were used. (A) The wedging rate was measured by comparing the anterior and posterior distances of a fractured vertebral body. (B) The local kyphosis angle was defined as the angle between 1 level above and 1 level below the fractured vertebra.

Table 1
Epidemiologic and clinical characteristics of patients.

	Age (year)	Sex	Time to failure (mo)	Symptom to PCI (mo)	Hx of Trauma	Initial PLIF approach	Fusion level	Failure level
Case 1	80	F	2	1	Yes	Post	L2-S1	L1-L2
Case 2	74	F	5	1	None	Ant & Post	L1-S1	T12-L1
Case 3	73	F	1	1	None	Ant & Post	L2-S1	L1-L2
Case 4	70	F	8	1	None	Post	T12-S1	T11-T12
Case 5	73	F	1	1	None	Ant & Post	L1-S1	T12-L1
Case 6	72	F	3	1	None	Ant & Post	T11-S1	T10-T11
Case 7	69	F	2	1	None	Post	L1-S1	T12-L1

Ant = anterior, F = female, Hx = history, Mo = month, PCI = percutaneous cement injection, PLIF = posterior lumbar interbody fusion, Post = posterior.

Table 2
Cement injection sites and volumes of percutaneous cement injection.

	Injection sites	Injection volume (ml)	F/U duration (month)
Case 1	L1 and L1-L2	8	18
Case 2	T11, T12 and T12-L1	12	18
Case 3	L1, L2 and L1-L2	11.5	20
Case 4	T11 and T11-T12	10	19
Case 5	T12, L1 and T12-L1	11	19
Case 6	T10, T11 and T10-T11	11.5	12
Case 7	T12, L1 and T12-L1	9	7

F/U = follow up.

Table 3
Radiological findings pre and after percutaneous cement injection.

	Immediate			Last		
	Pre-PCI (n=7)	after PCI (n=7)	P value	Pre-PCI (n=7)	follow-up (n=7)	P value
Anterior wedging rate (%)	34.5±6.7	25.9±8.7	.018	34.5±6.7	36.7±10.8	1.00
Local kyphosis (angle)	25.1±11.3	13.6±5.2	.028	25.1±11.3	31.2±7.5	.237

Data are presented as mean ± standard deviation.
PCI = percutaneous cement injection.

Table 4
Radiological findings between non-revision surgery group and revision surgery group.

	Non-revision surgery group (n=5)	Revision surgery group (n=2)	P value
Anterior wedging rate (%)			
Pre-PCI	33.5±7.0	36.9±7.5	.857
Immediate after PCI	26.0±10.1	25.6±6.9	.571
Last followed up	32.5±9.7	47.2±4.6	.190
Local kyphosis (angle)			
Pre-PCI	21.4±6.7	34.3±18.6	.571
Immediate after PCI	14.2±6.2	12.1±2.4	.571
Last followed up	28.7±7.3	37.6±2.8	.190

Data are presented as mean ± standard deviation.
PCI = percutaneous cement injection.

volume in each patient are presented in Table 2. Immediately after PCI, all patients showed pain reduction compared to before the procedure. Among 7 patients, 2 patients (cases 6 and 7) underwent revision surgery due to progression of vertebral body collapse and recurrence of intractable low back pain.

Immediately after cement injection, the anterior wedging rate (%) improved significantly ($P < .05$). However, at the last follow-up, the anterior wedging rate (%) was not significantly different compared to pre-PCI. In addition, immediately after PCI, the local kyphosis angle was significantly different ($P < .05$). However, at the last follow-up, the local kyphosis angle was not significantly different compared to pre-PCI (Table 3).

The anterior wedging rates (%) and local kyphosis angle, at pre-PCI, immediate after PCI, and at final follow-up, were not significantly different between the non-revision surgery and revision surgery groups ($P > .05$) (Table 4). Age, time to failure, and injection volume were not significantly different between the 2 groups ($P > .05$) (Table 5). There were no cases of extravasation or subsequent neural injury after PCI.

3.1. Representative case description

3.1.1. Case 4. A 70-year-old woman had undergone PLIF at the L3-S1 level in June 2009 for spinal stenosis and degenerative lumbar scoliosis. In September 2014, she visited the outpatient clinic in our hospital due to low back pain after a fall. Radiologic examination revealed a compression fracture of the L1 vertebra, and she underwent vertebroplasty at the L1 level. She subsequently underwent PLIF extension at the T12-L3 level on December 2014 for persistent back pain. In August 2015, X-ray

Table 5
Epidemiologic and clinical findings of non-revision surgery group and revision surgery group.

	Non-revision surgery group (n=5)	Revision surgery group (n=2)	P value
Age (years)	74.0±3.7	70.5±2.1	.190
Time to failure (month)	3.4±3.0	2.5±0.7	.857
Injection volume (ml)	10.5±1.6	10.4±1.5	.857
Failure level			.714
T10-T11	0	1	
T11-T12	1	0	
T12-L1	2	1	
L1-L2	2	0	

Data are presented as mean ± standard deviation.

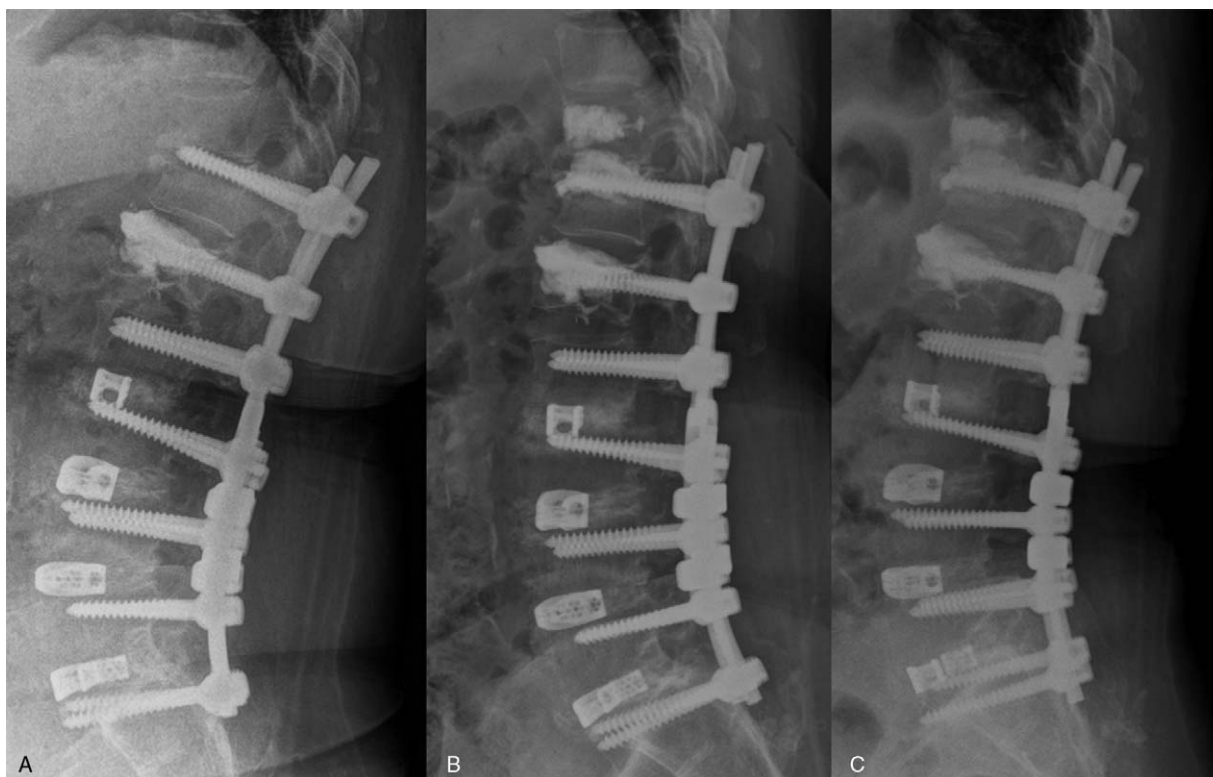

Figure 3. A 70-year-old woman with proximal junctional failure after posterior lumbar interbody fusion (case 4). (A) T11 proximal junctional fracture with penetration of T12 superior endplate by superior pedicle screw (case 4) revealed on X-ray. (B) Percutaneous cement injection was performed at the level of the T11 vertebral body and the T11-T12 disc space. (C) The thoracolumbar collapse showed minimal progression at the last follow-up.

revealed T11 PJF with penetration of the T12 superior endplate by a superior pedicle screw (Fig. 3A). PCI was performed at the level of the T11 vertebral body and the T11-T12 disc space to prevent collapse (Fig. 3B). The last follow-up visit took place in March 2017 and the thoracolumbar collapse showed minimal progression with only mild low back pain (Fig. 3C).

3.1.2. Case 7. A 69-year-old woman underwent PLIF, at the L1-S1 level, and lumbar kyphoscoliosis in May 2015 for correction of spinal stenosis, instability of multiple segments of the lumbosacral spine, and degenerative kyphoscoliosis of the lumbar spine. In July 2015, she complained of buttock and low back pain. A T12, L1 vertebral compression fracture, and L1 screw pullout to the superior endplate were revealed on X-ray (Fig. 4A). She underwent PCI in the T12 and L1 vertebral bodies, and discoplasty at the T12-L1 level (Fig. 4B). Progression of local kyphosis and T12, L1 vertebral body fractures was seen on X-ray at the last follow-up (Fig. 4C). In February 2016, she underwent PLIF extension at the T3-L1 level because of severe back pain with neurogenic claudication.

4. Discussion

The current study introduces therapeutic PCI in PJF after PLIF in patients requiring revision surgery. Five of 7 patients who experienced PJF after PLIF did not receive revision surgery after PCI. There were only 2 cases in which revision surgery was performed after PCI. In the other 5 cases, the pain caused by the PJF was decreased, and further collapse of the vertebral body was

prevented after PCI. Although revision surgery is the gold standard treatment for PJF, surgical treatment of elderly patients can be challenging due to the high risk of complications (as a result of patient comorbidities). In patients who are not suitable for surgery, minimally invasive procedures are more acceptable. Our study suggests that PCI could be considered an alternative treatment option before revision surgery for PJF after PLIF.

Several mechanisms for PJF have been proposed, including compression fracture and instrumentation failure at proximal structure.^[9,14] In previous studies, vertebroplasty was used to treat painful vertebral fractures, which helped stabilize the fractured vertebra and improved stability.^[15,16] In a study, osteoporotic patients requiring spine surgery, pedicle screw fixation with vertebroplasty augmentation and vertebroplasty in segments proximal and distal to the instrumented segments, showed no proximal and distal junctional segment fractures during 2 years of follow-up.^[9] In addition, PCI was performed safely and effectively for loosening of spine arthrodesis after failed interbody fusion.^[17-19] In previous study, 10 patients with loosened pedicle screw and instrumentation-associated vertebral fracture received percutaneous vertebroplasty, and has shown that the mean pain score improved significantly after PCI and only 2 patients needed revision open surgery.^[18] In the present study, we found that PCI restored the vertebral body immediately after injection. This is consistent with previous results showing that vertebroplasty reduces the local kyphosis angle by 3.3° to 7.4° in cases of osteoporotic vertebral compression.^[20,21] In a line with previous reports, our results showed an 11.5° reduction in local kyphosis immediately after PCI. Improving stability by PCI

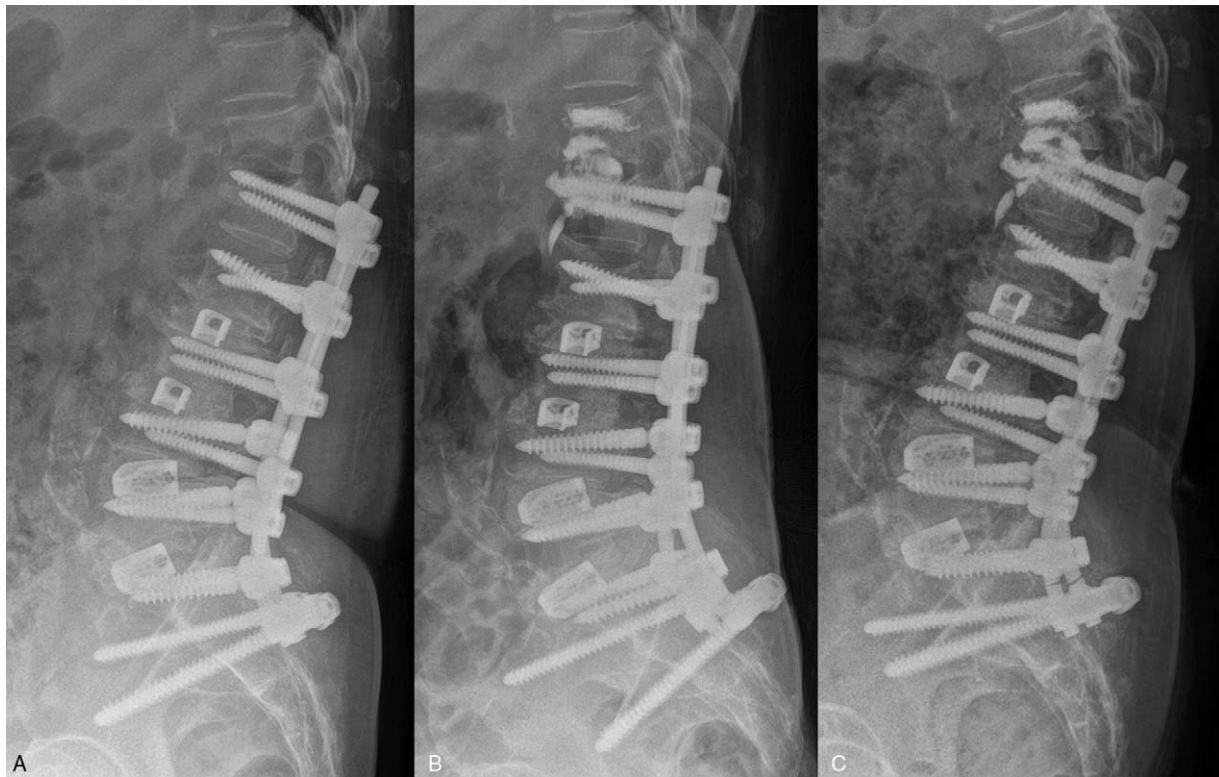

Figure 4. A 69-year-old woman with proximal junctional failure after posterior lumbar interbody fusion (case 7). (A) T12, L1 vertebral body compression fracture and L1 screw pull-out to superior endplate revealed on X-ray. (B) Percutaneous cement injection was performed at the level of the T12 and L1 vertebra bodies and discoplasty at the T12-L1 level. (C) Progression of local kyphosis and T12, L1 vertebral body fractures was seen on X-ray at the last follow-up.

in the segments of an instrumented body, the adjacent vertebra, and intervertebral disc is reasonable for treating PJF with proximal junctional fracture.

The indications for revision surgery after PJF are, including severe localized pain ineffective to nonsurgical management, new neurologic deficit, or progressive symptomatic deformity.^[6] But, the decision criteria for revision surgery or PCI after PLIF are not standardized. Hart et al reported the factors that influenced the decision to perform revision surgery after PJF, including traumatic etiology, severe proximal junctional kyphosis angle, and use of a combined posterior and anterior approach at initial surgery.^[4] In our study, epidemiologic and clinical feature such as age, time to failure, level of failure, volume of injection, and radiological features, including changes in anterior wedging rate (%) and local kyphosis angle, were not significantly different between the non-revision and revision surgery groups. We could not identify the factors affecting the results of PCI after PJF because of our small sample size. To identify the factors that affect the prognosis of PCI in PJF, more cases must be reviewed.

Five patients showed good outcomes after PCI, but the remaining 2 cases (without traumatic etiology) showed poor outcomes and had to undergo revision surgery within 1 year after PCI. Revision surgery was inevitable because the failures occurred at the same level as the initial PJF and conservative management was not effective. Although radiological findings were not significantly improved at the final follow-up, in 5 of 7 cases the low back pain decreased without revision surgery. Filling in the vertebral body and/or disc with cement reduces spinal instability, which in turn decreases mechanical low back pain and prevents further vertebral collapse. Few studies have

assessed long-term changes in radiologic finding or evaluated the extent to which the amount of height correction and degree of improvement are correlated. Further long-term follow-up studies are required because PCI does not completely prevent vertebral collapse.

A higher incidence of osteopenia and/or osteoporosis is a risk factor for PJF, due to fracture or failure of pedicle screws, for example.^[9] Evaluation and management of osteoporosis and osteopenia are important to prevent PJF, which is of significant clinical importance, and bone mineral density studies should be a routine component of evaluations of patients considered candidates for PLIF. Appropriate measures to strengthen the bone matrix, including smoking cessation, increased dietary intake of calcium and vitamin D, physiotherapy, and the use of bisphosphonates, calcitonin, or estrogen agonists is required.^[1,9,22,23] However, when performing PJF revision surgery, there is insufficient time for the medical treatment used for osteoporosis to heal the fracture sites, since bone marrow density has a tendency to improve only after long-term medical treatment. PCI in instrumented segments and adjacent uninstrumented segments can be a good clinical approach to provide prompt spinal stability in cases of PJF with osteoporosis.

In our study, we determined the cement volume required based on filling images and the degree of resistance to the cement injection. Many studies have sought to determine the most appropriate cement volume in PCI, although the optimal volume remains unclear. Theoretically, a higher volume could facilitate mechanical restoration of the vertebra. Fu et al reported a positive dose-response relationship between cement volume and pain reduction.^[24] Meanwhile, Kaufmann et al reported that for more

caudal vertebral levels, the presence of an intravertebral cleft and severe vertebral compression were associated with the requirement for a larger amount of cement.^[25] However, there was no significant association between the volume of cement injected and clinical outcomes, including post-procedure pain and medication use, between the 1-week and 2-year follow-up.^[26] Thus, it seems that cement volume is not associated with an improvement in clinical symptoms. In our study, 10.4 ± 1.5 ml (range, 8.0 to 12.0 ml) of cement was used in the procedures and there was no association between injection volume and clinical outcomes. Further studies are required to determine the optimal PCI volume and methods to stabilize vertebrae in compressive vertebral fractures.

There are several complications after PCI. The most common complication is cement leakage, which occur on paravertebral soft tissue, into the intervertebral disk, spinal canal, and artery vein.^[27] In case of PCI after PLIF, the instrumentation could interfere of visualization during cement injection. To reduce the risk of extravasation of cement, we performed multidirectional and multiple fluoroscopic images to proper visualization and injection of cement was stopped immediately in the event of cement reaches the posterior vertebral wall.

There were several limitations to this study. First, the follow-up period was only 18 months, which is a relatively short period in which to determine the long-term effects of PCI in PJF. The average follow-up period for PJF in other studies was 2 years; thus, the average follow-up in our study was relatively short.^[6,7] Second, all patients of our study were female. The major risk factors of PJF have been reported that older age (>55 years), osteoporosis, high body mass index, large abnormal preoperative sagittal parameters.^[14] However, female has not been found to be important risk factor in the development of PJF after PLIF.^[28,29] In this regard, predominance of female might not to affect the results of our study. However, the small sample size and female predominance are limitations of our study. Moreover, due to the retrospective study design, tools, and questionnaires for quantifying low back pain, such as the Oswestry disability index, were not used. To validate the rationale and indications for PCI treatment in PJF after PLIF, large-scale, randomized, controlled studies with standardized evaluation parameters are required.

5. Conclusion

This study is clinically important because it describes a non-surgical treatment for cases of PJF after PLIF requiring surgical revision. In our study, 5 of 7 patients who experienced PJF after PLIF did not require revision surgery after PCI. Considering that general anesthesia and open surgery are high-risk procedures for geriatric patients, our results suggest that non-surgical PCI could be a viable alternative treatment option for PJF.

Author contributions

Conceptualization: Jong Geol Do, Sang Jun Kim, Jong Won Kwon.

Data curation: Jong Geol Do, Sang Jun Kim, Jong Won Kwon.

Formal analysis: Jong Geol Do.

Methodology: Jong Geol Do, Sang Jun Kim, Jong Won Kwon.

Project administration: Sang Jun Kim, Jong Won Kwon.

Software: Jong Geol Do.

Supervision: Sang Jun Kim.

Writing – original draft: Jong Geol Do.

Writing – review & editing: Jong Geol Do, Sang Jun Kim, Jong Won Kwon.

Jong Geol Do orcid: 0000-0001-8001-7782.

References

- DiPaola CP, Molinari RW. Posterior lumbar interbody fusion. *J Am Acad Orthop Surg* 2008;16:130–9.
- Chrastil J, Patel AA. Complications associated with posterior and transforaminal lumbar interbody fusion. *J Am Acad Orthop Surg* 2012;20:283–91.
- Hostin R, McCarthy I, O'Brien M, et al. Incidence, mode, and location of acute proximal junctional failures after surgical treatment of adult spinal deformity. *Spine (Phila Pa 1976)* 2013;38:1008–15.
- Hart R, McCarthy I, O'Brien M, et al. Identification of decision criteria for revision surgery among patients with proximal junctional failure after surgical treatment of spinal deformity. *Spine (Phila Pa 1976)* 2013;38:E1223–7.
- Yagi M, Rahm M, Gaines R, et al. Characterization and surgical outcomes of proximal junctional failure in surgically treated patients with adult spinal deformity. *Spine (Phila Pa 1976)* 2014;39:e607–14.
- Kim YC, Lenke LG, Bridwell KH, et al. Results of revision surgery for proximal junctional kyphosis following posterior segmental instrumentation: Minimum 2-year postrevision follow-up. *Spine (Phila Pa 1976)* 2016;41:e1444–52.
- Theologis AA, Miller L, Callahan M, et al. Economic impact of revision surgery for proximal junctional failure after adult spinal deformity surgery: a cost analysis of 57 operations in a 10-year experience at a major deformity center. *Spine (Phila Pa 1976)* 2016;41:E964–72.
- Hart RA, Prendergast MA, Roberts WG, et al. Proximal junctional acute collapse cranial to multi-level lumbar fusion: a cost analysis of prophylactic vertebral augmentation. *Spine J* 2008;8:875–81.
- Aydogan M, Ozturk C, Karatoprak O, et al. The pedicle screw fixation with vertebroplasty augmentation in the surgical treatment of the severe osteoporotic spines. *J Spinal Disord Tech* 2009;22:444–7.
- Kebaish KM, Martin CT, O'Brien JR, et al. Use of vertebroplasty to prevent proximal junctional fractures in adult deformity surgery: a biomechanical cadaveric study. *Spine J* 2013;13:1897–903.
- Charles YP, Pelletier H, Hydiar P, et al. Pullout characteristics of percutaneous pedicle screws with different cement augmentation methods in elderly spines: An in vitro biomechanical study. *Orthop Traumatol Surg Res* 2015;101:369–74.
- Mattei TA, Mendel E, Bourekas EC. Postoperative cement augmentation after 360-degree fixation for highly unstable vertebral fractures in patients with multiple myeloma: a technical note on delayed trans-instrumentation vertebroplasty. *World Neurosurg* 2014;82:537e531-538.
- Watanabe K, Lenke LG, Bridwell KH, et al. Proximal junctional fracture in adults after spinal deformity surgery using pedicle screw constructs: analysis of morphological features. *Spine (Phila Pa 1976)* 2010;35:138–45.
- Lee J, Park YS. Proximal Junctional Kyphosis: Diagnosis, Pathogenesis, and Treatment. *Asian Spine J* 2016;10:593–600.
- Hurley MC, Kaakaji R, Dabus G, et al. Percutaneous vertebroplasty. *Neurosurg Clin N Am* 2009;20:341–59.
- Sebaaly A, Nabhane L, Issa El Khoury F, et al. Vertebral Augmentation: State of the Art. *Asian Spine J* 2016;10:370–6.
- Amoretti N, Bertrand AS, Gallo G, et al. Percutaneous consolidation of loosened spine arthrodesis under CT and fluoroscopy guidance by radiologists: a new useful technique. *Eur Radiol* 2015;25:1135–9.
- Fu TS, Li YD. Fluoroscopy-guided percutaneous vertebroplasty for symptomatic loosened pedicle screw and instrumentation-associated vertebral fracture: an evaluation of initial experiences and technical note. *J Neurosurg Spine* 2018;1–8.
- Yun DJ, Hwang BW, Oh HS, et al. Salvage percutaneous vertebral augmentation using polymethyl methacrylate in patients with failed interbody fusion. *World Neurosurg* 2016;95:618.e613–20.
- Boonen S, Wahl DA, Nauroy L, et al. Balloon kyphoplasty and vertebroplasty in the management of vertebral compression fractures. *Osteoporos Int* 2011;22:2915–34.
- Teng MM, Wei CJ, Wei LC, et al. Kyphosis correction and height restoration effects of percutaneous vertebroplasty. *AJNR Am J Neuro-radiol* 2003;24:1893–900.

- [22] Lee JH, Kim JU, Jang JS, et al. Analysis of the incidence and risk factors for the progression of proximal junctional kyphosis following surgical treatment for lumbar degenerative kyphosis: minimum 2-year follow-up. *Br J Neurosurg* 2014;28:252–8.
- [23] Nguyen NL, Kong CY, Hart RA. Proximal junctional kyphosis and failure—diagnosis, prevention, and treatment. *Curr Rev Musculoskelet Med* 2016;9:299–308.
- [24] Fu Z, Hu X, Wu Y, et al. Is There a dose-response relationship of cement volume with cement leakage and pain relief after vertebroplasty? *Dose Response* 2016;14:1559325816682867.
- [25] Kaufmann TJ, Trout AT, Kallmes DF. The effects of cement volume on clinical outcomes of percutaneous vertebroplasty. *AJNR Am J Neuro-radiol* 2006;27:1933–7.
- [26] Nieuwenhuijse MJ, Bollen L, van Erkel AR, et al. Optimal intravertebral cement volume in percutaneous vertebroplasty for painful osteoporotic vertebral compression fractures. *Spine (Phila Pa 1976)* 2012;37:1747–55.
- [27] Saracen A, Kotwica Z. Complications of percutaneous vertebroplasty: An analysis of 1100 procedures performed in 616 patients. *Medicine (Baltimore)* 2016;95:e3850.
- [28] Yagi M, Akilah KB, Boachie-Adjei O. Incidence, risk factors and classification of proximal junctional kyphosis: surgical outcomes review of adult idiopathic scoliosis. *Spine (Phila Pa 1976)* 2011;36:E60–8.
- [29] Wang H, Ma L, Yang D, et al. Incidence and risk factors for the progression of proximal junctional kyphosis in degenerative lumbar scoliosis following long instrumented posterior spinal fusion. *Medicine (Baltimore)* 2016;95:e4443.