



Cerebrospinal fluid hypovolemia syndrome mimicking ocular myasthenia gravis: A case report

Akihiro Shinkai^a, Yasuhiro Shinmei^{a,*}, Akihiro Takahashi^b, Kayoko Nakamura^a, Yoshiaki Tagawa^a, Shinki Chin^a, Susumu Ishida^a

^a Department of Ophthalmology, Faculty of Medicine and Graduate School of Medicine Hokkaido University, Sapporo, Japan

^b Higashi-Sapporo Neurology and Neurosurgery Clinic, Sapporo, Japan

ARTICLE INFO

Keywords:

Cerebrospinal fluid hypovolemia syndrome
Diplopia
Ptosis
Diurnal fluctuation
Myasthenia gravis
And epidural blood patch therapy

ABSTRACT

Purpose: Cerebrospinal fluid hypovolemia syndrome (CHS) is a rare clinical entity that can be caused by spontaneous cerebrospinal fluid (CSF) leakage. The aim of this study is to report a rare case of CHS after a traffic accident in a patient who presented with diplopia and ptosis with fluctuation and was initially diagnosed with ocular myasthenia gravis.

Observations: A 29-year-old man exhibited fluctuating left ptosis and diplopia after a traffic accident. Although he was suspected of having myasthenia gravis and was treated using oral pyridostigmine bromide, his symptoms did not improve. He also had orthostatic headaches and malaise after the accident. His symptoms were suspected to be associated with traumatic cerebrospinal fluid hypovolemia. After 1000-mL fluid replacement, his diplopia and ptosis improved, and orbital T2-weighted MRI detected a high-signal zone around the optic nerve. We diagnosed him with oculomotor nerve paresis associated with cerebrospinal fluid hypovolemia. The symptoms, including ptosis, diplopia, orthostatic headaches, and malaise, disappeared after epidural blood patch therapy.

Conclusions and Importance: When treating patients with fluctuating ocular symptoms, such as diplopia and ptosis, who have a history of trauma and orthostatic headaches, the possibility of CHS should be considered in the differential diagnosis.

1. Introduction

Cerebrospinal fluid hypovolemia syndrome (CHS) is a rare clinical entity that can be caused by spontaneous cerebrospinal fluid (CSF) leakage.^{1–3} The symptoms may be preceded by trauma, and patients often present with postural headaches as the main symptom and/or nausea, vomiting, and occasionally ocular manifestations, including blurred vision, photophobia, double vision, visual field defects, and abnormal eye movements.^{4–10} However, the mechanisms underlying these ocular manifestations are not well understood.

We report a rare case of CHS after a traffic accident in a patient who presented with diplopia and ptosis with fluctuation and was initially diagnosed with ocular myasthenia gravis.

2. Case report

A 29-year-old man exhibited left ptosis and diplopia, and was referred to our neuro-ophthalmology clinic. Six months ago, his car crashed into a roadside tree. He developed orthostatic headaches and malaise after the accident. It was difficult for him to open his eyes, and the out-of-focus feeling gradually worsened over time after waking up and recovered after lying down. Although his previous doctor suspected myasthenia gravis and he was treated using oral pyridostigmine bromide, his symptoms did not improve.

On examination at the first visit, his best-corrected decimal visual acuity was 1.5 in both eyes. The pupillary light reflex was prompt in both eyes. Although no notable limitation in extraocular muscle movement was found in either eye, on alternate prism cover testing, 8 prism

Abbreviations: Cerebrospinal fluid hypovolemia syndrome, (CHS); cerebrospinal fluid, (CSF); spontaneous intracranial hypotension, (SIH); magnetic resonance imaging, (MRI); MR myelography, (MRM); epidural blood patch, (EBP).

* Corresponding author. Department of Ophthalmology, Hokkaido University Graduate School of Medicine North 15, West 7, Kita-ku, Sapporo, 060-8638, Japan.
E-mail addresses: shinkai@huhp.hokudai.ac.jp (A. Shinkai), yshinmei@med.hokudai.ac.jp (Y. Shinmei), ataka@tenor.ocn.ne.jp (A. Takahashi), chibichibitank555@gmail.com (K. Nakamura), yocchinn0127@med.hokudai.ac.jp (Y. Tagawa), schin@med.hokudai.ac.jp (S. Chin), ishidasu@med.hokudai.ac.jp (S. Ishida).

<https://doi.org/10.1016/j.ajoc.2022.101478>

Received 20 August 2021; Accepted 8 March 2022

Available online 15 March 2022

2451-9936/© 2022 The Authors. Published by Elsevier Inc. This is an open access article under the CC BY-NC-ND license (<http://creativecommons.org/licenses/by-nc-nd/4.0/>).

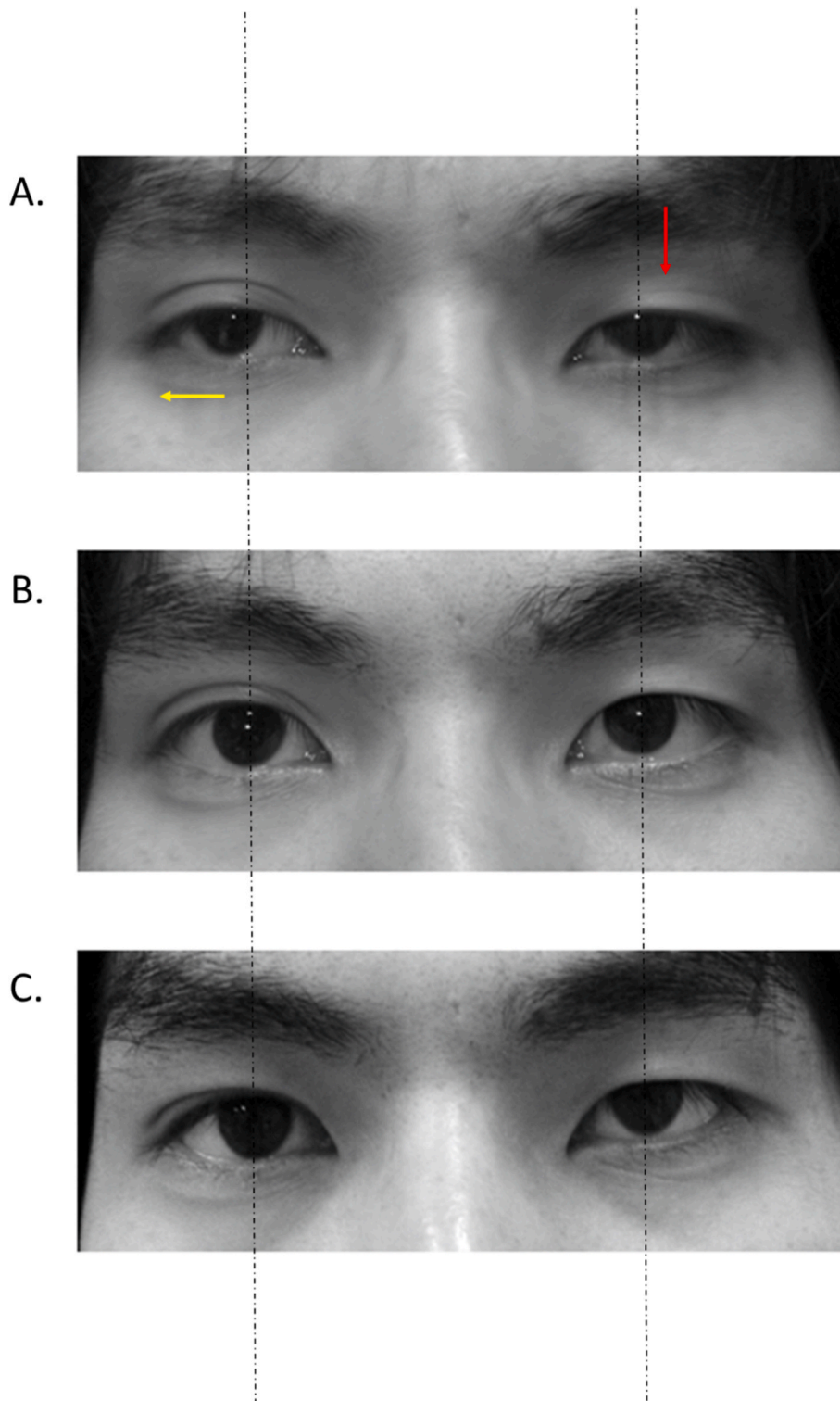


Fig. 1. (A) Face photograph before fluid replacement. Exotropia of the right eye (yellow arrow) and ptosis of the left eye (red arrow) were observed. Photographs after fluid replacement (B) and after epidural blood patch (EBP) therapy (C). Improvement in right exotropia and left ptosis is shown in both B and C. The dashed lines represent the center of both pupils in the orthophoric position. . (For interpretation of the references to colour in this figure legend, the reader is referred to the Web version of this article.)

diopeters of left exotropia and 4 prism diopeters of right exotropia were noted at distance. His left ptosis is shown in Fig. 1A. Slit lamp and fundus examinations yielded normal findings in both eyes. Blood test results were unremarkable. The anti-acetylcholine receptor antibody and edrophonium tests were also negative.

Based on his history of trauma, we suspected that his symptoms were not associated with myasthenia gravis, but with traumatic CHS. We then laid the patient on the bed in the Trendelenburg position (head lower than feet) and performed 1000 mL (500 mL of lactated Ringer's solution

and 500 mL of maintenance transfusion) of rapid intravenous fluid replacement within 2 hours in order to increase the intracranial CSF volume (fluid replacement test), and observed whether these symptoms improved.

Immediately after fluid replacement, his headache and malaise improved. Diplopia and ptosis also improved. The photo after fluid replacement is shown in Fig. 1B. His eye position became orthophoric and left ptosis improved.

Orbital MRI was performed before and after fluid replacement to

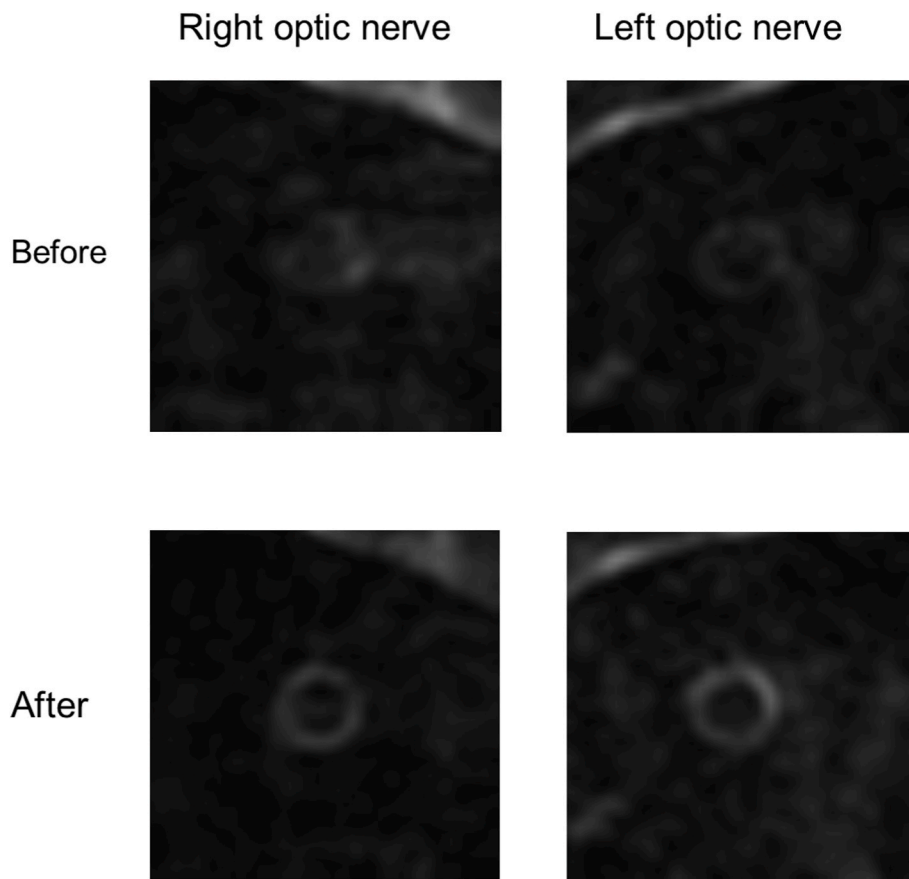


Fig. 2. Orbital MRI (fat saturated T2-weighted). The images were taken 15 mm posterior to the eyeball, including the optic nerve and optic nerve sheath. The right and left optic nerves were imaged individually in the coronal-oblique plane to ensure the slices were orthogonal to the longitudinal axis. The cerebrospinal fluid (CSF) between them was detected as a circular hyper-intensity. The MR images around the optic nerve before and after fluid replacement are shown. After fluid replacement, the high-signal zone around the optic nerve indicating CSF increased.

A. Before EBP

B. After EBP

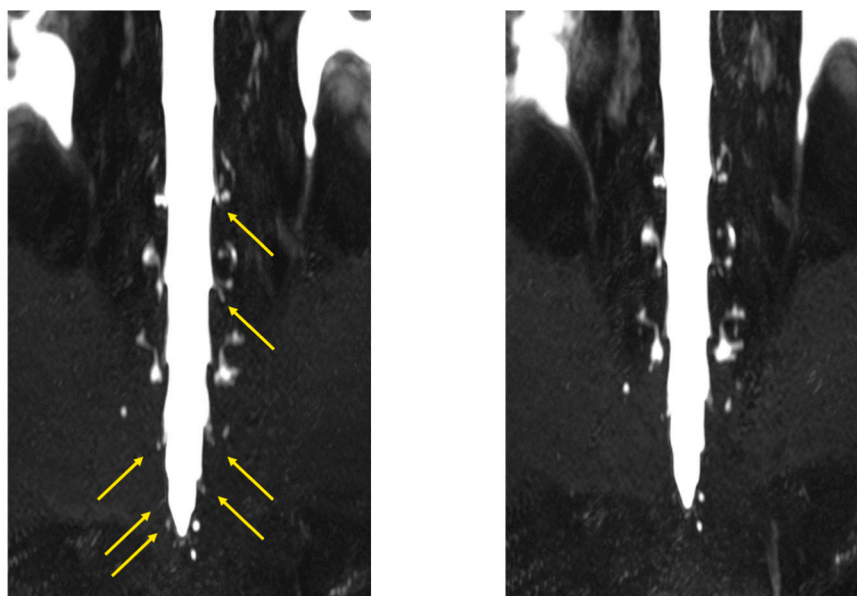


Fig. 3. Lumbar MR myelography (MRM) before and after EBP therapy. CSF space expansions at multiple nerve root sleeves with high-intensity signals were identified in the lumbar sacral region on MRM before EBP therapy (A). After EBP, these hyper-intensities decreased or disappeared.

evaluate the change in CSF with reference to the previous report.¹¹ The images shown in Fig. 2 were taken 15 mm posterior to the eyeball, including the optic nerve and optic nerve sheath. The CSF between them was detected as a circular hyper-intensity. After fluid replacement, the

high-signal zone around the optic nerve increased.

Next, MR myelography (MRM) was performed for the CSF leakage test. Although no notable CSF leak was detected on the first MRM (Fig. 3A), epidural blood patch (EBP) therapy was performed for the

clinical diagnosis and at the patient's request. The temporary improvement in symptoms after fluid replacement became permanent after EBP, and all symptoms, such as orthostatic headaches, malaise, diplopia, and left ptosis, disappeared. On comparison of the MRM images before and after EBP, the hyper-intensity along the nerve roots that was observed before the treatment (Fig. 3A; yellow arrows) decreased or disappeared after the treatment (Fig. 3B).

3. Discussion

Traffic accidents can cause CSF leakage, termed "spontaneous intracranial hypotension (SIH)". Zada et al.⁴ reviewed the ocular manifestations in SIH, which included blurred vision, photophobia, double vision, and visual field defects. Mokri et al. reported that 7 of 40 patients (17.5%) with SIH had a normal CSF pressure. They found that the core pathogenetic factor was a decreased volume of CSF rather than its pressure in SIH.¹² Therefore, the term "cerebrospinal fluid hypovolemia (CFH)" was proposed instead of "spontaneous intracranial hypotension".¹³ Transient third cranial nerve palsy due to CFH was previously reported.^{6–9} We considered the diplopia and ptosis with diurnal fluctuation in our patient to have been caused by oculomotor nerve paresis associated with CFH.

The pathophysiology of cranial nerve palsy in CFH is not fully understood, and potential causes include traction on cranial nerves due to downward displacement of cerebral structures and cranial nerve compression.^{9,13} The symptoms in CFH patients worsen within 2 hours of standing or sitting up and can be temporarily relieved by lying in a supine or recumbent position.¹⁴

Variable ptosis and diplopia are the most common manifestations of myasthenia gravis because ocular muscles are more commonly affected due to twitch fibers in ocular muscles developing tension faster and having a higher frequency of synaptic firing than limb muscles.^{15,16}

The orthostatic change in CFH may be confused with diurnal fluctuation in myasthenia gravis because both symptoms become exacerbated after waking up and recover after lying down. The history of trauma and orthostatic headaches were important for the differential diagnosis, including anti-acetylcholine receptor antibody in the serum and the edrophonium test. Fluid replacement improved his symptoms, and orbital MRI before and after fluid replacement detected an increase in CSF around the optic nerve, which suggested a decrease in the overall volume of CSF.¹⁷

EBP therapy for CHS¹⁸ may have improved these conditions by stopping CSF leakage. MRM was useful for identifying CSF leakage and confirming the effectiveness of EBP, as in previous reports.¹⁹ However, it was difficult to detect CSF leakage by pretreatment MRM alone and the diagnosis of CSF hypovolemia was only confirmed by comparison with post-EBP MRM in this case.

4. Conclusions

We reported a case of CHS after a traffic accident in a patient who presented with diplopia and ptosis with diurnal fluctuation mimicking ocular myasthenia gravis. The fluid replacement test was useful for the differential diagnosis and an increase in CSF after fluid replacement was detected on orbital MRI. EBP therapy was effective for the ocular symptoms and postural headaches. When treating patients with fluctuating diplopia or ptosis who have a history of trauma and orthostatic headaches, the possibility of CHS should be considered in the differential diagnosis.

Patient consent

We received written consent from the patient to publish this report.

The protocol for the fluid replacement test with orbital MRI was reviewed and approved by the institutional review board of Hokkaido University Hospital for clinical research.

Funding

No funding or grant support.

Authorship

All authors attest that they meet the current ICMJE criteria for authorship.

Declaration of competing interest

Nil.

Acknowledgements

None.

References

- Chung SJ, Kim JS, Lee MC. Syndrome of cerebral spinal fluid hypovolemia: clinical and imaging features and outcome. *Neurology*. 2000;55:1321–1327.
- Pattichis AA, Slee M. CSF hypotension: a review of its manifestations, investigation and management. *J Clin Neurosci*. 2016;34:39–43.
- Mokri B. Spontaneous low pressure, low CSF volume headaches: spontaneous CSF leaks. *Headache*. 2013;53:1034–1053.
- Zada G, Solomon TC, Giannotta SL. A review of ocular manifestations in intracranial hypotension. *Neurosurg Focus*. 2007;23:E8.
- Horton JC, Fishman RA. Neurovisual findings in the syndrome of spontaneous intracranial hypotension from dural cerebrospinal fluid leak. *Ophthalmology*. 1994; 101:244–251.
- Ferrante E, Savino A, Brioschi A, Marazzi R, Donato MF, Riva M. Transient oculomotor cranial nerves palsy in spontaneous intracranial hypotension. *J Neurosurg Sci*. 1998;42(3):177–179.
- Warner GT. Spontaneous intracranial hypotension causing a partial third cranial nerve palsy: a novel observation. *Cephalalgia*. 2002;22(10):822–823.
- Brady-McCreery KM, Speidel S, Hussein MA, Coats DK. Spontaneous intracranial hypotension with unique strabismus due to third and fourth cranial neuropathies. *Binocul Vis Strabismus Q*. 2002;17(1):43–48.
- Russo A, Tessitore A, Cirillo M, et al. A transient third cranial nerve palsy as presenting sign of spontaneous intracranial hypotension. *J Headache Pain*. 2011;12 (4):493–496.
- Shinmei Y, Takahashi A, Nakamura K, et al. Cerebrospinal fluid hypovolemia syndrome after a traffic accident with abnormal eye movements: a case report. *Am J Ophthalmol Case Rep*. 2020;22, 100997, 20.
- Yiannakas MC, Toosy AT, Raftopoulos RE, Kapoor R, Miller DH, Wheeler-Kingshott CA. MRI acquisition and analysis protocol for in vivo intraorbital optic nerve segmentation at 3T. *Invest Ophthalmol Vis Sci*. 2013;54(6):4235–4240.
- Mokri B, Hunter SF, Atkinson JL, Piepgras DG. Orthostatic headaches caused by CSF leak but with normal CSF pressures. *Neurology*. 1998;51:786–790.
- Mokri B. Spontaneous cerebrospinal fluid leaks: from intracranial hypotension to cerebrospinal fluid hypovolemia—evolution of a concept. *Mayo Clin Proc*. 1999;74 (11):1113–1123.
- Mea E, Chiapparini L, Savoardo M, et al. Application of IHS criteria to headache attributed to spontaneous intracranial hypotension in a large population. *Cephalalgia*. 2009;29(4):418–422.
- Nair AG, Patil-Chhablani P, Venkatramani DV, Gandhi RA. Ocular myasthenia gravis: a review. *Indian J Ophthalmol*. 2014;62(10):985–991.
- Al-Haidar M, Benatar M, Kaminski HJ. Ocular myasthenia. *Neurol Clin*. 2018;36(2): 241–251.
- Holbrook JF, Hudgins PA, Bruce BB, Saindane AM. Novel orbital findings of intracranial hypotension. *Clin Imag*. 2017;41:125–131.
- Sencakova D, Mokri B, McClelland RL. The efficacy of epidural blood patch in spontaneous CSF leaks. *Neurology*. 2001;57:1921–1923.
- Chazen JL, Talbott JF, Lantos JE, Dillon WP. MR myelography for identification of spinal CSF leak in spontaneous intracranial hypotension. *AJNR Am J Neuroradiol*. 2014;35(10):2007–2012.