

Case Report

# Convulsive Seizures as Presenting Symptom of Metronidazole-Induced Encephalopathy: A Case Report

Caspar Godthaab Sørensen<sup>a</sup> William Kristian Karlsson<sup>a</sup>  
Faisal Mohammad Amin<sup>a</sup> Mette Lindelof<sup>a, b</sup>

<sup>a</sup>Department of Neurology, Herlev-Gentofte Hospital, University of Copenhagen, Copenhagen, Denmark; <sup>b</sup>Department of Clinical Medicine, University of Copenhagen, Copenhagen, Denmark

## Keywords

Dentate nucleus · Cerebellar signs · Seizures · Encephalopathy and metronidazole

## Abstract

**Introduction:** Encephalopathy and convulsive seizures are rare manifestations of metronidazole toxicity. The incidence is unknown, but the condition has most frequently been reported in patients in their fifth to sixth decades. Usually, this condition is regarded as reversible, but permanent deficits and even death have been reported. **Case Report:** A 66-year-old female patient undergoing metronidazole treatment for pleural empyema was admitted to our institution after her second episode of seizure. Over the course of 1 week after admittance, the patient developed several convulsive seizures along with progressive cerebellar dysfunction and cognitive impairment. MRI revealed bilateral, symmetrical hyperintense signal changes in the pons and dentate nuclei. EEG, ECG, lumbar puncture, and blood samples were normal. The patient improved already 2–3 days after discontinuation of metronidazole and was discharged fully recovered after 17 days. Follow-up clinical assessment and MRI were unremarkable. **Conclusion:** Metronidazole-induced encephalopathy is a rare condition, and due to a general lack of awareness the diagnosis is often delayed. This condition should be considered in metronidazole-treated patients presenting with unprovoked seizures, myoclonus, cerebellar signs, and encephalopathy. Characteristic MRI lesions may support the clinical suspicion.

© 2018 The Author(s)  
Published by S. Karger AG, Basel

## Introduction

Metronidazole, a 5-nitroimidazole, is one of the most commonly used antibiotics against anaerobic bacterial and amoebic infections worldwide. It is generally well tolerated but may in rare cases cause neurological side effects. Metronidazole-induced encephalopathy is a challenging side effect, which is probably underdiagnosed [1], most likely due to general unawareness of this condition. The incidence is not known but reviews of case reports concerning metronidazole-induced encephalopathy suggest a peak incidence in patients between 50 and 60 years old [2]. In most cases, it is a reversible condition, but permanent sequelae and death have been reported [2, 3]. In this paper, we present a case of metronidazole-induced encephalopathy with generalized and focal seizures in a previously nonepileptic patient.

## Case Report

A 66-year-old female with a medical history of previous smoking and chronic depression had recently been prescribed 6 weeks of oral metronidazole 500 mg three times daily along with amoxicillin and clavulanic acid for pleural empyema. After 34 days of treatment, she noticed paresthesia of toes and fingertips. On day 36 of treatment, she had a seizure with loss of consciousness, facial contractions, shivering of the arms, and prolonged awakening. She was brought to an emergency department where physical examination, ECG, and brain CT were normal, and was discharged without neurological consultation. The following days, she felt unwell and on the day 45 of metronidazole treatment, a second seizure occurred, after which she was admitted to our Department. The husband had witnessed a few minutes of unconsciousness accompanied by contractions of the upper extremities and biting of the tongue followed by prolonged reawakening. Both seizures had been preceded by nausea and a tightening epigastric sensation. Neurological examination revealed decreased sensation of touch distally on upper and lower extremities but was otherwise unremarkable. Point-of-care arterial lactate upon admission was elevated (6.3 mmol/L). EEG, ECG, and blood samples, including kidney and liver function, hemoglobin and coagulation factors were all normal, except marginally elevated leukocytes and platelets (respectively  $11.5 \times 10^9$  cells/L and  $484 \times 10^9$  cells/L). Brain MRI with gadolinium contrast was performed the day after admission and showed only slight cortical atrophy; however, interpretation was impaired by poor image quality due to movement artefacts. Over the following 5 days, the patient further developed multifocal myoclonus, cognitive impairment as well as truncal and limb ataxia. Moreover, she had several focal seizures in her face and arms. On day 7 after admission, clinical suspicion of metronidazole-induced encephalopathy arose, and metronidazole was discontinued. Lumbar puncture showed normal protein, glucose, and cell counts. Brain MRI with gadolinium contrast was repeated on day 8 after admission, and metronidazole encephalopathy was confirmed as the fluid-attenuated inversion recovery sequence showed characteristic symmetrical hyperintense signal changes in the pons and dentate nuclei (Fig. 1a). The patient reported improvement 3 days after discontinuation of metronidazole. The patient was discharged 17 days after admission. At this time, she had completely recovered except decreased sensation of the feet. The sensory disturbances were ascribed to metronidazole-induced polyneuropathy, and the patient was referred to nerve conduction studies. Follow-up brain MRI 6 months later showed complete remission of the hyperintense signal changes in the pons and dentate nuclei (Fig. 1b).

## Discussion

Metronidazole readily crosses the blood-brain barrier [4, 5], but the pathophysiological mechanisms behind its neurotoxicity have not yet been fully elucidated. Several mechanisms have been proposed. In vitro, metronidazole forms byproducts which may competitively inhibit thiamine [6] and can also react with catecholamines to produce neurotoxic free radicals [7]. Experimental studies have suggested that metronidazole can influence levels of brain monoamines [8] and bind to neuronal RNA in rats [9]. Moreover, modulation of GABA receptors has been suggested in canine studies [10].

Clinical signs of encephalopathy or the combination of reduced consciousness and ataxia in a patient undergoing metronidazole treatment may bring metronidazole-induced encephalopathy into diagnostic considerations very early. Moreover, metronidazole-induced encephalopathy may be suspected in a previously nonepileptic patient with no biochemical, electrophysiological, or neuroimaging evidence or risk factors of epilepsy who presents with new onset of multifocal myoclonus or epileptic seizures. Our patient presented with seizures as well as mild cognitive symptoms masked by a postictal state. Side effects of metronidazole were suspected from the evolving clinical picture of encephalopathy, seizures, myoclonus, and cerebellar disturbances.

Diagnosis was confirmed when other possible underlying conditions were excluded and brain MRI displayed symmetrical lesions of the dentate nuclei and posterior pons. Ahmed et al. [11] first demonstrated neuroimaging findings in metronidazole-induced encephalopathy. Since then, several cases have been reported [2, 3]. Bilateral changes of the dentate nuclei, subcortical white matter, corpus callosum, and posterior pons are characteristic [2], but the initial MRI may be negative [12] as in the case of our patient.

In our patient, the diagnosis of metronidazole-induced encephalopathy was established 2–3 weeks after the first symptoms, and her condition significantly improved 2–3 days after cessation of metronidazole treatment. Irreversible deficits and even death have been reported in the literature [13]; however, in most patients, both clinical and MRI abnormalities are reversible, underlining the importance of recognizing the condition as swiftly as possible [2, 3].

## Statements of Ethics

The authors have no ethical conflicts to disclose.

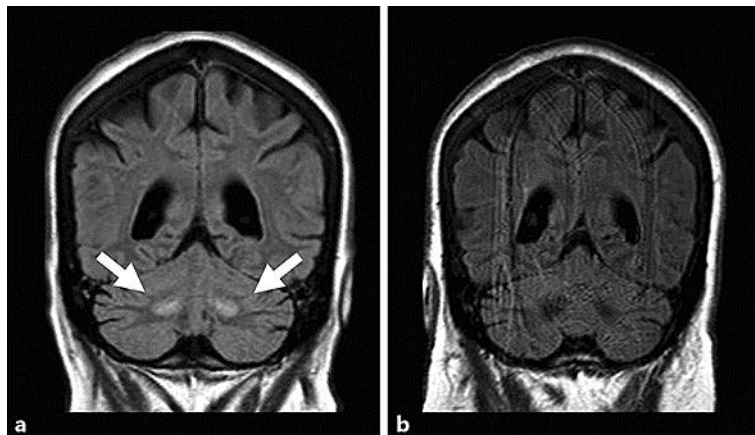
## Disclosure Statement

F.M.A. has received travel grant or payment for speaking from Novartis and Allergan.

## References

- 1 Bhattacharyya S, Darby RR, Raibagkar P, Gonzalez Castro LN, Berkowitz AL: Antibiotic-associated encephalopathy. *Neurology* 2016;86:963–971.
- 2 Kuriyama A, Jackson JL, Doi A, Kamiya T: Metronidazole-induced central nervous system toxicity: a systematic review. *Clin Neuropharmacol* 2011;34:241–247.
- 3 Roy U, Panwar A, Pandit A, Das SK, Joshi B: Clinical and neuroradiological spectrum of metronidazole induced encephalopathy: our experience and the review of literature. *J Clin Diagn Res* 2016;10:1–9.

- 4 Lamp KC, Freeman CD, Klutman NE, Lacy MK: Pharmacokinetics and pharmacodynamics of the nitroimidazole antimicrobials. *Clin Pharmacokinet* 1999;36:353–373.
- 5 Nau R, Sörgel F, Eiffert H: Penetration of drugs through the blood-cerebrospinal fluid/blood-brain barrier for treatment of central nervous system infections. *Clin Microbiol Rev* 2010;23:858–883.
- 6 Alston TA, Abeles RH: Enzymatic conversion of the antibiotic metronidazole to an analog of thiamine. *Arch Biochem Biophys* 1987;257:357–362.
- 7 Rao DN, Mason RP: Generation of nitro radical anions of some 5-nitrofurans, 2- and 5-nitroimidazoles by norepinephrine, dopamine, and serotonin. A possible mechanism for neurotoxicity caused by nitroheterocyclic drugs. *J Biol Chem* 1987;262:11731–11736.
- 8 Karamanakos PN, Pappas P, Boumba VA, Thomas C, Malamas M, Vougiouklakis T, Marselos M: Pharmaceutical agents known to produce disulfiram-like reaction: effects on hepatic ethanol metabolism and brain monoamines. *Int J Toxicol* 2007;26:423–432.
- 9 Bradley WG, Karlsson IJ, Rassol CG: Metronidazole neuropathy. *BMJ* 1977;2:610–611.
- 10 Evans J, Levesque D, Knowles K, Longshore R, Plummer S: Diazepam as a treatment for metronidazole toxicosis in dogs: a retrospective study of 21 cases. *J Vet Intern Med* 2003;17:304–310.
- 11 Ahmed A, Loes DJ, Bressier EL: Reversible magnetic resonance imaging findings in metronidazole induced encephalopathy. *Neurology* 1995;45:588–589.
- 12 Onder H: A case of MRI negative metronidazole-induced encephalopathy and recovery of electroencephalography at follow-up. *J Neurol Res* 2016;6:81–84.
- 13 Hobbs K, Stern-Nezer S, Buckwalter MS, Fischbein N, Finley Caulfield A: Metronidazole-induced encephalopathy: not always a reversible situation. *Neurocrit Care* 2015;22:429–436.



**Fig. 1.** Coronal fluid-attenuated inversion recovery with gadolinium contrast recorded by a 3T MRI scanner during (a) and 6 months after (b) full recovery from metronidazole-induced encephalopathy. The white arrows mark the hyperintense signal changes in the bilateral dentate nuclei.