

Massive Spontaneous Diaphragmatic Rupture Induced by a Squatting Position

Su Wan Kim, M.D., Seogjae Lee, Ph.D.

While a diaphragmatic rupture commonly results from trauma to the abdomen and chest, a spontaneous diaphragmatic rupture is very rare. A 68-year-old male presented with chest pain that had originated while doing farm work in a squatting position. Images revealed a 5 cm defect of the left diaphragmatic dome, and the entire stomach was displaced into the thorax. The diaphragmatic defect was round and half had a well-demarcated margin. The remaining fragile tissue was completely excised and was closed primarily. The patient was uneventfully discharged and resumed with a normal diet 10 days after the operation.

Key words: 1. Diaphragm
2. Chest pain
3. Computed tomography

CASE REPORT

A 68-year-old male presented with chest pain similar to acute coronary syndrome. The patient had felt a substernal pain from a period of four days prior to examination, which had begun while carrying out farm work in a squatting position. The severity of the chest pain had fluctuated, and then the patient felt intolerable chest pain that lasted for two hours. An electrocardiogram showed normal sinus rhythm, and cardiac enzymes were normal. However, compared with another chest X-ray four months earlier (Fig. 1A), a second chest X-ray revealed left diaphragmatic hernia with a markedly distended stomach and passive atelectasis of the left lower lung (Fig. 1B). An abdomen computed tomography showed that the herniated stomach was significantly distended by ingested air due to severe pyloric compression. The dia-

phragmatic defect was approximately 5 cm in diameter (Fig. 1C).

We performed an emergency operation because the patient suffered from continuing chest pain, which suggested a strangulation of the stomach. A left lateral thoracotomy was performed through the eighth intercostal space after intubation with a double-lumen endotracheal tube and insertion of a nasogastric tube for decompressing the stomach. We carefully inspected the stomach, which was entirely displaced into the thoracic cavity, including the greater omentum (Fig. 2A), and we then reduced the stomach into the peritoneal cavity. A diaphragmatic defect was identified on the highest central tendon and had a round shape, half of which had a well-demarcated margin (Fig. 2B). The diaphragm was thinned and unevenly rough owing to senile change. The remaining tissue of the fragile margin was completely excised (Fig. 2C) and was

Department of Thoracic and Cardiovascular Surgery, Jeju National University Hospital, Jeju National University School of Medicine

†This article was presented at the 44th Autumn Scientific Meeting of The Korean Society for Thoracic and Cardiovascular Surgery.

Received: November 6, 2012, Revised: December 17, 2012, Accepted: December 18, 2012

Corresponding author: Seogjae Lee, Department of Thoracic and Cardiovascular Surgery, Jeju National University Hospital, Jeju National University School of Medicine, 15 Aran 13-gil, Jeju 690-767, Korea
(Tel) 82-64-717-2081 (Fax) 82-64-757-8276 (E-mail) sj1106@jejunu.ac.kr

© The Korean Society for Thoracic and Cardiovascular Surgery. 2013. All right reserved.

© This is an open access article distributed under the terms of the Creative Commons Attribution Non-Commercial License (<http://creativecommons.org/licenses/by-nc/3.0>) which permits unrestricted non-commercial use, distribution, and reproduction in any medium, provided the original work is properly cited.

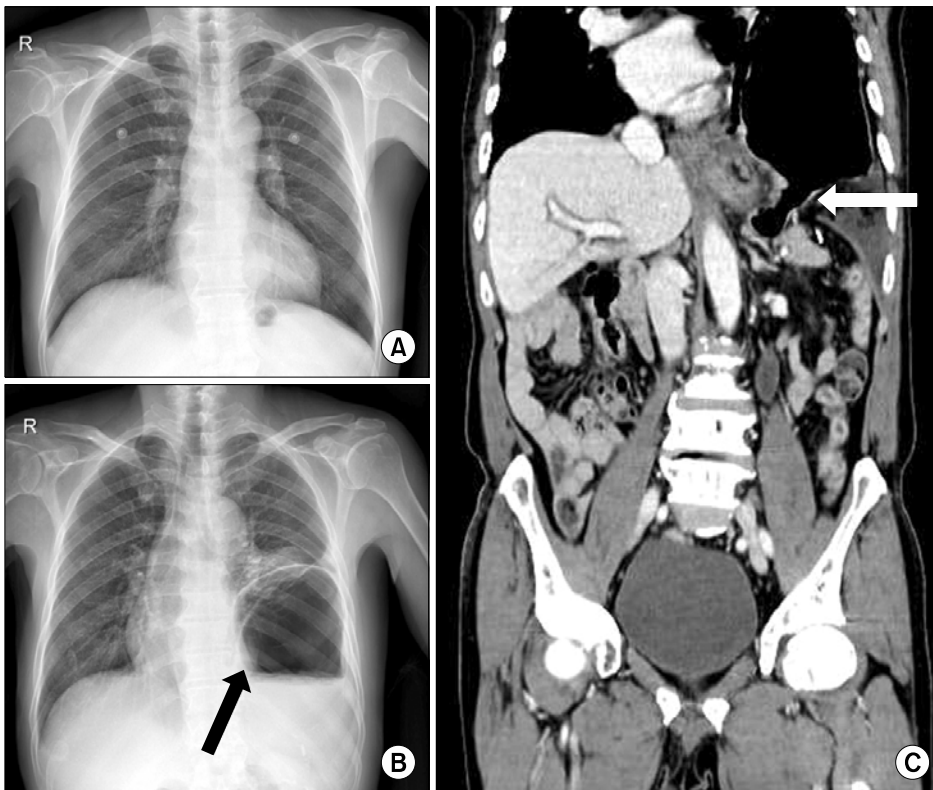


Fig. 1. The patient had a normal chest X-ray four months earlier (A). A new chest X-ray (B) and computed tomography (C) revealed that the stomach had migrated into the thoracic cavity. A black arrow (B) points to the stomach, which is extremely inflated by ingested air. A white arrow (C) points to a 5 cm defect of the diaphragm. The diaphragmatic dome is suspected to be a perforated site.

closed primarily using continuous running sutures and multiple interrupted sutures (Fig. 2D). The patient was extubated before leaving the operating room. The chest X-rays before discharge showed complete reduction of the stomach and full re-expansion of the left lung (Fig. 3). The patient was uneventfully discharged and resumed a normal diet 10 days after the operation.

DISCUSSION

Diaphragmatic rupture (DR) is commonly observed after a blunt or penetrating trauma to the abdomen and chest. Several reports of traumatic DR appear in the Korean literature. Recently, Hwang et al. [1] investigated 40 patients and Cho et al. [2] investigated 37 patients with traumatic DR. The mortality rates of these patients were 17.5% and 16.2%, respectively, and the patients had similar prognostic factors affecting mortality, such as a high injury severity score, high revised trauma score, and hypotension. However, spontaneous DR has not been reported in Korea.

Losanoff et al. [3] reported one case of spontaneous DR

that had been induced by a recent bout of coughing and reviewed the world literature about spontaneous DR of 28 patients from 1956 to 2009. Coughing was the precipitating event in 9 patients (32%), physical exercise in 6 patients (21%), vaginal delivery in 4 patients (14%), vomiting in 2 patients (7%), and massage in 1 patient (4%). On the other hand, there have been sporadic case reports of secondary spontaneous DR since 2009. Hamaoui et al. [4] reported a case of spontaneous DR in a 35-year-old male patient with Ehlers-Danlos syndrome, a genetic disorder that causes abnormalities in the synthesis and structure of collagen and can lead to multiple anatomical defects. Pehar et al. [5] reported a case of spontaneous DR related to local invasion by retroperitoneal liposarcoma. Diaphragmatic eventration is thought to be a secondary cause of spontaneous DR during pregnancy. Servais et al. [6] suggested that symptomatic diaphragmatic eventration during pregnancy should be repaired during the third trimester once fetal organogenesis is complete in order to prevent further herniation from the enlarging uterus and the risk of hernia strangulation.

One case of spontaneous DR in a Korean patient was re-

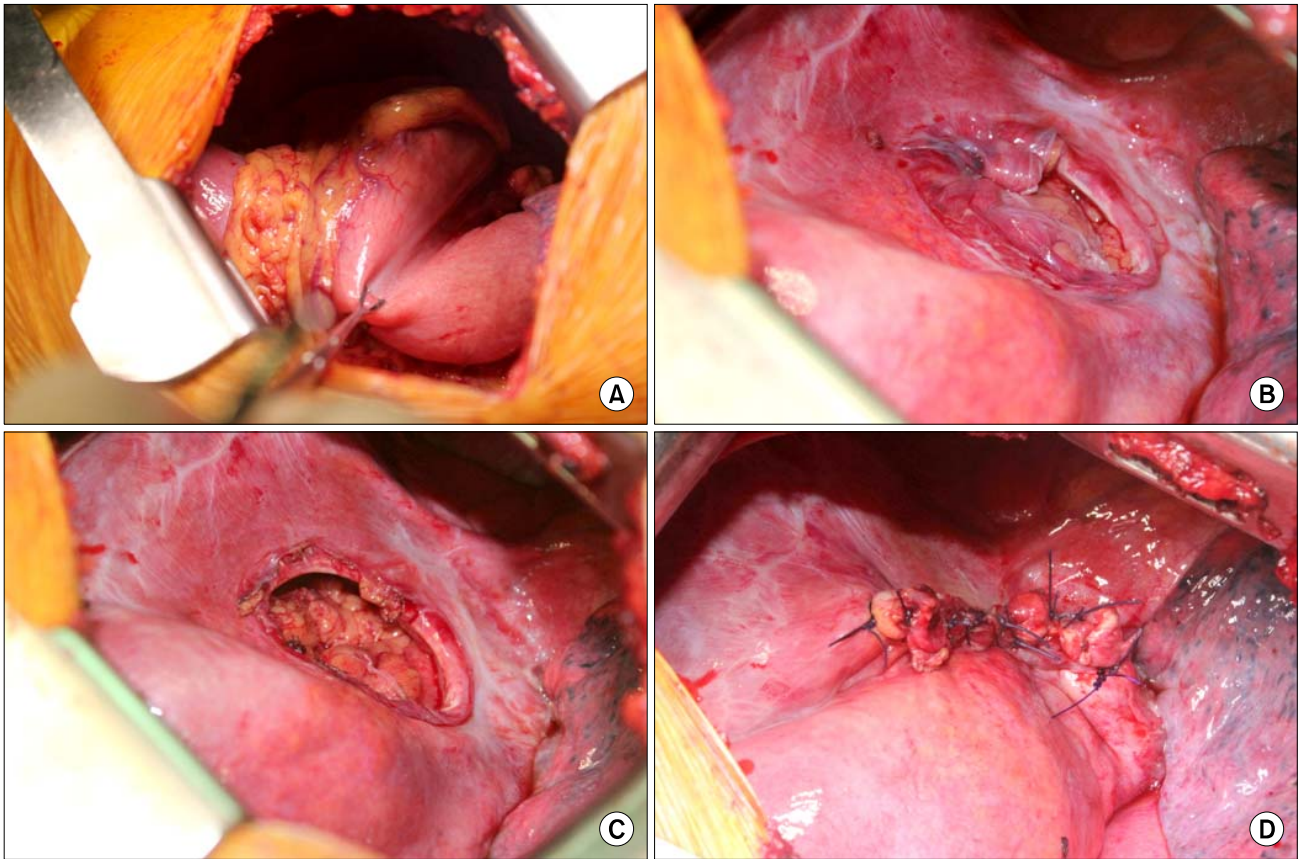


Fig. 2. The entire stomach including the greater omentum is displaced into the thorax (A). The diaphragmatic defect is observed on the highest central tendon, and has a round shape, half of which has a well-demarcated margin (B). The remaining tissue of the fragile margin was completely excised (C) and was closed primarily (D).

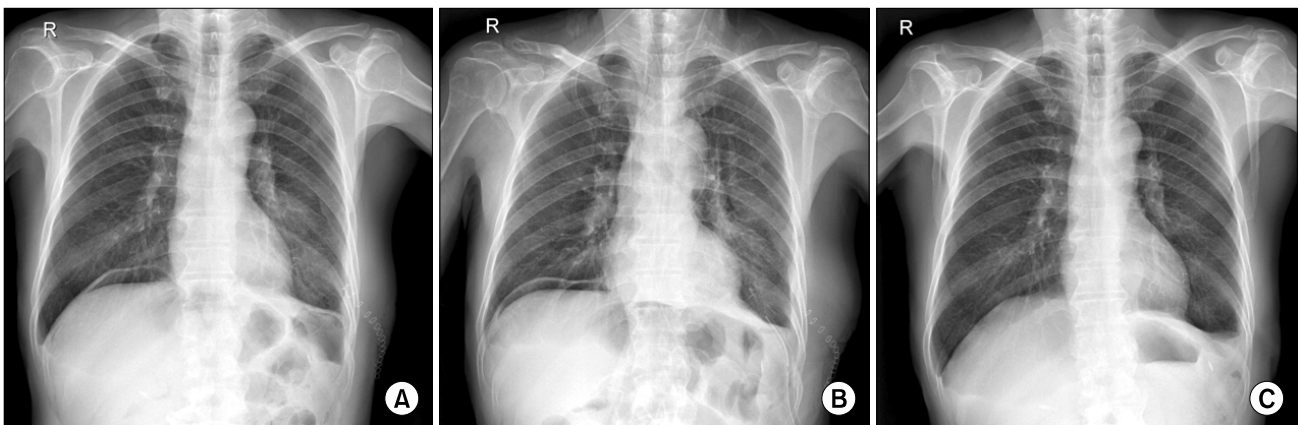


Fig. 3. (A) The diaphragm became flat after the repair. (B) Postoperatively, a small amount of pneumoperitoneum was observed, (C) but the pneumoperitoneum spontaneously disappeared after discharge.

ported by Yang et al. [7] in a United States journal. They reported a spontaneous DR in a 29-year-old woman and suggested that spontaneous DR might be caused by a static sport activity, such as pilates. We, however, report the first case of spontaneous DR in the Korean Journal of Thoracic and Cardiovascular Surgery. Furthermore, we present several photographs of high quality that clearly point out the diaphragmatic defect. No pictures grossly showing a diaphragmatic defect definitively like that of our patient have been published before.

Diaphragmatic injuries that are diagnosed promptly should be explored from the abdomen with either a laparotomy or laparoscopy because of the frequent association of other abdominal organ injury. In those cases with a significant delay in diagnosis, injuries generally should be explored from the thorax, with either thoracotomy or thoracoscopy, because the herniated abdominal structure is frequently adhered to the ipsilateral lung [8]. Additionally, it is recommended that the diaphragm be restored by simple interrupted suture or double layer suture methods with non-absorbable suture materials [1,2,8]. In our case, we performed a left thoracotomy because the patient had no abdominal trauma history and the suspicious rupture site was the central tendon, which could be observed by direct vision through the thoracotomy.

In summary, we report the first description of massive spontaneous DR arising while in the squatting position, probably resulting from increased intra-abdominal pressure. This and similar reports emphasize that in cases with high clinical suspicion of DR, diagnosis should be pursued even in the absence of a preceding traumatic event.

CONFLICT OF INTEREST

No potential conflict of interest relevant to this article was reported.

REFERENCES

1. Hwang SW, Kim HY, Byun JH. *Management of patients with traumatic rupture of the diaphragm*. Korean J Thorac Cardiovasc Surg 2011;44:348-54.
2. Cho S, Lee EB, Seok YK. *The prognostic factors of traumatic diaphragmatic rupture*. Korean J Thorac Cardiovasc Surg 2010;43:47-52.
3. Losanoff JE, Edelman DA, Salwen WA, Basson MD. *Spontaneous rupture of the diaphragm: case report and comprehensive review of the world literature*. J Thorac Cardiovasc Surg 2010;139:e127-8.
4. Hamaoui K, Riaz A, Hay A, Botha A. *Massive spontaneous diaphragmatic rupture in Ehlers-Danlos syndrome*. Ann R Coll Surg Engl 2012;94:e5-7.
5. Pehar M, Vukoja I, Rozic D, Miskovic J. *Spontaneous diaphragmatic rupture related to local invasion by retroperitoneal liposarcoma*. Ann R Coll Surg Engl 2012;94:e18-9.
6. Servais EL, Stiles BM, Finnerty BM, Paul S. *Ruptured diaphragmatic eventration: a rare cause of acute postpartum dyspnea*. Ann Thorac Surg 2012;93:e143-4.
7. Yang YM, Yang HB, Park JS, Kim H, Lee SW, Kim JH. *Spontaneous diaphragmatic rupture complicated with perforation of the stomach during Pilates*. Am J Emerg Med 2010;28:259.e1-3.
8. Daniel CE, Michael TJ. *Surgery of the diaphragm: a deductive approach*. In: Sellke FW, Del Nido PJ, Swanson SJ, Sabiston DC, Spencer FC. *Sabiston & Spencer surgery of the chest*. 7th ed. Philadelphia: Elsevier Saunders; 2004. p.501-15.