

# Outcomes of Management of Patients with Acute Mesenteric Ischemia: A Prospective Study

Meghraj Kundan<sup>1</sup>, Hethu Chebrolu<sup>1</sup>, Chetan Muniswamppa<sup>1</sup>, Niranjan Kumar<sup>2</sup>, Chintamani<sup>1</sup>, Vinayak Varma<sup>1</sup>

<sup>1</sup>Department of General Surgery, V.M.M.C and Safdarjung Hospital, New Delhi, India,

<sup>2</sup>Department of General Surgery, TMH, Jamshedpur, Jharkhand, India

Submitted: 15-May-2020

Revised: 18-May-2020

Accepted: 26-May-2020

Published: 09-Mar-2021

## INTRODUCTION

Acute mesenteric ischemia (AMI) is the sudden onset of small intestinal hypoperfusion, which can be due to reduction or cessation of arterial inflow. Ischemia can be caused by embolic obstruction of the intestinal blood supply, mostly to the superior mesenteric artery (SMA) because it emerges from the aorta at an oblique angle at L1 level. Acute ischemia can also occur due to acute thrombotic obstruction, mostly in an already diseased mesenteric vessel (e.g., atherosclerosis).

AMI is a potentially fatal vascular emergency with overall mortality of 60%–80%,<sup>[1-5]</sup> and its reported incidence is increasing.<sup>[3]</sup> It comprises of a group of pathophysiologic processes that have a common

## ABSTRACT

**Introduction:** Acute mesenteric ischemia (AMI) is the sudden onset of small intestinal hypoperfusion, which can be due to reduction or cessation of arterial inflow. It can be embolic or thrombotic. AMI is a potentially fatal vascular emergency, with overall mortality of 60%–80%. The present study was designed to study presentation, risk factors, and various outcomes of AMI patients, who were treated in the tertiary hospital. **Methodology:** All patients with features suggestive of AMI were taken in study. All patients underwent explorative laparotomy with exteriorization of bowel after initial resuscitation. Postoperatively, refeeding enteroclysis was done. **Observation and Results:** The total mortality rate was 62.50%. In patients with functional bowel length of 1 foot, 90.90% patients died. In patients with functional bowel length of 5–6 feet, only 12.50% died. It was observed that the mortality rate was more in the age group of 50–59 years with functional bowel length of 1 foot or <1 foot. Refeeding enteroclysis is an effective technique to use distal bowel. Contrast-enhanced computed tomography of the abdomen more suggestive of this pathology. **Conclusions:** A strong clinical suspicion and an aggressive approach should be considered in dealing with this condition because the outcome mainly depends on rapid diagnosis and treatment. With understanding of the pathogenesis of AMI and the better utilization of available radiological investigations, an improved outcome can be achieved. Mortality rates with refeeding enteroclysis are comparable with that of bowel anastomosis. This condition needs future research.

**KEYWORDS:** Acute mesenteric ischemia, contrast-enhanced computed tomography abdomen, exploratory diagnosis, gangrenous bowel

end point that is bowel necrosis. The incidence is low, estimated at 0.09%–0.2% of all acute surgical admissions.<sup>[6]</sup> The condition increases exponentially with age and has no gender predilection. Thrombotic occlusions are typically located proximal in the SMA. Embolic occlusions may lodge more distally, depending on the size of the embolus. Atherosclerosis, arrhythmias (specifically atrial fibrillation), hypovolemia, cardiac disease including congestive heart failure, recent myocardial infarction (MI) and valvular

**Address for correspondence:** Dr. Meghraj Kundan, Department of General Surgery, V.M.M.C and Safdarjung Hospital, New Delhi - 110 029, India.  
E-mail: drmeghrajkundand@gmail.com

This is an open access journal, and articles are distributed under the terms of the Creative Commons Attribution-NonCommercial-ShareAlike 4.0 License, which allows others to remix, tweak, and build upon the work non-commercially, as long as appropriate credit is given and the new creations are licensed under the identical terms.

**For reprints contact:** WKHLRPMedknow\_reprints@wolterskluwer.com

**How to cite this article:** Kundan M, Chebrolu H, Muniswamppa C, Kumar N, Chintamani, Varma V. Outcomes of management of patients with acute mesenteric ischemia: A prospective study. Niger J Surg 2021;27:16-21.

Access this article online	
<b>Quick Response Code:</b> 	<b>Website:</b> www.nigerianjsurg.com  <b>DOI:</b> 10.4103/njs.NJS_54_20

disease, advanced age, intraabdominal malignancy, and inflammatory bowel disease has been implicated in the pathogenesis of acute mesenteric thrombosis.<sup>[7-9]</sup>

AMI was categorized into four types based on its cause: (1) arterial thrombus, (2) arterial embolus, (3) nonocclusive, and (4) venous occlusion.

Arterial emboli are the most frequent cause of AMI and are responsible for approximately 40%–50% of cases.<sup>[2,3]</sup> Most mesenteric emboli have cardiac origin and preferentially lodge in the superior mesenteric artery (SMA) because it emerges from the aorta at an oblique angle. While 15% of arterial emboli occur at the origin of the SMA, 50% lodge distally to the origin of the middle colic artery, which is the first major branch of the SMA.<sup>[5]</sup> The symptoms are usually abrupt onset of severe abdominal pain associated with diarrhea, which may become bloody. Frequently, the diagnosis of SMA embolism can be made intraoperatively based on the distribution of ischemic bowel. Because most SMA emboli lodge distally to the origin of the middle colic artery, allowing the inferior pancreaticoduodenal branches to be perfused, the proximal jejunum is spared, whereas the rest of the small bowel is ischemic or infarcted.

Acute mesenteric thrombosis accounts for 25%–30% of all ischemic events.<sup>[2-4]</sup> Almost all mesenteric ischemia due to arterial thrombosis occurs in the preexisting severe atherosclerotic disease, most common site being near the origin of the SMA.<sup>[10]</sup> The extent of bowel ischemia or infarction is typically greater than that with embolism, extending from the duodenum to the transverse colon. Perioperative mortality ranges from 70% to 100%.

Nonocclusive mesenteric ischemia (NOMI) accounts for 20% of total mesenteric, which can result from a reactive vascular spasm within the intestinal circulation and poor perfusion. It can occur in low-flow situations, for example, shock, during dialysis, during cardiac procedures, and digoxin usage.

Mesenteric venous thrombosis (MVT) accounts for 10%–15% of mesenteric ischemia. It is the least common cause. Etiology includes primary clotting disorders, secondary to other intra-abdominal pathologic conditions (such as malignancy, intraabdominal sepsis, or pancreatitis). MVT is usually segmental, with edema and hemorrhage of the bowel wall and focal sloughing of the mucosa.

The present study was designed to study presentation, risk factors, and various outcomes of AMI patients, who were treated in our hospital.

## METHODOLOGY

All patients of AMI that underwent explorative laparotomy recruited from surgical ward prospectively. For all patients, surgical decision was taken based on clinical features, available radiological investigations (X-ray, ultrasonogram [USG], and contrast-enhanced computed tomography [CECT] abdomen). Fifty percent patients were diagnosed With AMI by radiological investigations pre operatively. In rest of patients, diagnosis was made on the basis of intra operative findings suggestive of gangrenous bowel with absent mesenteric vessel pulsations. Explorative laparotomy was done and bowel was thoroughly examined & resection of gangrenous bowel was done and viable bowel exteriorized as stoma. Refeeding enteroclysis was started after stabilization. All patients were followed up postoperatively; mortality rates were calculated. Length of functional small intestine and mortality rates was compared.

## OBSERVATION AND RESULTS

A total of 24 patients with AMI presented to emergency of this hospital from January 2018 to June 2019 were prospectively recruited for the study. All the patients were managed with proper resuscitation followed by explorative laparotomy. The patients' clinical presentation, intraoperative findings, and outcomes are presented in tables. In all patients, refeeding enteroclysis was done.<sup>[11]</sup>

Agewise comorbidity or predisposing factors, presentation, investigation, and operative procedures of the patients are described in Table 1, and intraoperative finding and postoperative status was presented in Table 2, whose conclusions are described below.

In a total of 24 patients, maximum number (54.17%) of patients was observed under the age group between 50 and 59 years followed by 37.5% in the age group of 40–49 years. The least (4.17%) patients were recorded in the age group of 30–39 and 60–69 years.

Regarding comorbidities/predisposing factors, 20.83% patients were known coronary artery disease patients. Nearly 16.67% patients were both smoker and alcoholics. 12.5% patients were only smokers. 12.5% patients had h/o stroke with residual paralysis. Rheumatic heart disease, hypertensive, diabetic patients were 8.33, 8.33, and 4.17, respectively. In all age groups, the most common clinical presentation (83.33%) was pain abdomen, vomiting, nonpassage of stools and flatus with diffuse abdominal tenderness. Particularly, maximum of 45.83% was in the age group of 50–59 years. 16.67% were presented with pain abdomen, vomiting, bleeding

**Table 1: Age wise distribution of factors, clinical presentation, investigations, and procedures**

Variable	Age (years) group of the patients				Total	Percentage
	30-39	40-49	50-59	60-69		
<b>Co-morbidities/predisposing factors</b>						
History of stroke with residual paralysis	0	3	0	0	3	12.50
Diabetic on treatment	0	0	1	0	1	04.17
No known comorbidities	0	0	4	0	4	16.67
Chronic smokers and alcoholic	0	3	1	0	4	16.67
A case of CAD	0	3	2	0	5	20.83
A known hypertensive on treatment	0	0	2	0	2	08.33
A case of RHD on treatment	0	0	2	0	2	08.33
Chronic smokers	1	0	1	1	3	12.50
Total	1	9	13	1	24	
Percentage	4.17	37.50	54.17	4.17		
<b>Presentation</b>						
Pain abdomen, vomiting, bleeding PR	0	2	2	0	4	16.67
Pain abdomen, vomiting, nonpassage of stool and flatus	1	7	11	1	20	83.33
Total	1	9	13	1	24	
Percentage	4.17	37.50	54.17	4.17		
<b>Investigation</b>						
CECT abdomen s/o SMA thrombosis	0	4	6	1	11	45.83
USG s/o intestinal obstruction	1	4	7	0	12	50.00
CECT abdomen s/o celiac trunk thrombosis	0	1	0	0	01	04.17
Total	1	9	13	1	24	
Percentage	4.17	37.50	54.17	4.17		
<b>Procedure</b>						
Explorative laparotomy with resection of gangrenous bowel with end jejunostomy with mucous fistula	0	4	10	1	15	62.50
Explorative laparotomy with resection of gangrenous bowel with end ileostomy with tube cecostomy	1	4	3	0	8	33.33
Explorative laparotomy with right hemicolectomy with end ileostomy with mucous fistula of the transverse colon	0	1	0	0	1	4.17
Total	1	9	13	1	24	

SMA: Superior mesenteric artery, CAD: Coronary artery disease, RHD: Rheumatic heart disease, PR: Per rectum, CECT: Contrast-enhanced computed tomography, USG: Ultrasonogram

**Table 2: Age wise distribution of intraoperative findings and postoperative status including mortality**

Small intestine extending	Age (years)				Total	Percentage
	30-39	40-49	50-59	60-69		
<b>Intra operation findings</b>						
1 foot/<1 foot from DJ junction to 1-2 feet of ICJ was gangrenous	0	4	6	1	11	45.83
2 feet from DJ junction to 1 foot of ICJ was gangrenous	0	0	1	0	1	04.17
3 feet from DJ junction to 1 foot of ICJ was gangrenous	0	0	1	0	1	04.17
4 feet from DJ junction to 1 foot of ICJ was gangrenous	0	0	2	0	2	08.33
>5-6 feet from DJ junction to <1 foot of ICJ was gangrenous	1	4	3	0	8	33.33
1 foot of ileum proximal to ICJ and caecum, ascending colon and hepatic flexure were gangrenous	0	1	0	0	1	4.17
Total	1	9	13	1	24	
Percentage	4.17	37.50	54.17	4.17		
<b>Postoperation status</b>						
Patient died within 2 days after operation	0	3	6	1	10	41.67
Patient died within 5 days after operation	0	1	1	0	2	08.33
Patient died within 2 months after operation	0	0	3	0	3	12.50
Patient alive	1	5	3	0	9	37.50
Total	1	9	13	1	24	
Percentage	4.17	37.50	54.17	4.17		

DJ: Duodenal Jejunal junction , ICJ: Ileo-Caecal Junction

per rectum with abdominal tenderness. None of patients presented with in 24 h of onset of symptoms.

All of them presented to the surgical emergency, decision for surgery was taken based on mainly clinical features, general status, and radiological investigations such as X-ray of the abdomen, ultrasound abdomen, and CECT scan of the abdomen. The most common ultrasonographic feature (50%) in patients in all age groups was bowel obstruction. CECT abdomen was done in stable patients; findings of CECT abdomen were suggestive of SMA thrombosis in 45.8% of patients, coeliac artery thrombosis in 4.17%. Computed tomography (CT) angiography was done in patients not having features suggestive of intestinal obstruction, gangrene of bowel.

Explorative laparotomy was done in all patients. Age-wise intraoperative finding and postoperative status are presented in Table 2. Maximum number of patients (45.83%) had functional small intestine length of around 1 foot from DJ followed by 33.33% of 5–6 feet from DJ. 41.67% of the patients were died within 2 days after surgery. 37.50% patients were alive.

Mortality rate of the patients after operation is represented in Table 3. Per operative photograph of small bowel are shown in Figures 1-3. Total mortality rate was 62.50%. It was observed that 37.5% of the patients who died were under the age between 50 and 59 years, followed by 20.83% in the age group of 40–49 years. No mortality was observed in the age group of 30–39 years in all possible length of the intestine. In patients with functional bowel length of 1 foot, 90.90% patients died. In patients with functional bowel length of 5–6 feet, only 12.50% died. Total patients alive are 37.50%. Maximum number of alive patients (16.66%) was observed in the sample study under the age group of 40–49 years with functional length of 5–6 feet. Moreover, no alive patients were observed in the age group of 60–69 years. It was concluded that

mortality rate was more in the age group of 50–59 years with functional bowel length of 1 foot or <1 foot.

## DISCUSSION

AMI is an emergency that necessitates urgent intervention. Outcomes worsen with delay in the diagnosis. Patients generally present with acute pain abdomen, nausea, and vomiting. In our study, also patients presented with similar complaints. Most of them had prodromal warning signs such as intermittent postprandial abdominal discomfort. Most patients neglected these signs and did not seek medical advice. Some were treated as gastritis in smaller, peripheral centers. At the time of presentation, patients had pain abdomen which can mimic pancreatitis, diverticulitis, small bowel obstruction, etc. However, in patients of mesenteric ischemia, patients rapidly deteriorate and pain is out of proportion to symptoms initially. There may be an intermittent decrease in pain due to gangrene, the pain then again increases due to peritonitis. Some patients also complain of bloody diarrhea, which drives the diagnosis more toward mesenteric ischemia in a patient of acute abdomen. In general, SMA embolism or thrombosis

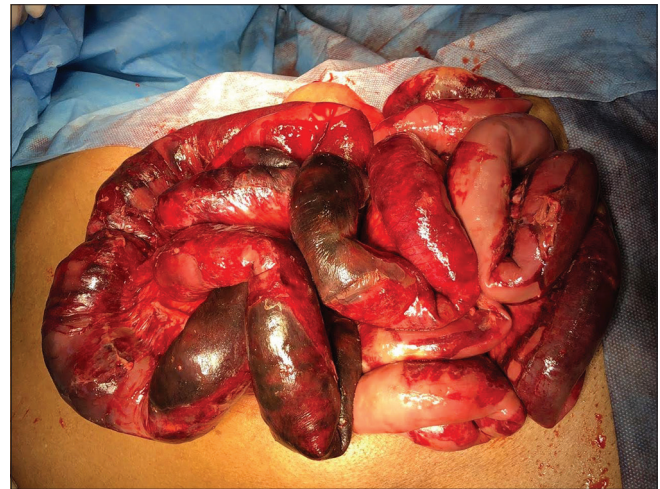

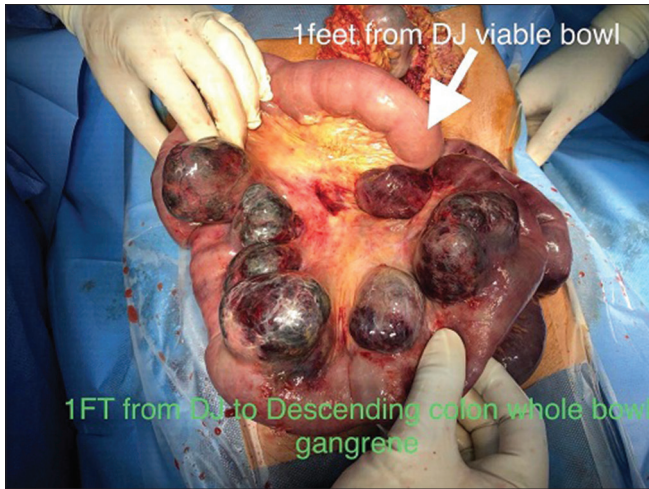
Figure 1: Photograph 1 showing ischemic and gangrenous bowel

Table 3: Comparison of mortality rate with respect to the length of functional small intestine

Length of functional small intestine	Mortality of the patient under different age group				Alive of the patients under different age group			
	30-39	40-49	50-59	60-69	30-39	40-49	50-59	60-69
1 foot/<1 foot	0	4 (16.67)	5 (20.83)	1 (4.17)	0	0	1 (4.17)	0
2 feet	0	0	0	0	0	0	1 (4.17)	0
3 feet	0	0	1 (4.17)	0	0	0	0	0
4 feet	0	0	2 (8.33)	0	0	0	0	0
5-6 feet	0	0	1 (4.17)	0	1 (4.17)	4 (16.66)	2 (8.33)	0
Small intestine till <1 foot proximal to ICJ	0	1 (4.17)	0	0	0	0	0	0
Total	0 (0.00)	5 (20.83)	9 (37.50)	1 (4.17)	1 (4.17)	4 (16.66)	4 (16.66)	0

DJ: Duodenal Jejunal junction, ICJ: Ileo-Caecal Junction



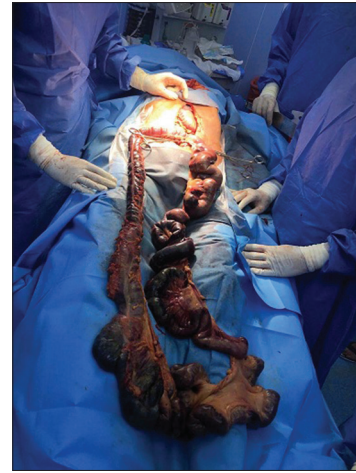

**Figure 2:** Photograph 2 showing gangrenous bowel

has the acute onset of symptoms than nonocclusive mesenteric ischemia and mesenteric vein thrombosis. In SMA thrombosis, patients frequently report prodromal symptoms followed by the acute onset of symptoms. Whereas in SMA embolism, there is a history of cardiac disease or previous thromboembolic phenomenon. In nonobstructive mesenteric ischemia (NOMI), most of the patients are critically ill patients with hemodynamic insult and a late presentation. None of the patients in our study had nonobstructive mesenteric ischemia (NOMI).

AMI leads to bowel infarction rapidly, so early diagnosis and treatment are needed. Proper history and diagnosis serves as the cornerstone in the early diagnosis of AMI. A presentation of acute abdomen in patients of atrial fibrillation, recent MI, recent thromboembolic phenomenon, and prodromal symptoms should raise the suspicion of AMI. Biochemical investigations are nonspecific to AMI, but may indicate septicemia, third space fluid loss, and hemodynamic instability. In our patient's hemoconcentration, leukocytosis, metabolic acidosis with high anion gap and high lactate concentrations, dyselectrolytemia, and sometimes, raised serum amylase were observed. Plain abdominal radiograph was done in all patients, none of them showed thumb print sign, but most showed dilated bowel loops. X-ray has limited role in the diagnosis of AMI, but it is a simple and cost-effective tool to rule out other diagnosis such as mechanical obstruction and perforation peritonitis.

In our study, abdominal USG was done in all patients because it is noninvasive and easily available. Although it was not gold standard, it could suggest gangrenous bowel, which is an indication of emergency surgery. In our study, ultrasound abdomen showed several features such as akinesis of bowel loop (impression given as



**Figure 3:** Photograph 3 showing gangrenous bowel

intestinal obstruction), echogenic line within the wall of bowel, and free fluid in the peritoneal cavity with internal echoes (in cases of gangrenous perforated bowel). Color Doppler gave information regarding vascularity in the intestinal wall. While ultrasound abdomen was not investigation of choice, but it is useful as a first line investigation in cases of AMI. Danse *et al.* reported in a study that Doppler sonography may be a feasible method for detecting acute intestinal ischemia due to proximal SMA occlusion.<sup>[12]</sup> CECT abdomen was done in patients, where operative decision was in dilemma and patients were vitally stable. CT angiography with three-dimensional reconstruction is the gold standard in the diagnosis of AMI. Contrast-enhanced angiography was done in stable patients and in patients without features of intestinal obstruction or gangrenous bowel, which suggested site of ischemia of vessels.

All the patients in our study presented after 24 h of acute onset of symptoms. Due to late presentation, signs of peritonitis were present, expectant management was not done. Preoperative work up was done. All patients were operated after intravenous fluid resuscitation with crystalloids and blood products to correct the volume deficit and metabolic derangement. Emergency exploratory laparotomy was performed, and resection of gangrenous bowel and stoma was made. Bypass grafting or other complex vascular procedures were not done in view of prolonged operative time, poor general condition of the patients. Postoperatively, progression of disease (gangrenous changes) was clinically assessed by inspecting the stoma, functioning of the stoma, and bowel peristalsis. Patients were started on anticoagulation medication and vasodilators. Total parenteral nutrition was supplemented to patients followed by oral nutrition with peripheral parenteral nutrition.

After stabilization of patients contents of end jejunostomy/

ileostomy were readministered into the stoma of distal bowel (mucus fistula). With this refeeding enteroclysis<sup>[11]</sup> technique, distal bowel can be used, so that short gut syndrome can be prevented. Refeeding enteroclysis was done with putting 16 or 18 French Foleys in the distal limb. The stoma effluent collected in stoma bag was emptied every hourly in day time, two hourly in night time. It was filtered through a porous cloth to remove the larger particles. The filtered effluent was then introduced down the distal limb of the fistula through the Foley catheter using a standard feeding bag. The rate of refeeding was adjusted to match stoma effluent output. Once refeeding was established parenteral nutrition was gradually stopped. Serum electrolytes, albumin, and weight were measured weekly. In two patients, Foleys migration was observed; it can be prevented by proper fixing of Foleys catheter to stoma appliances and skin. Complication-related overnight storage of stoma effluent was observed, it can be prevented by timely refeeding and discarding effluent which stored for the long period. Refeeding enteroclysis is a most effective technique to use distal limb and can get results similar to bowel anastomosis. With this technique, we can avoid bowel anastomosis in emergency setting where there is increased chance of leakage due to the progression of gangrene and sepsis. Total mortality rate in our study was 65.50% which was not deferent from mortality rates from other studies, i.e., 50%–90%.<sup>[13]</sup>

## CONCLUSIONS

AMI is a challenging clinical condition, which often results in delayed diagnosis and treatment. A strong clinical suspicion and an aggressive approach should be considered in dealing with this condition because the outcome mainly depends on rapid diagnosis and treatment. Contrast-enhanced CT of the whole abdomen may give more appropriate diagnosis preventing delay in the diagnosis. With understanding of the pathogenesis of AMI and the better utilization of available radiological investigations, an improved outcome can be achieved. Mortality rates with refeeding enteroclysis are comparable with that of bowel anastomosis. This needs more research.

## Declaration of patient consent

The authors certify that they have obtained all appropriate patient consent forms. In the form the patients have given their consent for their images

and other clinical information to be reported in the journal. The patients understand that their names and initials will not be published and due efforts will be made to conceal their identity, but anonymity cannot be guaranteed.

## Financial support and sponsorship

Nil.

## Conflicts of interest

There are no conflicts of interest.

## REFERENCES

1. Heys SD, Brittenden JC, Rofts TJ. Acute mesenteric ischaemia: The continuing difficulty in early diagnosis. *Postgrad Med J* 1993;69:48-51.
2. Lock G. Acute intestinal ischaemia. *Best Pract Res Clin Gastroenterol* 2001;15:83-98.
3. Bradbury AW, Brittenden J, McBride K, Ruckley CV. Mesenteric ischaemia: A multidisciplinary approach. *Br J Surg* 1995;82:1446-59.
4. Sitges-Serra A, Mas X, Roqueta F, Figueras J, Sanz F. Mesenteric infarction: An analysis of 83 patients with prognostic studies in 44 cases undergoing a massive small-bowel resection. *Br J Surg* 1988;75:544-8.
5. Stoney RJ, Cunningham CG. Acute mesenteric ischemia. *Surgery* 1993;114:489-90.
6. Bala M, Kashuk J, Moore EE, Kluger Y, Biffi W, Gomes CA, *et al.* Acute mesenteric ischemia: Guidelines of the World Society of Emergency Surgery. *World J Emerg Surg* 2017;12:38.
7. Kone BC. (2009) Mesenteric Ischemia and Infarction. In: Lang F. (eds) *Encyclopedia of Molecular Mechanisms of Disease*. Springer, Berlin, Heidelberg. <https://link.springer.com/>.
8. Schwartz LB, Gewertz BL. *Mesenteric Ischemia*. Surgical Clinics of North America. Philadelphia: W.B. Saunders; 1997.
9. Wilhelm MC; University of Virginia. *Mesenteric ischemia*. Charlottesville: School of Medicine, University of Virginia; 1981.
10. Kaley RN, Boley SJ. Acute mesenteric ischemia: An aggressive diagnostic and therapeutic approach. 1991 Roussel Lecture. *Can J Surg* 1992;35:613-23.
11. Coetzee E, Rahim Z, Boutall A, Goldberg P. Refeeding enteroclysis as an alternative to parenteral nutrition for enteric fistula. *Colorectal Dis* 2014;16:823-30. [doi: 10.1111/codi.12727].
12. Danse EM, Van Beers BE, Goffette P, Dardenne AN, Laterre PF, Pringot J. Acute intestinal ischemia due to occlusion of the superior mesenteric artery: Detection with Doppler sonography. *J Ultrasound Med* 1996;15:323-6.
13. Christensen MG, Lorentzen JE, Schroeder TV. Revascularisation of atherosclerotic mesenteric arteries: Experience in 90 consecutive patients. *Eur J Vasc Surg* 1994;8:297-302.