

# Early Treatment for Laser-induced Maculopathy

Yan-Yun Chen<sup>1</sup>, Ning Lu<sup>1</sup>, Ji-Peng Li<sup>1</sup>, Jie Yu<sup>1</sup>, Lan Wang<sup>2</sup>

<sup>1</sup>Beijing Tongren Eye Center, Beijing Tongren Hospital, Capital Medical University, Beijing 100730, China

<sup>2</sup>Department of Ophthalmology, Beijing United Family Hospital, Beijing 100015, China

**Key words:** Corticosteroid; Laser; Maculopathy

Accidental exposure to the laser may result in visual impairment from retinal injury. Laser-induced damages to the macula include outer retinal disruption, foveal hemorrhage, macular edema, epiretinal membrane, full thickness macular hole, etc.<sup>[1,2]</sup> There are some case reports of visual improvement following the use of oral corticosteroids, but till date, there is no known effective treatment for this condition.<sup>[3,4]</sup> We report a case series of laser-induced maculopathy treated with standard doses of oral corticosteroids.

Consecutive patients who presented to the Tongren Eye Center with laser-induced maculopathy between August 2012 and December 2014 were included in the study. Those with macular hole at presentation underwent vitrectomy for macular hole were excluded. All patients underwent a comprehensive ophthalmic evaluation including measurement of best-corrected visual acuity (logMAR), fundus photography, and macular optical coherence tomography (OCT) scanning. Based on time to presentation after the laser injury, the patients were divided into two groups: an early group comprising those who presented within a week of sustaining injury and were treated with corticosteroids (Group 1); and those who presented after 1 week and as well as those who refused treatment (Group 2). The treatment group received oral prednisolone 1 mg/kg, for 3 days and tapered by 10 mg/week.

Nineteen patients (19 eyes) with laser-induced maculopathy were seen during the study. Six patients (6 eyes) with macular hole were excluded from the study. Hence, totally 13 eyes of 13 patients were included: 5 eyes of 5 patients in Group 1 and 8 eyes of 8 patients in Group 2. The age ranged from 7 to 28 years. The laser devices responsible for injury included 6 laser pointers, 5 laser toys, 1 laser torch, and 1 accidental exposure during cosmetic laser instrument. From the history, the approximate distance between the laser device ranged from 0.1 to 2.0 m and symptoms on presentation included decreased visual acuity, central scotomas, and metamorphopsia.

Maculopathy seen in Group 1 included: ellipsoid layer and retinal pigment epithelium (RPE) layer disruption, macular edema, and macular hemorrhage. During follow-up (3–10 months), there was no significant tissue proliferation in these eyes. OCT showed complete ellipsoid layer healing in 2 eyes in Group 1 [Figure 1]. The maculopathy in Group 2 included: macular pigment deficiency [5 eyes; Supplementary Figure 1 (a1 and a2)], ellipsoid layer and RPE layer disruption with RPE proliferation [1 eye; Supplementary Figure 1 (b1 and b2)], macular scar (1 eye), and epiretinal membrane [1 eye; Supplementary Figure 1 (c1 and c2)].

Visual acuity increased by two or more lines in four eyes (80%) in Group 1. However, in Group 2, only one eye showed an increase of two or more lines, 4 eyes remained the same as in their primary presentation, and 3 eyes showed decreased visual acuity.

There is no commonly accepted treatment or regimen for the use of corticosteroids in the treatment of acute laser retinal injury. Hossein *et al.*<sup>[3]</sup> reported a case after accidental exposure to a laser pointer exposure. Spectral-domain OCT showed a hyperreflective band in the foveal region with visual acuity of 20/200. The patient was treated with a high-dose of systemic corticosteroid. The hyperreflectivity resolved following 1 week of treatment with the improvement of visual acuity to 20/40. Lee *et al.*<sup>[4]</sup> reported 3 cases after laser exposure. Two cases were treated immediately with a 6-day oral methylprednisolone dose pack. OCT demonstrated partial resolution of the outer nuclear and external limiting

**Address for correspondence:** Dr. Ning Lu,  
Beijing Tongren Eye Center, Beijing Tongren Hospital, Capital Medical  
University, Beijing 100730, China  
E-Mail: luningnl@aliyun.com

This is an open access article distributed under the terms of the Creative Commons Attribution-NonCommercial-ShareAlike 3.0 License, which allows others to remix, tweak, and build upon the work non-commercially, as long as the author is credited and the new creations are licensed under the identical terms.

**For reprints contact:** reprints@medknow.com

© 2017 Chinese Medical Journal | Produced by Wolters Kluwer - Medknow

**Received:** 05-04-2017 **Edited by:** Yuan-Yuan Ji  
**How to cite this article:** Chen YY, Lu N, Li JP, Yu J, Wang L. Early Treatment for Laser-induced Maculopathy. Chin Med J 2017;130:2121-2.

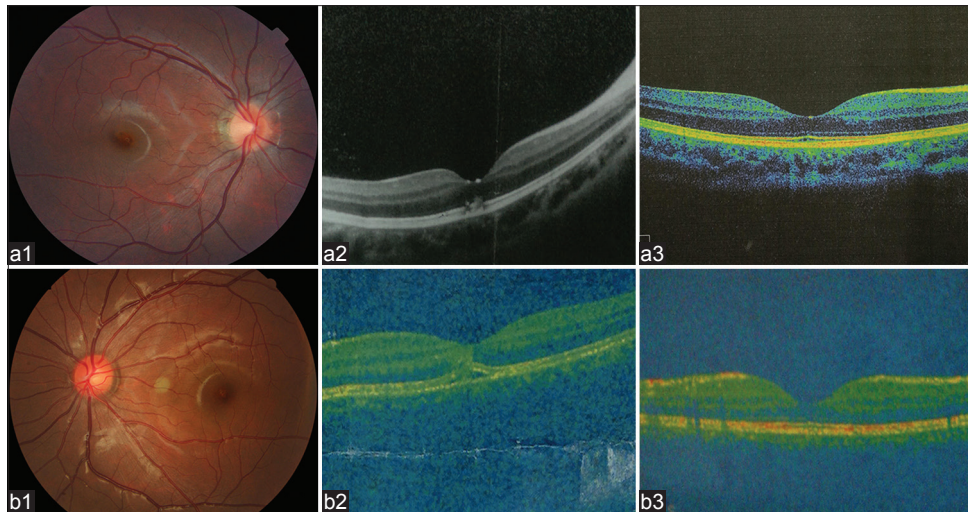
## Access this article online

### Quick Response Code:



**Website:**  
www.cmj.org

**DOI:**  
10.4103/0366-6999.213412



**Figure 1:** Fundus and OCT. Case 1 was hurt by a laser toy (a1–a3). The fundus showed disordered macular pigment (a1) in the macular at 7 days after exposure (BCVA 1.0). OCT (a2) demonstrated disruption of ELM and ellipsoid layer. The patient received early corticosteroids treatment immediately at his presentation. Ten months later (a3), the disruption of ELM and ellipsoid layer were completely repaired with good visual prognosis (BCVA 0.3). Case 2 was hurt by a laser torch (b1–b3). The fundus (b1) showed minor macular edema with BCVA of 0.3 at 2 days after exposure. OCT (b2) demonstrated disruption of ELM and ellipsoid layer, hyperreflective band in the foveal region indicating macular edema. The patient received early corticosteroid treatment immediately at his presentation. Five months later (b3), OCT showed disruption of ELM and ellipsoid layer were completely repaired (BCVA 0.1). OCT: Optical coherence tomography; ELM: External limiting membrane; BCVA: Best-corrected visual acuity.

membrane layer with the improvement of visual acuity to a certain degree. These reports suggest the benefit of systemic corticosteroid treatment in laser-induced maculopathy.

An earlier animal study also demonstrated the beneficial effect of methylprednisolone on laser-induced retinal lesions. Brown *et al.*<sup>[5]</sup> reported treatment with systemic methylprednisolone demonstrated improved photoreceptor survival in argon retinal lesions in rhesus monkeys. The pathophysiology of retinal laser injury is known to be composed of mechanical/thermal disruption of retinal architecture as well as retinal and choroidal vascular occlusion, a situation where lipid peroxidation plays an important role in mediating retinal destruction. The potent antioxidant and the anti-inflammatory ability to preserve blood-retinal barrier integrity suggest an important role for corticosteroids in minimizing laser-induced damage. Following treatment with steroids, two eyes in our series demonstrated resolution of damage to the ellipsoid layer with improvement in visual acuity. Three eyes demonstrated partial recovery of ellipsoid layer disruption and no significant tissue proliferation on follow-up. None of the eyes in Group 2 showed resolution of the ellipsoid layer lesion and OCT showed detected ellipsoid layer deficiency on follow-up. Furthermore, there were complications such as macular scar and the epiretinal membrane that compromised visual prognosis. The sample size is small, but visual prognosis was better in the treatment group. More data are required to better determine the role of corticosteroids in the treatment of laser-induced maculopathy.

*Supplementary information is linked to the online version of the paper on the Chinese Medical Journal website.*

### Declaration of patient consent

The authors certify that they have obtained all appropriate patient consent forms. In the form, the patient(s) has/have given his/her/their consent for his/her/their images and other clinical information to be reported in the journal. The patients understand that their names and initials will not be published and due efforts will be made to conceal their identity, but anonymity cannot be guaranteed.

### Financial support and sponsorship

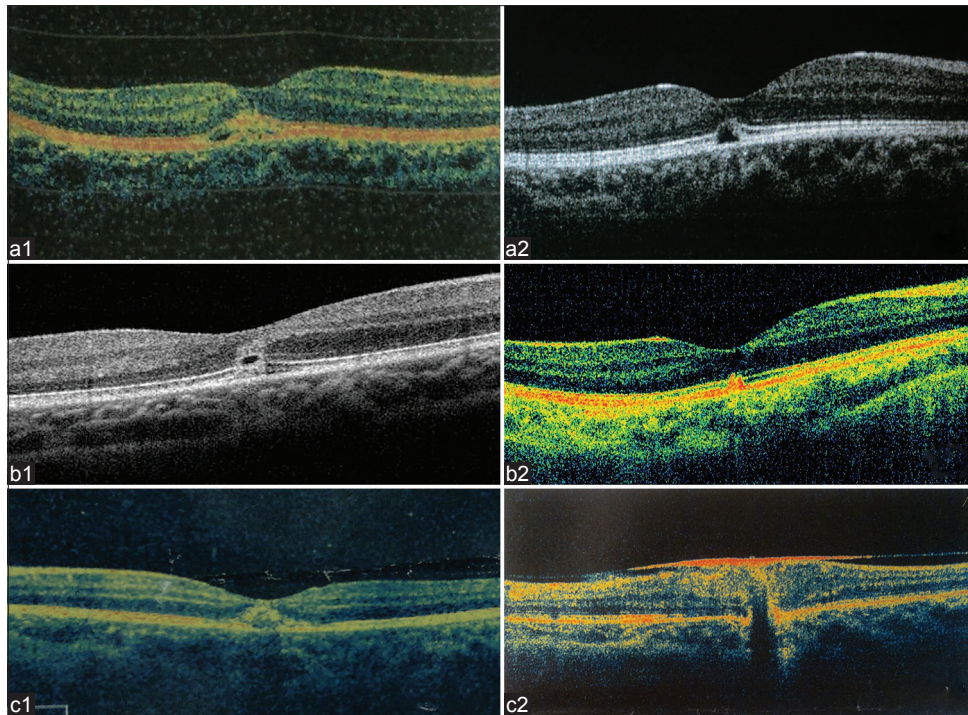
Nil.

### Conflicts of interest

There are no conflicts of interest.

### REFERENCES

1. Raoof N, Chan TK, Rogers NK, Abdullah W, Haq I, Kelly SP, *et al.* 'Toy' laser macular burns in children. *Eye (Lond)* 2014;28:231-4. doi: 10.1038/eye.2013.315.
2. Alsulaiman SM, Alrushood AA, Almasaud J, Alzaaidi S, Alzahrani Y, Arevalo JF, *et al.* High-power handheld blue laser-induced maculopathy: The results of the King Khaled Eye Specialist Hospital Collaborative Retina Study Group. *Ophthalmology* 2014;121:566-72.e1. doi: 10.1016/j.ophtha.2013.09.006.
3. Hossein M, Bonyadi J, Soheilian R, Soheilian M, Peyman GA. SD-OCT features of laser pointer maculopathy before and after systemic corticosteroid therapy. *Ophthalmic Surg Lasers Imaging* 2011;42:e135-8. doi: 10.3928/15428877-20111208-03.
4. Lee GD, Baurnal CR, Lally D, Pitcher JD, Vander J, Duker JS, *et al.* Retinal injury after inadvertent handheld laser exposure. *Retina* 2014;34:2388-96. doi: 10.1097/IAE.0000000000000397.
5. Brown J Jr., Hacker H, Schuschereba ST, Zwick H, Lund DJ, Stuck BE, *et al.* Steroidal and nonsteroidal antiinflammatory medications can improve photoreceptor survival after laser retinal photocoagulation. *Ophthalmology* 2007;114:1876-83. doi: 10.1016/j.ophtha.2007.04.035.



**Supplementary Figure 1:** OCT in the natural history group. Case 3 was hurt by a laser pointer (a1 and a2). OCT (a1) detected discontinuity in the outer photoreceptor layer with hyperreflective zone in the outer retina after 1 day of laser exposure (BCVA 0.7). Six months later, OCT showed ELM and ellipsoid layer deficiency in the macular (a2) without any improvement of BCVA. Case 4 was hurt by a laser pointer (b1 and b2). OCT (b1) showed a hyporeflective zone between the ELM and ellipsoid layer 2 days after injury with BCVA 0.3. Eight month later, OCT (b2) revealed discontinuity in the outer photoreceptor layers with retinal pigment epithelium proliferation in the outer retina (BCVA 0.7). Case 5 was hurt by a cosmetic laser (c1 and c2). OCT (c1) showed a mound of hyperreflectivity central foveal thickening with surrounding foci of disruption in the ellipsoid layer 1 day after exposure (BCVA 1.0). After 2 months, a thick end epiretinal membrane (c2) was detected with decreased BCVA. OCT: Optical coherence tomography; ELM: External limiting membrane; BCVA: Best-corrected visual acuity.