

REVIEW ARTICLE

## Recent advances in neoadjuvant chemoradiotherapy in locally advanced rectal cancer

Kazushige Kawai, Soichiro Ishihara, Hiroaki Nozawa, Keisuke Hata, Tomomichi Kiyomatsu, Toshiaki Tanaka, Takeshi Nishikawa, Kensuke Otani, Koji Yasuda, Koji Murono, Kazuhito Sasaki and Toshiaki Watanabe

*Department of Surgical Oncology, The University of Tokyo*

### Abstract:

Preoperative chemoradiotherapy (CRT) has been actively used in Europe and the United States to treat advanced low rectal cancer, and provides excellent local control. In Japan, however, the standard treatment is lateral lymph node dissection, and to date CRT has not been actively used. In recent years, an increasing number of Japanese institutions have been using preoperative CRT to treat locally advanced rectal cancer. In this review, we describe the latest trends in CRT under five headings: short-course or long-course radiation, efforts to improve combined chemotherapy, the addition of preoperative adjuvant chemotherapy, the watch and wait strategy, and the significance of lateral lymph node dissection in patients receiving CRT.

### Keywords:

advanced low rectal cancer, chemoradiotherapy, local recurrence, watch and wait

J Anus Rectum Colon 2017; 1(2): 39-44

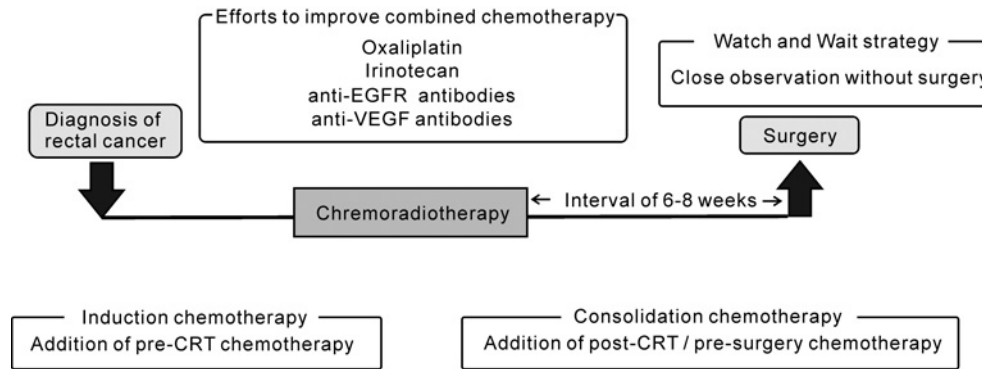
### Introduction

The standard treatment for advanced low rectal cancer differs significantly in Japan compared to Europe and the United States. In Europe and the United States, ever since the addition of radiotherapy was shown to be effective in reducing local recurrence in a number of clinical trials<sup>1,2)</sup>, radiotherapy has been actively used as part of the treatment for advanced low rectal cancer. In 2006, a clinical trial conducted by the European Organisation for Research and Treatment of Cancer (EORTC) showed that the combined use of chemotherapy significantly improved the effect of radiotherapy in limiting local recurrence<sup>3)</sup>, and currently the standard treatment comprises preoperative chemoradiotherapy (CRT) and total mesorectal excision (TME). In Japan, however, historically, emphasis has been placed on the development of surgical treatments rather than on radiotherapy, and the standard treatment according to the current guidelines for the management of colorectal cancer is TME and bilateral lymph node dissection<sup>4)</sup>. In Japan, a few institutions started to incorporate radiotherapy in treatments beginning in the 1980s, and CRT is now gradually emerging as an option for the treatment of locally advanced colorectal cancer

when R0 resection is infeasible. However, the 2014 guidelines still state that “In Japan, the value of preoperative chemoradiotherapy for rectal cancer in which the inferior margin of the tumor is on the anal side of the peritoneal reflection has yet to be established,” and it is yet to be adopted as the standard treatment. In recent years, a lot of studies have been conducted to improve the outcomes of CRT (Figure 1). In this review, we describe these latest trends in CRT under five headings: short-course or long-course radiation, efforts to improve combined chemotherapy, the addition of preoperative adjuvant chemotherapy, the watch and wait strategy, and the significance of lateral lymph node dissection in patients receiving CRT.

#### • Short-course or long-course radiation

Long-course radiation has conventionally been the mainstream method of radiotherapy. This approach involves administering a daily low dose of 1.8-2 Gy, up to a total dose of 45-50 Gy, over approximately a month. Surgery is generally performed 6-8 weeks after the completion of radiotherapy. Short-course radiation consists of the administration of a daily dose of 5 Gy for 5 days, to a total dose of 25 Gy, and performing surgery early on, approximately 7 days after



**Figure 1.** Efforts to improve the outcomes of chemoradiotherapy (CRT) for rectal cancer.

the completion of radiation. In terms of the course of treatment, short-course radiation has the major advantages of reducing the time required to complete treatment, but concerns about this procedure include the low response rate due to the short time before surgery is performed, as well as the risk of increased adverse events due to the high dose used in each session.

Two randomized comparative studies of short-course and long-course radiation have been performed to date. The first was a Polish study published in 2006, which compared 155 patients who underwent short-course radiation and 157 who underwent long-course radiation<sup>5</sup>. Although the pathological complete response (pCR) rate was 0.7% for the short-course group, significantly lower from the 16.1% achieved with long-course radiation, there was no difference in the incidence of postoperative complications or late effects, and no significant difference in overall survival, relapse-free survival, or local recurrence rates between the two groups. Another randomized comparative study of short-course and long-course radiation in 163 patients was carried out in Australia in 2012<sup>6</sup>. Similar to the Polish study, this study also found that the pCR rate was only 1% in the short-course group, compared with 15% in the long-course group, but that there were no differences in the incidences of postoperative complications or late effects, or in the overall survival or local recurrence rates. The results of these two comparative studies were extremely similar, suggesting that short-course radiation may have potential as a treatment that provides local control equivalent to that achieved by long-course radiation without increasing postoperative or late complications.

#### • Efforts to improve combined chemotherapy

5FU-based anticancer agents are used as chemotherapy in combination with normal radiotherapy methods, with the aim of increasing sensitivity to radiation. A number of trials comparing capecitabine with the continuous infusion of 5FU were performed in the late 2000s<sup>7</sup>, and these showed that the response to capecitabine was not inferior to that achieved by 5FU. Oral anticancer drugs are far superior in terms of both cost and convenience to patients, and today oral 5FU formulations such as capecitabine are used most

commonly for treatment. However, the pCR rate obtained from capecitabine alone is only around 10%-20%<sup>8</sup>. As patients who exhibit a good pathological response also have a good prognosis, attempts to increase this response rate by improving the anticancer agents used in combination with radiotherapy are underway, worldwide.

The largest number of clinical trials have tested regimens that incorporate oxaliplatin (Table 1). The NSABP-R04 trial (United States)<sup>9,10</sup>, the STAR-01 trial (Italy)<sup>11</sup>, the ACCORD 12 trial (France)<sup>12</sup>, the CAO/ARO/AIO-04 trial (Germany)<sup>13</sup>, the FOWARC trial (China)<sup>14</sup>, and others were all Phase III randomized comparative trials that compared 5FU monotherapy with regimens that also included oxaliplatin (Table 1). Unfortunately, however, most of these trials found that although there was no difference in response rate between the two groups, adverse events were significantly more common in patients who also received oxaliplatin. In the CAO/ARO/AIO-04 trial, the pCR was 13% in the 5FU monotherapy arm and 17% for the 5FU+oxaliplatin arm, significantly higher in the latter ( $p = 0.04$ ), with no difference in the incidence of adverse events. However, in that trial, the method of administration and dosage of 5FU were different in the 5FU monotherapy arm and the 5FU+oxaliplatin arm, and the difference in the pCR rate may not have simply been due to the additional effect of oxaliplatin. In terms of Japanese clinical trials, Ishihara *et al.* and Matsuzaka *et al.* have reported the results of the SHOGUN Phase I and II clinical trials of a combination regimen of S-1 and oxaliplatin<sup>15,16</sup>. Although those trials had a low enrollment of 44 patients, the pCR rate was 27.3%, far higher than those seen in other trials, with the incidence of Grade 3 or 4 adverse events less than half those of other trials at only 11.1%. As these results were better than those previously reported for 5FU continuous infusion or regimens containing capecitabine, we consider that gimeracil, one of the constituents of S1, may increase the concentration of 5FU, improving sensitivity to radiation, while oteracil potassium, another ingredient in S1, may act to reduce adverse events. No long-term outcomes from this trial have yet been reported, and their future publication is awaited. A number of Phase I and II trials of regimens containing irinotecan have also reported good outcomes<sup>17,18</sup>, but there have been no reports as yet of any

**Table 1.** Clinical Trials Have Tested Regimens That Incorporate Oxaliplatin

Trial Name	Country	Year of publication	Phase	Number of patients	Regimen	pCR rate (control versus combined oxaliplatin)	Grade 3 or 4 adverse events (control versus combined oxaliplatin)
NSABP-R04 (9)	United States	2014	III	1,608	5FU/capecitabine+ oxaliplatin	17.8% vs. 19.5% n.s.	5FU 26.5% vs. 40.1% Capecitabine 30.1% vs. 41.9%
STAR-01 (11)	Italy	2011	III	747	5FU+oxaliplatin	16% vs. 16% n.s.	8% vs. 24%, p<0.001
ACCORD 12 (12)	France	2012	III	598	Capecitabine+ oxaliplatin	13.9% vs. 19.2% n.s.	10.9% vs. 25.4%, p<0.001
CAO/ARO/AIO-04 (13)	Germany	2012	III	1,265	5FU+ oxaliplatin	13% vs. 17%, p=0.038	20% vs. 23%
FOWARC (14)	China	2016	III	495	5-FU+ leukovorin+ oxaliplatin	14.0% vs. 27.5%	Leukopenia 12.9% vs. 19.0% Diarrhea 7.7% vs. 14.1%
SHOGUN (15, 16)	Japan	2015	II	44	S1+ oxaliplatin	27.3%	11.1%

n.s. not significant

Phase III trial comparing 5FU monotherapy with a regimen including irinotecan. We are currently awaiting the results of the ARISTOTLE (Advanced Rectal study with Standard Therapy Or a novel agent, Total mesorectal excision and Long term Evaluation) trial, a Phase III randomized trial currently underway in the United Kingdom.

Molecular targeted drugs are another alternative for addition to the regimens. Numerous Phase I and II trials of regimens including anti-epidermal growth factor receptor (anti-EGFR) antibodies have been performed, but as the overall pCR rate is only about 9%, they cannot be described as superior to 5FU monotherapy regimens<sup>8</sup>. The primary endpoint was not achieved in any of these studies, and they all concluded without progressing to a Phase III trial. A number of Phase I and II trials of anti-vascular endothelial growth factor (anti-VEGF) antibodies have also been reported, such as that by Willett *et al.*, who found that five of 32 patients (16%) achieved pCR with the combined use of bevacizumab<sup>19</sup>, but these trials included few control subjects, and it cannot be said that the additional effect of bevacizumab has been demonstrated clearly. A number of other regimens have also been studied in clinical trials, such as the combination of oxaliplatin and molecular targeted drugs, but in all of these studies patient numbers were low, and none has yet provided sufficient evidence for their effectiveness as regimens.

Worldwide, efforts are thus actively underway to improve the regimens used in CRT, but at this point no definitive consensus has been achieved, and the results of further clinical studies are awaited.

#### • Addition of preoperative adjuvant chemotherapy

Another approach to increasing the effectiveness of CRT is to administer additional chemotherapy before or after CRT. Additional chemotherapy before the start of CRT is known as “induction chemotherapy,” and Phase II studies are underway with the anticipation that the introduction of such chemotherapy will improve the pCR rate and prove

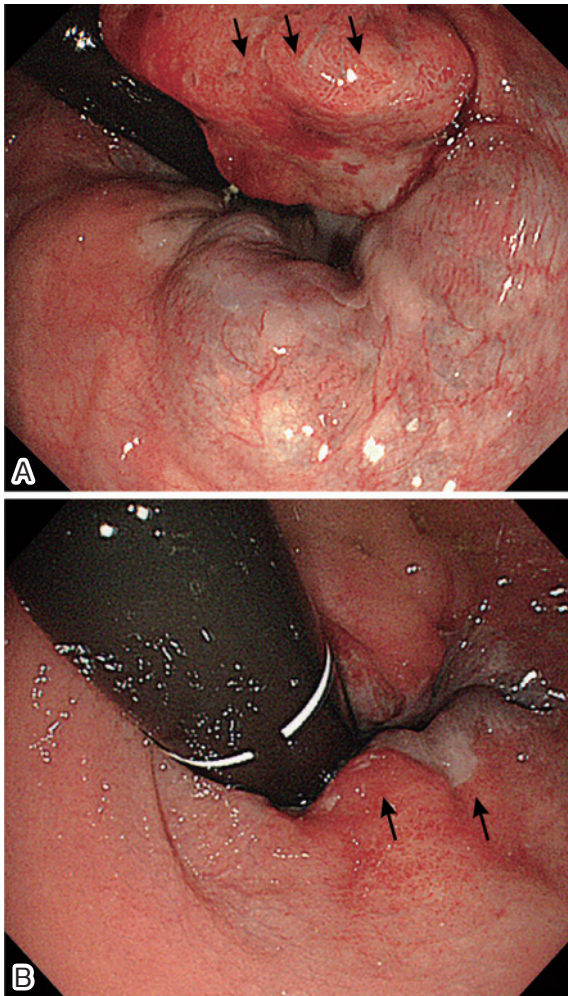
more tolerable than postoperative adjuvant chemotherapy. Various different regimens for combined use have been reported, including FOLFOX<sup>20</sup>, CapeOX [the EXPERT trial<sup>21</sup> and GCR-3 trial<sup>22</sup>], CapeOX + cetuximab (the EXPERT-C trial<sup>23</sup>), and FOLFOX + bevacizumab<sup>24</sup>. However, no randomized comparative clinical trial has demonstrated that induction chemotherapy significantly improved the pCR rate, and although in the GCR trial induction chemotherapy, before the start of CRT was found to be more tolerable than postoperative adjuvant chemotherapy and with fewer adverse events, it did not improve the long-term prognosis, with no significant difference in overall survival or the local recurrence rate.

Additional chemotherapy administered after CRT, but before surgery, is known as “consolidation chemotherapy,” and it is attracting attention as a method of making use of the period between CRT and surgery. Many institutions leave a six-week break between the end of CRT and surgery, and as a longer waiting period increases the pCR rate, there has been a tendency to extend this period in recent years. In some cases, it may exceed 2 months, and the goal of consolidation chemotherapy is to improve the pCR rate by the addition of FOLFOX or another chemotherapy regimen during this long waiting period. In 2011, Garcia-Aguilar *et al.* compared 60 patients who were administered CRT alone with 67 patients who were administered CRT and two cycles of FOLFOX, and found that the pCR rate improved significantly from 18% for the former group to 25% for the latter, with no difference in adverse events<sup>25</sup>. Efforts are therefore currently underway worldwide to adapt the “C” component of CRT by adjusting the timing of administration and dosage in order to provide more effective therapy.

#### • Watch and wait strategy

As described above, around 10%-20% of patients who undergo radical surgery after CRT achieve pCR, with no residual cancer cells found in pathology specimens, and if it could be determined preoperatively whether or not pCR has





**Figure 2.** An endoscopic view before (A) and after CRT (B). Marginal swelling (Black arrows) completely flattened after CRT, and the central ulcer was covered with regenerating epithelium.

been achieved, then these patients would not require additional radical surgery, making it possible to cure their cancer with CRT alone. Clinical complete response (cCR), in which endoscopy reveals that the tumor has almost disappeared and cancer is not detected by biopsy, is achieved by some patients after preoperative CRT (Figure 2), but patients with cCR do not necessarily correspond to those who achieve pCR, with residual cancer found in pathological samples from resected specimens in many patients who achieve cCR. Attempts are currently underway worldwide to use FDG-PET, MRI, and other diagnostic imaging modalities performed after CRT for the preoperative prediction of pCR, but in many cases, a few cancer cells persist in deep tissues, even if the cancer has completely disappeared from the mucosa, and as yet, no completely reliable method of predicting pCR has been established.

The “watch and wait” (W&W) strategy has recently come into use for patients who have achieved cCR, mainly in Europe and the United States. This entails carefully monitoring the patient rather than immediately performing surgery, and only carrying out radical surgery as salvage therapy if the tumor again starts to increase in size. This offers the ma-

ior benefit of enabling the rectum to be conserved in patients who have achieved true pCR, avoiding the risk of stoma in patients with cancers near the anus in particular. The results of a number of studies have been published, with the largest number of patients having been enrolled by Gama *et al.*'s group in Brazil, who in a 2014 paper stated that 90 of 183 patients with rectal cancer who underwent CRT had achieved cCR in their initial assessment<sup>26</sup>. Additional treatment for cancer recurrence was required in 28 of these patients, meaning that the rectum was ultimately preserved in 62 patients, or approximately one third of the total, a good result.

In that study, however, two of the 28 patients in whom the cancer recurred, died without salvage surgery having been feasible. Even if there is no residual cancer on the surface of the mucosa after CRT, cancer cells often persist in deeper tissues, such as the muscularis, and any recurrent growth of this residual cancer is difficult to detect at an early stage by endoscopy or CT. Accordingly, a relapse may go unnoticed until after the possibility for radical surgery is invalidated. If patients who achieve cCR decide to undergo radical surgery, in almost all cases local control is extremely good, with no local recurrence, and until adequate methods of surveillance for relapse are established, given Japan's current situation, the immediate introduction of W&W is still too high a risk.

#### • *The significance of lateral lymph node dissection in CRT patients*

As described above, CRT + TME is the standard treatment in Europe and the United States, and lateral lymph node dissection is not usually performed. This policy is based on the idea that lateral lymph node metastases are distant metastases and as such constitute a “systemic condition,” and TNM staging reflects this, with lateral lymph node metastasis classified as an M factor. In the Japanese guidelines for the treatment of colorectal cancer, however, lateral lymph nodes are classified as N3 lymph nodes, and as such are among those to be dissected. In a 2012 study, Akiyoshi *et al.* reported that the dissection of lateral lymph nodes in the internal iliac region enables far better survival than that for Stage IV, indicating the importance for survival of controlling some lateral lymph nodes as regional lymph nodes<sup>27</sup>. Lateral lymph node metastasis can be controlled to some extent by preoperative CRT, but a unified consensus has yet to be achieved regarding whether or not lateral lymph node dissection is also required for patients who have undergone CRT. In 2001, Nagawa *et al.* reported the results of a single-center randomized study in which they compared patients with advanced low rectal cancer who underwent radiotherapy alone with those who also underwent lateral lymph node dissection<sup>28</sup>. They found that the addition of lateral lymph node dissection made no difference to overall survival or disease-free survival, but that it did make a significant difference to urinary and sexual function. Nagawa *et al.* therefore argued that the performance of preventive lat-

eral lymph node dissection in addition to radiotherapy was of little significance. No subsequent randomized comparative studies have been performed, however, and practice varies greatly even among Japanese institutions that employ CRT, with some carrying out preventive lymph node dissection in all patients, some only using it for patients in whom lateral lymph node metastasis is suspected prior to CRT, and some performing it only if lateral lymph node metastasis is suspected even after CRT.

### Conclusion

Although preoperative CRT is an outstandingly useful treatment for the local control of advanced low rectal cancer, it has little effect on prolonging survival, and has also been reported to cause complications, such as reduced anal function and late effects. Whether to restrict the use of CRT to patients in whom it will be highly effective and those at high risk of local recurrence, rather than performing it for all patients according to the same protocol, is therefore a question that is currently being explored. In the future, we may be able to provide personalized treatments, based on the results of studies of a range of different biomarkers and diagnostic imaging techniques, to predict the effectiveness of CRT.

#### Conflicts of Interest

There are no conflicts of interest.

#### References

1. Initial report from a Swedish multicentre study examining the role of preoperative irradiation in the treatment of patients with resectable rectal carcinoma. Swedish Rectal Cancer Trial. *Br J Surg*. 1993 Oct; 80(10): 1333-6.
2. Hyams DM, Mamounas EP, Petrelli N, et al. A clinical trial to evaluate the worth of preoperative multimodality therapy in patients with operable carcinoma of the rectum: A progress report of National Surgical Breast and Bowel Project Protocol R-03. *Dis Colon Rectum*. 1997 Feb; 40(2): 131-9.
3. Bosset JF, Collette L, Calais G, et al. Chemotherapy with preoperative radiotherapy in rectal cancer. *N Engl J Med*. 2006 Sep; 355(11): 1114-23.
4. Watanabe T, Itabashi M, Shimada Y, et al. Japanese Society for Cancer of the Colon and Rectum (JSCCR) Guidelines 2014 for treatment of colorectal cancer. *Int J Clin Oncol*. 2015 Apr; 20(2): 207-39.
5. Bujko K, Nowacki MP, Nasierowska-Guttmejer A, et al. Long-term results of a randomized trial comparing preoperative short-course radiotherapy with preoperative conventionally fractionated chemoradiation for rectal cancer. *Br J Surg*. 2006 Oct; 93(10): 1215-23.
6. Ngan SY, Burmeister B, Fisher RJ, et al. Randomized trial of short-course radiotherapy versus long-course chemoradiation comparing rates of local recurrence in patients with T3 rectal cancer: Trans-Tasman Radiation Oncology Group trial 01.04. *J Clin Oncol*. 2012 Nov; 30(31): 3827-33.
7. Hofheinz RD, Wenz F, Post S, et al. Chemoradiotherapy with capecitabine versus fluorouracil for locally advanced rectal cancer: A randomised, multicentre, non-inferiority, phase 3 trial. *Lancet Oncol*. 2012 Jun; 13(6): 579-88.
8. Fernandez-Martos C, Nogue M, Cejas P, et al. The role of capecitabine in locally advanced rectal cancer treatment: An update. *Drugs*. 2012 May; 72(8): 1057-73.
9. O'Connell MJ, Colangelo LH, Beart RW, et al. Capecitabine and oxaliplatin in the preoperative multimodality treatment of rectal cancer: Surgical end points from National Surgical Adjuvant Breast and Bowel Project trial R-04. *J Clin Oncol*. 2014 Jun; 32(18): 1927-34.
10. Allegra CJ, Yothers G, O'Connell MJ, et al. Neoadjuvant 5-FU or Capecitabine Plus Radiation With or Without Oxaliplatin in Rectal Cancer Patients: A Phase III Randomized Clinical Trial. *J Natl Cancer Inst*. 2015 Nov; 107(11).
11. Aschele C, Cionini L, Lonardi S, et al. Primary tumor response to preoperative chemoradiation with or without oxaliplatin in locally advanced rectal cancer: Pathologic results of the STAR-01 randomized phase III trial. *J Clin Oncol*. 2011 Jul; 29(20): 2773-80.
12. Gerard JP, Azria D, Gourgou-Bourgade S, et al. Clinical outcome of the ACCORD 12/0405 PRODIGE 2 randomized trial in rectal cancer. *J Clin Oncol*. 2012 Dec; 30(36): 4558-65.
13. Rodel C, Liersch T, Becker H, et al. Preoperative chemoradiotherapy and postoperative chemotherapy with fluorouracil and oxaliplatin versus fluorouracil alone in locally advanced rectal cancer: Initial results of the German CAO/ARO/AIO-04 randomised phase 3 trial. *Lancet Oncol*. 2012 Jul; 13(7): 679-87.
14. Deng Y, Chi P, Lan P, et al. Modified FOLFOX6 With or Without Radiation Versus Fluorouracil and Leucovorin With Radiation in Neoadjuvant Treatment of Locally Advanced Rectal Cancer: Initial Results of the Chinese FOWARC Multicenter, Open-Label, Randomized Three-Arm Phase III Trial. *J Clin Oncol*. 2016 Sep; 34(27): 3300-7.
15. Ishihara S, Matsusaka S, Kondo K, et al. A phase I dose escalation study of oxaliplatin plus oral S-1 and pelvic radiation in patients with locally advanced rectal cancer (SHOGUN trial). *Radiat Oncol*. 2015 Jan; 10: 24.
16. Matsusaka S, Ishihara S, Kondo K, et al. A multicenter phase II study of preoperative chemoradiotherapy with S-1 plus oxaliplatin for locally advanced rectal cancer (SHOGUN trial). *Radiother Oncol*. 2015 Aug; 116(2): 209-13.
17. Gollins SW, Myint S, Susnerwala S, et al. Preoperative downstaging chemoradiation with concurrent irinotecan and capecitabine in MRI-defined locally advanced rectal cancer: A phase I trial (NWC0G-2). *Br J Cancer*. 2009 Sep; 101(6): 924-34.
18. Willeke F, Horisberger K, Kraus-Tiefenbacher U, et al. A phase II study of capecitabine and irinotecan in combination with concurrent pelvic radiotherapy (CapIri-RT) as neoadjuvant treatment of locally advanced rectal cancer. *Br J Cancer*. 2007 Mar; 96(6): 912-7.
19. Willett CG, Duda DG, di Tomaso E, et al. Efficacy, safety, and biomarkers of neoadjuvant bevacizumab, radiation therapy, and fluorouracil in rectal cancer: A multidisciplinary phase II study. *J Clin Oncol*. 2009 Jun; 27(18): 3020-6.
20. Marechal R, Vos B, Polus M, et al. Short course chemotherapy followed by concomitant chemoradiotherapy and surgery in locally advanced rectal cancer: A randomized multicentric phase II study. *Ann Oncol*. 2012 Jun; 23(6): 1525-30.
21. Chua YJ, Barbachano Y, Cunningham D, et al. Neoadjuvant capecitabine and oxaliplatin before chemoradiotherapy and total mesorectal excision in MRI-defined poor-risk rectal cancer: A phase 2 trial. *Lancet Oncol*. 2010 Mar; 11(3): 241-8.
22. Fernandez-Martos C, Garcia-Albeniz X, Pericay C, et al. Chemoradiation, surgery and adjuvant chemotherapy versus induc-

- tion chemotherapy followed by chemoradiation and surgery: Long-term results of the Spanish GCR-3 phase II randomized trial. *Ann Oncol*. 2015 Aug; 26(8): 1722-8.
23. Dewdney A, Cunningham D, Taberero J, et al. Multicenter randomized phase II clinical trial comparing neoadjuvant oxaliplatin, capecitabine, and preoperative radiotherapy with or without cetuximab followed by total mesorectal excision in patients with high-risk rectal cancer (EXPERT-C). *J Clin Oncol*. 2012 May; 30(14): 1620-27.
24. Borg C, Andre T, Mantion G, et al. Pathological response and safety of two neoadjuvant strategies with bevacizumab in MRI-defined locally advanced T3 resectable rectal cancer: A randomized, noncomparative phase II study. *Ann Oncol*. 2014 Nov; 25(11): 2205-10.
25. Garcia-Aguilar J, Smith DD, Avila K, et al. Optimal timing of surgery after chemoradiation for advanced rectal cancer: Preliminary results of a multicenter, nonrandomized phase II prospective trial. *Ann Surg*. 2011 Jul; 254(1): 97-102.
26. Habr-Gama A, Gama-Rodrigues J, Sao Juliao GP, et al. Local recurrence after complete clinical response and watch and wait in rectal cancer after neoadjuvant chemoradiation: Impact of salvage therapy on local disease control. *Int J Radiat Oncol Biol Phys*. 2014 Mar; 88(4): 822-8.
27. Akiyoshi T, Watanabe T, Miyata S, et al. Results of a Japanese nationwide multi-institutional study on lateral pelvic lymph node metastasis in low rectal cancer: Is it regional or distant disease? *Ann Surg*. 2012 Jun; 255(6): 1129-34.
28. Nagawa H, Muto T, Sunouchi K, et al. Randomized, controlled trial of lateral node dissection vs. nerve-preserving resection in patients with rectal cancer after preoperative radiotherapy. *Dis Colon Rectum*. 2001 Sep; 44(9): 1274-80.

Journal of the Anus, Rectum and Colon is an Open Access article distributed under the Creative Commons Attribution-NonCommercial-NoDerivatives 4.0 International License. To view the details of this license, please visit (<https://creativecommons.org/licenses/by-nc-nd/4.0/>).