

# Effect of Highly Active Antiretroviral Therapy on Fundus Images and Retinal Microvessel Diameter in HIV/AIDS Patients

Qin Li<sup>1,\*</sup>, Dongqiong Chen<sup>2,\*</sup>, Fang Ye<sup>3</sup>, Xiaoying Wang<sup>4</sup>, Shangsong Yang<sup>1</sup>, Li Wang<sup>5</sup>, Weibo Wen<sup>2</sup>

<sup>1</sup>Department of Basic Theory of Traditional Chinese Medicine, Yunnan University of Traditional Chinese Medicine, Kunming, People's Republic of China; <sup>2</sup>Department of Gynecology, the First Affiliated Hospital of Yunnan University of Traditional Chinese Medicine, Kunming, People's Republic of China; <sup>3</sup>TCM for AIDS Project Office, Linxiang Hospital of Traditional Chinese Medicine, Lincang, People's Republic of China; <sup>4</sup>Research and Teaching Management Section, Kunming Municipal Hospital of Traditional Chinese Medicine, Kunming, People's Republic of China; <sup>5</sup>Clinical Research Centre for the Prevention and Treatment of AIDS in Chinese Medicine, Yunnan Institute of Traditional Chinese Medicine, Kunming, People's Republic of China

\*These authors contributed equally to this work

Correspondence: Weibo Wen, Department of Gynecology, the First Affiliated Hospital of Yunnan University of Traditional Chinese Medicine, Kunming, Yunnan, People's Republic of China, Email weibowen1968@hotmail.com; Li Wang, Clinical Research Centre for the Prevention and Treatment of AIDS in Chinese Medicine, Yunnan Institute of Traditional Chinese Medicine, Kunming, People's Republic of China, Email wanglichina1234567890@hotmail.com

**Introduction:** We aimed to investigate whether there were changes in fundus picture and retinal microvasculature of patients with human immunodeficiency virus (HIV)/acquired immune deficiency syndrome (AIDS) who were treated with highly active antiretroviral therapy (HAART).

**Methods:** From July 2015 to November 2016, 130 HIV/AIDS patients were collected by the Yunnan Institute of Traditional Chinese Medicine, including 63 treatment-naïve patients and 67 that received HAART for 12 months. Fundus picture lesions, retinal microvascular diameters, CD4+ T lymphocyte count and HIV-1 plasma viral loads were compared between the two groups. The recruited patients were mainly young and middle-aged, with more males than females. There were no significant differences in smoking history, comorbidities and opportunistic infections between the two groups.

**Results:** According to the analysis results from SPSS 20.0 software, the number of CD4+ T lymphocytes in the treated patients ( $563.34 \pm 2.56$  cells/ $\mu$ L) increased significantly ( $P=0.009$ ) as compared with untreated patients ( $451.37 \pm 2.10$  cells/ $\mu$ L), and the HIV-1 plasma viral load reduced considerably (4794 vs 0 copy/mL,  $P=0.000$ ). No significant differences were observed from the fundus picture of patients after effective HAART therapy, including the retinal artery diameter, venous diameter and arteriovenous diameter ratio.

**Keywords:** fundus, retinal microvascular, HIV/AIDS, HAART

## Introduction

Microangiopathy has an incidence of 70% in Acquired Immune Deficiency Syndrome (AIDS) patients.<sup>1,2</sup> Known as human immunodeficiency virus (HIV) retinopathy, microangiopathy mostly occurs in the retina and mainly manifests as cotton wool plaques.<sup>3,4</sup> Other manifests are telangiectasia, microangioma, retinal hemorrhage, and rarely Roth spots. For HIV retinopathy patients, their CD4+ T lymphocyte number will decrease to less than 200 cells/ $\mu$ L, and with the decrease of CD4+ T lymphocytes the incidence of opportunistic infections will increase gradually.<sup>5</sup> Early treatment of highly active anti-retroviral therapy (HAART) can restrain HIV replication and increase the number of CD4+ T lymphocytes, thus reducing the incidence of HIV retinopathy.<sup>6</sup> However, the use of antiviral drugs during long-term HAART will cause varying side effects, such as drug-induced liver damage, lipodystrophy, etc.<sup>7</sup> Reassuringly, these side effects can be reflected by changes in the retinal microvascular.<sup>8,9</sup> Abnormalities of retinal microvascular are usually earlier than clinical symptoms and abnormal organ function indicators, which can be used for monitoring and early warning of

adverse reactions of AIDS and can be preliminarily predicted to avoid serious consequences before the occurrence of adverse reactions.<sup>10</sup>

To date, the non-invasive detection of retinal can be achieved by using traditional retinal imaging technology and integrating optical wavelength imaging technology.<sup>11</sup> Besides, with the help of retinal image reading technology based on cloud computing, the retinal vascular diameter and other retinal disease information can be precisely collected, which makes it convenient to evaluate the efficacy of HAART or predict HAART induced side effects by monitoring the retinal microvascular changes.<sup>10</sup> However, only a few studies on the changes of retinal microvascular in AIDS patients after HAART have been reported.<sup>12,13</sup>

To verify whether there are changes in the fundus picture and the diameters of retinal microvascular in HIV patients after improved immunity due to HAART, we reviewed the clinical data of 130 HIV/AIDS patients including fundus lesions, retinal microvascular diameters, CD4+ T lymphocyte counts and HIV-1 plasma viral loads.

## Materials and Methods

### Patients

From July 2015 to November 2016, 130 HIV/AIDS patients from Yunnan Institute of Traditional Chinese Medicine were collected. All patients were enrolled in the Yunnan Province Chinese Medicine Treatment AIDS Pilot Project and confirmed HIV-positive by the local Center for Disease Control (CDC). The Inclusion criteria were as follows: patient age 18–60 years; participated in the test voluntarily; able to strictly abide by the research requirements; and had full mental capacity. The exclusion criteria were as follows: pregnant or lactating; enrolled in clinical trials for other AIDS-related drugs within 1 year prior to enrolment; received AIDS-related immunomodulatory therapy within 1 year before enrolment; were allergic to the medications used in the study; and had a severe neurological or mental illness.

The enrolled patients were divided into two groups. The untreated group, consisting of 63 patients, did not receive any treatment. The treatment group included 67 patients, received the first-line HAART regimen for 12 months recommended by the state. The study was approved by the Ethics Committee of Yunnan Academy of Traditional Chinese Medicine (No. 2015002). All procedures performed in studies involving human participants were in accordance with the ethical standards of the institutional and national research committee and with the 1964 Helsinki Declaration and its later amendments or comparable ethical standards. All included patients provided informed consent.

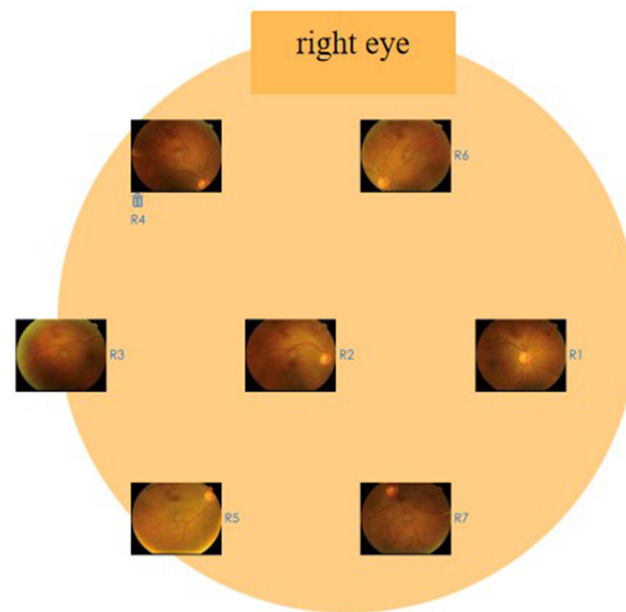
### Fundus Measurement

Before and after treatment, two colored fundus pictures were taken for each eye by the same ophthalmologist using a Japanese Kowa Nonmyd WX3D nondilated eye camera (with a precision of 9 microns per pixel), at 50° angle with the optic disc at the center. Then, the fundus pictures and basic information of each patient were uploaded to a fundus evaluation platform (Figure 1 shows the interface of the platform) for following analysis (Sichuan Heal Thsun Vision Technology Development Co., Ltd).

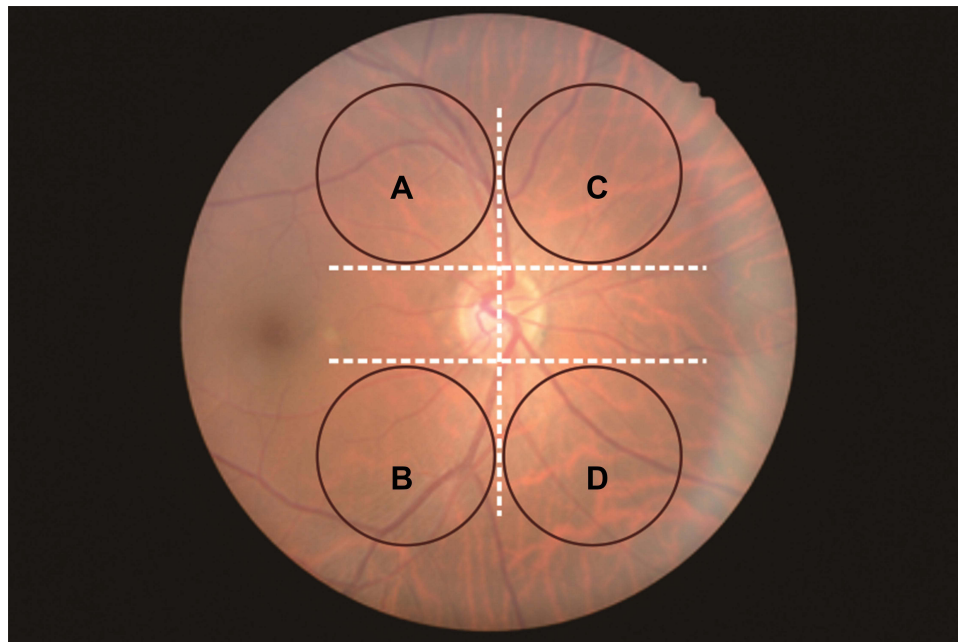
For fundus lesion detection, the conditions of fundus bleeding, microhemangioma, cotton-like soft exudation and hard exudation were observed. For retinal microvascular diameter measurement, four areas within the region 1–1.5 PD from the edge of the optic disc were selected as the observation area (as shown in the schematic diagram of Figures 2 and 3). Microvascular diameters of the retinal arteries and veins were extracted from the four quadrants, respectively, as shown in Figure 4, and the corresponding arteriovenous ratios were calculated.

### Absolute CD4+ T Lymphocyte Counts

Firstly, 1.5 mL of peripheral venous blood was collected from the patients with EDTAK2 anticoagulation negative pressure vacuum blood collection tube. Then, within 48 hours, the blood samples were incubated with FITC-conjugated CD4 antibody Kit (38939; BD Biosciences), and analyzed by a flow cytometer (Becton, Dickinson and Company) according to the instructions of the manufacturers.



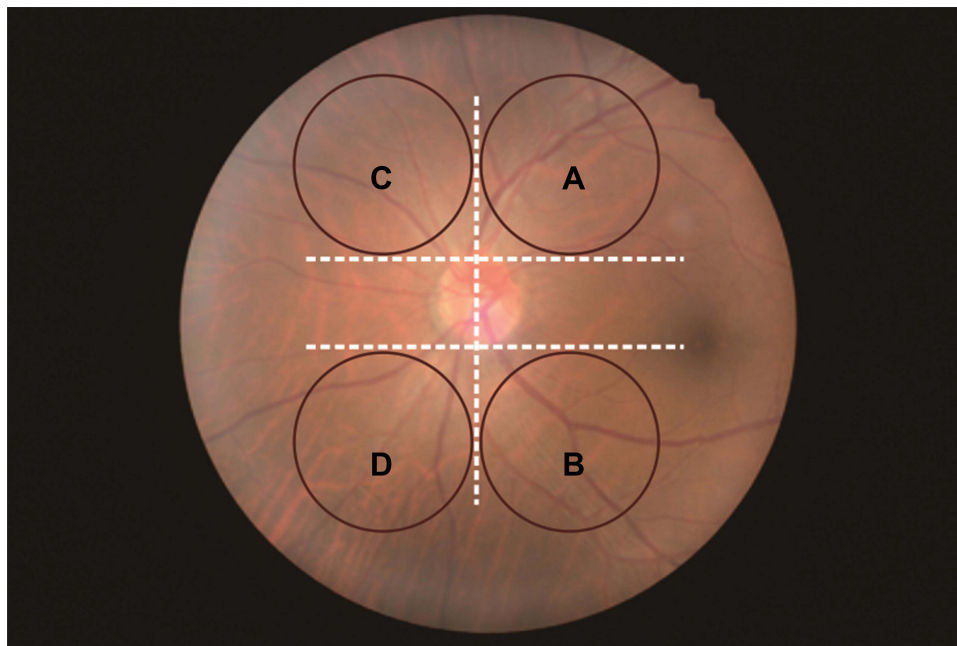
**Figure 1** Interface of the fundus picture analysis platform. The general information and fundus picture were uploaded and analyzed on the platform at Sichuan HealthSun Vision Medical Technology Development Co.,Ltd ([Sichuan HealthSun Vision](http://www.healthsunvision.com)).



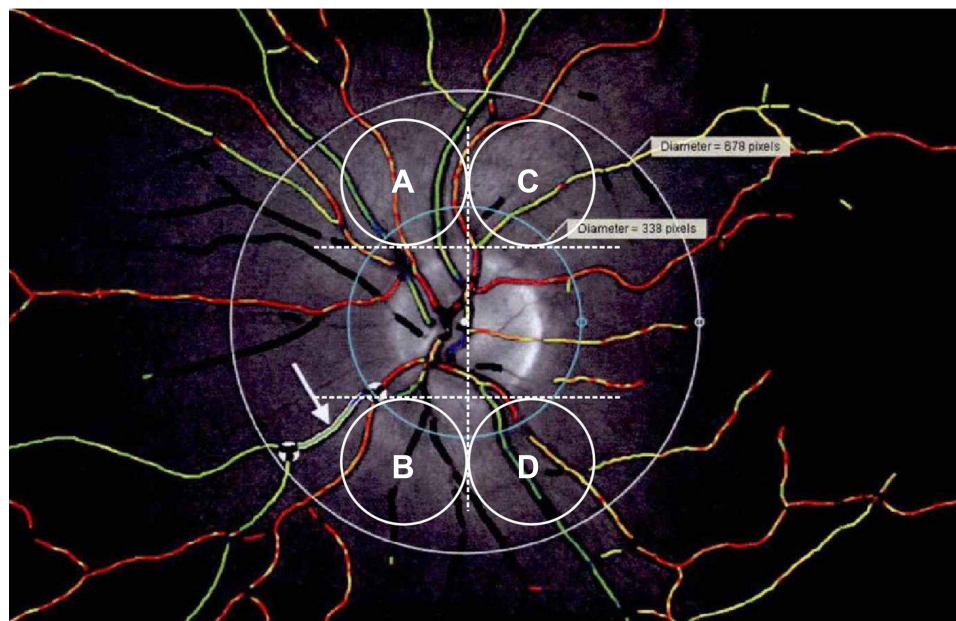
**Figure 2** Schematic diagram of the 4 areas selected for analysis of right eye. (A) superior temporal, (B) inferior temporal, (C) superior nasal, (D) under nasal.

## HIV-1 Viral Load Determination

A 3–5mL of peripheral venous blood was collected from each patient and centrifuged at 3000 rpm for 20 minutes at room temperature, supernatant was transferred to a sterile centrifuge tube for nucleic acid extraction using a NP968-C nucleic acid extractor (Xi'an Tianlong Technology Co., Ltd.). The PCR-fluorescent probe method was performed using a Sun Yat-Sen University Daan Gene Detection Kit (06/2015; Sun Yat-sen University Daan Gene Co., Ltd.) to detect the blood HIV viral load, on a ABI DA7600RT-PCR instrument.



**Figure 3** Schematic diagram of the 4 areas selected for analysis of left eye. (A) superior temporal, (B) inferior temporal, (C) superior nasal, (D) under nasal.



**Figure 4** Retinal microvascular diameter measurement. The measurement area was 1–1.5PD, as outlined by the two circles with a distance of 0.5PD. Red color indicates artery and green color indicates vein. (A) superior temporal, (B) inferior temporal, (C) superior nasal, (D) under nasal.

## Statistical Analysis

Statistical analyses were performed using SPSS 20.0 software. The measurement data with normal distribution were described as mean  $\pm$  standard deviation ( $\bar{x} \pm s$ ), and those with non-normal distribution were described by median (interquartile range). According to whether the data follow normal distribution or not, a nonparametric test (Mann–Whitney U-Rank sum test), chi-square test or Fisher's accurate probability test were used to analyze differences in age, gender, smoking history, comorbidity and opportunistic

infection between the two groups. Independent sample *t*-tests or nonparametric test (Mann–Whitney *U*-test) was used to compare the vascular diameters of the retinas in the fundus images between the two groups.

## Results

The average ages of untreated group and treated group were 36.62± 8.77 years (range, 22–54y), and 35.28 ±7.45 years (range, 20–69 y), respectively. The majorities of the patients in both groups were male, with the percentages of males in the untreated group and treatment group being 76.19% and 74.63%, respectively. No statistical difference was found in age and gender between the two groups ( $P=0.372$ ,  $P=0.836$ ), as well as smoking history, comorbidity and opportunistic infection (Table 1).

No obvious lesion was observed on the standard fundus pictures in both two groups before and after treatment. The retinal artery diameters, including superior temporal, inferior temporal, superior nasal, inferior nasal and mean arterial diameter of the right eye were 107.91±10.95, 112.37±13.54, 88.86±13.06, 91.52±10.61, 100.30±8.35 micrometers in untreated group, and 104.12±13.04, 108.72±14.48, 89.35±12.90, 90.78±12.62, 99.04±10.01 micrometers in treatment group, respectively, no statistical difference was found between the two groups. The average diameter of retinal vein was relatively larger than artery, but there was also no significant difference between the two groups. Meanwhile, arteriovenous diameter ratios of superior temporal, inferior temporal, superior nasal, and inferior nasal in the right eye showed no significant differences between untreated group and treatment group too (Table 2).

For the left eyes, the retinal artery diameters, including superior temporal, inferior temporal, superior nasal, inferior nasal and mean arterial diameter were 108.02±10.40, 111.57±12.30, 92.64(13.53), 93.50±15.20 and 101.96±8.59 micrometers in untreated group, and 106.00±11.47, 110.33±13.08, 92.30(13.43), 93.46±16.59 and 93.46±16.59 micrometers in treatment group, respectively. No statistical difference was found between the two groups in average retinal artery and retinal vein diameters, as well as the arteriovenous diameter ratios (Table 3).

The absolute CD4+ T lymphocyte count in the treated group was significantly higher than that of un-treated group at 12 months of HAART treatment (563.34±2.56 vs 451.37±2.10 cells/ $\mu$ L,  $P=0.009$ ), and the plasma viral load was significantly lower (4794 vs 0 copy/mL,  $P=0.000$ ) than those in the treatment group (Table 4).

**Table 1** Comparisons of Demographic Characteristics Between the Two Groups

Variable	Untreated Group (n=63)	Treatment Group (n=67)	Z/ $\chi^2$	P
Age, years, median (IQR)	35(10)	34(11)	-0.893	0.372 <sup>a</sup>
Gender				
Male, n(%)	48(76.19)	50(74.63)	0.043	0.836 <sup>b</sup>
Female, n(%)	15(23.81)	17(25.37)		
Smoking history, n (%)				
Never smoker	6 (9.52)	8 (11.94)	0.576	0.750 <sup>b</sup>
Former smoker	2 (3.17)	1 (1.49)		
Current smoker	55 (87.31)	58 (86.57)		
Comorbidity, n (%)				
Hypertension	3 (4.76)	4 (5.97)	0.000	1.000 <sup>c</sup>
Diabetes	1 (1.59)	0 (0)		0.485 <sup>d</sup>
Hyperlipidemia	0 (0)	1 (1.49)		1.000 <sup>d</sup>
Renal disease (elevated serum creatinine)	15 (23.80)	19 (28.36)	0.348	0.555 <sup>b</sup>
Opportunistic infection n (%)				
Tuberculosis (TB)	5 (7.93)	8 (11.94)	0.578	0.447 <sup>b</sup>
Cytomegalovirus infection	1 (1.59)	0 (0)		0.485 <sup>d</sup>

**Notes:** <sup>a</sup>Owing to the skewed distribution, median (IQR) and Mann–Whitney *U*-test was applied in age. <sup>b</sup>Pearson chi-square test were applied in gender, smoking history, renal disease, tuberculosis. <sup>c</sup>Likelihood ratio test were applied in hypertension. <sup>d</sup>Fisher's exact test was applied in diabetes, hyperlipidemia, cytomegalovirus infection.



**Table 2** Comparisons of Retinal Diameters in the Right Eye Between the Two Groups ( $\mu\text{m}$ )

Items	Untreated Group (n=63)	Treatment Group (n=67)	t/z	P
Superior temporal artery diameter, Mean $\pm$ SD	107.91 $\pm$ 10.95	104.12 $\pm$ 13.04	1.769	0.079
Inferior temporal artery diameter, Mean $\pm$ SD	112.37 $\pm$ 13.54	108.72 $\pm$ 14.48	1.448	0.150
Superior nasal artery diameter, Mean $\pm$ SD	88.86 $\pm$ 13.06	89.35 $\pm$ 12.90	-0.207	0.837
Inferior nasal artery diameter, Mean $\pm$ SD	91.52 $\pm$ 10.61	90.78 $\pm$ 12.62	0.348	0.729
Mean arterial diameter, Mean $\pm$ SD	100.30 $\pm$ 8.35	99.04 $\pm$ 10.01	0.771	0.442
Superior temporal vein diameter, Mean $\pm$ SD	139.50 $\pm$ 21.09	141.06 $\pm$ 18.17	-0.451	0.653
Inferior temporal vein diameter, Mean $\pm$ SD	145.17 $\pm$ 18.88	143.79 $\pm$ 16.99	0.434	0.665
Superior nasal vein diameter, Mean $\pm$ SD	105.72 $\pm$ 15.14	102.99 $\pm$ 17.15	0.952	0.343
Inferior nasal vein diameter, Mean $\pm$ SD	105.06 $\pm$ 14.99	99.52 $\pm$ 17.67	1.871	0.064
Mean venous diameter, Mean $\pm$ SD	124.50 $\pm$ 11.31	121.67 $\pm$ 10.91	1.447	0.150
Superior temporal arteriovenous diameter ratio, Mean $\pm$ SD	0.79 $\pm$ 0.14	0.75 $\pm$ 0.12	1.917	0.058
Inferior temporal arteriovenous diameter ratio, Mean $\pm$ SD	0.78 $\pm$ 0.12	0.76 $\pm$ 0.12	1.080	0.282
Superior nasal arteriovenous diameter ratio, median (IQR)	0.83(0.17)	0.86(0.25)	-0.611	0.541 <sup>a</sup>
Inferior nasal arteriovenous diameter ratio, median (IQR)	0.89(0.19)	0.90(0.18)	-0.747	0.455 <sup>a</sup>
Mean arteriovenous diameter ratio, $\mu\text{m}$ , Mean $\pm$ SD	0.81 $\pm$ 0.09	0.82 $\pm$ 0.08	-0.326	0.745

**Note:** <sup>a</sup>Owing to the skewed distribution, median (IQR) and Mann-Whitney *U*-test were applied in superior nasal arteriovenous diameter ratio, inferior nasal arteriovenous diameter ratio.

**Table 3** Comparisons of Retinal Diameters in the Left Eye Between the Two Groups ( $\mu\text{m}$ )

Items	Untreated Group (n=63)	Treatment Group (n=67)	t/z	P
Superior temporal artery diameter, Mean $\pm$ SD	108.02 $\pm$ 10.40	106.00 $\pm$ 11.47	1.036	0.302
Inferior temporal artery diameter, Mean $\pm$ SD	111.57 $\pm$ 12.30	110.33 $\pm$ 13.08	0.549	0.584
Superior nasal artery diameter, median (IQR)	92.64(13.53)	92.30(13.43)	-0.569	0.570 <sup>a</sup>
Inferior nasal artery diameter, Mean $\pm$ SD	93.50 $\pm$ 15.20	93.46 $\pm$ 16.59	0.014	0.989
Mean arterial diameter, Mean $\pm$ SD	101.96 $\pm$ 8.59	99.97 $\pm$ 10.58	1.166	0.246
Superior temporal vein diameter, Mean $\pm$ SD	139.55 $\pm$ 17.77	139.73 $\pm$ 15.79	-0.059	0.953
Inferior temporal vein diameter, Mean $\pm$ SD	142.04 $\pm$ 18.21	144.40 $\pm$ 14.88	0.797	0.427
Superior nasal vein diameter, Mean $\pm$ SD	105.30 $\pm$ 16.66	106.78 $\pm$ 19.49	-0.455	0.650
Inferior nasal vein diameter, median (IQR)	103.13(23.59)	101.85(26.36)	-0.707	0.480 <sup>a</sup>
Mean venous diameter, Mean $\pm$ SD	124.12 $\pm$ 11.84	123.20 $\pm$ 11.59	0.443	0.658
Superior temporal arteriovenous diameter ratio, median (IQR)	0.75(0.12)	0.75(0.17)	-0.605	0.545 <sup>a</sup>
Inferior temporal arteriovenous diameter ratio, median (IQR)	0.90(0.19)	0.83(0.16)	-1.650	0.099 <sup>a</sup>
Superior nasal arteriovenous diameter ratio, median (IQR)	0.80(0.13)	0.77(0.12)	-1.204	0.228 <sup>a</sup>
Inferior nasal arteriovenous diameter ratio, Mean $\pm$ SD	0.89 $\pm$ 0.17	0.94 $\pm$ 0.19	-1.348	0.180
Mean arteriovenous diameter ratio, median (IQR)	0.82(0.12)	0.81(0.10)	-0.865	0.387 <sup>a</sup>

**Notes:** <sup>a</sup>Owing to the skewed distribution, median (IQR) and Mann-Whitney *U*-test were applied in superior nasal artery diameter, inferior nasal vein diameter, superior temporal arteriovenous diameter ratio, inferior temporal arteriovenous diameter ratio, superior nasal arteriovenous diameter ratio, mean arteriovenous diameter ratio.

**Table 4** Comparison of Absolute CD4+T Lymphocyte Counts and Plasma Viral Loads Between the Two Groups

	Untreated Group (n=63)	Treatment Group (n=67)	t/z	P
CD4+T lymphocytes, cells/ $\mu\text{L}$ , Mean $\pm$ SD	451.37 $\pm$ 2.10	563.34 $\pm$ 2.56	-2.645	0.009
HIV RNA, copy/mL, median (IQR)	4794(13,574)	0(9684)	-4.503	0.000 <sup>a</sup>

**Note:** <sup>a</sup>Owing to the skewed distribution, median (IQR) and Mann-Whitney *U*-test were applied in superior nasal arteriovenous diameter ratio, inferior nasal arteriovenous diameter ratio.

## Discussion

In this study, the enrolled patients are mainly young and middle-aged male. We compared the clinical data of fundus lesions, retinal microvascular diameters, CD4+ T lymphocyte counts and HIV-1 plasma viral loads of the participants with or without HAART treatment. Apart from the significant increase of CD4+ T lymphocyte number and decrease of plasma viral load, no significant change was found in the fundus and the retinal microvascular diameters.

It is known that the number of CD4+ T lymphocytes is closely related to body immunological function. As reported by existing research, the number of CD4+ T lymphocytes in HIV patients was approximately 200/ $\mu$ L, far below the normal level of 700–1100/ $\mu$ L.<sup>14,15</sup> With the decrease of CD4+ T lymphocytes, the incidence of opportunistic infections will increase, threatening the function of blood-retinal barrier<sup>12,13</sup> and finally lead to HIV retinopathy.<sup>16–18</sup>

HAART has been demonstrated to be the most effective treatment for HIV infection. According to our results, the CD4+ T lymphocyte counts of the patients significantly increased from 451.37 $\pm$ 2.10 to 563.34 $\pm$ 2.56 cells/ $\mu$ L, and the plasma viral load of HIV-1 decreased significantly from 4794 to 0 copy/mL ( $P=0.000$ ) after effective HAART treatment. However, we did not find any obvious fundus lesion in both research groups. This suggests that if the CD4+ T lymphocyte count is close to the normal level (451.37 $\pm$ 2.10 cells/ $\mu$ L of untreated group and 563.34 $\pm$ 2.56 cells/ $\mu$ L of treatment group), the HIV patient may not experience obvious fundus lesion. Further study is required to find out at what level of CD4+ T lymphocyte count HIV-related fundus lesion is likely to occur.

The retinal artery is the only artery that can be seen with the naked eye, which reflects the situation of arterial vessel system. HAART was reported to cause a variety of side effects like peripheral neuritis, liver damage, bone marrow hematopoietic function inhibition, and abnormal peripheral fat distribution.<sup>19,20</sup> Medical staff found that lipidaemia in AIDS patients is associated with the use of nucleoside reverse transcriptase inhibitors and protease inhibitors,<sup>21,22</sup> as nucleoside reverse transcriptase inhibitors may cause fat loss and protease inhibitors may increase the risk of fat accumulation.<sup>23,24</sup> Besides, the longer patients take this kind of drugs, the more likely they would develop fat metabolism disorder.<sup>25</sup> Finally, patients will suffer from dyslipidaemia induced arterial stenosis and retinal arterial stenosis.<sup>26</sup> The results of the current study showed that there was no significant difference between the untreated group and the treatment group in terms of artery diameter, inferior temporal artery diameter, superior nasal artery diameter, inferior nasal artery diameter and mean arterial diameter. Indicating that HAART does not cause stenosis of the retinal central artery in patients.

Microangiopathy is one of the most common eye-related complications of HIV/AIDS in clinic.<sup>27</sup> It mostly occurs in the retina, mainly manifests as cotton wool plaques, followed by microvascular dilation, microhemangioma formation, retinal hemorrhage, and rarely Roth spots.<sup>28</sup> The retinal veins tend to show varying degrees of dilation, hyperaemia, irregular diameter and flexure, and flare-like or irregular bleeding in the adjacent retina<sup>(29,30)</sup>. In the current study, we found no significant differences between the untreated group and the treatment group in the mean values of the superior temporal vein diameter, inferior temporal vein diameter, superior nasal vein diameter, inferior nasal vein diameter and vein diameter. This is an indication that HAART is unlikely to cause the dilatation of patients' retinal central venous vessels (superior temporal vein, inferior temporal vein, superior nasal vein and inferior nasal vein).

Most epidemiological studies about retinal microvascular lesions were based on the arteriovenous ratio, as the arteriovenous ratio could reveal pathophysiological processes of arterioles stenosis. In this study, the ratio of superior temporal arteriovenous access, inferior temporal arteriovenous access, superior nasal arteriovenous access and inferior nasal arteriovenous access showed no significant differences between untreated group and treatment group demonstrating that HAART probably has no influence on patients' arterioles stenosis.

Fundus picture combined with relative image analysis techniques have been used to detect and/or predict a range of cardiovascular risk factors (ie, hypertension, hyperglycemia, and dyslipidemia) and major adverse cardiac events. Studies found that retinal microtubule morphology may be helpful to evaluate the immune recovery of AIDS patients receiving HAART and guide the selection of HAART regimens. In this study, we intended to establish the correlation between retinal vessel caliber and immune status of HIV/AIDS patients. However, no significant changes in retinal microvessels were observed between HIV/AIDS patients with or without HAART. Research finding, the change in retinal diameter of HIV/AIDS patients after 9 months of HAART was found to be associated with reduced CD4 + cell numbers on HIV.<sup>11</sup>

We speculated that the HIV/AIDS patients without HAART were still within a normal immune range, hence no retinopathy occurred, as evidenced by the high CD4+ cell count.

The present study had some limitations. Most of the patients enrolled in this study were young and middle-aged, with a treatment duration of 12 months and high CD4+ cell counts. Further studies involving elder patients and those on long-term HAART medication ( $\geq 12$  months) are required before a solid conclusion could be made.

## Conclusion

In this study, HAART treatment was found to increase the CD4+ T lymphocyte counts of HIV/AIDS patients significantly. However, fundus pictures acquired by nondilated eye camera showed no obvious fundus lesions nor retinal microangiopathy in the enrolled 130 HIV/AIDS patients with or without HAART. The potential reason may be attributed to the near-normal CD4+ T lymphocyte level in the treatment-naïve patients. Further study is needed to determine whether HAART had influence on the fundus and retinal microvasculars in HIV/AIDS patients, by recruiting more participants and prolonging follow-up time.

## Ethics Approval

This study was approved by the Ethics Committee of Yunnan Academy of Traditional Chinese Medicine (2015002). All the experimental protocols were in accordance with the ethical guidelines of the Helsinki Declaration. All the patients gave their informed consent.

## Acknowledgments

We thank the technical support in molecular bioassays offered by Knorigene Technologies. Qin Li and Dongqiong Chen are co-first authors for this study.

## Author Contributions

All authors contributed to data analysis, drafting or revising the article, have agreed on the journal to which the article will be submitted, gave final approval of the version to be published, and agreed to be accountable for all aspects of the work.

## Funding

This was supported by [National Natural Science Foundation of China, No.82060864], [Yunnan Provincial Science and Technology Department Science and Technology Program Key Project, No.2019FA036], [Yunnan Provincial Department of Education Teacher Science and Technology Project, No 0.2020J0290], [Construction project of the research platform for the prevention and treatment of autoimmune diseases in Yunnan Province, No.30360201100], [Yunnan Provincial Science and Technology Department Science and Technology Program Key Research and Development Project, No.202003AC100005], [Yunnan Provincial Science and Technology Department Science and Technology Program Key Research and Development Project, No.202103AC100005], [Yunnan Provincial Science and Technology Department Science and Technology Program Key Research and Development Project, No.202103AC100005].

## Disclosure

The authors declare no conflicts of interest in this work.

## References

1. Xie L-Y, Chen C, Kong W-J, Du K-F, Guo C-G, Wei W-B. A comparative study on retinal thickness of the macular region among AIDS patients with normal ocular fundus, HIV-related microvascular retinopathy patients, and cytomegalovirus retinitis patients. *Medicine*. 2019;98(26):e16073. doi:10.1097/MD.00000000000016073
2. Jabs DA, Van Natta ML, Trang G, et al. Association of systemic inflammation with retinal vascular caliber in patients with AIDS. *Invest Ophthalmol Vis Sci*. 2019;60(6):2218–2225. doi:10.1167/iovs.18-26070
3. Jabs DA, Van Natta ML, Pak JW, Danis RP, Hunt PW. Association of Retinal Vascular Caliber and Age-Related Macular Degeneration in Patients With the Acquired Immunodeficiency Syndrome. *Invest Ophthalmol Vis Sci*. 2018;59(2):904–908. doi:10.1167/iovs.17-23334



4. Chiotan C, Radu L, Serban R, Cornăcel C, Cioboată M, Anghelie A. Posterior segment ocular manifestations of HIV/AIDS patients. *J Med Life*. 2014;7(3):399. doi:10.1016/j.survophthal.2003.12.008
5. Sun HY, Peng XY, Li D, Mao FF, You QS, Jonas JB. Cytomegalovirus retinitis in patients with AIDS before and after introduction of HAART in China. *Eur J Ophthalmol*. 2014;24(2):209–215. doi:10.5301/ejo.5000354
6. Silva B, Peixoto G, da Luz S, de Moraes S, Peres S. Adverse effects of chronic treatment with the Main subclasses of highly active antiretroviral therapy: a systematic review. *HIV Med*. 2019;20(7):429–438. doi:10.1111/hiv.12733
7. da Cunha J, Maselli LMV, Stern ACB, Spada C, Bydlowski SP. Impact of antiretroviral therapy on lipid metabolism of human immunodeficiency virus-infected patients: old and new drugs. *World J Virol*. 2015;4(2):56. doi:10.5501/wjv.v4.i2.56
8. Saydam O, Ozgen Saydam B, Adiyaman SC, et al. Risk factors for diabetic foot ulcers in metreleptin naïve patients with lipodystrophy. *Clin Diabetes Endocrinol*. 2021;7(1):1–10. doi:10.1186/s40842-021-00132-9
9. Iwasaki Y, Yamamoto N, Kawaguchi T, et al. Human immunodeficiency virus-related retinal microangiopathy and systemic cytomegalovirus disease association. *Jpn J Ophthalmol*. 2013;57(4):372–378. doi:10.1007/s10384-013-0247-7
10. Gangaputra S, Kalyani PS, Fawzi AA, et al.; Studies of the Ocular Complications of AIDS Research Group. Retinal vessel caliber among people with acquired immunodeficiency syndrome: relationships with disease-associated factors and mortality. *Am J Ophthalmol*. 2012;153(3):434–444.e1. PMID: 22019225; PMCID: PMC3289046. doi:10.1016/j.ajo.2011.08.028
11. Pivetti-Pezzi P, Tamburi S, Accorinti M, et al. Immunological and viral markers of HIV infection and retinal microangiopathy. *Eur J Ophthalmol*. 1993;3(3):138–142. doi:10.1177/112067219300300306
12. Gallo RC, Salahuddin SZ, Popovic M, et al. Frequent detection and isolation of cytopathic retroviruses (HTLV-III) from patients with AIDS and at risk for AIDS. *science*. 1984;224(4648):500–503. doi:10.1126/science.6200936
13. Dadgostar H, Holland GN, Huang X, et al. Hemorheologic abnormalities associated with HIV infection: in vivo assessment of retinal microvascular blood flow. *Invest Ophthalmol Vis Sci*. 2006;47(9):3933–3938. doi:10.1167/iovs.06-0138
14. Hanson DL, Chu SY, Farizo KM, Ward JW. Distribution of CD4+ T Lymphocytes at Diagnosis of Acquired Immunodeficiency Syndrome—Defining and Other Human Immunodeficiency Virus—Related Illnesses. *Arch Intern Med*. 1995;155(14):1537–1542. doi:10.1001/archinte.1995.00430140115012
15. Chen C, Guo C-G, Meng L, et al. Comparative analysis of cytomegalovirus retinitis and microvascular retinopathy in patients with acquired immunodeficiency syndrome. *Int J Ophthalmol*. 2017;10(9):1396. doi:10.18240/ijo.2017.09.11
16. Ganta KK, Chaubey B. Mitochondrial dysfunctions in HIV infection and antiviral drug treatment. *Expert Opin Drug Metab Toxicol*. 2019;15(12):1043–1052. doi:10.1080/17425255.2019.1692814
17. Abah IO, Neube N, Bradley HA, Agbaji OO, Kanki P. Antiretroviral Therapy-associated adverse drug reactions and their effects on virologic Failure—a retrospective cohort study in Nigeria. *Curr HIV Res*. 2018;16(6):436–446. doi:10.2174/1389450120666190214144609
18. Yang J, Chen J, Ji Y, et al. Lipid profile and renal safety of tenofovir disoproxil fumarate-based anti-retroviral therapy in HIV-infected Chinese patients. *Int J Infect Dis*. 2019;83:64–71. doi:10.1016/j.ijid.2019.03.034
19. Leyes P, Cofan M, González-Cordón A, et al. Increased cholesterol absorption rather than synthesis is involved in boosted protease inhibitor-associated hypercholesterolaemia. *Aids*. 2018;32(10):1309–1316. doi:10.1097/QAD.0000000000001837
20. Gibellini L, De Biasi S, Nasi M, et al. Different origin of adipogenic stem cells influences the response to antiretroviral drugs. *Exp Cell Res*. 2015;337(2):160–169. doi:10.1016/j.yexcr.2015.07.031
21. Ioannou GN, Bryson CL, Weiss NS, Boyko EJ. Associations between lipodystrophy or antiretroviral medications and cirrhosis in patients with HIV infection or HIV/HCV coinfection. *Eur J Gastroenterol Hepatol*. 2015;27(5):577–584. doi:10.1097/MEG.0000000000000290
22. Guaraldi G, Zona S, Orlando G, et al. Morphological and Metabolic Components of Lipodystrophy in Various Nevirapine-Based Highly Active Antiretroviral Therapy (HAART) Regimens. *Clin Drug Investig*. 2011;31(11):759–767. doi:10.1007/BF03256916
23. Dodson P, Galton D, Winder A. Retinal vascular abnormalities in the hyperlipidaemias. *Trans Ophthalmol Soc U K*. 1981;101(1):17–21.
24. Gogri PY, Misra SL, Kothari RN, Bhandari AJ, Gidwani HV. Ophthalmic manifestations of HIV patients in a rural area of western Maharashtra, India. *Int Scholarly Res Notices*. 2014;2014:1–8. doi:10.1155/2014/347638
25. Jiramongkolchai K, Liu TYA, Arevalo JF. Peripheral retinal neovascularization with vitreous hemorrhage in HIV retinopathy. *Case Rep Ophthalmol*. 2017;8(2):353–357. doi:10.1159/000477161
26. Sahoo S. HIV-and AIDS-related ocular manifestations in Tanzanian patients. *Malaysian j Med Sci*. 2010;17(1):12.
27. Golen JR, Eichenbaum D. Neovascularization of the optic disk and vitreous hemorrhage after immune recovery and treatment of cytomegalovirus retinitis in an HIV-positive patient. *Retin Cases Brief Rep*. 2013;7(4):395–398. doi:10.1097/ICB.0b013e318298bdb5
28. Hemminki V, Kähönen M, Tuomisto MT, Turjanmaa V, Uusitalo H. Determination of retinal blood vessel diameters and arteriovenous ratios in systemic hypertension: comparison of different calculation formulae. *Graefes Arch Clin Exp Ophthalmol*. 2007;245(1):8–17. doi:10.1007/s00417-006-0358-7

## HIV/AIDS - Research and Palliative Care

Dovepress

### Publish your work in this journal

HIV/AIDS - Research and Palliative Care is an international, peer-reviewed open-access journal focusing on advances in research in HIV, its clinical progression and management options including antiviral treatment, palliative care and public healthcare policies to control viral spread. The manuscript management system is completely online and includes a very quick and fair peer-review system, which is all easy to use. Visit <http://www.dovepress.com/testimonials.php> to read real quotes from published authors.

Submit your manuscript here: <https://www.dovepress.com/hiv-aids-research-and-palliative-care-journal>