

Image Report

# Cavernous angioma presenting with subarachnoid hemorrhage which was diffusely distributed in the basal cisterns and mimicked intracranial aneurysm rupture

Atsuhito Uneda, Satoru Yabuno, Takahiro Kanda, Kenta Suzuki, Koji Hirashita, Masatoshi Yunoki, Kimihiro Yoshino

Department of Neurosurgery, Kagawa Rosai Hospital, Marugame, Kagawa, Japan

E-mail: \*Atsuhito Uneda - uneda-oka@umin.ac.jp; Satoru Yabuno - satoru\_yabuno0220@yahoo.co.jp; Takahiro Kanda - kt.foot.7esoog@gmail.com; Kenta Suzuki - flying1369@yahoo.co.jp; Koji Hirashita - hira4113@yahoo.co.jp; Masatoshi Yunoki - yunomasato@yahoo.co.jp; Kimihiro Yoshino - yoshino@kagawah.johas.go.jp  
\*Corresponding author

Received: 09 June 17 Accepted: 11 July 17 Published: 22 August 17

**Key Words:** Angiographically negative, cavernous angioma, cavernoma, subarachnoid hemorrhage

## INTRODUCTION

Intracranial cavernous angiomas (cavernomas, cavernous hemangiomas, cavernous malformations) usually cause intraparenchymal hemorrhage but are rarely described as a cause of isolated subarachnoid hemorrhage (SAH).<sup>[2,6,10]</sup> Some cases of intracranial cavernous angiomas presenting with isolated SAH have been reported.<sup>[3,7,9,10,12]</sup> However, cavernous angiomas presenting with so-called angiographically negative aneurysmal-like SAH are rare. To our knowledge, only one case of cavernous angioma presenting with perimesencephalic SAH has been reported.<sup>[11]</sup> We describe a case of cavernous angioma presenting with SAH, which was diffusely distributed in the basal cisterns and mimicked intracranial aneurysm rupture.

## CASE REPORT

A 50-year-old woman suddenly developed severe headache, vomiting, and dizziness, and had a high blood pressure (193/103 mmHg). Brain computed tomography (CT) showed that SAH was diffusely distributed in the basal cisterns, as well as blood at the fourth ventricle [Figure 1a–c]. However, repetitive CT angiography and digital subtraction angiography failed to reveal an identifiable source of the SAH. Brain magnetic resonance imaging (MRI) performed on day

10 showed a cavernous angioma on the surface of the left cerebellar hemisphere [Figure 1d], which became more obvious on subsequent MRI on day 16 [Figure 1e–g]. We concluded that this angioma was the cause of the SAH. An obscure lesion suggestive of the presence of cavernous angioma was found on retrospective review of the initial CT [Figure 1c]. We recommended surgical treatment, but the patient requested conservative management.

This is an open access article distributed under the terms of the Creative Commons Attribution-NonCommercial-ShareAlike 3.0 License, which allows others to remix, tweak, and build upon the work non-commercially, as long as the author is credited and the new creations are licensed under the identical terms.

For reprints contact: [reprints@medknow.com](mailto:reprints@medknow.com)

Access this article online	
Quick Response Code:	Website: <a href="http://www.surgicalneurologyint.com">www.surgicalneurologyint.com</a>
	DOI: 10.4103/sni.sni_210_17

**How to cite this article:** Uneda A, Yabuno S, Kanda T, Suzuki K, Hirashita K, Yunoki M, et al. Cavernous angioma presenting with subarachnoid hemorrhage which was diffusely distributed in the basal cisterns and mimicked intracranial aneurysm rupture. *Surg Neurol Int* 2017;8:202.  
<http://surgicalneurologyint.com/Cavernous-angioma-presenting-with-subarachnoid-hemorrhage-which-was-diffusely-distributed-in-the-basal-cisterns-and-mimicked-intracranial-aneurysm-rupture/>

Therefore, she was treated conservatively and discharged on day 26 in good condition. As of 21 months after onset, she is in good health with no evidence of rebleeding.

## DISCUSSION

We described a case of cavernous angioma presenting with SAH, which was diffusely distributed in the basal cisterns and mimicked intracranial aneurysm rupture. Cavernous angiomas are vascular hematomas of blood vessels. The incidence of cavernous angiomas ranges 0.4–0.6% in the general population, and approximately 36% of these present with hemorrhage.<sup>[5]</sup> Intraparenchymal hemorrhage usually occurs but intracranial cavernous angiomas presenting with isolated SAH are rare.<sup>[2,6,10]</sup>

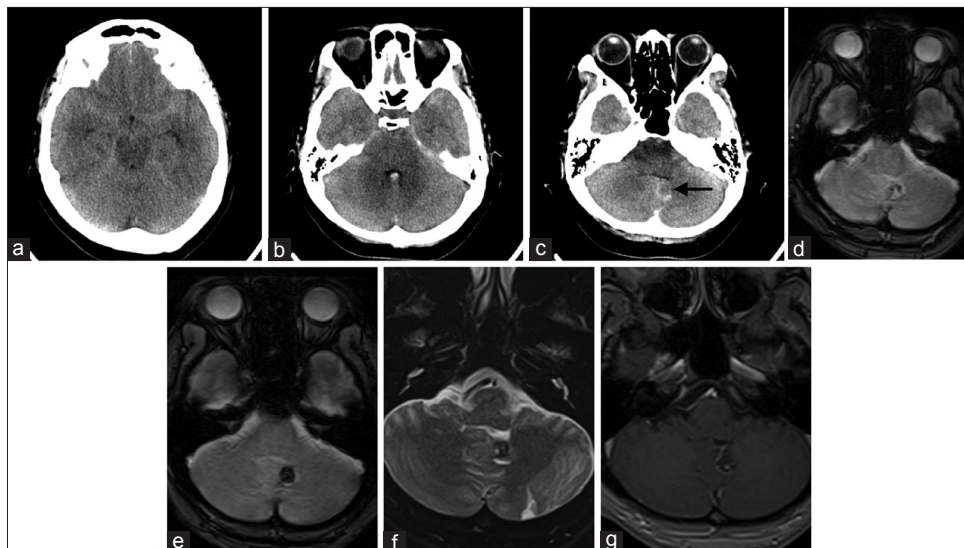
Some cases of cavernous angiomas in the brain stem, cerebellum, cerebellopontine angle, sylvian cistern, and suprasellar cistern presenting with isolated SAH have been reported.<sup>[3,7,9,10,12]</sup> In these cases, the patterns of SAH differed from aneurysmal SAH. Cavernous angiomas presenting with so-called angiographically negative aneurysmal-like SAH, such as the present case, are rare with only one reported case presenting with perimesencephalic SAH.<sup>[11]</sup>

The precise percentage of cavernous angioma in angiographically negative SAH is unknown. Of 213 patients with CT angiographically negative SAH, Heit *et al.* reported that a single cortical cavernous malformation (0.4%) was identified on MRI.<sup>[6]</sup> Woodfield *et al.* performed subsequent MRI on 131 of 240 patients with angiographically negative SAH, and only 2 of them (1.5%) had cavernous malformation.<sup>[10]</sup>

In our case, the lesion gradually became apparent on delayed MRI over time. An obscure lesion, which suggested the presence of cavernous angioma, was found by a retrospective review of the initial CT after identifying the cavernous angioma on MRI. However, this lesion was difficult to identify at first review in the initial CT.

Surgically accessible cavernous angiomas with sudden or progressive symptoms and those with recurrent hemorrhage should be considered for surgical treatment.<sup>[4]</sup> Some authors recommend surgical treatment even for asymptomatic cavernous malformations, especially when imaging shows evidence of growth.<sup>[4]</sup> Cerebellar cavernous angiomas have an annual risk of bleeding of 2.39%.<sup>[1]</sup> The annual risk of bleeding is reportedly 7.78 times higher in patients with posterior fossa cavernous angiomas who have experienced a previous episode of hemorrhage.<sup>[8]</sup> In the present case, we recommended surgical resection to prevent recurrent hemorrhage, but the patient requested conservative management. We will reconsider surgical treatment if the patient becomes symptomatic or develops recurrent hemorrhage.

This report suggests that cavernous angioma should be considered in the differential diagnosis of patients with angiographically negative aneurysmal-like SAH. This condition should be considered even in the absence of distinct intraparenchymal hemorrhage that suggests the presence of angiographically occult cavernous angioma. A careful search of CT images for an obscure lesion that suggests the presence of cavernous angioma is important for early diagnosis, but this lesion is difficult to identify at first sight. Delayed brain MRI is the most useful method for revealing such an angioma.



**Figure 1:** (a-c) Axial slices of acute unenhanced brain CT show SAH diffusely distributed in the basal cisterns and also show blood at the fourth ventricle. An obscure lesion, which suggested the presence of cavernous angioma (arrow), was found by retrospective review of the initial CT scan. (d) Axial T2-weighted image on day 10 shows a hypointense lesion on the surface of the left cerebellar hemisphere. (e) Axial T2-weighted image on day 16 more obviously shows the angioma. (f) Axial T2-weighted image on day 16 shows a mixed signal core surrounded by a hypointense rim. (g) Contrast-enhanced T1-weighted image shows a coexisting, developmental, venous anomaly

## Financial support and sponsorship

Nil.

## Conflicts of interest

There are no conflicts of interest.

## REFERENCES

1. Cantu C, Murillo-Bonilla L, Arauz A, Higuera J, Padilla J, Barinagarrementeria F. Predictive factors for intracerebral hemorrhage in patients with cavernous angiomas. *Neurol Res* 2005;27:314-8.
2. Cuvinciuc V, Viguier A, Calviere L, Raposo N, Larrue V, Cognard C, et al. Isolated acute nontraumatic cortical subarachnoid hemorrhage. *AJNR Am J Neuroradiol* 2010;31:1355-62.
3. Escott EJ, Rubinstein D, Cajade-Law AG, Sze CI. Suprasellar cavernous malformation presenting with extensive subarachnoid hemorrhage. *Neuroradiology* 2001;43:313-6.
4. Gross BA, Du R. Cerebral cavernous malformations: Natural history and clinical management. *Expert Rev Neurother* 2015;15:771-7.
5. Gross BA, Lin N, Du R, Day AL. The natural history of intracranial cavernous malformations. *Neurosurg Focus* 2011;30:E24.
6. Heit JJ, Pastena GT, Nogueira RG, Yoo AJ, Leslie-Mazwi TM, Hirsch JA, et al. Cerebral angiography for evaluation of patients with CT angiogram-negative subarachnoid hemorrhage: An 11-year experience. *AJNR Am J Neuroradiol* 2016;37:297-304.
7. Lenzi J, Seferi A, Nardone A, Salvati M, Vreto G, Santoro A, et al. Sylvian subarachnoid and extra-pial cavernous angioma. *J Neurosurg Sci* 2005;49:163-6; discussion 166.
8. Pozzati E, Acciarri N, Tognetti F, Marliani F, Giangaspero F. Growth, subsequent bleeding, and de novo appearance of cerebral cavernous angiomas. *Neurosurgery* 1996;38:662-9; discussion 669-70.
9. Takado Y, Minakawa T, Hadeishi H, Yoshida Y. A mass in the cerebellopontine angle presenting with subarachnoid haemorrhage. *J Clin Neurosci* 2009;16:1051-117.
10. Woodfield J, Rane N, Cudlip S, Byrne JV. Value of delayed MRI in angiogram-negative subarachnoid haemorrhage. *Clin Radiol* 2014;69:350-6.
11. Yaghi S, Oomman S, Keyrouz SG. Non-aneurysmal perimesencephalic subarachnoid hemorrhage caused by a cavernous angioma. *Neurocrit Care* 2011;14:84-5.
12. Yamamoto M, Fukushima T, Ikeda K, Nagasaka S, Sakamoto S, Oka K, et al. Intracranial cavernous angioma manifesting as subarachnoid hemorrhage--case report. *Neurol Med Chir (Tokyo)* 1993;33:706-9.