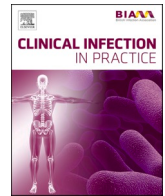




Since January 2020 Elsevier has created a COVID-19 resource centre with free information in English and Mandarin on the novel coronavirus COVID-19. The COVID-19 resource centre is hosted on Elsevier Connect, the company's public news and information website.

Elsevier hereby grants permission to make all its COVID-19-related research that is available on the COVID-19 resource centre - including this research content - immediately available in PubMed Central and other publicly funded repositories, such as the WHO COVID database with rights for unrestricted research re-use and analyses in any form or by any means with acknowledgement of the original source. These permissions are granted for free by Elsevier for as long as the COVID-19 resource centre remains active.



Case Reports and Series

Multi inflammatory syndrome in a 16-year-old male following first dose of m-RNA COVID-19 vaccination

Patrick Hugh McGann^{a,b,*}, Ahmed O.A. Krim^a, Jared Green^a, Jacqueline Venturas^a^a Waikato district health board, Waikato Hospital, 183 Pembroke Street, Hamilton 3204, New Zealand^b St. James University Hospital, Beckett Street, Leeds LS9 7TF, UK

ARTICLE INFO

Keywords

Multi-inflammatory syndrome
COVID-19 Vaccination

ABSTRACT

Multisystem Inflammatory Syndrome (MIS) is an uncommon systemic illness that occurs 4–6 weeks after primary infection with SARS-CoV-2. There are emerging reports of MIS arising following vaccination against SARS-CoV-2. We report a 16-year-old male with a multi system inflammatory condition meeting the case definition for MIS following BTN162b2 mRNA SARS-CoV-2 (Pfizer BioNTech) vaccine with no other identifiable precipitant or evidence of primary infection with SARS-Cov-2.

Background

Multi-Inflammatory Syndrome has been described in both children (MIS-C; also known as Paediatric Inflammatory Multisystem Syndrome Temporally associated with SARS-CoV-2 [PIMS-TS]) and adults (MIS-A), 4–6 weeks after SARS-CoV-2 infection. MIS presents with a clinical picture similar to diseases such as hemophagocytic lymphohistiocytosis (HLH) or Kawasaki disease (KD). The Brighton Collaboration diagnostic criteria for MIS-C/MIS-A are detailed in Table 1 (Vogel et al., 2021). The pathophysiology is poorly understood but is thought to arise from an exuberant immune response to SARS-CoV-2, characterised by persistent viral IgG antibodies with monocyte and CD8 + T-cell activation (Bartsch et al., 2021; Vella et al., 2021).

Symptomatic acute myocarditis has been reported amongst adolescents aged 12 to 15 years, more commonly after the second dose of Pfizer-BioNTech COVID-19 Vaccination (SARS-CoV-2 mRNA, 2021). There are emerging case reports documenting Multisystem Inflammatory Syndrome following BTN162b2 mRNA (Pfizer-BioNTech) m-RNA SARS-CoV-2 vaccine (Nune et al., 2021; FRANCISCO EM, 2021; Kahn, 2019), inactivated SARS COV-2 vaccine (Uwaydah et al., 2021) and ChAdOx1 nCov-19 vaccination [MIS-V] (Attwell et al., 2021).

Case report

We report the case of a 16-year-old male, who presented with a severe multisystem inflammatory condition 12 days after receiving a

single dose of Pfizer-BioNTech mRNA SARS-CoV-2 vaccine in an area with no community transmission of SARS- CoV-2.

A well and active 16-year-old male presented to the surgical department at a regional hospital in New Zealand in September 2021 with a 2-day history of fever and upper abdominal pain. Past medical history included methicillin sensitive staphylococcal septic arthritis of the hip at the age of 10 years, at which time mild congenital aortic regurgitation was identified. Examination showed him to be alert and orientated, febrile at 39 °C, tachycardic but normotensive. Cardiovascular examination was normal with no audible murmur. Oxygen saturations were within normal limits and no abnormalities were detected on auscultation. He had diffuse upper abdominal tenderness. There was no spinal tenderness or joint swelling.

Initial investigations showed an elevated C-reactive protein (CRP), lymphopaenia, mild thrombocytopenia, elevation in alanine aminotransferase (ALT) and normal renal function. Troponin T (TnT) and N-terminal pro-Brain Natriuretic Peptide (NT-proBNP) were within the normal range. Chest radiograph (CXR) and a 12-lead electrocardiograph (ECG) were normal. Abdominal ultrasound showed splenomegaly at 14.5 cm. 2 sets of blood cultures taken before administration of antibiotics were negative. The patient was commenced on empirical antibiotics, intravenous cefuroxime 1.5 g 8 hourly and metronidazole 500 mg 8 hourly.

Over the next 48 h the patient became progressively more unwell with persistent fevers, worsening abdominal pain, respiratory distress and hypoxemia. A diffuse erythematous rash appeared on his arms and

* Corresponding author at: Department of infectious diseases, Waikato hospital, 183 Pembroke Street, Hamilton 3204, New Zealand.

E-mail addresses: patrick.mcgann@waikatodhb.health.nz (P. Hugh McGann), ahmed.krim@waikatodhb.health.nz (A.O.A. Krim), jared.green@waikatodhb.health.nz (J. Green), jacqueline.venturas@waikatodhb.health.nz (J. Venturas).

<https://doi.org/10.1016/j.clinpr.2022.100139>

Received 13 November 2021; Received in revised form 20 January 2022; Accepted 4 February 2022

Available online 15 February 2022

2590-1702/© 2022 The Authors. Published by Elsevier Ltd on behalf of British Infection Association. This is an open access article under the CC BY-NC-ND license (<http://creativecommons.org/licenses/by-nc-nd/4.0/>).

Table 1

Brighton Collaboration Diagnostic Criteria for Multi-Inflammatory Syndrome in children (MIS-C) and adults (MIS-A).

Level 1 of Diagnostic Certainty-Definitive Case.
1. Age < 21 years (MIS-C) or ≥ 21 years (MIS-A)
AND
2. Fever for ≥ 3 consecutive days.
AND
3. Two or more of the following clinical features:
a. Mucocutaneous (rash, erythema, or cracking of the lips/mouth/pharynx, bilateral nonexudative conjunctivitis, erythema/edema of the hands and feet)
b. Gastrointestinal (abdominal pain, vomiting, diarrhea).
c. Shock/hypotension.
d. Neurologic (altered mental status, headache, weakness, paresthesias, lethargy)
AND
4. Elevated Markers of inflammation including any of the following:
a. Elevated CRP, ESR, ferritin, or procalcitonin.
AND
5. Two or more measures of disease activity:
a. Elevated BNP or NT-proBNP or troponin.
b. Neutrophilia, lymphopenia, thrombocytopenia.
c. Evidence of cardiac involvement by echocardiography or physical stigmata of heart failure.
d. ECG changes consistent with myocarditis or myopericarditis.
AND
6. Laboratory confirmed SARS-CoV-2 infection.
OR
7. Personal history of confirmed COVID-19 within twelve weeks.
OR
8. Close contact with known COVID-19 case within 12 weeks.
OR
9. Following SARS-CoV-2 vaccination.

trunk [Fig. 1]. He remained normotensive, but due to escalating oxygen requirements he was transferred to the intensive care unit where he was intubated and ventilated. Antibiotics were changed to meropenem 1 g 8 hourly and clarithromycin 500 mg 12 hourly.

Repeat CXR showed bilateral dense lower lobe consolidation [Fig. 2]. CT scan of chest and abdomen showed no evidence of thromboembolic disease but diffuse inflammation and soft tissue oedema around the gallbladder, liver and within the epigastric region, as well as a small pericardial effusion, symmetrical confluent airspace consolidation in the lower lobes, and widespread symmetrical ground glass opacities bilaterally. [Fig. 3]. A *trans*-oesophageal echocardiogram was performed in ITU which showed elevated pulmonary pressures, no evidence of endocarditis or myocarditis and mild aortic regurgitation unchanged

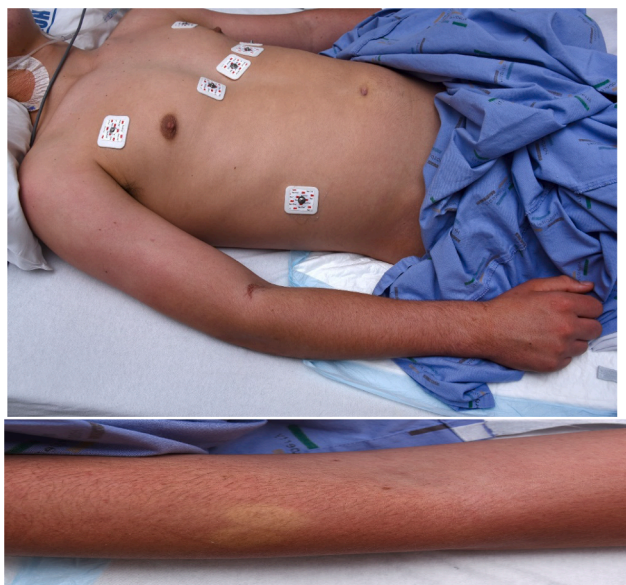

Fig. 1. Diffuse, blanching erythematous rash on arms and trunk.

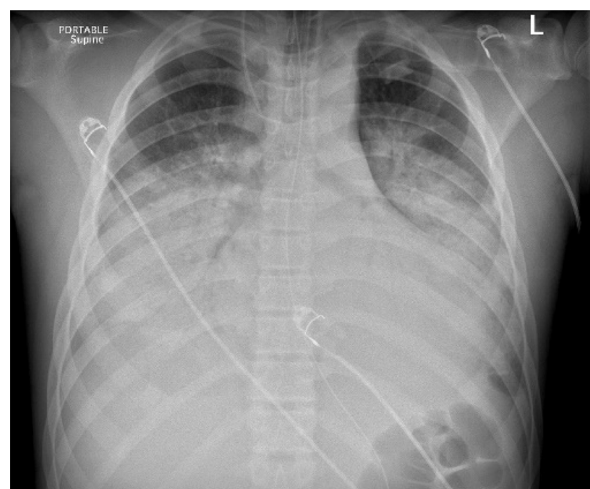


Fig. 2. Chest radiograph on day 3, showing a diffuse hazy and coalescent airspace opacification bilaterally with a predominance in the mid and lower zones.

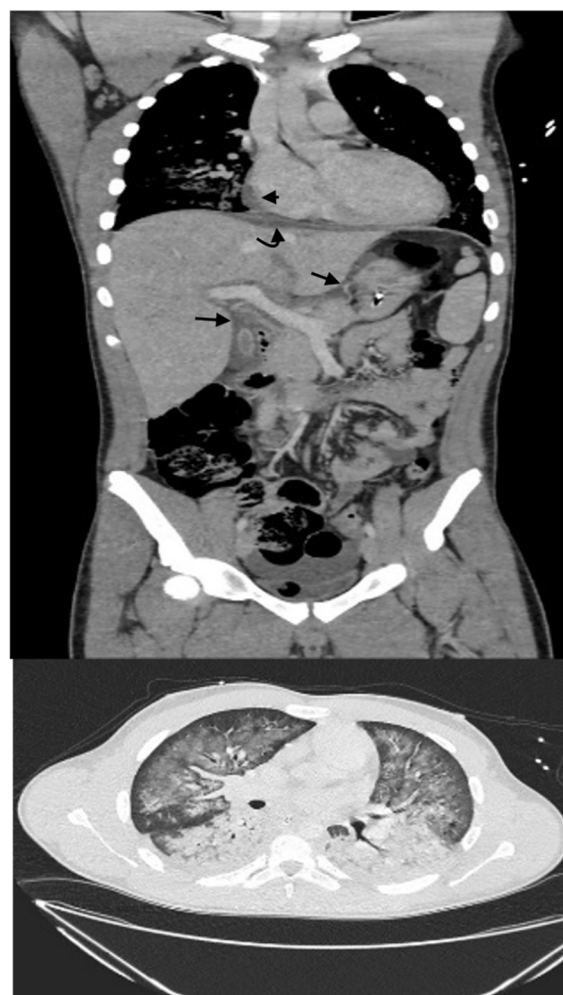

Fig. 3. Coronal image CT scan of upper abdomen and chest shows diffuse inflammation changes and soft tissue oedema around the gallbladder, liver and within the epigastric region (Black arrows), Subphrenic oedema (Curved arrow), tiny pericardial effusion (Arrowhead). Axial image of lung bases; shows bilateral symmetrical lung changes of dense consolidation and perihilar ground-glass opacifications.

from that incidentally seen on previous echocardiogram.

A screen for infection was negative. This included multiple blood and urine cultures, serology for Cytomegalovirus (CMV), Epstein Barr virus (EBV), Parvovirus, murine typhus, *Mycoplasma pneumoniae*, Human immunodeficiency virus (HIV), Hepatitis B and C and *Streptococcus pyogenes*. Polymerase chain reaction (PCR) for EBV, *Leptospira*, and *Neisseria meningitidis* were negative. Reverse Transcriptase-PCR (RT-PCR) of nasopharyngeal aspirate and bronchoalveolar lavage (BAL) for SARS-CoV-2 virus were negative. RT-PCR of BAL was also negative for the following pathogens: Influenza virus, Respiratory Syncytial Virus (RSV), Adenovirus, Metapneumovirus, Parainfluenza, Rhinovirus, Enterovirus, *Legionella* species and *Mycoplasma pneumoniae*. Serology for SARS-CoV2 revealed positive IgM and IgG anti-spike antibodies but negative nucleocapsid antibodies, consistent with response to vaccination. An immunology screen including antinuclear antigen (ANA), antineutrophil cytoplasmic antibodies (ANCA), complement levels, immunoglobulins and lymphocyte subsets was normal.

The patient developed acute respiratory distress syndrome for which hydrocortisone 50 mg IV q6 hourly and prone ventilation were commenced. Respiratory function improved sufficiently for him to be extubated on day 5. However, the patient remained critically unwell, febrile and confused. A CT brain and venogram showed no meningeal enhancement and no evidence of thrombosis. Investigations [Table 2] showed elevated CRP, procalcitonin, creatinine phosphokinase (CPK), progressive thrombocytopenia, elevated ferritin and triglycerides with high D-dimer levels. Soluble CD25 was significantly elevated at 14,563 pg/ml (0–2677). To investigate the possibility of HLH a bone marrow biopsy was performed. The bone marrow aspirate showed no excess of histiocytes, with no features of haemophagocytosis.

A repeat ECG at day 7 [Fig. 4] showed new T wave inversion in leads III, AVF, V2 and V3. Cardiac enzymes were elevated with TnT of 153 ng/L and NT-proBNP was 133 pmol/L. Cardiac MRI demonstrated a small pericardial effusion, evidence of mild-to-moderate global systolic impairment with left ventricular ejection function of 42%, and a small area of epicardial enhancement in the basal to mid anterolateral left ventricle segments consistent with myocarditis.

At this point (day 7) the patient was pulsed with 3 days of intravenous methylprednisolone, 500 mg/day and treated with human normal immunoglobulin (IVIg) 2 mg/kg. There was a rapid clinical improvement with defervescence and resolution of all symptoms and rash. CXR showed rapid clearing of the pulmonary infiltrates and within 3 days the patient no longer required supplemental oxygen. Markers of inflammation fell quickly, and the ECG changes resolved. The patient was discharged home 14 days after admission having made an excellent recovery.

Discussion

This patient's presentation was initially thought to be due to infection, however the rapid progression with multisystem involvement, an extensive negative screen for infection and lack of response to broad spectrum antibiotics lead us to re-consider this diagnosis. The presentation included unremitting fever, an erythematous cutaneous rash, gastrointestinal involvement, altered mental status, and myocarditis. In addition, there were features of inflammation (elevated CRP, procalcitonin ferritin, LDH, sCD25), lymphopaenia and thrombocytopenia. While no haemophagocytosis was seen on bone marrow aspirate, the patient had other features in keeping with secondary HLH.

The clinical features fit the Brighton Collaboration Case Definition for MIS-C with a level 1 certainty (Vogel et al., 2021 May 21). Severe pulmonary involvement has been excluded from the definition of MIS in order to exclude patients with COVID-19 pulmonary disease. However, in one series, up to 20% of children admitted to hospital required mechanical ventilation (Feldstein et al., 2020). In our case, we were able to exclude SARS-CoV-2 infection given lack of epidemiological risk as the patient lived in an area of New Zealand where there was no community transmission of COVID 19, and antibody testing was consistent with vaccination and not infection. While the patient's presentation had some features in keeping with KD, the presence of severe gastrointestinal symptoms and cardiac dysfunction without coronary artery dilation are more in keeping with MIS-C. Patients with features of severe MIS-C are likely to have an inflammatory state similar to that seen in HLH (Attwell et al., 2021). Cases of secondary HLH have been reported following inactivated SARS COV-2 vaccine (Uwaydah et al., 2021) and ChAdOx1 nCov-19 vaccination (Vogel et al., 2021 May 21).

The patient had a partial improvement with low dose glucocorticoids then a rapid response when treated according to the treatment guidelines for PIMS-TS (Harwood et al., 2021) with pulsed methylprednisolone and human normal IVIg. Given this rapid response to treatment we did not need to consider other treatment options such as IL-6 inhibitors.

Despite extensive investigations we were unable to identify another cause for this presentation. The patient had received the first dose of BTN162b2 mRNA SARS-CoV-2 vaccination 12 days prior to this illness and whilst we cannot establish definite causality the proximity and nature of this presentation raise a high suspicion that this may be MIS following vaccination (MIS-V). The case was reported to the New Zealand immunisation safety monitoring board. We are unaware of any other reports of probable MIS-V within New Zealand. Following discussion with clinical vaccinologists, at the New Zealand Immune Advisory Centre a decision was made not to proceed with further mRNA vaccination.

Table 2
Laboratory results by day of hospital admission.

Laboratory results (normal ranges)	Day 1	Day 3	Day 4	Day 5	Day 6	Day 7	Day 8	Day 10	Day 14
Haemoglobin (130–175) g/L	143	130	131	122	110	114	121	125	118
Neutrophils (1.9–7.5) x10 ⁹ /L	5.05	1.79	1.16	1.13	2.07	2.51	0.25	2.76	1.78
Lymphocytes (1–4) x10 ⁹ /L	0.32	0.20	0.53	0.26	0.03	0.24	0.81	1.84	3.08
Platelets (150–400) x10 ⁹ /L	106	61	52	46	55	66	78	180	445
CRP (0–8) mg/L	37	170		200	84	36	16	10	
Procalcitonin ng/ml		4.2	6	3.4					
Creatinine (60–105) umol/L	78	52	78	58	45	50	44	47	48
Albumin (34–48) g/L	40	28	26	24	25	26	26	30	34
ALT (0–55 U/L) U/L	73	125		131	126	128		111	107
LDH (120–250)U/L			661		829				
Ferritin (15–150) ug/L				6990			4120		
D- Dimer ((500) mcg/L			13,800	9100	10,500		9000	12,200	3000
Fibrinogen (1.5–4.0) g/L		3.3	3.0	3.4	2.1	1.5		1.1	1.5
Triglycerides (0.5–2.3) mmol/L		3.7		8.4					
Creatinine kinase (60–220) U/L				1650				82	
Troponin T (0–14) ng/L		15				153	177		19
NT-proBNP (<35) pmol/L		26				133	68		4

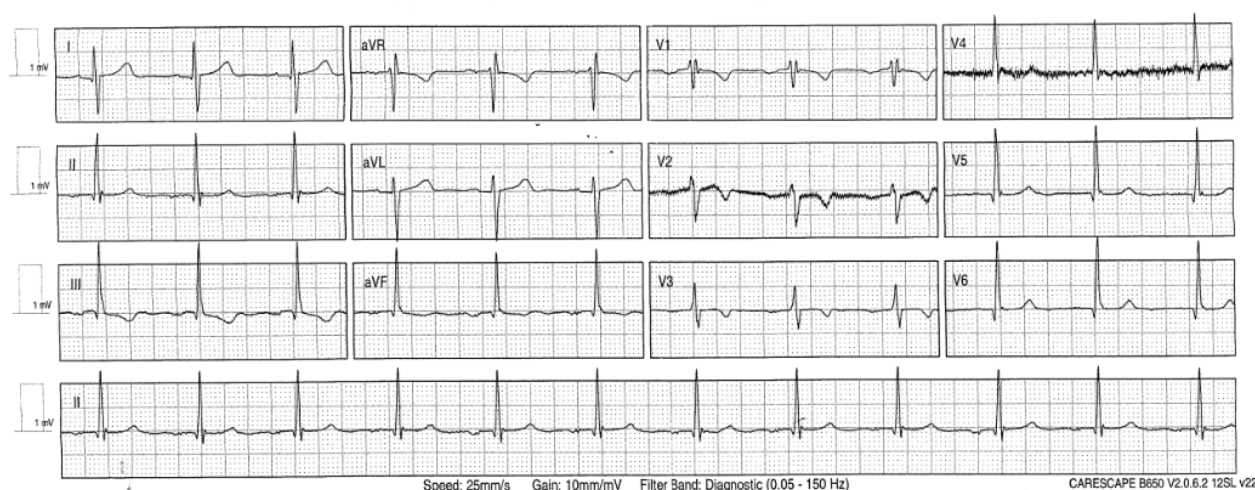


Fig. 4. 12 lead ECG showing T wave inversion in leads III, aVF, V2 and V3.

Conclusions

While the overall efficacy and safety profile of the BNT162b2 COVID-19 vaccine remains excellent, this report highlights the need for clinicians to be aware of the possibility of MIS-V in patients presenting with a multisystem illness in proximity to SARS-CoV-2 vaccination and if the presentation is in keeping with this diagnosis, not to delay directed therapy.

CRedit authorship contribution statement

Patrick Hugh McGann: Conceptualization, Writing – original draft.
Ahmed O.A. Krim: Investigation. **Jared Green:** Writing – review & editing. **Jacqueline Venturas:** Writing – original draft.

Declaration of Competing Interest

The authors declare that they have no known competing financial interests or personal relationships that could have appeared to influence the work reported in this paper.

References

- Attwell, L., Zaw, T., McCormick, J., Marks, J., McCarthy, H. 2021. Haemophagocytic lymphohistiocytosis after ChAdOx1 nCoV-19 vaccination. *J Clin Pathol.* 2021 Jul 22: jclinpath-2021-207760. Epub ahead of print.PMID:34301797.
- Bartsch, Y.C., Wang, C., Zohar, T., Fischinger, S., Atyeo, C., Burke, J.S., Kang, J., Edlow, A.G., Fasano, A., Baden, L.R., Nilles, E.J., Woolley, A.E., Karlson, E.W., Hopke, A.R., Irimia, D., Fischer, E.S., Ryan, E.T., Charles, R.C., Julg, B.D., Lauffenburger, D.A., Yonker, L.M., Alter, G., 2021. Humoral signatures of protective and pathological SARS-CoV-2 infection in children. *Nat Med.* 27 (3), 454–462.
- Feldstein, L.R., Rose, E.B., Horwitz, S.M., Collins, J.P., Newhams, M.M., Son, M.B.F., et al., 2020 Jul 23. Overcoming COVID-19 Investigators, and the CDC COVID-19 Response Team. Multisystem Inflammatory Syndrome in U.S. Children and Adolescents. *N Engl J Med.* 383 (4), 334–346.
- FRANCISCO EM. Meeting highlights from the Pharmacovigilance Risk Assessment Committee (PRAC) 30 August – 2 September 2021 [Internet]. European Medicines Agency. 2021 [cited 2021 Sep 15]. Available from: <https://www.ema.europa.eu/en/news/meeting-highlights-pharmacovigilance-risk-assessment-committee-prac-30-august-2-september-2021>.
- Harwood, R., Allin, B., Jones, C.E., Whittaker, E., Ramnarayan, P., Ramanan, A.V., Kaleem, M., Tulloh, R., Peters, M.J., Almond, S., Davis, P.J., Levin, M., Tometzki, A., Faust, S.N., Knight, M., Kenny, S., Agbeko, R., Aragon, O., Baird, J., Bamford, A., Bereford, M., Bharucha, T., Brogan, P., Butler, K., Carroll, E., Cathie, K., Chikermane, A., Christie, S., Clark, M., Deri, A., Doherty, C., Drysdale, S., Duong, P., Durairaj, S., Emonts, M., Evans, J., Fraser, J., Hackett, S., Hague, R., Heath, P., Herberg, J., Ilina, M., Jay, N., Kelly, D., Kerrison, C., Kraft, J., Leahy, A., Linney, M., Lyall, H., McCann, L., McMaster, P., Miller, O., O'Riordan, S., Owens, S., Pain, C., Patel, S., Pathan, N., Pauling, J., Porter, D., Prendergast, A., Ravi, K., Riorden, A., Roderick, M., Schofield, B.R., Semple, M.G., Sen, E., Shackley, F., Sinha, I., Tibby, S., Verganano, S., Welch, S.B., Wilkinson, N., Wood, M., Yardley, I., 2021. A national consensus management pathway for paediatric inflammatory multisystem syndrome temporally associated with COVID-19 (PIMS-TS): results of a national Delphi process. *The Lancet Child & Adolescent Health* 5 (2), 133–141.
- Kahn, Benjamin BA1; Apostolidis, Sokratis A. MD2,3; Bhatt, Vatsal MD4; Greenplate, Allison R. PhD3,5,6; Kallish, Staci DO7; LaCava, Anthony MD8; Lucas, Alfredo BA1; Meyer, Nuala J. MD, MS8; Negoianu, Dan MD9; Ogdie, Alexis R. MD, MSCE2; Shashaty, Michael G. S. MD, MSCE8; Takach, Patricia A. MD8; Zuroff, Leah MD, MS10; Wherry, E. John PhD3,5,6; Anesi, George L. MD, MSCE, MBE8 Multisystem Inflammation and Organ Dysfunction After BNT162b2 Messenger RNA Coronavirus Disease 2019 Vaccination, *Critical Care Explorations*: November 2021 - Volume 3 - Issue 11 - p e0578.
- Nune, A., Iyengar, K.P., Goddard, C., Ahmed, A.E., 2021. Multisystem inflammatory syndrome in an adult following the SARS-CoV-2 vaccine (MIS-V). *BMJ Case Rep* 14 (7), e243888. <https://doi.org/10.1136/bcr-2021-243888>.
- SARS-CoV-2 mRNA Vaccination-Associated Myocarditis in Children Ages 12-17: A Stratified National Database Analysis | medRxiv [Internet]. [cited 2021 Sep 15]. Available from: <https://www.medrxiv.org/content/10.1101/2021.08.30.21262866v1>.
- Uwaydah, A.K., Hassan, N.M.M., Abu Ghoush, M.S., Shahin, K.M.M., 2021. Adult multisystem inflammatory syndrome in a patient who recovered from COVID-19 postvaccination. *BMJ Case Rep.* 14 (4), e242060. <https://doi.org/10.1136/bcr-2021-242060>.
- Vella, L.A., Giles, J.R., Baxter, A.E., Oldridge, D.A., Diorio, C., Kuri-Cervantes, L. et al. Deep immune profiling of MIS-C demonstrates marked but transient immune activation compared to adult and pediatric COVID-19. *Sci Immunol* [Internet]. 2021 Mar 2 [cited 2021 Sep 15]. <https://www.ncbi.nlm.nih.gov/pmc/articles/PMC8128303/>.
- Vogel, T.P., Top, K.A., Karatzios, C., Hilmers, D.C., Tapia, L.I., Mocer, P., et al., 2021 May 21. Multisystem inflammatory syndrome in children and adults (MIS-C/A): Case definition & guidelines for data collection, analysis, and presentation of immunization safety data. *Vaccine.* 39 (22), 3037–3049.