

# Extramedullary nasal plasmacytoma arising after polyp excision and the role of the inflammation in tumor development: A case report

ARIANNA DI STADIO<sup>1</sup>, VALERIA GAMBACORTA<sup>1</sup>, STEFANO DE CRESCENZO<sup>2</sup>, ANGELO SIDONI<sup>2</sup>, MARIA CRISTINA CRISTI<sup>3</sup>, ALFREDO DI GIOVANNI<sup>1</sup>, MASSIMO MARANZANO<sup>4</sup> and GIAMPIETRO RICCI<sup>1</sup>

Departments of <sup>1</sup>Otolaryngology and <sup>2</sup>Anatomic Pathology, University of Perugia;

<sup>3</sup>Department of Otolaryngology, Silvestrini Hospital, I-65121 Perugia, Italy;

<sup>4</sup>Department of Oral Maxillo-Facial and Facial Plastic Surgery, University of Manchester, Manchester M13 9PL, UK

Received June 7, 2019; Accepted December 6, 2019

DOI: 10.3892/mco.2020.2007

**Abstract.** A correlation between inflammation and cancer has been identified in the case of nasal cancer, however a specific connection between nasal inflammation and extramedullary nasal plasmacytoma (ENP), to the best of our knowledge, has not yet been determined. The present case report describes a patient affected by ENP, in who the tumor arose in the same area, from which a nasal polyp was previously surgically removed, five months after the polyp excision. The patient underwent surgical endoscopic tumor asportation without being treated with radio-chemotherapy. ENP was totally removed via surgery and no signs of recurrence were identified by endoscopy or magnetic resonance imaging during the last check-up 1 year after tumor asportation. It was hypothesized that in this elderly patient, who was exposed to viral infections and pollution for several years, ENP may be correlated to the inflammatory process that occurred after surgery, and this likely contributed to a neoplastic mutation in B-cells.

## Introduction

Extramedullary nasal plasmacytoma (ENP) is a rare disease characterized by localized monoclonal plasma cells proliferation without apparent systemic involvement (1). This tumor represents 5-10% of all plasma cell neoplasms (2) and, despite it can be identified in different areas of the head and neck, nasal cavity and nasopharynx are generally the structures

more affected from this type of cancer (3) maybe because nose is frequently exposed to inflammation related to pollution and viral infection (4).

ENP represents 1% of all head cancers (5) and involves unspecific symptoms, such as nasal obstruction due to inflammation of the nasal mucosa over the tumor in the 80% of cases; sometimes this main symptom is associated with epistaxis (35%), pain (20%), rhinorrhea (10%), regional lymphadenopathy (10%), and more rarely with a paralysis of the sixth cranial nerve (5%) (6).

The endoscopy appearance of ENP looks like as a benign mass, especially in the early stages of the tumor (7), so it can be misdiagnosed as a polyp and treated by corticosteroids. The steroid treatment, by reducing the inflammation, improves part of the symptoms but it does not solve the problem.

Still today, the etiopathology of ENP is not completely understood, anyway researchers identified that smog and viruses [commonly present in the upper airways tract (UA)] are inflammatory agents able to induce carcinogenesis; this phenome explains the presence of the tumors observed in this upper respiratory tract (8,9). However, a correlation between the nasal inflammation and ENP has not been identified yet.

In this case report, we described a rare case of ENP that arose, 5 months after surgical removal of a nasal polyp, in the same area from which the polyp has been resected. This clinical evidence might support the association between inflammation and ENP especially in patients over 70 years old that have been exposed to the carcinogens for several years.

## Case report

This case study was conducted in accordance with the Declaration of Helsinki and all procedures followed the Institutional Regulations Board (IRB) of Silvestrini Hospital (Perugia, Italy). The study was approved by the IRB of Silvestrini Hospital in January 2018, but no approval number was assigned in accordance with the national laws. The patient signed a written informed consent for the treatment of his data (publication of his data and images).

---

*Correspondence to:* Dr Arianna Di Stadio, Department of Otolaryngology, University of Perugia, Piazza Menghini 1, I-65121 Perugia, Italy  
E-mail: arianna.distadio@unipg.it; ariannadistadio@hotmail.com

*Key words:* extramedullary nasal plasmacytoma, polyp, nasal obstruction, surgery, inflammation, tumorigenesis

A 72-year-old male patient was initially admitted to the Department of Otolaryngology of Silvestrini University Hospital in January 2018 due to a progressive, predominantly left-sided nasal obstruction without other additional associated symptoms, such as nasal discharge, epistaxis, or pain.

The patient never experienced any nasal issues until 7 months ago, when he started to perceive a prevalently unilateral nasal obstruction. The man treated the symptomatology, as suggested by his general doctor, by cortisone inhalation (two puffs three times per day for 20 days). The patient, due to the persistence of the symptoms even after the end of the inhalatory treatment, arranged a consultation with an otolaryngologist.

During the first clinical consultation, we did not observe any evident craniofacial dysmorphism. An endoscopic examination of the nose was performed to further investigate the origin of the nasal obstruction. The exam revealed the presence of a round mass located anteriorly in the left choana, which did not present any connection with the nasal ostium. The lesion was covered by normal mucosa. The finding occupied 30% of the nostril (Fig. 1). No other pathological findings were identified during the nasal endoscopy both in the left and in the right choana. The rhinopharynx was disease free as the mouth and the throat.

The mass, clinically diagnosed as unilateral left nasal polyp, was surgically removed. Magnetic resonance imaging (MRI) was not performed because of the clinical findings (symptoms and signs) were supportive of a benign lesion. The tissue, was sent, immediately after removal, to the pathologist to determine its histologic nature. The conclusive report of the pathologist described an inflammatory picture without signs of atypical mucosa, typical aspect of a benign nasal polyp. The man completely solved the nasal obstruction one week after the surgery.

In the end of May, five months later the surgery, the patient presented to our clinic due to the recurrence of the left nasal obstruction. Also in this occasion, he did not present any associated symptoms as nasal discharge, epistaxis, or pain. The nasal-endoscopic investigation identified a pale-reddish round mass into the left choana very close to the nostril. The mass, occupying about 80% of the left nasal cavity (Fig. 2), presented a smooth surface covered by normal mucosa. The remaining structures as nasopharynx, mouth, pharynx, larynx, neck, ears appeared to be free of any disease.

In this occasion, due to the recurrence of the pathology, we decided, although the lesion seemed to be a benign finding, to further investigate the patient by MRI. The exam identified a mass in the left middle nasal cavity that extended to the homolateral ethmoid bone with no bony erosion (Fig. 3).

The tumor was completely removed by surgery through endonasal endoscopy and, the operatory piece was sent to the pathologist for cellular and biochemical analyses. The pathology report described the following: i) Macroscopically, the neoplasm consisted of multiple greyish fragments up to 0.8 cm that were submitted in their entirety for histological review and ii) microscopically, the mass consisted of a pure population of plasma cells with basophilic cytoplasm and small, eccentric nuclei (Fig. 4).

The immunohistochemistry, conducted on the tissue surgically removed, confirmed the plasmatic nature of the cells, including CD38 and MUM1 (Fig. 5A and B) reactivity. The

presence of the monotypic immunoglobulin light chains  $\kappa$  and the absence of  $\lambda$  chain (Fig. 6A and B) indicated a monoclonal process. Due to these two findings the pathologist concluded that the removed mass was an ENP (10).

Due to results observed on the second specimen, the first one was re-analyzed for confirming the primary diagnosis of polyp. The pathologist observed a mixed inflammatory infiltrate consisting of neutrophil granulocytes, eosinophils and lymphocytes on the background of an edematous stroma that confirmed the first diagnosis and he did not retain necessary to perform immunohistochemistry on the tissue due to the clarity of the finding.

The patient, to complete the diagnostic process, underwent a hematologic screening, protein electrophoresis, Bence Jones proteinuria, and bone marrow analysis. Total body MRI and PET/CT scans were performed to exclude a systemic condition. The definitive diagnosis, based on the results of all overmentioned investigations, was extramedullary plasmacytoma class 1 (11).

After an oncologist consulting, we decided to avoid additional treatments such as radio and chemotherapy, due to the early stage of tumor and the absence of systemic disease, but to monitor the patient with short follow ups. The patient was seen at 1 week, 2 weeks, and 6 months after surgery and consecutively every 6 months until May 2019 (date of last follow up). The nasal endoscopy performed during the last control was negative for disease recurrence, as well as the MRI results.

## Discussion

We presented a patient suffering from nasal obstruction as single isolated symptom-without additional complaints, which in the first occasion was due to polyp in the left choana as clearly identified by the endoscopic exam, while on the second observation five months after polyp removal, was due to a malign mass. The mass responsible of the nasal obstruction appeared like a benign lesion at the endoscopic investigation and the apparent benignity was confirmed by the absence of an infiltrative process (typical of malignant lesion) in the MRI but, the immunohistochemistry performed on the tissue removed by surgery evidenced the typical findings of an ENP.

The bilateral nasal obstruction is a common symptom both of the inflammation associated with a nasal polyp and, to the one due to a neoplasia. In our patient, this symptom was correlated with a benign lesion in the first observation and secondly, it was symptomatic of an ENP in early stage. In both observations, the patient never presented any other symptoms associated with the nasal obstruction such as epistaxis (12,13), rhinorrhea (12), anosmia (13), nasal discharge (12,13) or sudden episode of obstructive sleep apnea syndrome (14). These symptoms have been widely described in patients affected from nasal cancer (12-14).

In addition to this poor symptomatology, the endoscopy, that we performed in both consultations, showed similar benign aspects. The mass had a regular smooth shape, and it was covered by normal mucosa during the first check-up (nasal polyp) or slightly inflamed mucosa during the second one (ENP). Slight mucosa inflammation is rarely observed in case of neoplasia, in fact, usually, a malign lesion presents a mucosa with color alterations (extreme redness) (11) a mass

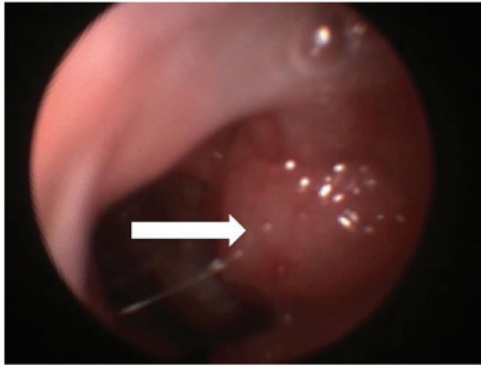


Figure 1. Endoscopic examination (first observation) revealed a pink mass (white arrow) in the left nostril with a smooth surface that occupied approximately 30% of the left nasal cavity.

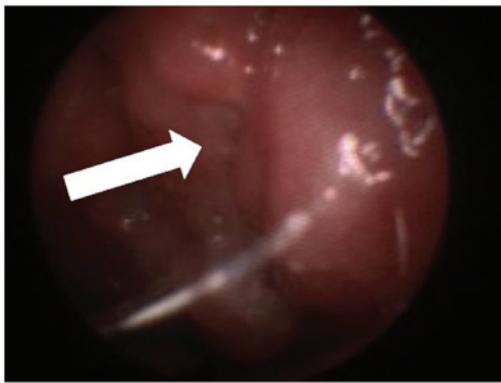


Figure 2. Endoscopic examination (second observation) showed a pale-reddish mass in the left nostril without ulceration (white arrow), which occupied approximately 80% of the left nasal cavity.

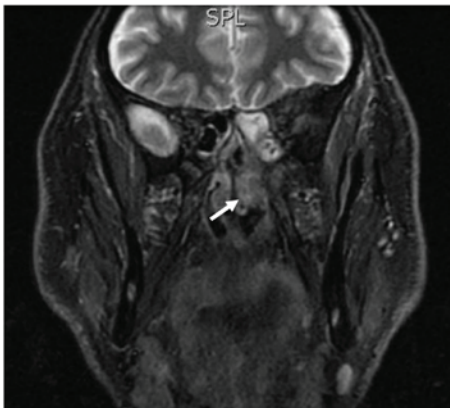


Figure 3. MRI scan of the mass in the left middle nasal cavity with extension to the homolateral ethmoid and no bony erosion as indicated by the white arrow. MRI, magnetic resonance imaging.

with irregular shape (12-14), and diffused ulcerations with or without active bleeding (13). A benign mass instead, appears with a pink or grey in natural mucosa (15) and the neoformation presents a regular round/ovular shape (15).

Our patient performed MRI (an investigation generally performed after nasal endoscopy to evaluate the invasiveness and aggressiveness of the mass) that did not evidence typical

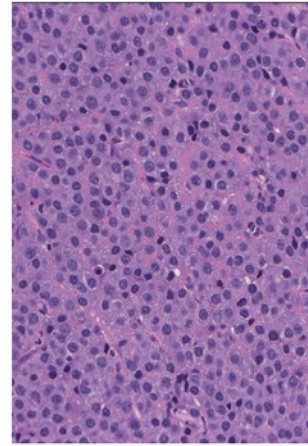


Figure 4. Hematoxylin and eosin staining performed on the ENP tissue before immunohistochemical analysis. Magnification, x30. ENP, extramedullary nasal plasmacytoma.

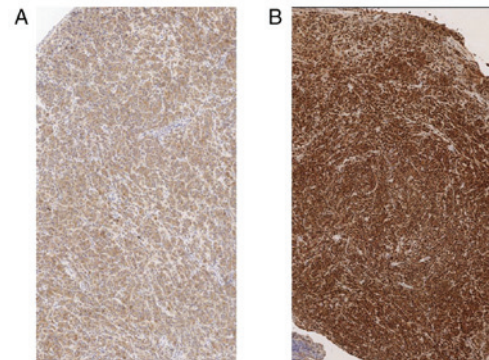


Figure 5. Immunohistochemistry of the mass removed during the second surgery. (A) A positive reactivity to CD38 from plasma cells and the presence of plasmablastic differentiation. (B) A positivity to MUM1 nuclear stain indicative of plasma cell differentiation. Magnification, x3.

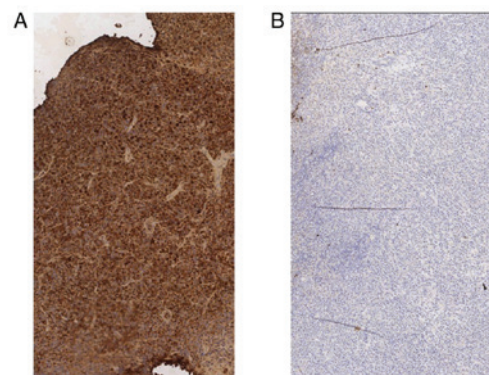


Figure 6. The immunochemistry results performed on the mass removed in the second surgery indicated a positivity for (A)  $\kappa$  chain and a (B) negative for  $\lambda$  chain. This finding was indicative of an ENP. Magnification, x3. ENP, extramedullary nasal plasmacytoma.

signs of cancer, such as bone erosion (16) or infiltration of close structures (12).

Despite the two neoformations showed clinically similar aspects, the results of pathologic analysis on their histology were completely opposite. The tissue removed during the first



surgery presented an inflammatory aspect without signs of cellular atypia, while the one that was taken off during the second surgery presented  $\kappa$  chains characteristic of ENP (6,17).

The mass in the left choana recurred within five months after the first surgery for polyp's asportation. The mass arose exactly in the same point from which the polyp was previously removed, looking like as the inflammation from the previous surgery had stimulated an aberrant lymphocyte response.

The relationship between inflammation and cancer has been previously described by other authors in particular related to nose and paranasal sinus (4). The researchers affirmed that episodes of recurrent inflammation could be a precursor of nasopharyngeal carcinoma (4). However, the connection/correlation between inflammation and ENP has not been investigated yet.

ENP is a B-cell neoplasm that generally occurs in the UA. The nose, paranasal sinus, and oropharynx are commonly exposed to smog that contains small carcinogenic particles (8) and also to recurrent virus infection (e.g., Epstein-Barr), whose role in cancer development has been confirmed (9). Virus and carcinogenic substance hyperstimulate B-cells to react for fighting the host aggression in case of viral infection, or to fight the inflammation in case of smog (18,19). The rapid growth of B-lymphocyte due to recurrent inflammations induces genetic mutations in these hematopoietic cells that can cause tumor formation (20,21).

The aging process impacts the immune system by reducing the number of hematopoietic cells (22) and by increasing the risk of DNA mutation during an active immune response that, furthermore, may contribute to the development of hematopoietic cancer (23). Smog and pesticides as *Hexachlorobenzene* that are normally present in the air can affect the efficiency of the immune-response and increasing the risk of DNA damage (24).

We speculate that in our patient ENP was due to an aberrant B-cells response in an aging patient (72 years old) exposed to pollution and pesticides for years. Recurrent inflammation and the direct effect of the carcinoid on the DNA integrity, other than their effect on the immunity answer (reduced) allowed the growth of an ENP, by activating an aberrant immune response after the polyp excision.

As support of 'the inflammatory theory' as cause of ENP, we had the 1 year follow-up of our patient without disease recurrence, despite he did not receive radio-chemotherapy as usual in cases of ENP (24-26). We speculate that the absence of tumor recurrence was due to the absence of additional inflammatory process that could potentially stimulate a new aberrant immune response.

This case report presents a limitation related to the absence of Epstein-Barr test that was not performed during the patient's screening.

Additional studies on large sample are necessary to conclusively elucidate which factors contribute to development of nasal plasmacytoma.

Plasmacytoma might present all aspects of a typical benign lesion, both clinically and upon MRI, especially in the early stages of the disease. The resection of a benign nasal lesion in an elderly patient should be carefully monitored over time, because of the inflammation induced by the surgery could initiate the growth of a malignant lesion due to a pathological immune response.

## Acknowledgements

Not applicable.

## Funding

No funding was received.

## Availability of data and materials

The datasets used and/or analyzed during the present study are available from the corresponding author on reasonable request.

## Authors' contributions

ADS contributed to study design, analysis of data, analysis of results, definition of conclusion and writing. VG contributed to data collection, supported writing the manuscript. SDC and AS collected and analyzed the data. MCC contributed to data collection and the literature review. ADG collected the data and contributed to the literature review. MM collected the data and contributed criticism to the paper. GR analyzed the results, critically revised the manuscript and supervised the study.

## Ethics approval and consent to participate

The present study was approved by the International Revisional Board (IRB) of Silvestrini University Hospital and the patient signed a written consent before being included in the study.

## Patient consent for publication

The patient authorized publication of his data in an anonymized form.

## Competing interests

The authors declare that they have no competing interests.

## References

1. Does GM, Landgren O, McGlynn KA, Curtis RE, Linet MS and Devesa SS: Plasmacytoma of bone, extramedullary plasmacytoma, and multiple myeloma: Incidence and survival in the United States, 1992-2004. *Br J Haematol* 144: 86-94, 2009.
2. International Myeloma Working Group: Criteria for the classification of monoclonal gammopathies, multiple myeloma and related disorders: A report of the international myeloma working group. *Br J Haematol* 121: 749-757, 2003.
3. Chang YL, Chen PY and Hung SH: Extramedullary plasmacytoma of the nasopharynx: A case report and review of the literature. *Oncol Lett* 7: 458-460, 2014.
4. Wu EL, Riley CA, Hsieh MC, Marino MJ, Wu XC and McCoul ED: Chronic sinonasal tract inflammation as a precursor to nasopharyngeal carcinoma and sinonasal malignancy in the United States. *Int Forum Allergy Rhinol* 7: 786-793, 2017.
5. Moyano MD, Mella TA, Eduardo PO and Bermeo SJ: Extramedullary plasmacytoma nasal septum: Case report and literature review. *Rev Otorrinolaringol Cir Cabeza Cuello* 76: 301-307, 2016.
6. Susnerwala SS, Shanks JH, Banerjee SS, Scarffe JH, Farrington WT and Slevin NJ: Extramedullary plasmacytoma of the head and neck region: Clinicopathological correlation in 25 cases. *Br J Cancer* 75: 921-927, 1997.

7. Corvo MA, Granato L, Ikeda F and de Próspero JD: Extramedullary nasal plasmacytoma: Literature review and a rare case report. *Int Arch Otorhinolaryngol* 17: 213-217, 2013.
8. Nettesheim P, Creasia DA and Mitchell TJ: Carcinogenic and cocarcinogenic effects of inhaled synthetic smog and ferric oxide particles. *J Natl Cancer Inst* 55: 159-169, 1975.
9. Sinha S and Gajra A: Cancer, Nasopharynx. In: StatPearls (Internet). StatPearls Publishing, Treasure Island, FL, 2019.
10. El-Naggar AK, Chan JKC, Grandis JR, Takata T and Sliotweg PJ (eds): WHO classification of head and neck tumours. Vol 9. 4th edition. IARC Press, Lyon, 2017.
11. Bataskis JG: Pathology consultation. Plasma cell tumors of the head and neck. *Ann Otol Rhinol Laryngol* 92: 311-313, 1983.
12. Ashraf MJ, Azarpira N, Khademi B, Abedi E, Hakimzadeh A and Valibeigi B: Extramedullary plasmacytoma of the nasal cavity report of three cases with review of the literature. *Iran Red Crescent Med J* 15: 363-366, 2013.
13. Fernandes AM, Podovani JA and Maniglia JP: Extramedullary plasmocytoma of nasopharynx: A case report and revision of literature. *BJORL* 64: 296-298, 1998.
14. Asai N, Ohkuni Y, Kawamura Y and Kaneko N: A case of obstructive sleep apnea syndrome caused by malignant melanoma in the nasal cavity and paranasal sinus. *J Cancer Res Ther* 9: 276-277, 2013.
15. Stevens WW, Schleimer RP and Kern RC: Chronic rhinosinusitis with nasal polyps. *J Allergy Clin Immunol Pract* 4: 565-572, 2016.
16. Agarwal A: Neuroimaging of plasmacytoma. A pictorial review. *Neuroradiol J* 27: 431-437, 2014.
17. Strojjan P, Soba E, Lamovec J and Munda A: Extramedullary plasmacytoma: Clinical and histopathologic study. *Int J Radiat Oncol Biol Phys* 1: 692-701, 2002.
18. Yi B, Rykova M, Jäger G, Feueracker M, Hörl M, Matzel S, Ponomarev S, Vassilieva G, Nichiporuk I and Choukèr A: Influences of large sets of environmental exposures on immune responses in healthy adult men. *Sci Rep* 5: 13367, 2015.
19. Hatton OL, Harris-Arnold A, Schaffert S, Krams SM and Martinez OM: The interplay between epstein-Barr virus and B lymphocytes: Implications for infection, immunity, and disease. *Immunol Res* 58: 268-276, 2014.
20. Jeon JP, Kim JW, Park B, Nam HY, Shim SM, Lee MH and Han BG: Identification of tumor necrosis factor signaling-related proteins during epstein-barr virus-induced B cell transformation. *Acta Virol* 52: 151-159, 2008.
21. Hansen KD, Sabunciyan S, Langmead B, Nagy N, Curley R, Klein G, Klein E, Salamon D and Feinberg AP: Large-scale hypomethylated blocks associated with epstein-barr virus-induced B-cell immortalization. *Genome Res* 24: 177-184, 2014.
22. Geiger H and Rudolph KL: Aging in the lympho-hematopoietic stem cell compartment. *Trends Immunol* 30: 360-365, 2009.
23. Moehrle BM and Geiger H: Aging of hematopoietic stem cells: DNA damage and mutations? *Exp Hematol* 44: 895-901, 2016.
24. Starek-Świechowicz B, Budziszewska B and Starek A: *Hexachlorobenzene* as a persistent organic pollutant: Toxicity and molecular mechanism of action. *Pharmacol Rep* 69: 1232-1239, 2017.
25. Creach KM, Foote RL, Neben-Wittich MA and Kyle RA: Radiotherapy for extramedullary plasmacytoma of the head and neck. *Int J Radiat Oncol Biol Phys* 73: 789-794, 2009.
26. Attanasio G, Viccaro M, Barbaro M, De Seta E and Filippo R: Extramedullary plasmacytoma of paranasal sinuses. A combined therapeutic strategy. *Acta Otorhinolaryngol Ital* 26: 118-120, 2006.



This work is licensed under a Creative Commons Attribution-NonCommercial-NoDerivatives 4.0 International (CC BY-NC-ND 4.0) License.