

Case report

Purtscher-like retinopathy in adult-onset Still's disease, complicated by treatment-related central serous chorioretinopathy

Anthony A. Tang, Albert L. Lin^{**}

Department of Ophthalmology, University of Mississippi Medical Center, Jackson, MS, USA

ARTICLE INFO

Keywords:

Adult-onset Still's disease
Purtscher-like retinopathy
Central serous chorioretinopathy

ABSTRACT

Purpose: We describe a case of Purtscher-like retinopathy associated with adult-onset Still's disease, complicated by the development of central serous chorioretinopathy secondary to high dose corticosteroids.

Observations: A 53 year old female diagnosed with adult-onset Still's disease (AOSD) presented to us with findings consistent with Purtscher-like retinopathy in both eyes, with 20/70 visual acuity in the right eye and 20/20 visual acuity in the left eye. She was initiated on high dose corticosteroids by her rheumatologists for her AOSD. A month later, her vision worsened significantly to counting fingers at 3 feet in the right eye and 20/60 visual acuity in the left. Her examination revealed serous macular detachments involving her fovea consistent with central serous chorioretinopathy secondary to exogenous steroids. After discussion with her rheumatologists, she was tapered off her steroids quickly and bridged to steroid sparing agents, with subsequent resolution of her serous macular detachments and improvement of vision back to baseline.

Conclusion and Importance: The association of Purtscher-like retinopathy and AOSD is important from a multi-disciplinary standpoint due to the possibility of life-threatening systemic thrombotic microangiopathy. In addition, patients undergoing treatment for AOSD with exogenous corticosteroids may develop central serous retinopathy with vision loss, and may require quick transitioning to steroid-sparing agents if focal laser is not feasible.

1. Introduction

Adult-onset Still's disease (AOSD) is a rare multi-organ inflammatory disease that can present with a daily spiking fever, arthralgia/arthritis, neutrophil-dominant leukocytosis, hepatosplenomegaly, and evanescent salmon-colored maculopapular rashes.¹ A retrospective study estimated the annual incidence of AOSD to be 0.16/100000, affecting both genders equally.² Because of the breadth of organ systems AOSD can affect, AOSD is typically a diagnosis of exclusion. In the absence of other diseases, the Yamaguchi criteria can be implemented to help identify AOSD since there are no definitive tests. AOSD has a bimodal age distribution between the ages of 15–25 and 36–46.³ Previous studies have elaborated on the impact of AOSD on multiple organ systems, but other than uveitis, ophthalmologic manifestations are rare. However, a Purtscher-like retinopathy (PLR) has been described several reports in the literature.^{4–9} In this report, we describe a case of PLR associated with AOSD, complicated by central serous chorioretinopathy caused by high dose corticosteroids.

1.1. Case

A 53-year-old African American female originally presented to an outside health facility with a rash on her arms that later spread to her trunk and legs. She denied any recent history of travel or tick exposure. After a negative rapid strep throat test, she was sent home on a short low dose steroid taper and amoxicillin. One week after her initial presentation of the rash, she developed myalgia, weakness, fatigue, dyspnea on exertion, and a 102.5 °F fever and went to a different health facility for care. Work-up revealed an elevated white blood cell count of $12.0 \times 10^9/L$, erythrocyte sedimentation rate (ESR) of 55 mm/hr and C-reactive protein (CRP) 14.9 mg/mL. She received vancomycin and piperacillin/tazobactam empirically with a diagnosis of fever of unknown origin and was discharged. Three days later, she presented to our facility with the symptoms mentioned above with minimal improvement other than reduction of her fever to 100.1 °F.

After admission to the medical team with rheumatological consultation, her work-up, including thyroid stimulating hormone, lipids, hepatitis panel, liver enzymes, antistreptolysin O, procalcitonin, viral flu titers, fibrinogen, HIV, SPEP, inguinal lymph node biopsy, and blood

^{*} Corresponding author. Department of Ophthalmology, 2500 N. State Street, Jackson, MS, 39216, USA.

E-mail address: alin@umc.edu (A.L. Lin).

<https://doi.org/10.1016/j.ajoc.2020.100631>

Received 19 July 2019; Received in revised form 18 November 2019; Accepted 21 February 2020

Available online 25 February 2020

2451-9936/ © 2020 The Authors. Published by Elsevier Inc. This is an open access article under the CC BY-NC-ND license

(<http://creativecommons.org/licenses/by-nc-nd/4.0/>).

cultures were unremarkable. As a diagnosis of exclusion, AOSD was suspected due to her physical exam findings along with an elevated ESR, CRP, ferritin, and lactate dehydrogenase (LDH). She was started on high dose corticosteroids and methotrexate, and then subsequently discharged as her fever improved on corticosteroids. She was readmitted a month later after finishing her course on corticosteroids due to worsening labs, with ferritin trending up to 20,000 ng/mL and LDH of 1,367 units/liter. She was restarted on high dose intravenous corticosteroids, with which her labs trended down, and she was discharged again with a longer corticosteroid taper. During her admission, she developed blurry vision and photopsias, and was quickly referred to the ophthalmology service upon discharge.

On initial presentation, best corrected visual acuity (BCVA) in the right eye (OD) was 20/70 and 20/20 in the left eye (OS). Intraocular pressure, pupils, extraocular motility, confrontational visual fields, and anterior segment were normal. Fundus examination revealed peripapillary cotton wool spots with hemorrhages present that were consistent with Purtscher-like retinopathy. Early blockage in the peripapillary retina secondary to cotton wool spots was noted on fluorescein angiography (FA), along with mild proximal venous staining and late leakage in the affected vessels (Fig. 1). Optical coherence tomography (OCT) showed focal lesions of ganglion cell thickening consistent with cotton wool spots, but no other abnormalities. PLR was made as a tentative diagnosis secondary to her AOSD, and observation other than treatment of her AOSD was recommended. A few days after her initial visit, she developed severeodynophagia and hypotension for which she was admitted back into the hospital. She was initially started on fluconazole and acyclovir, but later switched to ganciclovir when her cytomegalovirus (CMV) titers were found to be elevated. An esophagogastroduodenoscopy revealed chronic gastritis. In addition, during her hospital stay she developed acute thrombocytopenia with schistocytes

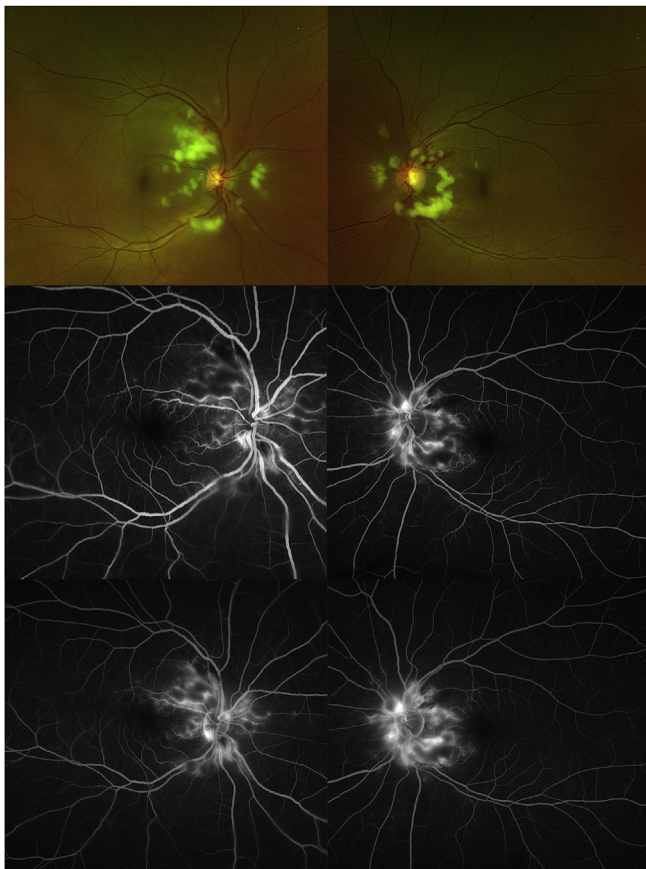


Fig. 1. Top - Fundus photos of both eyes on initial visit. Middle - Early phase FA. Bottom - late phase FA.

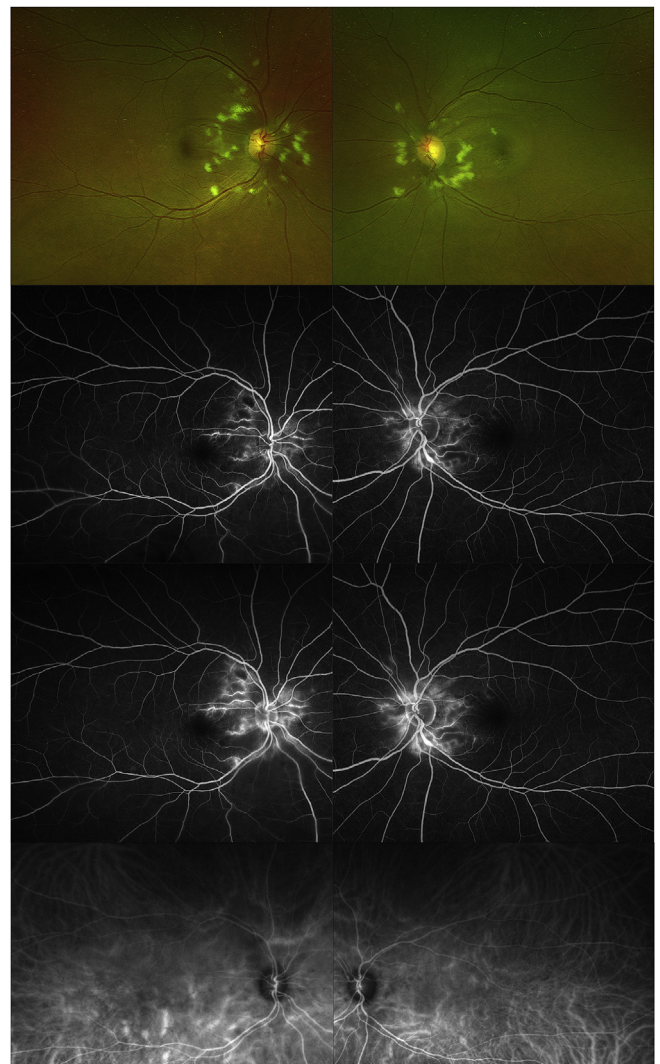


Fig. 2. Top - Fundus photos one month after initial visit. Top middle - Early phase FA. Middle bottom - late phase FA. Bottom - ICG angiography of both eyes.

on peripheral smear and low fibrinogen (< 200 mg/dl). She was treated for disseminated intravascular coagulation with fresh frozen plasma and cryoprecipitate. Hematology work-up was unremarkable for an exact underlying cause other than her disseminated CMV causing macrophage activation syndrome. After improvement in her presenting symptoms, she was discharged on high dose oral steroids, and her methotrexate was held due to her CMV viremia.

She followed up one month after her initial ophthalmology presentation due to worsening vision. On exam, BCVA worsened to counting fingers at 3 feet OD and 20/60 OS. Fundus examination revealed her cotton wool spots resolving, but she now had new serous macular detachments affecting the fovea. FA demonstrated minimal new changes from the original FA other than slight leakage at the optic nerve in both eyes. Indocyanine green angiography (ICG) revealed inferior venous beading of the arcade vessels with multiple inferior, mildly dilated hyperfluorescent choroidal vessels, but no focal areas of leakage or pooling (Fig. 2). No angiographic evidence of classic central serous chorioretinopathy was noted on FA or ICG. OCT demonstrated serous subfoveal macular detachments in both eyes (Fig. 3). Her findings were consistent with corticosteroid-induced central serous chorioretinopathy, and her chronic course of high dose steroids was thought to be the culprit. Neither focal laser nor photodynamic therapy were considered viable treatment options due to the lack of focal areas of

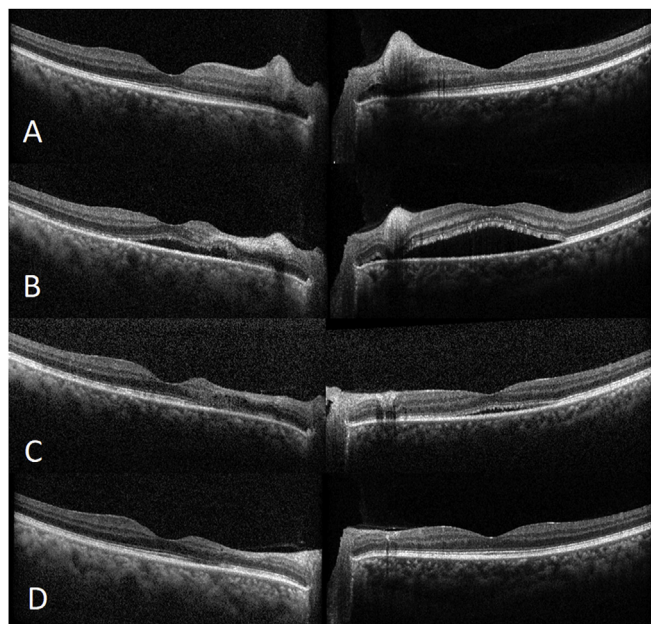


Fig. 3. Top - Baseline visit OCT of both eyes. Middle top - OCT of both eyes 1 month after presentation with new serous detachments. Middle bottom - OCT of both eyes 6 weeks after development of CSR while tapering steroids. Bottom - OCT almost 3 months after development of CSR while off steroids and on methotrexate and anakinra. BCVA of 20/50 in the right eye and 20/20 in the left eye.

leakage on angiography. After discussion with her rheumatology team, her corticosteroids were tapered again after her CMV viremia cleared, and was then restarted on methotrexate and bridged to anakinra. Subsequent visits demonstrated both an improvement in subretinal fluid and vision with a corresponding lower dose of corticosteroids. Three months after the initial steroid taper, her vision returned to baseline (BCVA of 20/50 OD and 20/20 OS).

2. Discussion

AOSD was first described in 1896 in adults with similar findings as children with systemic juvenile idiopathic arthritis that did not meet the full criteria for rheumatoid arthritis. The etiology of AOSD is still unknown. The typical symptoms seen in AOSD are intermittent daily fevers, salmon-pink maculopapular rashes, and arthritis. Elevated ESR, CRP, and ferritin levels are common lab findings in this disease. Though not a diagnostic finding of AOSD, there have been several instances of PLR associated with AOSD in the literature. Since PLR is often asymptomatic because it is fovea sparing, PLR may be possibly more common in AOSD than previously thought. In this case, PLR developed secondary to AOSD that was later complicated by central serous chorioretinopathy from exogenous corticosteroids.

The exact pathophysiology of PLR is still debated, but the most accepted mechanism currently involves microembolization of retinal vasculature.¹² The resulting microvascular occlusions of the nerve fiber layer result in the characteristic cotton wool spots noted on fundoscopic exam. AOSD causes activation of the complement system and leukocyte aggregation, which can cause leukoembolization in the retina. As the inflammatory disease is treated, the leukoembolization is thought to resolve along with treatment, resulting in resolution of exam findings. Some reports described an association of a life-threatening systemic thrombotic microangiopathy (TMA) with PLR in AOSD, as demonstrated in this report. However, it is not clear whether the PLR precedes TMA as a prognostic indicator, if PLR is secondary to TMA, or occurs in conjunction with TMA.^{5,8,9} In our case, our patient developed disseminated intravascular coagulation, a form of TMA, after being

diagnosed with PLR, but was managed successfully.

The general treatment algorithm of AOSD starts with anti-inflammatories, typically high dose corticosteroids, with a prolonged taper of corticosteroids if the disease is controlled.¹⁰ Steroid-sparing agents such as methotrexate and azathioprine are then used if AOSD is not adequately managed by high dose corticosteroids or recurs during corticosteroid taper. For recalcitrant AOSD after the previous treatments, biologics such as interleukin-1 and interleukin-6 inhibitors can be used for immunomodulation. Though the literature suggests some cases of PLR improving with high dose corticosteroids, currently there is no evidence high dose corticosteroids specifically for PLR associated with AOSD improves long-term vision.^{7,11,12} In this case, exogenous corticosteroids, known to be a risk factor for central serous chorioretinopathy, induced a secondary central serous chorioretinopathy with subsequent vision loss.^{13,14} One report has described the development of central serous chorioretinopathy in AOSD after exogenous steroids, but unlike our case, PLR did not develop and angiography revealed expansile dots amenable to focal photodynamic therapy.¹⁵ In our patient, vision improvement and reduction in subretinal fluid directly correlated with a decreasing dose of steroids as well as resuming methotrexate, with eventual bridging to anakinra.

3. Conclusion

The association of PLR with AOSD is a finding both ophthalmologists and rheumatologists should both be aware of, especially since no visual symptoms may be initially present. With the increasing number of reports describing PLR with AOSD, this association may possibly be more prevalent than once thought. Multidisciplinary management of AOSD along with complete ophthalmological examination may be warranted due to the association of PLR with possible life-threatening TMA. Last, any patient with deteriorating vision while on treatment for AOSD needs a prompt fundoscopic exam with ancillary testing to assess for treatment complications. In this case, the development of central serous chorioretinopathy on exogenous corticosteroids, not amenable focal laser or photodynamic therapy, warranted changing treatment to steroid-sparing agents quickly with corticosteroid taper to both improve vision and to treat the patient's AOSD. Recognition of these potential issues of PLR associated with AOSD is critical between disciplines in order to optimize both systemic and ophthalmologic management.

Patient consent

Consent to publish the case report was not obtained. This report does not contain any personal information that could lead to the identification of the patient.

Declaration of competing interests

The authors declare that they have no known competing financial interests or personal relationships that could have appeared to influence the work reported in this paper.

References

1. Yamaguchi M, Ohta A, Tsunematsu T, et al. Preliminary criteria for classification of adult Still's disease. *J Rheumatol.* 1992;19:424–430.
2. Akkara Veetil BM, Yee AH, Warrington KJ, Aksamit Jr AJ, Mason TG. Aseptic meningitis in adult onset Still's disease. *Rheumatol Int.* 2012;32(12):4031–4034.
3. Owlia MB, Mehrpoor G. Adult-onset Still's disease: a review. *Indian J Med Sci.* 2009;63(5):207–221.
4. Yachoui R. Purtscher-like retinopathy associated with adult-onset still disease. *Retin Cases Brief Rep.* 2018 Fall;12(4):379–381.
5. El Karoui K, Karras A, Lebrun G, et al. Thrombotic microangiopathy and purtscher-like retinopathy associated with adult-onset still's disease: a role for glomerular vascular endothelial growth factor? *Arthritis Rheum.* 2009;61:1609–1613.
6. Buyukavsar C, Karagoz E, Sonmez M, et al. A rare ocular manifestation of adult onset still's disease: purtscher's-like retinopathy. *Ocul Immunol Inflamm.* 2018;26(2):286–291.

7. Liu FC, Chiang SY, Chang DM, et al. Purtscher's-like retinopathy as an initial presentation of adult-onset Still's disease: a case report and review of the literature. *Clin Rheumatol*. 2007;26:1204–1206.
8. Okwuosa TM, Lee EW, Starosta M, et al. Purtscher's-like retinopathy in a patient with adult-onset still's disease and concurrent thrombotic thrombocytopenic purpura. *Arthritis Rheum*. 2007;57:182–185.
9. Masuyama A, Kobayashi H, Kobayashi Y, et al. A case of adult-onset Still's disease complicated by thrombotic thrombocytopenic purpura with retinal microangiopathy and rapidly fatal cerebral edema. *Mod Rheumatol*. 2013 Mar;23(2):379–385.
10. Mitrovic S, Fautrel B. Complications of adult-onset Still's disease and their management. *Expert Rev Clin Immunol*. 2018 May;14(5):351–365.
11. Miguel AI, Henriques F, Azevedo LF, et al. Systematic review of Purtscher's and Purtscher-like retinopathies. *Eye*. 2013 Jan;27(1):1–13.
12. Agrawal A, McKibbin M. Purtscher's retinopathy: epidemiology, clinical features and outcome. *Br J Ophthalmol*. 2007 Nov;91(11):1456–1459.
13. Carvalho-Recchia CA1, Yannuzzi LA, Negrão S, et al. Corticosteroids and central serous chorioretinopathy. *Ophthalmology*. 2002 Oct;109(10):1834–1837.
14. Gupta SR, Suhler EB, Rosenbaum JT. The dilemma of central serous retinopathy, a corticosteroid-induced complication, in patients with ocular inflammatory disease. *J Rheumatol*. 2010 Sep;37(9):1973–1974.
15. Liu T, Dong Y, Zong DF, et al. A case of adult-onset Still's disease presenting with multifocal central serous chorioretinopathy. *Eur Rev Med Pharmacol Sci*. 2014;18(3):421–425.