



Vein Graft Aneurysm after Aorto-Renal Bypass for Childhood Renovascular Hypertension Due to Fibromuscular Dysplasia

Ara Cho¹, Hyunmin Ko², and Seung-Keo Min¹

¹Division of Vascular Surgery, Department of Surgery, Seoul National University College of Medicine, Seoul, ²Department of Surgery, Kyung Hee University Hospital, Seoul, Korea

Renovascular hypertension (RVHT) is a major cause of surgically correctable secondary hypertension. Refractory hypertension despite multiple antihypertensive drugs requires angioplasty, surgical revascularization, or even nephrectomy. Herein, we report a pediatric patient who had been treated with angioplasty, nephrectomy, and aortorenal bypass surgery for RVHT due to fibromuscular dysplasia and re-do endoaneurysmal graft replacement for a vein graft aneurysm. This case highlights the various treatment modalities for RVHT and the recurrent nature of the disease with a rare presentation of a vein graft aneurysm after aortorenal bypass.

Key Words: Renovascular hypertension, Fibromuscular dysplasia, Aneurysm, Saphenous vein

Received April 13, 2022
Revised June 13, 2022
Accepted June 20, 2022
Published on June 30, 2022

Corresponding author: Seung-Keo Min
Division of Vascular Surgery, Department of Surgery, Seoul National University Hospital, 101 Daehak-ro, Jongno-gu, Seoul 03080, Korea
Tel: 82-2-2072-0297
Fax: 82-2-766-3975
E-mail: skminmd@snuh.org
<https://orcid.org/0000-0002-1433-2562>

Copyright © 2022 The Korean Society for Vascular Surgery

This is an Open Access article distributed under the terms of the Creative Commons Attribution Non-Commercial License (<http://creativecommons.org/licenses/by-nc/4.0>) which permits unrestricted non-commercial use, distribution, and reproduction in any medium, provided the original work is properly cited.

Cite this article; Vasc Specialist Int 2022. <https://doi.org/10.5758/vsi.220017>

INTRODUCTION

Renovascular hypertension (RVHT) is one of the leading causes of secondary hypertension. It is correctable by surgery and comprises 5% to 10% of childhood hypertension. The causes of RVHT are diverse, including fibromuscular dysplasia (FMD), Moyamoya disease, Takayasu arteritis, or else. FMD is a heterogeneous group of systemic, noninflammatory, and nonatherosclerotic disease of the vascular wall. FMD causes renal artery stenosis (RAS) with “string of beads” appearance, and also affects intrarenal microvasculature and renin-angiotensin system, which leads to RVHT [1]. Patients with refractory hypertension, despite adequate medication, require endovascular treatment including balloon angioplasty and stenting, as well as surgical treatment, including bypass graft and nephrectomy. Each intervention has its advantages and drawbacks. Aortorenal bypass surgery (ARBS), a surgical revascularization method,

commonly utilizes an autologous saphenous vein graft (SVG) as a vascular conduit.

Vein graft aneurysm (VGA) is an uncommon cause of graft failure and requires appropriate management. According to previous reports, the incidence of VGA varies from 5% to 50% [2-4]. VGA is commonly treated by replacing the aneurysm with a prosthetic graft. We report a case of pediatric RVHT, treated with various modalities including balloon angioplasty, nephrectomy, and ARBS. Rare VGA developed later and was treated with endoaneurysmal prosthetic graft replacement. This case report was approved by the Institutional Review Board of Seoul National University Hospital (IRB no. 2102-107-1197). The requirement for informed consent was waived due to the retrospective nature of the study.

CASE

A 14-year-old female was referred to our vascular clinic due to uncontrolled hypertension. She was diagnosed with RVHT secondary to FMD at age 7. Examination and screening revealed a systolic blood pressure of 170 mmHg, stenosis of both renal arteries, and right kidney atrophy, as observed in computed tomography (CT) images (Fig. 1A).

Balloon angioplasty was performed for stenotic renal arteries and three antihypertensive drugs were administered, including amlodipine, atenolol, and carvedilol (Fig. 1B). However, blood pressure was not well controlled, and the plasma renin activity (PRA) was very high, measuring 58 ng/mL/h (normal range, 0.3-2.9). Two months later,

right nephrectomy was performed, however, hypertension persisted. Repeated balloon angioplasty of the stenotic left renal artery was performed, but recurrent stenosis developed after two months (Fig. 1C). Therefore, bypass surgery was decided. A retrograde aorto-left renal bypass was performed using an autologous great saphenous vein (GSV) graft (Fig. 2A). ARBS was performed via a midline transperitoneal approach. After injecting heparin (4,000 units) and mannitol (6 g), the aorta and left renal artery were clamped, and a reversed GSV was used for a bypass conduit. Immediately after the operation, the PRA was reduced to 1.0 ng/mL/h and the blood pressure returned to within the normal range. Two years after surgery, her blood pressure increased and was refractory to antihyper-

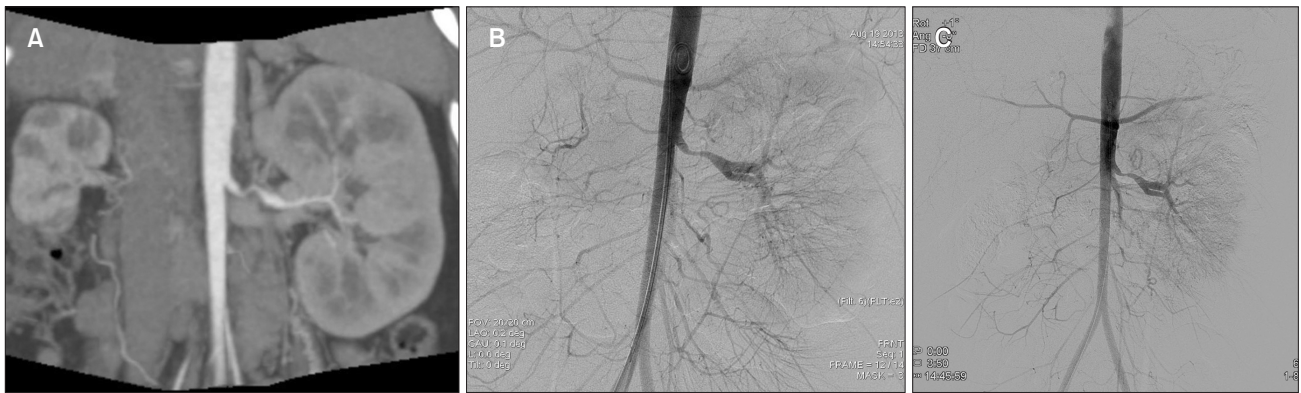


Fig. 1. (A) Computed tomography coronal image showed atrophic right kidney due to total occlusion of the right renal artery and severe stenosis of the left renal artery (LRA). (B) Angiography confirmed severe stenosis of the LRA. Percutaneous transluminal angioplasty (PTA) was carried out on the LRA. (C) Angiography 3 months after PTA revealed restenosis requiring repeated angioplasty.

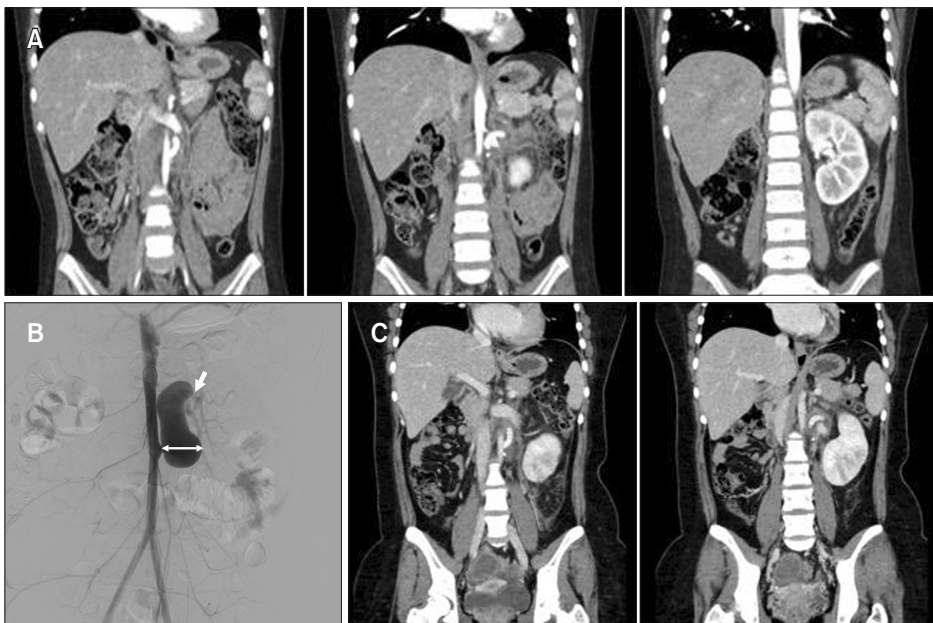


Fig. 2. (A) Computed tomography (CT) showed the patent aorto-renal bypass graft without stenosis or aneurysm. (B) Angiography 2 years after surgery revealed aneurysmal dilatation (2.3 cm, two-way arrow) of the autologous vein graft. Arrow indicates distal anastomotic stenosis. (C) CT after endoaneurysmal graft replacement with expanded polytetrafluoroethylene graft showed patent graft.

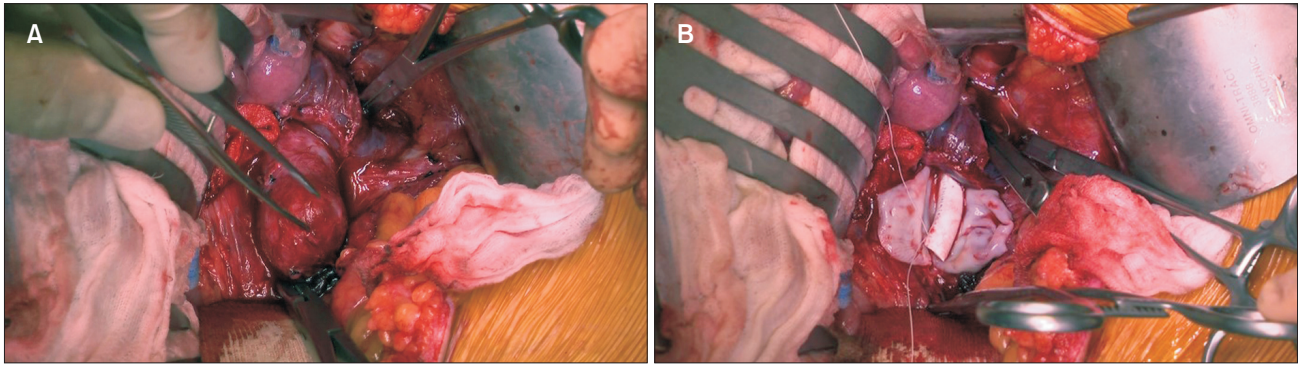


Fig. 3. (A) Operative photo showed the vein graft aneurysm in the left aorto-renal bypass. (B) Endoaneurysmal graft replacement with a 6-mm Gore-Tex graft was performed.

tensive medication. PRA increased to 34.3 ng/mL/h. Five years after bypass surgery, follow-up CT revealed a 2.3-cm sized aneurysmal dilatation of the vein graft and stenosis at the distal anastomosis site to the left renal artery (Fig. 2B). Balloon angioplasty with a 4-mm balloon catheter was performed on the stenotic portion of the distal left renal artery, and minimal flow improvement was observed. Due to the high risk of aneurysmal rupture and remaining distal anastomotic stenosis, a re-do surgery was performed. After retroperitoneal dissection, the previous aorto-renal vein graft was dissected from the adherent tissues (Fig. 3). After injecting heparin (4,000 units) and mannitol (20 g), the aorta and left renal artery were clamped, and endoaneurysmal graft replacement was performed using a 6-mm expanded polytetrafluoroethylene (ePTFE) graft (Gore-Tex, W. L. Gore & Associates, Flagstaff, AZ, USA). The distal anastomosis was extended to the bifurcation of the left renal artery. Postoperative CT showed intact graft flow (Fig. 2C). The postoperative course was uneventful, and the patient was discharged with a prescription for two antihypertensive medications. At discharge, PRA decreased to 4.43 ng/mL/h and the serum creatinine level was normal. Serial duplex scanning was performed every 6 months thereafter, and there were no adverse events up to a year of follow-up.

DISCUSSION

Childhood hypertension is rare, and 5% to 10% of cases are caused by renovascular disease. The causes of RVHT are fibromuscular dysplasia, neurofibromatosis type 1, syndromic disease such as Marfan syndrome, vasculitis such as Takayasu arteritis, Moyamoya disease and extrinsic compression such as neuroblastoma [5]. The purposes of treating RVHT are to control the blood pressure elevation and maintain the renal mass and preserve renal function by improving the circulation in the kidney. The initial treat-

ment involves antihypertensive medication, lifestyle modifications, and risk factor management [5].

The indication for revascularization in treating adult RVHT due to atherosclerosis remains controversial. Revascularization may be helpful in patients with refractory hypertension, rapid deterioration of pulmonary edema or glomerular filtration rate, progressive vascular occlusive disease, and pediatric RVHT. Surgical restoration of renal blood flow was prevalent in the 1960s; however, endovascular procedures for renal artery revascularization have increased exponentially since 1996 [6]. Along with angioplasty, stent placement aids long-term patency. Surgical revascularization is another option. Renal artery reimplantation has been performed on the aorta, superior mesenteric artery, and segmental renal arteries. Renal bypass includes the aortorenal, iliorenal, splenorenal, and interposition of renorenal bypass. Resection of the pathologic segment followed by re-anastomosis or renal artery patch angioplasty are other possible options. Partial or total nephrectomy is performed if necessary [7]. This case is valuable in that many serial treatment modalities were performed, from minimally invasive to invasive nephrectomy and bypass. Furthermore, rare VGA developed and was treated using a re-do operation. Vascular surgeons should learn about the merits and drawbacks of each therapy, and a multidisciplinary team approach is optimal for treating this disease.

Endovascular treatment is minimally invasive and cosmetically superior since there is no incision. It can be performed under local anesthesia, although general anesthesia is usually required in pediatric patients. However, restenosis of the renal artery may occur; therefore, regular follow-up and repeated intervention are required. Finally, contrast-related problems occur in patients with renal dysfunction. In pediatric patients, balloon angioplasty is preferred and stenting is not recommended considering the patient's growth.

Surgical revascularization should be reserved for the patients refractory to balloon angioplasty. Due to the lack of conduits and small vessels for manipulation, bypass surgery is usually deferred to adolescents. Nephrectomy of an atrophic kidney is an important surgical option to treat RVHT by removing the source of the elevated renin-angiotensin system without significant loss of functioning renal mass.

This report focuses on the surgical treatment of RVHT, especially bypass surgery and VGA.

1) How does a vein graft aneurysm develop? What are the risk factors?

The hemodynamic environment of the renal bed, which has low resistance and high-velocity blood flow, is considered to be the cause of SVG enlargement and aneurysmal formation, similar to the arteriovenous fistula for hemodialysis. Disruption of the vasa vasorum in children with immature adventitial and medial plexuses creates focal dilation with local ischemia [8]. Post-stenotic dilatation also contributes to aneurysm formation in SVGs. Patients with genetic diseases or vasculitis may have defective GSVs, which are prone to aneurysmal degeneration.

2) How often a VGA develops after ARBS?

In 1973, Stanley et al. [3] from the Michigan group reviewed 100 ARBS with SVG and reported complications such as graft expansion, aneurysmal dilatation, and stenosis. The rate of aneurysmal change was 6%, and they warned of potential aneurysmal degeneration of the SVG in the pediatric population with RVHT. In 1981, Stanley and Fry [4] reported a 20% incidence of aneurysmal degeneration in SVGs implanted in children. Revascularization with vein grafts was standard during the 1960s; however, more than half of conduits underwent aneurysmal deterioration.

However, in 1974, Dean et al. [9] reviewed 108 patients with SVGs for ARBS who were followed up for up to 9 years. Aneurysmal degeneration was observed in approximately 5% of patients, and none required reoperation.

3) Which conduit is optimal for aortorenal bypass in pediatric RVHT?

Possible vascular conduits for renal revascularization include autologous veins, arteries, and prosthetic grafts. A vein is the most commonly used conduit for ARBS and autologous GSV is mainly used. GSV surpasses prosthetic grafts in terms of resistance to infection, better primary patency, and ease of handling, particularly for branch artery repair [10].

Coleman et al. [7] from the Michigan group reported that vein grafts should be avoided for children who require ARBS due to the risk of aneurysmal change. Rather they preferred the internal iliac artery (IIA) as a conduit for ARBS. There is a concern regarding IIA excision for grafting due to the risk of pelvic ischemia; however, there has been no report of buttock claudication and genitourinary dysfunction [7]. In addition, splenic, hepatic, and gastroduodenal arteries are recommended for renal revascularization in children without celiac axis-associated diseases [11].

Another option is prosthetic grafting. As children have growth potential, surgical revascularization using a prosthetic graft should be delayed until puberty. In addition, prosthetic grafts are more susceptible to infection than autologous grafts. The incidence of prosthetic graft infections ranges from 1% to 6% [12]. Stanley et al. [2] did not recommend prosthetic grafts due to potential infectivity, technical difficulties in anastomosing to small arteries, and unpredictable long-term durability considering the life expectancy of children.

FMD causes abnormal cell growth in arterial walls, resulting in dissection and multifocal stenosis. Moreover, FMD is not known to involve the veins or lymphatic system [13]. Therefore, the use of vein grafts for FMD is not an absolute contraindication.

According to our institution's protocol, autologous vein grafts, especially GSV, are recommended as the first choice of vascular conduit for ARBS. However, in FMD patients with a high risk of VGA, other conduits or surgical techniques must be considered. Anastomosing a prosthetic graft to a 2-mm artery is challenging, and long-term patency is doubtful. Using an autogenous artery also predisposes patients to vasculitis and aneurysmal changes.

4) Does a VGA rupture, and when does a VGA need to be treated?

In this case, VGA was observed two years after ARBS using autologous GSV. After two more years of follow-up, the VGA was replaced with a prosthetic graft, considering the increased risk of rupture and concomitant anastomotic stenosis.

Although rupture is rare, growing aneurysms increase the risk of ruptures. Interestingly, there are only two reports of VGA ruptures in the literature. In 1999, Lavigne et al. [14] reported that a 42-year-old female patient with epigastric pain had a rupture of a 6 cm-sized VGA, 19 years after ARBS with GSV. A nephrectomy was performed, and the patient was discharged without complications. In 2000, Travis et al. [10] reported the rupture of a 6-cm aneurysm in a 75-year-old female 22 years after ARBS with SVG. The

patient underwent bypass with an ePTFE graft without complications. These two patients had ruptured aneurysms measuring 6 cm, which are definite indications for surgical treatment. In pediatric patients, no cases of rupture have been reported.

Treatment for VGA is indicated in cases of symptomatic or high-risk complications. VGA causes compression, fistula formation in the adjacent structures, and rupture. The threshold diameter of VGA rupture is unknown; however, the threshold diameter of the re-do operation should be >2 cm and <6 cm.

5) How to treat a VGA

Common methods for treating aortorenal VGA are replacement using a prosthetic graft, either endoaneurysmal or after aneurysm resection, or endovascular treatment. There are some case reports of successful open repair; six cases used prosthetic grafts, including four PTFE grafts and two Dacron grafts [7,10,15-17]. In addition, in 2018, Hu et al. [18] reported a novel endovascular intervention for aortorenal VGA using covered stent and coils, which remained intact after a 12-month follow-up. A covered stent can be deployed when the proximal and distal landing zones are sufficiently long without branching, which was not applicable in our case.

6) How to prevent a VGA?

Recently, Ciftci et al. [19] reported good results with external stenting after vein grafting for popliteal artery aneurysms after a 12-month follow-up. The biomechanical effects of external stenting may reduce luminal irregularities, intimal hyperplasia, thrombus formation, oscillatory shear stress, and aneurysm dilatation. External stenting after ARBS should also be tested.

Neufang et al. [20] reported 57 infrainguinal bypasses performed with varicose GSV segments with external PTFE reinforcement. The primary and secondary 5-year patency rates were 54% and 73%, respectively. We postulate that

external wrapping of the vein graft with a prosthetic graft may prevent the progression and rupture of the VGA. VGA prevention by external stenting or wrapping needs to be proven after long-term follow-up.

In conclusion, this report dealt with the management of pediatric RVHT secondary to FMD and the complications of VGA. This case demonstrates the complexity of the treatment for ongoing RAS progression and recurrent stenosis. The optimal treatment must be individualized according to the child's specific renal artery disease and relevant medical conditions. In ARBS for pediatric RVHT, a vein graft carries a risk of aneurysmal change, especially in FMD. Thus, it is necessary to evaluate aneurysmal changes using serial and long-term duplex ultrasound or CT scanning. VGA can be treated with prosthetic graft replacement.

FUNDING

None.

CONFLICTS OF INTEREST

The authors have nothing to disclose.

ORCID

Ara Cho

<https://orcid.org/0000-0002-4609-5207>

Hyunmin Ko

<https://orcid.org/0000-0002-5078-6860>

Seung-Kee Min

<https://orcid.org/0000-0002-1433-2562>

AUTHOR CONTRIBUTIONS

Concept and design: SKM. Analysis and interpretation: AC, HK. Data collection: AC, HK. Writing the article: AC, SKM. Critical revision of the article: AC, SKM. Final approval of the article: all authors. Statistical analysis: none. Obtained funding: none. Overall responsibility: SKM.

REFERENCES

- 1) van Twist DJL, de Leeuw PW, Kroon AA. Renal artery fibromuscular dysplasia and its effect on the kidney. *Hypertens Res* 2018;41:639-648.
- 2) Stanley JC, Criado E, Upchurch GR Jr, Brophy PD, Cho KJ, Rectenwald JE, et al. Pediatric renovascular hypertension: 132 primary and 30 secondary operations in 97 children. *J Vasc Surg* 2006;44:1219-1228; discussion 1228-1229.
- 3) Stanley JC, Ernst CB, Fry WJ. Fate of 100 aortorenal vein grafts: characteristics of late graft expansion, aneurysmal dilatation, and stenosis. *Surgery* 1973;74:931-944.
- 4) Stanley JC, Fry WJ. Pediatric renal artery occlusive disease and renovascu-

- lar hypertension. Etiology, diagnosis, and operative treatment. *Arch Surg* 1981;116:669-676.
- 5) Tullus K, Brennan E, Hamilton G, Lord R, McLaren CA, Marks SD, et al. Renovascular hypertension in children. *Lancet* 2008;371:1453-1463.
 - 6) Murphy TP, Soares G, Kim M. Increase in utilization of percutaneous renal artery interventions by medicare beneficiaries, 1996-2000. *AJR Am J Roentgenol* 2004;183:561-568.
 - 7) Coleman DM, Eliason JL, Beaulieu R, Jackson T, Karmakar M, Kershaw DB, et al.; University of Michigan Pediatric Renovascular Hypertension Center. Surgical management of pediatric renin-mediated hypertension secondary to renal artery occlusive disease and abdominal aortic coarctation. *J Vasc Surg* 2020;72:2035-2046.e1.
 - 8) Short RHD. The vasa vasorum of the femoral vein. *J Pathol* 1940;50:419-430.
 - 9) Dean RH, Wilson JP, Burko H, Foster JH. Saphenous vein aortorenal bypass grafts: serial arteriographic study. *Ann Surg* 1974;180:469-478.
 - 10) Travis JA, Hansen KJ, Miller PR, Dean RH, Geary RL. Aneurysmal degeneration and late rupture of an aortorenal vein graft: case report, review of the literature, and implications for conduit selection. *J Vasc Surg* 2000;32:612-615.
 - 11) Moncure AC, Brewster DC, Darling RC, Atnip RG, Newton WD, Abbott WM. Use of the splenic and hepatic arteries for renal revascularization. *J Vasc Surg* 1986;3:196-203.
 - 12) Zetrenne E, McIntosh BC, McRae MH, Gusberg R, Evans GR, Narayan D. Prosthetic vascular graft infection: a multi-center review of surgical management. *Yale J Biol Med* 2007;80:113-121.
 - 13) Poloskey SL, Olin JW, Mace P, Gornik HL. Fibromuscular dysplasia. *Circulation* 2012;125:e636-e639.
 - 14) Lavigne J, Keppenne V, Limet R. Late rupture of a saphenous vein aortorenal graft. *J Vasc Surg* 1999;29:722-723.
 - 15) Bath J, Cho JS. Aneurysm of a 32-year-old aortorenal saphenous vein bypass graft. *Ann Vasc Surg* 2012;26:1128.e7-1128.e10.
 - 16) Ernst CB, Stanley JC, Marshall FF, Fry WJ. Autogenous saphenous vein aortorenal grafts. A ten-year experience. *Arch Surg* 1972;105:855-864.
 - 17) Di Marco L, Pacini D, Careddu L, Leone A, Di Bartolomeo R. Giant aneurysm of venous aorto-right renal artery bypass. *J Cardiovasc Med (Hagerstown)* 2013;14:610-612.
 - 18) Hu H, Chen X, Wu Z, Zhao J, Huang B, Ma Y, et al. Aneurysmal degeneration of an aortorenal bypass for Takayasu renal artery stenosis: a novel endovascular intervention. *Ann Vasc Surg* 2018;49:316.e1-316.e4.
 - 19) Ciftci Ü, Marti R, Fahrni J, Gähwiler R, Thalhammer C, Gürke L, et al. External stenting and disease progression in vein grafts 1 year after open surgical repair of popliteal artery aneurysm. *J Vasc Surg* 2021;74:521-527.
 - 20) Neufang A, Espinola-Klein C, Savvidis S, Schmiedt W, Poplawski A, Vahl CF, et al. External polytetrafluoroethylene reinforcement of varicose autologous vein grafts in peripheral bypass surgery produces durable bypass function. *J Vasc Surg* 2018;67:1778-1787.