



Case Letter

Bullous pemphigoid in a metastatic lung cancer patient associated with nivolumab



Yuka Maya MD^a, Reine Moriuchi MD, PhD^{a,*}, Yuka Takashima MD^a, Moeko Hotta MD^a, Hiroshi Izumi MD^b, Satoko Shimizu MD, PhD^a

^a Department of Dermatology, Sapporo City General Hospital, Sapporo, Japan

^b Department of Respiratory Medicine, Sapporo City General Hospital, Sapporo, Japan

ARTICLE INFO

Article history:

Received 24 April 2020

Received in revised form 30 August 2020

Accepted 1 September 2020

Keywords:

Bullous pemphigoid

Nivolumab

irAEs

Lung cancer

Dear Editors,

Immune checkpoint inhibitors that target antigens such as programmed cell death protein 1 (PD-1) have been increasingly used to treat advanced malignancies. These medications can induce various distinct adverse events called “immune-related adverse events” (irAEs); however, the spectrum of these has yet to be completely characterized. Herein, we report a rare case of nivolumab-induced bullous pemphigoid (BP).

An 80-year-old Japanese woman presented with itchy bullous eruptions over the entire body. She had been receiving nivolumab therapy (3 mg/kg intravenously every 2 weeks) for 14 months for intractable lung cancer that had metastasized to the lymph nodes, bones, and muscles. Physical examination revealed itchy edematous plaques and tense bullae over the entire body without mucosal involvement (Fig. 1A). Laboratory investigation showed positivity for anti-BP180-NC16a antibodies (53.4 U/mL, normal limit <9 U/mL). A histological examination revealed vacuolar changes at the dermal-epidermal junction with eosinophilic infiltration in the dermis (Fig. 1B). Direct immunofluorescence showed linear C3 deposition at the dermal-epidermal junction (Fig. 1C). A diagnosis of BP was made, and the estimated grade of cutaneous irAEs was grade 3 per the Common Terminology Criteria for Adverse Events. Oral prednisolone (30 mg/day = 0.64 mg/kg/day)

was started and tapered after the discontinuation of the nivolumab therapy. The oral prednisolone was effective, and the patient experienced no relapses until her death from cancer 16 months later.

Nivolumab is a monoclonal antibody that targets PD-1, which is expressed on the surface of immune cells and regulates immunity. Nivolumab and other immune checkpoint inhibitors that target PD-1/PD-L1 and CTLA-4 exert powerful antitumor effects by enhancing the immune reaction. These agents may cause side effects that have been attributed to a persistently stimulated immune system and thus are termed irAEs. Cutaneous irAEs of anti PD-1/PD-L1 inhibitors sometimes manifest as pruritus, generalized maculopapular eruptions, and vitiligo (Lopez et al., 2018). In addition, nivolumab-associated BP is a rare form of cutaneous irAE. A search of PubMed revealed 31 cases of BP that occurred during nivolumab therapy.

Other immune checkpoint inhibitors, including pembrolizumab, durvalumab, and atezolizumab, have also been reported as causative drugs of BP. Although the pathological findings do not differ between conventional BP and BP as an irAE, most patients with anti-PD-1-associated BP show improvement with the discontinuation of the immunotherapy followed by systemic corticosteroid treatment (Jour et al., 2016; Lopez et al., 2018). In patients who continue or restart immunotherapy, the BP worsens or relapses (Anastasopoulou et al., 2018; Jour et al., 2016). These cases confirm the close relationship between PD-1 inhibitor and

* Corresponding author.

E-mail address: parallelridge@yahoo.co.jp (R. Moriuchi).

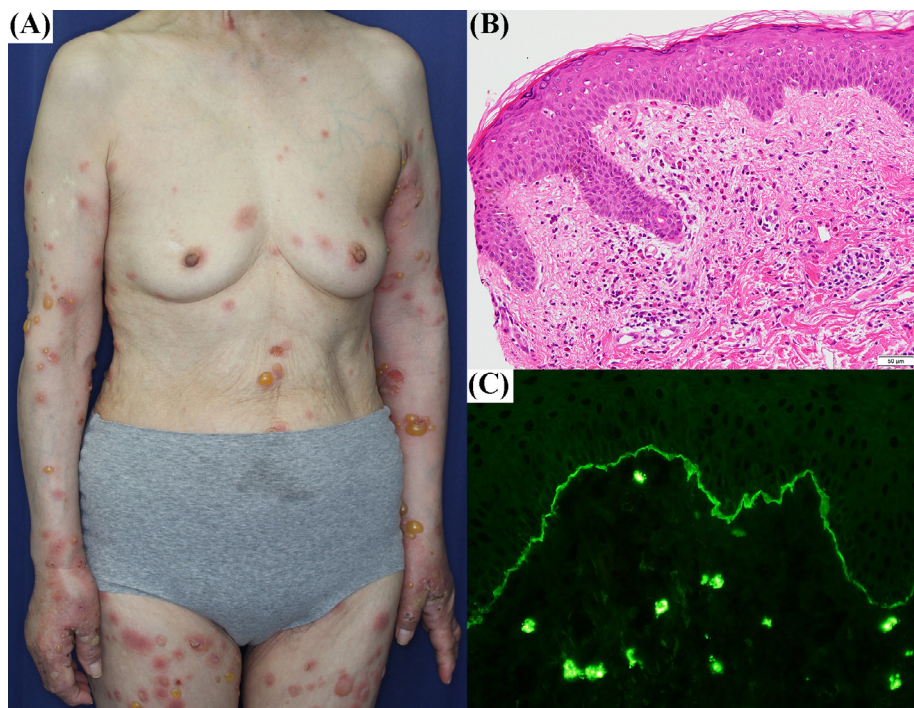


Fig. 1. (A) Pruritic edematous plaques and tense bullae over the entire body; (B) histological examination revealing vacuolar changes at the dermal-epidermal junction with eosinophilic infiltration in the dermis; (C) direct immunofluorescence showing linear C3 deposition at the dermal-epidermal junction. A consent form for the use of the photo was obtained from the patient.

BP, and the cessation of immune checkpoint inhibitors is confirmed to improve severe BP (grades 3–4).

The exact pathomechanism behind PD-1 inhibitor-induced BP remains unclear. One hypothesis is that the blockade of PD-1 can activate autoreactive T cells through decreased regulatory T-cell function that may, in turn, induce autoantibodies in B cells (Hirotsu et al., 2017; Hwang et al., 2016). As immunotherapies against malignant neoplasms are expected to become more common, an improved understanding of the mechanism of autoimmune disorders associated with immune checkpoint inhibitors and the accumulation of those cases are necessary.

Conflicts of Interest

None.

Funding

None.

Study Approval

N/A.

References

Anastasopoulou A, Papaxoinis G, Diamantopoulos P, Christofidou E, Benopoulou O, Stratigos A, et al. Bullous pemphigoid-like skin lesions and overt eosinophilia in a patient with melanoma treated with nivolumab: case report and review of the literature. *J Immunother* 2018;41(3):164–7.

Hirotsu K, Chiou AS, Chiang A, Kim J, Kwong BY, Pugliese S. Localized bullous pemphigoid in a melanoma patient with dual exposure to PD-1 checkpoint inhibition and radiation therapy. *JAAD Case Rep* 2017;3(5):404–6.

Hwang SJE, Carlos G, Chou S, Wakade D, Carlino MS, Fernandez-Penas P. Bullous pemphigoid, an autoantibody-mediated disease, is a novel immune-related adverse event in patients treated with anti-programmed cell death 1 antibodies. *Melanoma Res* 2016;26(4):413–6.

Jour G, Glitza IC, Ellis RM, Torres-Cabala CA, Tetzlaff MT, Li JY, et al. Autoimmune dermatologic toxicities from immune checkpoint blockade with anti-PD-1 antibody therapy: a report on bullous skin eruptions. *J Cutan Pathol* 2016;43(8):688–96.

Lopez AT, Khanna T, Antonov N, Audrey-Bayan C, Geskin L. A review of bullous pemphigoid associated with PD-1 and PD-L1 inhibitors. *Int J Dermatol* 2018;57(6):664–9.