






ORIGINAL RESEARCH

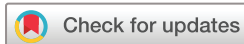Long-term follow-up of certolizumab pegol in uveitis due to immune-mediated inflammatory diseases: multicentre study of 80 patients

José Luis Martín-Varillas ¹, Lara Sanchez-Bilbao,² Vanesa Calvo-Río,² Alfredo Adán,³ Inés Hernanz,³ Adela Gallego-Flores,⁴ Emma Beltran-Catalan ⁵, Sonia Castro-Oreiro,⁶ Patricia Fanlo,⁷ Alvaro Garcia Martos,⁸ Ignacio Torre,⁹ Miguel Cordero-Coma,¹⁰ Juan Ramon De Dios,¹¹ Ángel García-Aparicio,¹² Marisa Hernández-Garfella,¹³ Amalia Sánchez-Andrade,¹⁴ Andrea García-Valle,¹⁵ Olga Maiz,¹⁶ Roberto Miguélez,¹⁷ Sergio Rodríguez-Montero,¹⁸ Ana Urruticoechea,¹⁹ Raúl Veroz,²⁰ Arantxa Conesa,²¹ Cristina Fernández-Carballido ²², Vega Jovaní,²³ Jose J Mondejar,²⁴ Olga Martínez González,²⁵ Patricia Moya Alvarado,²⁶ Susana Romero-Yuste,²⁷ Paula Rubio-Muñoz,²⁸ Eva Peña-Sainz-Pardo,²⁹ Marta Garijo-Bufort,³⁰ Rosalía Demetrio-Pablo,³¹ José L Hernández ^{32,33}, Ricardo Blanco ²

To cite: Martín-Varillas JL, Sanchez-Bilbao L, Calvo-Río V, *et al.* Long-term follow-up of certolizumab pegol in uveitis due to immune-mediated inflammatory diseases: multicentre study of 80 patients. *RMD Open* 2022;**8**:e002693. doi:10.1136/rmdopen-2022-002693

JLH and RB are joint senior authors.

Received 25 August 2022
Accepted 31 October 2022



© Author(s) (or their employer(s)) 2022. Re-use permitted under CC BY-NC. No commercial re-use. See rights and permissions. Published by BMJ.

For numbered affiliations see end of article.

Correspondence to
Dr José L Hernández;
hernandezjluis@gmail.com

ABSTRACT

Objectives To evaluate effectiveness and safety of certolizumab pegol (CZP) in uveitis due to immune-mediated inflammatory diseases (IMID).

Methods Multicentre study of CZP-treated patients with IMID uveitis refractory to conventional immunosuppressant. Effectiveness was assessed through the following ocular parameters: best-corrected visual acuity, anterior chamber cells, vitritis, macular thickness and retinal vasculitis. These variables were compared between the baseline, and first week, first, third, sixth months, first and second year.

Results We studied 80 (33 men/47 women) patients (111 affected eyes) with a mean age of 41.6±11.7 years. The IMID included were: spondyloarthritis (n=43), Behçet's disease (n=10), psoriatic arthritis (n=8), Crohn's disease (n=4), sarcoidosis (n=2), juvenile idiopathic arthritis (n=1), reactive arthritis (n=1), rheumatoid arthritis (n=1), relapsing polychondritis (n=1).

Conclusions CZP seems to be effective and safe in uveitis related to different IMID, even in patients refractory to previous biological drugs.

INTRODUCTION

Non-infectious uveitis (NIU) is a common and severe clinical manifestation occurring in a wide spectrum of immune-mediated inflammatory diseases (IMID), leading to visual loss at a variable rate. In Behçet's disease (BD), it has been estimated that up to 35%–90% of patients may develop uveitis, including the presence of retinal vasculitis.^{1–3}

WHAT IS ALREADY KNOWN ON THIS TOPIC

⇒ Antitumour necrosis factor- α (anti-TNF- α) drugs have substantially improved the management of patients with uveitis refractory to conventional immunosuppressive therapy, especially adalimumab and infliximab; however, evidence on other anti-TNF- α drugs, such as certolizumab pegol (CZP), is scarce.

WHAT THIS STUDY ADDS

⇒ This study provides real-world clinical practice effectiveness of CZP in patients with refractory uveitis in multiple immune-mediated inflammatory diseases, even in those patients with insufficient response to other anti-TNF- α drugs.

HOW THIS STUDY MIGHT AFFECT RESEARCH, PRACTICE OR POLICY

⇒ We can increase the therapeutic armamentarium in the ocular affection of several diseases with difficult management.

Likewise, uveitis was reported in 30%–70% of patients with sarcoidosis.⁴ Similarly, in axial spondyloarthritis (SpA) or juvenile idiopathic arthritis (JIA), acute anterior uveitis is the predominant extra-articular manifestation, with a prevalence of 12%–33% and 10%–20%, respectively.^{5–8} Other systemic inflammatory conditions such as Crohn's disease (CD) or ulcerative colitis (UC) may present with ocular impairment.⁹

However, the increasing development of biological therapy has led to a significant improvement in the ocular prognosis of patients with IMID. Drugs targeting tumour necrosis factor (TNF)- α such as adalimumab (ADA) and infliximab (IFX) have been the most studied group.¹⁰ ADA has been approved by European Medicines Agency (EMA) and Food and Drug Administration (FDA) for non-infectious non-anterior uveitis, based on two phase III trials (VISUAL I and VISUAL II),^{11 12} and long-term follow-up solid data on these patients are reported (VISUAL III).¹³ Although IFX is only authorised in Japan (PDMA) for use in Behçet's uveoretinitis,^{14 15} data on effectiveness and safety profile in Caucasian patients with NIU refractory to conventional immunosuppressive therapy are widely demonstrated.^{16–22} Nevertheless, there is limited evidence to support the use of other anti-TNF- α drugs, such as certolizumab pegol (CZP) or golimumab (GOL), for ocular complications in patients with IMID, and the current focus is mainly on SpA uveitis.^{23–25}

CZP is a Fab fragment of a recombinant humanised anti-TNF- α antibody expressed in *Escherichia coli* and conjugated to polyethylene glycol conferring pharmacokinetic and pharmacodynamic advantages over drugs of the same family.²⁶ In addition, CZP may be a therapeutic option in pregnant women as it lacks the Fc-region which prevents it from crossing the placental barrier.²⁷

Taking all these considerations into account, we aimed to evaluate the long-term effectiveness and safety of CZP therapy in a large series of Caucasian patients with refractory uveitis due to several IMIDs.

PATIENTS AND METHODS

Design, enrolment criteria and definitions

We conducted a national multicentre observational study on 80 patients with IMID with refractory uveitis treated with CZP. Patients who had received CZP between January 2015 and January 2020 were selected and followed-up at the Uveitis Units from several Spanish hospitals.

Anatomical classification of uveitis was performed according to the Standardisation of Uveitis Nomenclature (SUN) Working Group.²⁸

All the patients had uveitis refractory to corticosteroids and had previously received at least one conventional synthetic immunosuppressive drug. The conventional immunosuppressive drugs and dosages used before CZP initiation were as follows: azathioprine (AZA) (100–150 mg/day orally), methotrexate (MTX) (7.5–25 mg/week subcutaneously or orally), ciclosporin A (CsA) (3–6 mg/kg/day orally), mycophenolate mofetil (MMF) (2–3 g/day orally), leflunomide (LFN) (20 mg/day orally), cyclophosphamide (CFM) (500–1000 mg/m²/month intravenously) and salazopyrine (SSZ) (1000–2000 mg/day orally). In case of severe uveitis, the therapeutic scheme included three consecutive pulses of methylprednisolone (MP), 500–1000 mg/day.

Malignancy or systemic infectious diseases were excluded before anti-TNF- α initiation, as previously described.^{16 17 21 22}

CZP was administered at the standard dose of 400 mg at baseline and weeks 2 and 4, then continued as 400 mg injections monthly, or 200 mg injections every other week.

According to SUN classification, remission was established in absence of signs of ocular inflammation for at least 3 months. Relapses or flares were defined as the presence of inflammatory ocular activity in patients who had reached remission.^{28 29} Flares on the same eye were considered separate only if the interval between them was >3 months.²³

Before CZP initiation, all patients signed written informed consent since the prescription of CZP was an *off-label* indication by the EMA for the treatment of non-infectious and non-anterior uveitis.

Outcome variables

To determine effectiveness, the intraocular inflammation, macular thickness, visual acuity and the sparing effect of glucocorticoids were assessed. These variables were recorded at baseline (CZP initiation), first week, first month, third month, sixth month and first and second years. Intraocular inflammation included the following features: anterior or posterior chamber inflammation, vitritis, retinal vasculitis, papillitis and macular thickness. The degree of intraocular inflammation was evaluated according to the SUN Working Group.²⁸ Vitritis was assessed by the Nussenblatt scale.²⁹

Fluorescein angiography (FA) was performed to evaluate the presence of retinal vasculitis. Retinal vasculitis was defined as retinal angiographic leakage, staining and/or occlusion on FA.³⁰

To assess the macular thickness, high-definition optical coherence tomography (OCT), using a Cirrus HD-OCT (Carl Zeiss, Dublin, California, USA), was performed. Scans were obtained using the 512×128 scan pattern. Macular thickening was defined as a macular thickness >250 μ m.

The best-corrected visual acuity (BCVA) was estimated using the Snellen chart. For the present study, 20/20 (normal vision) was expressed as 1.0 and 0/20 as 0.0.

As another effectiveness outcome, flares before and after CZP initiation were compared.

Statistical analysis

Variables were tested for normality by the Kolmogorov-Smirnov test. Results were expressed as mean \pm SD for variables with a normal distribution, or as median and IQR (25th, 75th) for those not normally distributed. Paired sample T-test or Wilcoxon signed-rank test were used to compare continuous variables over different time points. The following variables were assessed and compared between baseline and first week, first month, third month, sixth month, first year and second year: BCVA, anterior chamber cells, vitritis, retinal vasculitis, macular

thickness (OCT) and glucocorticoid-sparing effect. The incidence of uveitis flares was reported as the incidence rate (IR) per 100 patients-year in both groups (before and after CZP onset) and incidence rate ratio (IRR), with their Poisson 95% CI. Analyses were performed using IBM SPSS software V.28 (IBM, Armonk, New York, USA). Statistical significance was considered as a *p* value <0.05 in all the calculations.

RESULTS

Baseline features of the study sample

Eighty Caucasian patients (111 affected eyes) with refractory uveitis to conventional treatment who received CZP as a therapeutic alternative agent were included in the study. The mean age at CZP initiation was 41.6±11.7 years and 58.8% were women. In 20 patients, in addition to the presence of refractory uveitis, the desire for pregnancy was the reason for CZP initiation. The underlying diseases were: SpA (n=43), BD (n=10), psoriatic arthritis (n=8), CD (n=4), sarcoidosis (n=2), JIA (n=1), reactive arthritis (n=1), rheumatoid arthritis (n=1), relapsing polychondritis (n=1), TINU (n=1), pars planitis (n=1), birdshot (n=1) and idiopathic uveitis (n=6). Anterior uveitis was the most frequent ocular pattern (n=61). The main demographic and clinical data of the whole series are summarised in [table 1](#).

Previous immunosuppressive therapy before CZP initiation

Besides oral glucocorticoids (mean prednisone dose; 13.9±11.6 mg/day) and before the initiation of biological therapy, patients had received the following conventional immunosuppressive agents: MTX (n=38), SSZ (n=28), AZA (n=14), CsA (n=10), LFN (n=3), MMF (n=4) and CFM (n=1). MP intravenous pulses were administered to four patients due to the severity of ocular impairment. Moreover, 52 subjects (63%) were on previous biological therapy with a median of 2¹⁻³ drugs per patient. The most frequent biological drug used was ADA (n=48), followed by IFX (n=32), GOL (n=15), etanercept (n=7), tocilizumab (n=5), rituximab (n=1), anakinra (n=1) and secukinumab (n=1) ([figure 1](#)).

Certolizumab therapy: effectiveness

CZP was initiated as monotherapy in 39 patients and combined with another conventional immunosuppressive agent in the remaining 41, as follows: MTX (n=23), AZA (n=9), SSZ (n=7), CsA (n=1) and HCQ (n=1) ([table 2](#)). In 28 patients, CZP was administered as the first biological agent.

The main outcome variables assessed in the study (intraocular inflammation, macular thickness, BCVA) showed a rapid and maintained improvement from the first week and throughout the follow-up ([figure 2](#)).

The mean BCVA increased from a mean value of 0.64±0.27 before the initiation of biological therapy to 0.88±0.21 in the second year (*p*<0.001) ([figure 2A](#)). Similarly, all patients experienced an improvement in the parameters of ocular inflammation. The percentage of

Table 1 Main general features of a series of 80 patients with refractory uveitis due to immune-mediated inflammatory diseases (IMID) treated with certolizumab pegol (CZP)

No. of patients/eyes affected, n/n	80/111
Age, mean (SD), years	41.6±11.7
Sex, male/female, n/n (%)	33/47 (41.2/58.8)
Time between IMID diagnosis and CZP initiation, median (IQR)	72 (35–144)
Patients initiating CZP due to pregnancy, n (%)	20 (25)
Underlying IMID, n (%)	
Spondyloarthritis	43 (53.7)
Behçet's disease	10 (12.5)
Psoriatic arthritis	8 (10)
Crohn's disease	4 (5)
Sarcoidosis	2 (2.5)
Juvenile idiopathic arthritis	1 (1.3)
Reactive arthritis	1 (1.3)
Rheumatoid arthritis	1 (1.3)
Relapsing polychondritis	1 (1.3)
TINU	1 (1.3)
Pars planitis	1 (1.3)
Birdshot choroidopathy	1 (1.3)
Idiopathic uveitis	6 (7.5)
Ocular parameters at CZP initiation	
AC cells count, median (IQR)	1 [1.0–1.75]
Patients who present vitritis, n (%)	14 (17.5)
BCVA, mean (SD)	0.68±0.27
OCT, mean (SD)	297.48±48.19
Patients who present retinal vasculitis, n (%)	3 (3.8)
Uveitis pattern, n (%)	
Bilateral/Unilateral	31/49 (38.7/61.3)
Anterior	61 (76.3)
Intermediate	4 (5.0)
Posterior	7 (8.8)
Panuveitis	7 (8.8)
BCVA, best-corrected visual acuity; OCT, optical coherence tomography.	

eyes with an improvement of AC cell count according to SUN criteria and vitritis was increased to 100% in both cases in the second year. Concerning the three patients who had retinal vasculitis at the beginning of the study, a rapid and sustained improvement was observed, with no new episodes at the end of the study. Furthermore, of the three patients who had choroiditis at CZP initiation, only one was active at the end of the follow-up. Furthermore, we observed a significant decrease in macular thickness

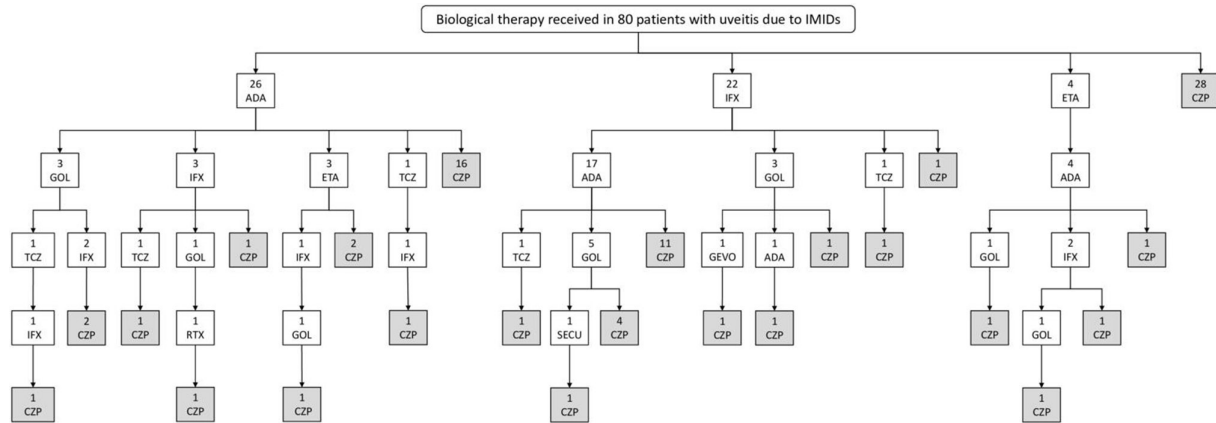


Figure 1 Flow chart of the biological treatments received in the 80 patients with refractory uveitis in different immune-mediated inflammatory diseases (IMID). ADA, adalimumab; CZP, certolizumab pegol; ETA, etanercept; GOL, golimumab; GEVO, gevokizumab; IFX, infliximab; IMID, immune-mediated inflammatory; RTX, rituximab; SECU, secukinumab; TCZ, tocilizumab.

measured by OCT from $297.5 \pm 48.1 \mu\text{m}$ at baseline to $266.1 \pm 36.2 \mu\text{m}$ in the second year ($p < 0.001$) (figure 2B).

As another effectiveness parameter, number of flares 2 years before and after CZP initiation were recorded and compared. The IR of flares before CZP was 1.23 (95% CI 1.06 to 1.42) per 100 patients-year and 0.34 (95% CI 0.25 to 0.44) per 100 patients-year after CZP initiation. The IR difference was 0.89 (95% CI 0.70 to 1.09) ($p < 0.0001$). The IRR was 3.64 (95% CI 2.67 to 5.04) ($p < 0.0001$).

We also found a rapid decrease in the median glucocorticoid dose from the start of CZP (10 (5–27.5) mg/day) to the end of the follow-up (3.1 (0–8.7) mg/day ($p < 0.001$) (figure 2C).

Certolizumab therapy: follow-up data and safety profile

After a median follow-up of 24^{12–36} months, 95% of patients achieved ocular remission. CZP was discontinued in 16 (20%) patients due to maintained remission ($n=3$), insufficient ocular response ($n=4$) and incomplete response of extraocular manifestations ($n=9$). In this latter group, six patients had recurrent episodes of peripheral arthritis (psoriatic arthritis ($n=2$), SpA ($n=2$), reactive arthritis ($n=1$) and relapsing polychondritis ($n=1$)), two patients were diagnosed with CD with recurrent episodes of intestinal ulcers and one patient with sarcoidosis due to persistence of skin lesions (panniculitis).

Of the 76 patients who maintained ocular remission, optimisation of treatment was performed in 12 of them by increasing the CZP administration interval to 200 mg every 4 weeks, with no reported worsening. No severe side effects were reported in any of the patients included in the study.

DISCUSSION

The optimal therapeutic scheme for NIU remains a challenge for rheumatologists and ophthalmologists. Despite the advances in biological therapies, current effectiveness data in this field only support the use of ADA in cases where conventional therapy is insufficient to control the disease (EMA and FDA approved).^{11 12} The use of other

anti-TNF- α drugs is based on observational studies with a low level of evidence, and usually, these agents are reserved for situations in which ADA is contraindicated or ineffective.

To the best of our knowledge, this multicentre study represents the largest series of multiple patients with IMID with refractory uveitis on CZP therapy in a real-world clinical setting. The main reason for prescribing CZP was poor control of ocular inflammation and in addition, in 20 patients, desire for pregnancy. CZP was effective in most cases, with a statistically significant rapid and maintained improvement of all ocular parameters during a 2-year follow-up. Moreover, we have observed a glucocorticoid-sparing effect, showing a significant decrease in the median oral prednisone dose from 10 mg/day at IFX initiation to 3 mg/day after 2 years of therapy. These results are in keeping with the scarcely available literature addressing the effectiveness of CZP in uveitis. In this regard, a Spanish observational study conducted by Llorenç *et al* reported complete remission of patients with chronic uveitis treated with CZP and prior failure to anti-TNF- α drugs.³¹ Similarly, Prieto-Peña *et al* described a series of 14 pregnant women with different IMIDs and uveitis treated with CZP with consistent effectiveness and safety data and no adverse fetal events.³²

We also studied, as an effectiveness end point, the mean number of flares before and after CZP initiation, and we observed a marked significant reduction of 75%. In this line, several studies support our data. Rudwaleit *et al* observed a three time-lower rate of uveitis flares in comparison with the placebo group in a series of SpA treated with CZP for 24 weeks.³³ Likewise, Tosi *et al* also reported a significant reduction of ocular flares in 11 patients with longstanding refractory uveitis treated with CZP.³⁴ Besides, a subanalysis of the multicentre phase IV C-VIEW study showed a reduction in the number of anterior uveitis flares in patients with SpA after 48 weeks of follow-up.²³ Subsequently, a 2-year extension study obtained similar consistent results.³⁵

Table 2 Treatment schedule and long-term follow-up of a series of 80 patients with refractory uveitis due to immune-mediated inflammatory diseases (IMID) treated with certolizumab pegol (CZP)

Conventional immunosuppressant before CZP initiation, n (%)	60 (75)
Ciclosporin	10 (12.5)
Azathioprine	14 (17.5)
Methotrexate	38 (47.5)
Salazopyrin	28 (35.0)
Cyclophosphamide	1 (1.3)
Mycophenolate	4 (5.0)
Leflunomide	3 (3.8)
Pulses of intravenous MP	4 (5.0)
Biological treatment before CZP initiation, n (%)	52 (63)
No. of biological drugs per patient, median (IQR)	2(1–3)
Adalimumab	48 (60)
Infliximab	32 (40)
Etanercept	7 (8.8)
Golimumab	15 (18.8)
Tocilizumab	5 (6.3)
Rituximab	1 (1.3)
Secukinumab	1 (1.3)
Gevokizumab	1 (1.3)
Mean dose of prednisone at CZP initiation (mg/day), mean±SD	16.9±10.8
CZP regimen	
Monotherapy/Combination, n (%)	39/41 (48.8/51.2)
Ciclosporin	1 (1.3)
Azathioprine	9 (11.3)
Methotrexate	23 (28.8)
Salazopyrine	7 (8.8)
Hydroxychloroquine	1 (1.3)
Follow-up time since CZP initiation (months), median (IQR)	24 (12–36)
Optimisation, n (%)	12 (15)
Reason for withdrawal, n (%)	16 (20)
Remission	3 (3.8)
Ocular inefficacy	4 (5)
Extraocular inefficacy	9 (11.3)
Side effects	0 (0.0)
MP, methylprednisolone.	

Up to 95% of the patients achieved ocular remission until the end of follow-up, and three patients were able to discontinue treatment without new ocular events. Once remission was achieved, CZP treatment was optimised in a not negligible percentage of patients, by increasing the

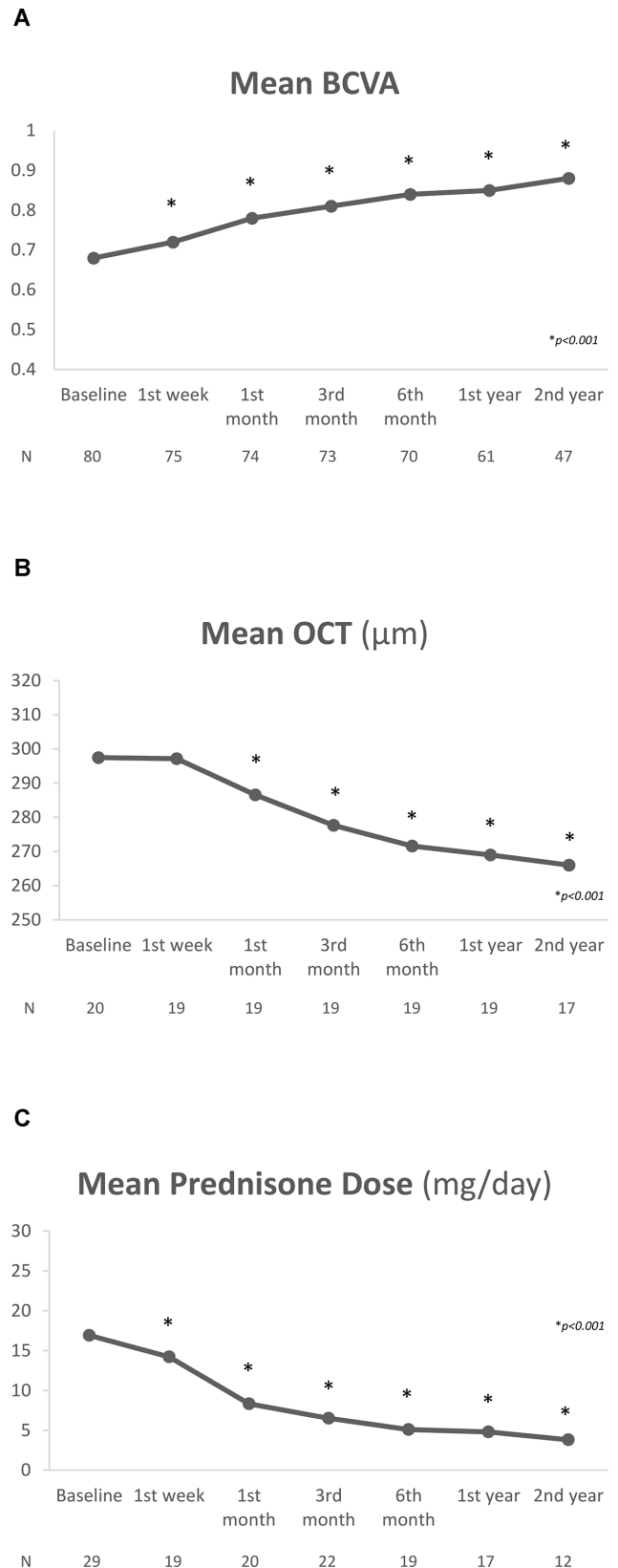


Figure 2 Rapid and maintained improvement following the initiation of certolizumab pegol (CZP). (A) Best-corrected visual acuity (BCVA); (B) macular thickness (optical coherence tomography (OCT)) (data from patients with macular involvement); (C) glucocorticoid-sparing effect following CZP therapy (mg/day) (data from patients who received prednisone at any time during follow-up).

administration interval to 200 mg every 4 weeks, and no relapses occurred. These data are consistent with those found in optimisation studies involving other anti-TNF- α agents such as ADA or IFX.^{22–36}

However, four patients did not achieve adequate ocular control. Additionally, poor control of extraocular symptoms led to discontinuation of treatment in another nine patients.

Noteworthy, more than half of the patients (63%) had received biological treatment before CZP initiation, with a median of 2^{1–3} drugs per patient. This reflects the severity of the different diseases and their refractoriness to multiple therapies. In addition, it is important to emphasise that all of them had received at least one anti-TNF- α as a first-line agent or subsequently. In patients with rheumatoid arthritis, it has been postulated that in the case of a failure of the anti-TNF- α drug failure, the most useful strategy is switching to another therapeutic target.³⁷ Nevertheless, it seems that in patients with uveitis it may be feasible to use other drugs of the same family as shown in our study.

Concerning CZP safety, no serious, or moderate or mild adverse events were reported in our series. However, in the subanalysis of the C-VIEW study, five patients reported serious adverse effects such as vestibular disorder, sarcoidosis or prostate cancer.^{23–35} Similarly, and in agreement with previous studies, no pregnancy complications or congenital malformations attributable to CZP were reported.^{38–40}

Our study has several limitations mainly inherent to its observational nature, the lack of a control group, the relatively low number of optimised patients and the heterogeneity of the underlying IMID with different uveitis patterns. For these reasons, further randomised controlled trials comparing conventional immunosuppressive drugs and other anti-TNF- α agents are required. Nevertheless, it is very difficult to perform studies on refractory uveitis with large populations, especially since the development and approval of biosimilar drugs. Therefore, future valuable information will probably come from observational multicentre studies, such as ours.

In conclusion, our results suggest that CZP seems to be effective and safe, in the short-term and long-term, in Caucasian patients with IMID with refractory uveitis.

Author affiliations

¹Rheumatology, Hospital Comarcal de Laredo, Laredo, Spain

²Rheumatology, Hospital Universitario Marqués de Valdecilla, IDIVAL, Santander, Spain

³Ophthalmology, Hospital Clinic de Barcelona, Barcelona, Spain

⁴Rheumatology, University Hospital Complex Badajoz, Badajoz, Spain

⁵Rheumatology, Hospital del Mar, Barcelona, Spain

⁶Rheumatology, Joan XXIII University Hospital in Tarragona, Tarragona, Spain

⁷Internal Medicine, Complejo Hospitalario de Navarra, Pamplona, Spain

⁸Rheumatology, Hospital Universitario del Tajo, Aranjuez, Spain

⁹Rheumatology, Hospital de Basurto, Basurto, Spain

¹⁰Ophthalmology, Complejo Asistencial Universitario de Leon, Leon, Spain

¹¹Department of Rheumatology, Araba University Hospital, Vitoria-Gasteiz, Spain

¹²Rheumatology, Hospital Universitario de Toledo, Toledo, Spain

¹³Ophthalmology, General University Hospital Consortium of Valencia, Valencia, Spain

¹⁴Rheumatology, University Hospital Lucus Augusti, Lugo, Spain

¹⁵Rheumatology, Complejo Asistencial de Palencia, Palencia, Spain

¹⁶Rheumatology, Hospital of Donostia, San Sebastian, Spain

¹⁷Rheumatology, Hospital Universitario de Mostoles, Mostoles, Spain

¹⁸Rheumatology, Hospital Virgen de Valme, Sevilla, Spain

¹⁹Rheumatology, Hospital Can Misses, Eivissa, Illes Balears, Spain

²⁰Rheumatology, Hospital de Merida, Merida, Spain

²¹Rheumatology, Hospital General Universitario de Castello, Castellon de la Plana, Spain

²²Rheumatology, Hospital Universitario San Juan de Alicante, Sant Joan d'Alacant, Spain

²³Rheumatology, Hospital General Universitario de Alicante, Alicante, Spain

²⁴Ophthalmology, Hospital General Universitario de Alicante, Alicante, Spain

²⁵Rheumatology, Hospital Universitario de Salamanca, Salamanca, Spain

²⁶Rheumatology, Hospital de la Santa Creu i Sant Pau, Barcelona, Spain

²⁷Rheumatology, Complejo Hospitalario Universitario de Pontevedra, Pontevedra, Spain

²⁸Rheumatology, Fundació Hospital de l'Esperit Sant, Barcelona, Spain

²⁹Pediatric, Hospital Universitario 12 de Octubre, Madrid, Spain

³⁰Rheumatology, Hospital de Sagunto, Sagunto, Spain

³¹Ophthalmology, Hospital Universitario Marqués de Valdecilla, IDIVAL, Santander, Spain

³²Internal Medicine, Hospital Universitario Marqués de Valdecilla, IDIVAL, Santander, Spain

³³Medicine and Psychiatry Department, Universidad de Cantabria, Santander, Spain

Contributors JLM-V: conception or design of the work; data collection; data analysis and interpretation; drafting the article; critical revision of the article; final approval of the version to be published. LS-B: conception or design of the work; data collection; data analysis and interpretation; drafting the article; critical revision of the article. VC-R: conception or design of the work; data analysis and interpretation; drafting the article. AA, AG-F, EB-C, SC-O, PF, AGM, IT, MC-C, JRDD, AG-A, MH-G, AS-A, AG-V, OM, RM, SR-M, AU, RV, AC, CF-C, VJ, JJM, OMG, PMA, SR-Y, PR-M, EP-S-P, MG-B, RD-P: conception or design of the work; data collection; drafting the article. JLM-V: conception or design of the work; data analysis and interpretation; statistical analysis; drafting the article; critical revision of the article; final approval of the version to be published. RB: conception or design of the work; data analysis and interpretation; drafting the article; critical revision of the article; final approval of the version to be published.

Funding This work was also partially supported by RETICS Programmes, RD08/0075 (RIER) and RD12/0009/0013 from 'Instituto de Salud Carlos III' (ISCIII) (Spain).

Competing interests JLM-V received grants/research support from AbbVie, Pfizer, Lilly, Celgene, Janssen, and UCB Pharma. VC-R received grants/research support from MSD and Roche and had consultation fees/participation in the company-sponsored speaker's bureau from AbbVie, Lilly, Celgene, Grünenthal and UCB Pharma. LS-B received grants/research support from Roche, Lilly and Pfizer. EB-C had consultation fees/participation in the company-sponsored speaker's bureau from AbbVie, Amgen, Janssen, MSD, Pfizer, Lilly, Novartis y UCB. PF received grants/research supports from Sobi and Novartis and had consultation fees/participation in the company-sponsored speaker's bureau from Sobi and Novartis. AGM received consultation fees from Novartis and Amgen and sponsored speaker's bureau from Novartis, Jansen, Amgen, UCB and Grünenthal. MC-C was a lecturer for AbbVie, Merck Sharp & Dohme, Allergan and UCB. He also participated in Advisory Boards of AbbVie and Allergan. He also had travel grants from AbbVie, UCB and Allergan. RV had consultation fees/participation in the company-sponsored speaker's bureau from AbbVie, Pfizer, MSD, UCB, Gebro, Celgene, Janssen, Bristol Myers, Lilly, Galápagos, Amgen. CF-C received honoraria for lectures/presentations from AbbVie, Galapagos, Janssen, Lilly, MSD, Novartis, Pfizer and UCB; consulting fees from AbbVie, Janssen, Lilly, Novartis and UCB and support for attending meetings from AbbVie, Galapagos, Janssen, Lilly, Novartis, Roche and UCB. JLH received grants/research support from Amgen and participation in company-sponsored speaker's bureau from Amgen, MSD and Novartis. RB received grants/research support from AbbVie, MSD and Roche, and had consultation fees/participation in a company-sponsored speaker's bureau from AbbVie, Pfizer, Roche, Bristol Myers, Janssen and MSD.

Patient consent for publication Not applicable.

Ethics approval This study was approved by Ethics Committee: CEIm Cantabria (reference number: JLM-CER-2020-01). Participants gave informed consent to participate in the study before taking part.

Provenance and peer review Not commissioned; externally peer reviewed.

Data availability statement No data are available.

Open access This is an open access article distributed in accordance with the Creative Commons Attribution Non Commercial (CC BY-NC 4.0) license, which permits others to distribute, remix, adapt, build upon this work non-commercially, and license their derivative works on different terms, provided the original work is properly cited, appropriate credit is given, any changes made indicated, and the use is non-commercial. See: <http://creativecommons.org/licenses/by-nc/4.0/>.

ORCID iDs

José Luis Martín-Varillas <http://orcid.org/0000-0001-6147-6633>

Emma Beltran-Catalan <http://orcid.org/0000-0001-8070-6916>

Cristina Fernández-Carballido <http://orcid.org/0000-0002-0910-4944>

José L Hernández <http://orcid.org/0000-0002-6585-8847>

Ricardo Blanco <http://orcid.org/0000-0003-2344-2285>

REFERENCES

- Sakane T, Takeno M, Suzuki N, et al. Behçet's Disease. *N Engl J Med Overseas Ed* 1999;341:1284–91.
- Taylor SRJ, Singh J, Menezes V, et al. Behçet disease: visual prognosis and factors influencing the development of visual loss. *Am J Ophthalmol* 2011;152:1059–66.
- Tugal-Tutkun I, Onal S, Altan-Yaycioglu R, et al. Uveitis in Behçet disease: an analysis of 880 patients. *Am J Ophthalmol* 2004;138:373–80.
- Rothova A. Ocular involvement in sarcoidosis. *Br J Ophthalmol* 2000;84:110–6.
- Stolwijk C, van Tubergen A, Castillo-Ortiz JD, et al. Prevalence of extra-articular manifestations in patients with ankylosing spondylitis: a systematic review and meta-analysis. *Ann Rheum Dis* 2015;74:65–73.
- de Winter JJ, van Mens LJ, van der Heijde D, et al. Prevalence of peripheral and extra-articular disease in ankylosing spondylitis versus non-radiographic axial spondyloarthritis: a meta-analysis. *Arthritis Res Ther* 2016;18:196.
- Foster CS. Diagnosis and treatment of juvenile idiopathic arthritis-associated uveitis. *Curr Opin Ophthalmol* 2003;14:395–8.
- Heiligenhaus A, Niewerth M, Ganser G, et al. Prevalence and complications of uveitis in juvenile idiopathic arthritis in a population-based nation-wide study in Germany: suggested modification of the current screening guidelines. *Rheumatology* 2007;46:1015–9.
- Harbord M, Annese V, Vavricka SR, et al. The first European evidence-based consensus on extra-intestinal manifestations in inflammatory bowel disease. *J Crohns Colitis* 2016;10:239–54.
- Schwartzman S. Advancements in the management of uveitis. *Best Pract Res Clin Rheumatol* 2016;30:304–15.
- Jaffe GJ, Dick AD, Brézín AP, et al. Adalimumab in patients with active noninfectious uveitis. *N Engl J Med* 2016;375:932–43.
- Nguyen QD, Merrill PT, Jaffe GJ, et al. Adalimumab for prevention of uveitic flare in patients with inactive non-infectious uveitis controlled by corticosteroids (visual II): a multicentre, double-masked, randomised, placebo-controlled phase 3 trial. *The Lancet* 2016;388:1183–92.
- Suhler EB, Adán A, Brézín AP, et al. Safety and efficacy of adalimumab in patients with noninfectious uveitis in an ongoing open-label study: visual III. *Ophthalmology* 2018;125:1075–87.
- Ohno S, Umehayashi I, Matsukawa M, et al. Safety and efficacy of infliximab in the treatment of refractory uveoretinitis in Behçet's disease: a large-scale, long-term postmarketing surveillance in Japan. *Arthritis Res Ther* 2019;21:2.
- Ohno S, Nakamura S, Hori S, et al. Efficacy, safety, and pharmacokinetics of multiple administration of infliximab in Behçet's disease with refractory uveoretinitis. *J Rheumatol* 2004;31:1362–8.
- Calvo-Río V, Blanco R, Beltrán E, et al. Anti-TNF- α therapy in patients with refractory uveitis due to Behçet's disease: a 1-year follow-up study of 124 patients. *Rheumatology* 2014;53:2223–31.
- Santos-Gómez M, Calvo-Río V, Blanco R, et al. The effect of biologic therapy different from infliximab or adalimumab in patients with refractory uveitis due to Behçet's disease: results of a multicentre open-label study. *Clin Exp Rheumatol* 2016;34:S34–40.
- Tugal-Tutkun I, Mudun A, Urgancioglu M, et al. Efficacy of infliximab in the treatment of uveitis that is resistant to treatment with the combination of azathioprine, cyclosporine, and corticosteroids in Behçet's disease: an open-label trial. *Arthritis Rheum* 2005;52:2478–84.
- Niccoli L, Nannini C, Benucci M, et al. Long-Term efficacy of infliximab in refractory posterior uveitis of Behçet's disease: a 24-month follow-up study. *Rheumatology* 2007;46:1161–4.
- Bou R, Adán A, Borrás F, et al. Clinical management algorithm of uveitis associated with juvenile idiopathic arthritis: interdisciplinary panel consensus. *Rheumatol Int* 2015;35:777–85.
- Riancho-Zarrabeitia L, Calvo-Río V, Blanco R, et al. Anti-TNF- α therapy in refractory uveitis associated with sarcoidosis: Multicenter study of 17 patients. *Semin Arthritis Rheum* 2015;45:361–8.
- Martín-Varillas JL, Atienza-Mateo B, Calvo-Río V, et al. Long-Term follow-up and optimization of infliximab in refractory uveitis due to Behçet disease: national study of 103 white patients. *J Rheumatol* 2021;48:741–50.
- van der Horst-Bruinsma I, van Bentum R, Verbraak FD, et al. The impact of certolizumab pegol treatment on the incidence of anterior uveitis flares in patients with axial spondyloarthritis: 48-week interim results from C-VIEW. *RMD Open* 2020;6:e001161.
- Lopalco G, Emmi G, Gentileschi S, et al. Certolizumab Pegol treatment in Behçet's disease with different organ involvement: A multicenter retrospective observational study. *Modern Rheumatology* 2017;27:1031–5.
- Palmou-Fontana N, Calvo-Río V, Martín-Varillas JL, et al. Golimumab in refractory uveitis associated to juvenile idiopathic arthritis: multicentre study of 7 cases and literature review. *Clin Exp Rheumatol* 2018;36:652–7.
- Pasut G. Pegylation of biological molecules and potential benefits: pharmacological properties of certolizumab pegol. *BioDrugs* 2014;28:15–23.
- Porter C, Armstrong-Fisher S, Kopotsha T, et al. Certolizumab pegol does not bind the neonatal Fc receptor (FcRn): consequences for FcRn-mediated in vitro transcytosis and ex vivo human placental transfer. *J Reprod Immunol* 2016;116:7–12.
- Jabs DA, Nussenblatt RB, Rosenbaum JT, et al. Standardization of uveitis Nomenclature for reporting clinical data. Results of the first International workshop. *Am J Ophthalmol* 2005;140:509–16.
- Nussenblatt RB, Palestine AG, Chan C-C, et al. Standardization of vitreal inflammatory activity in intermediate and posterior uveitis. *Ophthalmology* 1985;92:467–71.
- Tugal-Tutkun I, Onal S, Altan-Yaycioglu R, et al. Uveitis in Behçet disease: an analysis of 880 patients. *Am J Ophthalmol* 2004;138:373–80.
- Llorenç V, Mesquida M, Sainz de la Maza M, et al. Certolizumab pegol, a new anti-TNF- α in the armamentarium against ocular inflammation. *Ocul Immunol Inflamm* 2016;24:167–72.
- Prieto-Peña D, Calderón-Goercke M, Adán A, et al. Efficacy and safety of certolizumab pegol in pregnant women with uveitis: recommendations on the management with immunosuppressive and biologic therapies in uveitis during pregnancy. *Clin Exp Rheumatol* 2021;39:105–14.
- Rudwaleit M, Rosenbaum JT, Landewé R, et al. Observed incidence of uveitis following Certolizumab pegol treatment in patients with axial spondyloarthritis. *Arthritis Care Res* 2016;68:838–44.
- Tosi GM, Sota J, Vitale A, et al. Efficacy and safety of certolizumab pegol and golimumab in the treatment of non-infectious uveitis. *Clin Exp Rheumatol* 2019;37:680–3.
- van der Horst-Bruinsma IE, van Bentum RE, Verbraak FD, et al. Reduction of anterior uveitis flares in patients with axial spondyloarthritis on certolizumab pegol treatment: final 2-year results from the multicenter phase IV C-VIEW study. *Ther Adv Musculoskelet Dis* 2021;13:1759720X211003803.
- Martín-Varillas JL, Calvo-Río V, Beltrán E, et al. Successful optimization of adalimumab therapy in refractory uveitis due to Behçet's disease. *Ophthalmology* 2018;125:1444–51.
- Gottenberg J-E, Brocq O, Perdriger A, et al. Non-TNF-Targeted biologic vs a second anti-TNF drug to treat rheumatoid arthritis in patients with insufficient response to a first anti-TNF drug: a randomized clinical trial. *JAMA* 2016;316:1172–80.
- Uma M. Pregnancy concerns in women with inflammatory bowel disease. *Gastroenterol Hepatol* 2015;11:273–5.
- Clowse MEB, Scheuerle AE, Chambers C, et al. Pregnancy outcomes after exposure to Certolizumab pegol: updated results from a pharmacovigilance safety database. *Arthritis Rheumatol* 2018;70:1399–407.
- Kiely PDW. Biologic efficacy optimization—a step towards personalized medicine. *Rheumatology* 2016;55:780–8.