

# DISTRIBUTION OF A MAJOR CONNECTIVE TISSUE PROTEIN, FIBRONECTIN, IN NORMAL HUMAN TISSUES\*

BY SVANTE STENMAN AND ANTTI VAHERI

(From the Departments of Pathology and Virology, University of Helsinki, Helsinki 29, Finland)

Fibronectin (1) is a polymorphic glycoprotein found in blood and tissues of vertebrates (2) and in cultures of adherent fibroblastic (3) and astroglial (4) cells. The circulating form of this glycoprotein was described nearly 30 years ago as "cold-insoluble globulin" which co-precipitates with fibrinogen in the cold (5). The concentration in normal human plasma is about 300  $\mu\text{g/ml}$  (6). Fibronectin is a major protein in cultures of fibroblastic cells (3) from various species, and has also been known as LETS protein or CSP (7-11). Fibronectin of cultured human fibroblasts and that of human plasma are immunologically identical and have the same mobility in immunoelectrophoresis (3, 12). Both are dimers of disulfide-bonded 200,000-220,000 mol wt polypeptides (13-15).

The biological role of fibronectin is poorly understood. The protein has been studied mostly in cell culture conditions, where it seems to be involved in cell adhesion (16-18). In chicken and mouse embryos, fibronectin is found in basement membranes and in the extracellular connective tissue matrix (19, 20). In the present work, immunofluorescence has been used to demonstrate fibronectin in normal human adult tissues.

## Materials and Methods

*Anti-Fibronectin Serum.* Antiserum to human plasma fibronectin (cold-insoluble globulin) was raised in rabbits. The purity of the antigen used for immunization was controlled with sodium dodecyl sulphate-polyacrylamide gel electrophoresis, in which a single polypeptide band was detected. Immunofluorescence obtained in indirect staining was completely blocked by preincubation of the antiserum with purified plasma fibronectin. The anti-fibronectin serum gave a single precipitation line against normal human plasma, against extract of human fibroblasts, and against the purified antigen in immunodiffusion analysis (17), and it gave a single polypeptide band in immunoprecipitation with radiolabeled fibroblast extracts (16), as was documented previously.

*Histologic Techniques.* All tissue specimens were obtained as fresh surgical biopsy samples. For immunofluorescence staining, we used frozen sections fixed in acetone ( $-20^{\circ}\text{C}$ , 20 min) or paraffin-embedded ( $56^{\circ}\text{C}$ , the method described in ref. 21) sections fixed in alcohol.

Conventional histological techniques (22) were used to demonstrate collagen (Van Gieson's stain), elastin (Weigert's resorcin-fuchsin elastic stain) and reticulin (Gomori's reticulin stain). Sections previously stained for immunofluorescence were fixed in 3.5% formaldehyde before histologic staining.

*Immunofluorescence Staining.* Fixed sections were washed twice for 10 min in phosphate-buffered saline (PBS),<sup>1</sup> and treated for 30 min at room temperature with rabbit anti-fibronectin

\* Supported by grant CA 17373 of the National Cancer Institute, and by grants from the Sigrid Jusélius Foundation and the President J. K. Paasikivi Foundation, Helsinki, Finland.

<sup>1</sup> Abbreviations used in this paper: PBS, phosphate-buffered saline; FITC, fluorescein isothiocyanate.

serum diluted 1:40 in PBS. The PBS washes were repeated, and fluorescein isothiocyanate (FITC)-conjugated sheep anti-rabbit gamma globulin (Wellcome Research Laboratories, Beckenham, England) diluted 1:40 in PBS was soaked on the sections for 30 min at room temperature. After two 10-min washes with PBS, the preparation was mounted using a solution containing equal volumes of glycerol and Veronal-buffered (50 mM, pH 8.6) sodium chloride (100 mM).

In control experiments, the anti-fibronectin rabbit serum was substituted either with normal rabbit serum, with anti-fibronectin serum pretreated with purified plasma fibronectin (50  $\mu\text{g/ml}$ ), or with PBS.

*Fluorescence Microscopy.* Stained sections were examined with a Zeiss Universal microscope equipped with the epi-illuminator III RS (Carl Zeiss, Oberkochen, West Germany) and an HBO 200 W high pressure mercury lamp. The filters used for specific FITC fluorescence were excitation filters BP 455-490, dichroic mirror FT 510, and barrier filters LP 520. All sections were tested for autofluorescence by using the intense green emission light (545 nm) of the mercury lamp for fluorescence excitation with excitation filter BP 546/10, dichroic mirror FT 580, and barrier filter LP 590. Autofluorescence was then intensely red and could be distinguished from the green FITC fluorescence which was detected with a blue emission light. Only those specimens without autofluorescence were studied, except for detection of autofluorescing elastic laminae in arteries (e.g. Fig. 4b).

Photographs were made on Agfapan 400 Professional film developed in Atomal FF (Agfa-Gaevent, Leverkusen, West Germany) to normal contrast at a sensitivity of 26 DIN.

## Results

*General Findings.* Fibronectin was ubiquitously present in all studied tissues. It was especially abundant in basement membranes, around smooth muscle cells and striated muscle fibers, in the connective tissue stroma of lymph nodes and the spleen, and in sinusoidal walls of the liver. The fluorescence was specific, as control-stained sections were negative (see Materials and Methods), and autofluorescence was absent or very weak.

In all sites, the distribution of fibronectin corresponded to histologically demonstrated reticulin (Fig. 1), but not to collagen or elastic fibers. In several sites, however, reticulin and collagen were present in the same structures. By sequentially using polarization and fluorescence microscopy, it could be demonstrated that birefringent collagen bundles and fluorescing fibronectin fibers were separate structures, e.g. in the spleen trabeculae and capsule and dermis. The collagen bundles and fibronectin fibers were often situated close together.

*Lymphatic Tissues.* The spleen (Fig. 2) contained fibronectin in a dense network which branched throughout the tissue. The network was sparse or absent in germinal centers. Thin fibers of fibronectin were packed between collagen bundles in the capsule and trabeculae. In the lymph nodes (Fig. 3), a similar but more sparse network was seen. Little or no fibronectin was detected in the germinal centers. Sinusoidal walls and the capsule contained a dense, continuous fibronectin stroma.

*Blood Vessels.* All blood vessels, including capillaries, contained a zone of fibronectin corresponding to the basement membrane of the endothelium (Fig. 4). The internal elastic lamina, which contains elastic fibers (in many specimens autofluorescing), was outside this zone and clearly separated from it (compare Figs. 4 a and b). Fibronectin was also present in the loose connective tissue of the adventitia. In muscular arteries (Fig. 4 a), fibronectin was further found around the smooth muscle cells of the media. In nonmuscular arteries (Fig. 4 c), the media contained thin strands of fibronectin.

*Muscle.* Striated muscle fibers contained fibronectin in the sarcolemma,

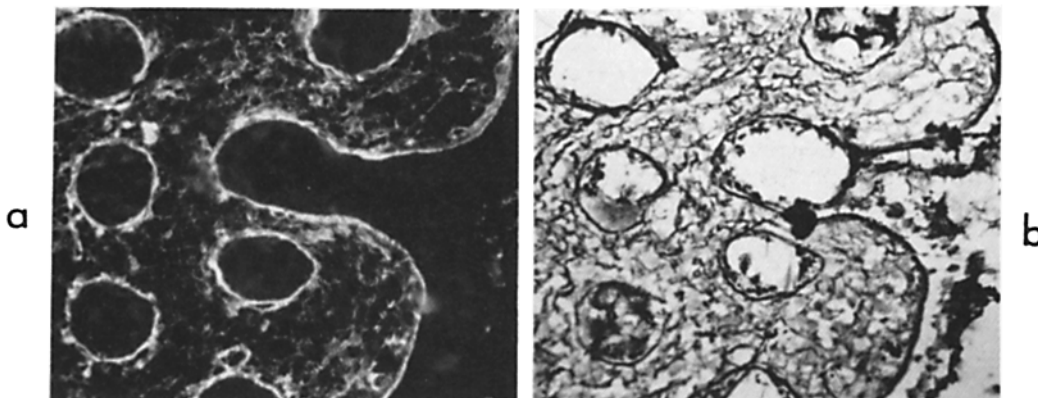


FIG. 1. Immunofluorescence staining for fibronectin (a) and histological staining for reticulin (b) of the same section of large intestine mucosa. Fibronectin is seen in basement membranes and in the loose connective tissue of the lamina propria.  $\times 400$ .

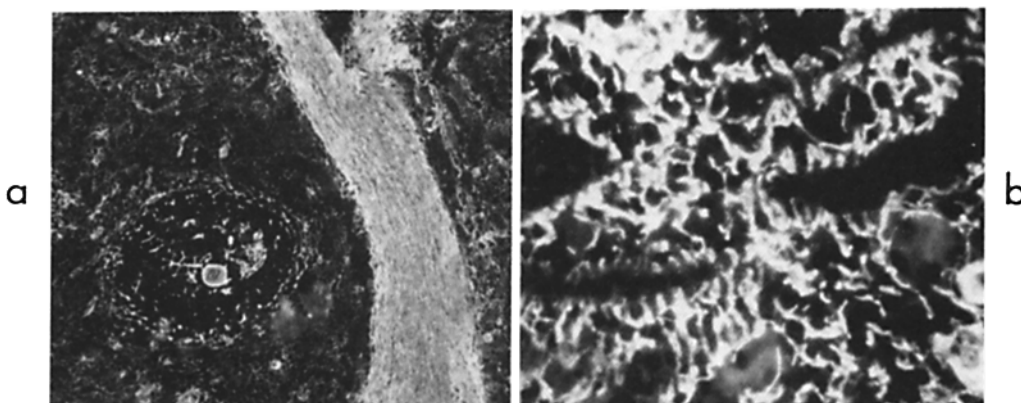


FIG. 2. Spleen. Fibronectin is abundant in trabeculae (a), and in the stroma a dense fibronectin-containing network is visible (b). (a),  $\times 65$ ; (b),  $\times 400$ .

where a continuous sheet was visualized (Fig. 5). In smooth muscle, fibronectin was present in the pericellular coating of individual cells (Fig. 6).

*Respiratory Tract.* In the trachea and bronchi, fibronectin was seen as a zone corresponding to the basement membrane beneath the epithelium. In the alveolar walls (Fig. 7), fibronectin was seen around the capillaries and at sites corresponding to the basement membrane of the alveolar epithelium.

*Glands.* The basement membranes in glands contained fibronectin. This was especially conspicuous in the thyroid gland (Fig. 8). In the mammary gland (Fig. 9), the fibronectin-specific fluorescence of the basement membranes was weaker. In the parathyroid gland (Fig. 10), little fibronectin was detected outside intensely staining blood vessels.

*Liver.* The sinusoids of the liver had a continuous thin zone of fibronectin probably located between the sinusoidal lining and liver cell plates (Fig. 11). No fibronectin was visualized between hepatocytes. In portal areas, fibronectin was present in the loose connective tissue and in blood vessels.

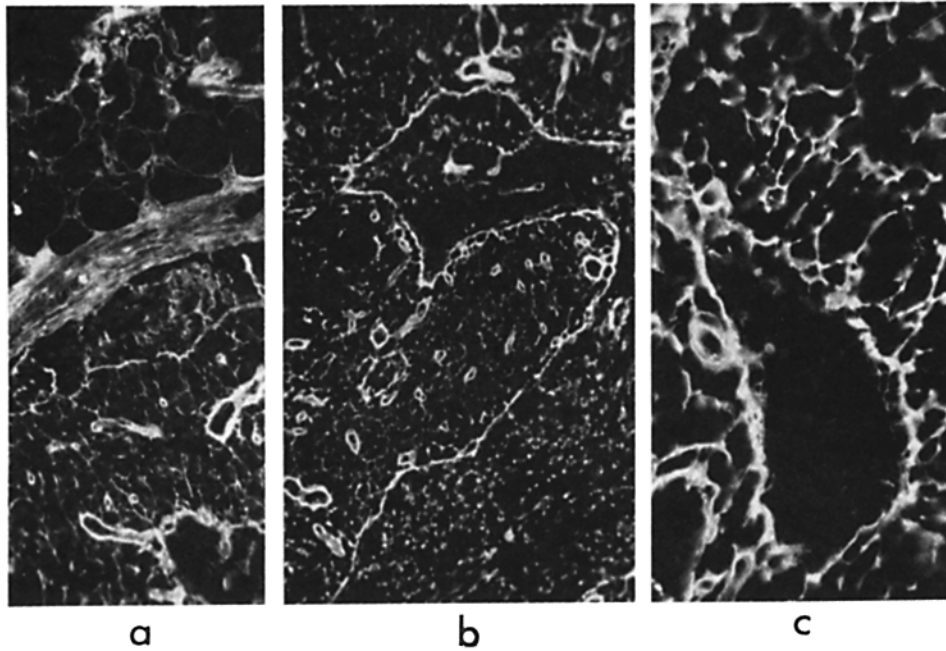


FIG. 3. Lymph node. (a) The capsule contains fibronectin and the surface of individual fat cells outside the capsule is also positive in immunofluorescence staining. In the stroma a loose fibronectin-containing network is observed. Fibronectin forms a continuous sheet in the surface of sinusoid walls (b) and capillaries (c). (a) and (b),  $\times 130$ ; (c),  $\times 320$ .

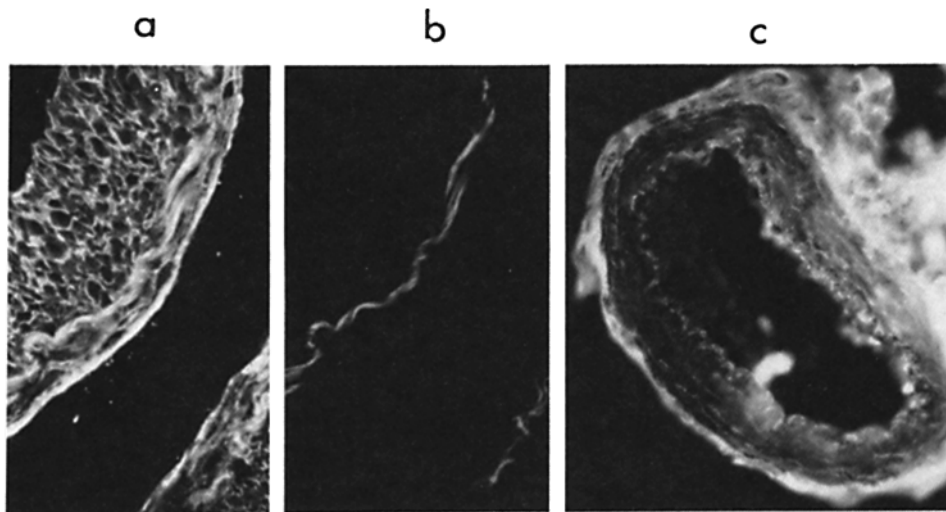


FIG. 4. Artery. (a) The basement membrane of the endothelium contains fibronectin, and individual muscle cells show fibronectin in the cellular coating. The internal elastic lamina was autofluorescent in this specimen. It is shown separately in (b) clearly separated from the endothelial basement membrane. In specimens without autofluorescence, the elastic lamina is not visualized and does not contain fibronectin. In nonmuscular arteries (c), the basement membrane contains fibronectin. Thin strands of fibronectin are also seen in the media and large amounts of fibronectin are visible in the adventitia.  $\times 320$ .

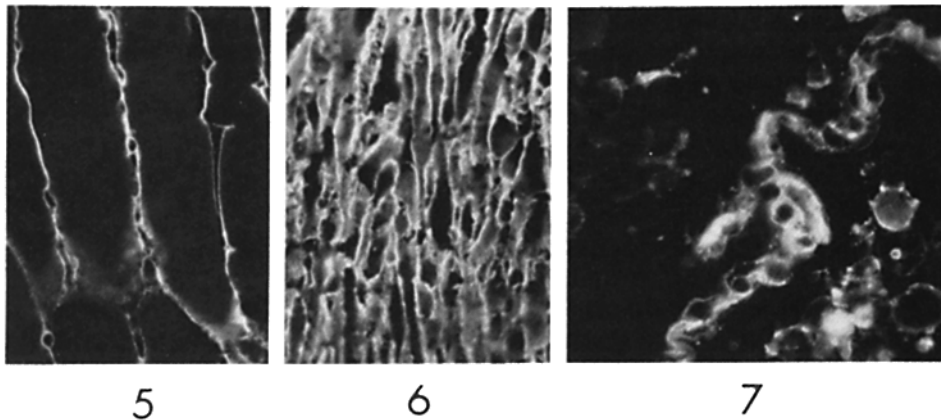


FIG. 5. Striated muscle. Fibronectin is located in the sarcolemma.  $\times 320$ .

FIG. 6. Smooth muscle of the large intestine. The pericellular coating is rich in fibronectin. Smooth muscle cells in other sites were similarly stained (see Fig. 4 a).  $\times 400$ .

FIG. 7. Lung. The alveolar basement membrane contains fibronectin.  $\times 400$ .

*Gastrointestinal Tract.* In the stomach (Fig. 12), fibronectin was distinctly distributed in the region of the basement membrane of the surface epithelium. In the muscular layer, fibronectin was present around the individual smooth muscle cells (Fig. 6). In the lamina propria, fibronectin occurred as thin strands of the loose connective tissue and in blood vessel walls as described above. The basement membrane of the mesothelium was rich in fibronectin. In the intestine (Fig. 1 a), fibronectin was distributed in the same manner as that in the stomach.

*Kidney and Urogenital Tract.* Glomeruli contained fibronectin in sites corresponding to the mesangial cells (Fig. 13). Fibronectin was also detected around the tubuli at sites probably corresponding to capillaries and the interstitial connective tissue (Fig. 14). In testis (Fig. 15) and epididymis (Fig. 16), basement membranes and loose connective tissue of the stroma contained fibronectin.

*Skin.* The dermal connective tissue contained thin strands of fibronectin (Fig. 17) intercalated with abundant collagen bundles. Some fibronectin was detected in the basement membrane of the epidermis.

*Connective Tissue.* Fibronectin was characteristically present in loose connective tissue around blood vessels (Fig. 4 c) and nerves and in the lamina propria of the gastrointestinal tract (Figs. 1 a and 12). In the connective tissue of the mammary gland only thin fibronectin strands occurred in the collagen-rich stroma, but around ducts and lobuli, fibronectin formed a sparse network (Fig. 9). A similar distribution of thin fibronectin fibers was observed in the collagen-rich dermis (Fig. 17). In the loose connective tissue of testis and epididymis, fibronectin was predominant (Figs. 15 and 16). In fat tissue (Fig. 3 a), fibronectin was seen on the surface of individual fat cells. In basement membranes, fibronectin was abundant, except in the skin and kidney.

### Discussion

This work shows that fibronectin is a major connective tissue protein in adult

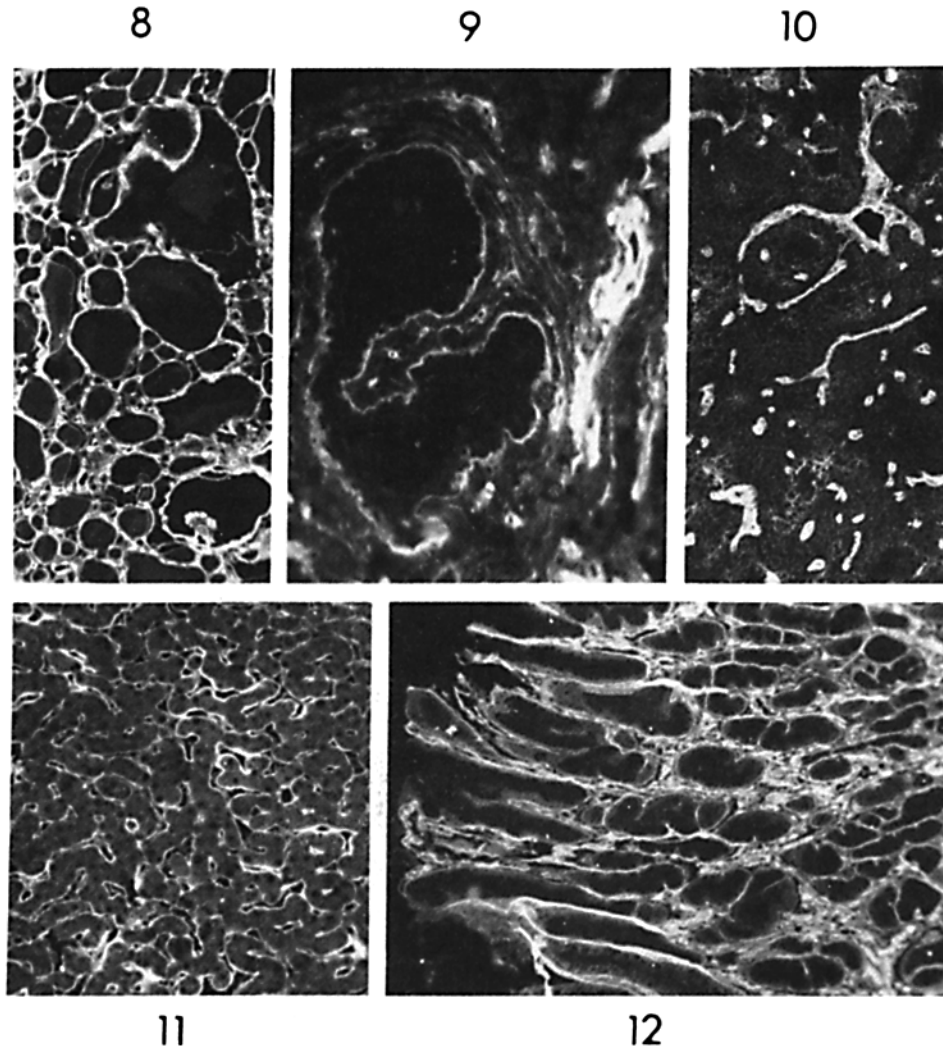


FIG. 8. Thyroid gland. Fibronectin appears in basement membranes.  $\times 50$ .

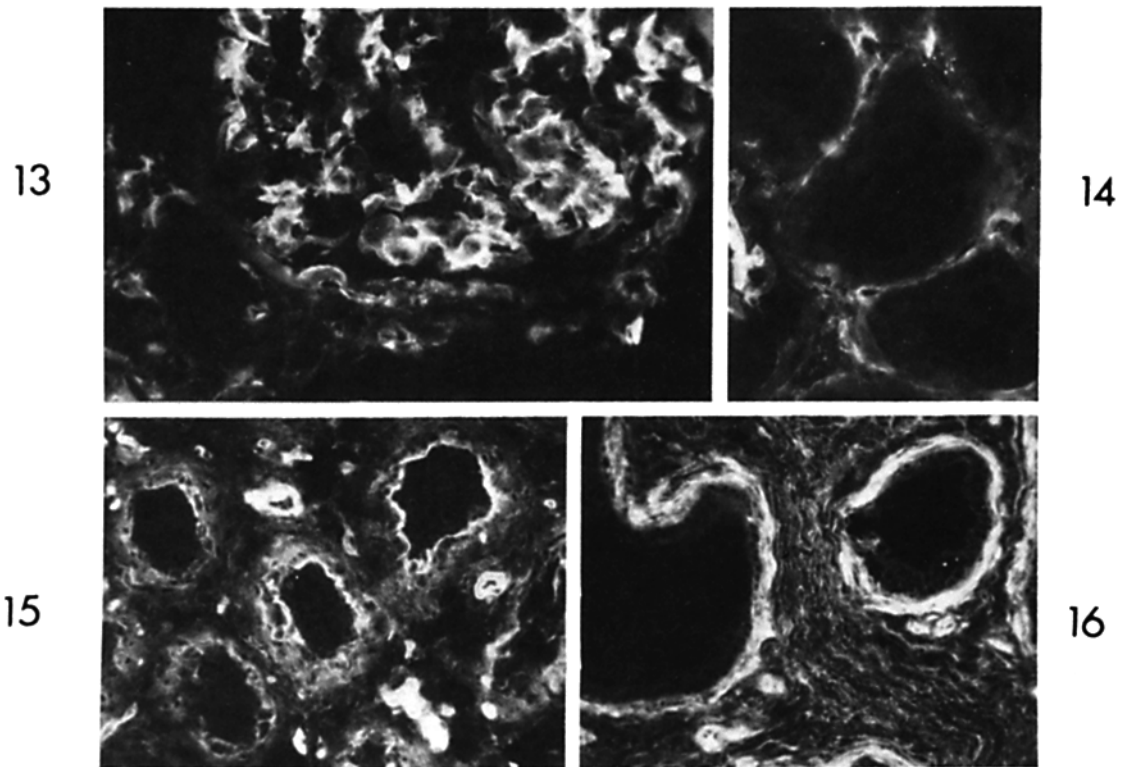
FIG. 9. Mammary gland. Fibronectin in basement membranes and in the connective tissue appears as thin strands. Large amounts of fibronectin are seen in the wall of a small vein to the right of the fig.  $\times 160$ .

FIG. 10. Parathyroid gland. Fibronectin is present in capillary walls only.  $\times 65$ .

FIG. 11. Liver. Fibronectin is located in the perivascular tissue of sinusoids.  $\times 130$ .

FIG. 12. Stomach. Fibronectin can be seen in basement membranes of the surface epithelium and in the loose connective tissue of the lamina propria. The basement membrane of the mesothelium also contained fibronectin (not shown).  $\times 50$ .

human tissues, typically occurring in most basement membranes, in the reticulin stroma of lymphatic tissues, and in loose connective tissue. In smooth and striated muscle cells, fibronectin is located in the pericellular coating of individual cells. In all these sites where fibronectin was detected by immunofluorescence, reticulin could be demonstrated with histological staining, but no co-distribution of fibronectin with collagen and elastic fibers was observed.

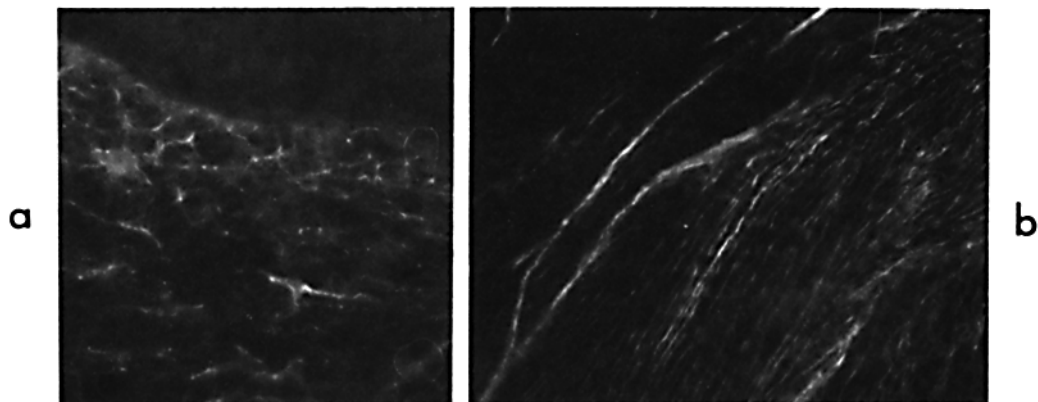


**FIG. 13.** Glomerulus of the kidney. Fibronectin is distributed in the mesangium but not in basement membranes.  $\times 400$ .

**FIG. 14.** Kidney tubuli. Fibronectin occurs in interstitial tissues and around capillaries, but not in basement membranes of tubuli.  $\times 400$ .

**FIG. 15.** Testis. Fibronectin is visible in basement membranes and in loose connective tissue stroma and blood vessel walls.  $\times 160$ .

**FIG. 16.** Epididymis. Fibronectin strands are seen in basement membranes and loose connective tissue.  $\times 160$ .



**FIG. 17.** Skin. (a) In the papillary connective tissue a fine network of fibronectin can be seen (bottom of fig.). The dermo-epidermal junction is weakly positive and epidermis negative (top of fig.). (b) In the deep dermal connective tissue, fibronectin is seen as thin strands between fluorescence-negative collagen bundles. (a),  $\times 400$ ; (b),  $\times 160$ .

Fibronectin is therefore one of the noncollagenous glycoproteins of connective tissue (23) and is obviously a component of reticulin, which is the descriptive name for fibers blackened by silver impregnation (22). Other proteins present in reticulin fibers include at least collagen type III (24) and some noncollagenous glycoproteins (25, 26). In mouse serum, a glycoprotein which chemically resembles fibronectin has been shown by immunohistological methods to cross-react with a protein present in reticulin fibers (27).

Most previous studies on the function of fibronectin have been done with cultivated fibroblasts, in which fibronectin is a major surface-associated glycoprotein. In fibroblast layers, fibronectin forms an extensive pericellular matrix which mediates cell-cell and cell-substratum contacts (3, 12). This matrix can be considered analogous to the fibronectin deposited in basement membranes. We therefore propose a structural role of fibronectin in positioning and anchoring cells *in vivo*. A similar function of fibronectin in cell adhesion *in vitro* has been proposed earlier (16-18).

The known biochemical interactions of fibronectin support the above hypothesis. Soluble fibronectin has a high affinity *in vitro* for collagenous proteins (28, 29), it interacts with the glycosaminoglycan heparin (30), and both soluble (11) and cell-associated (9) fibronectin are cross-linked to fibrinogen or fibrin by the action of plasma transglutaminase (activated blood coagulation factor XIII). In this way, fibronectin may *in vivo* form a structural link between the cell surface and collagenous proteins in the connective tissue matrix.

It is not clear whether the fibronectin of basement membranes is produced by connective tissue cells or by the adjacent epithelial cells. Data from *in vitro* experiments support both possibilities. First, fibroblasts produce *in vitro* a dense surface-associated matrix (3, 12). Second, undifferentiated cells from primitive mouse kidney mesenchyme produce *in vitro* a loose fibronectin network around individual mesenchymal cells. When this tissue is induced to differentiate into kidney tubuli, the fibronectin is confined to the basement membrane which is formed around tubuli (20). Similarly, when myoblasts fuse *in vitro* to form myotubes, fibrillar surface fibronectin is redistributed into a diffuse cell coating (31) analogous to that described here for muscle fibers. These data indicated that changes in fibronectin expression are closely linked with cell differentiation and organogenesis.

In cultures of fibroblastic (3) and astroglial (4) cells, fibronectin is detected intracellularly as a cell surface-associated matrix protein, and also secreted in large quantities into the culture medium. In the present *in vivo* study no intracellular fibronectin was detected, and no association between single connective tissue cells and fibronectin could be observed with certainty. The abundance of intracellular fibronectin and production of the protein into a pericellular matrix (16) *in vitro* may therefore be due to cell culture conditions allowing cell adhesion to a substratum and stimulation of cell proliferation.

Analogous situations *in vivo* would be chronic inflammation and formation of granulation tissue in wound healing, where fibroblasts characteristically proliferate. Our preliminary data from studies of such tissues show that, in fact, large amounts of fibronectin are detected in and around the proliferating fibroblasts. In such areas of wound healing, interaction of cellular or plasma (serum) (12) fibronectin with fibrin, collagen, and cell surfaces provides a link



between proliferating cells and the connective tissue matrix around the damaged area or the clot formed within it. Similarly, fibronectin could play a role in the orientation of regenerating epithelial cells which proliferate on basement membranes (32).

### Summary

Fibronectin is a major surface-associated glycoprotein of cultured fibroblasts and it is also present in human plasma. Antiserum specific for human fibronectin was used to study the distribution of fibronectin in normal adult human tissues. The protein was detected (a) characteristically in various basement membranes including capillary walls; (b) around individual smooth muscle cells and in the sarcolemma of striated muscle fibers; and (c) in the stroma of lymphatic tissue and as thin fibers in loose connective tissue. The distribution of fibronectin was distinct from that of collagen and elastic fibers, but was very similar to reticulin, as demonstrated by conventional histological staining. The results indicate that fibronectin is a major component of connective tissue matrix. The distribution also indicates that most types of adherent cells abut fibronectin-containing structures. This supports the possible role of fibronectin in cell-cell and cell-matrix interactions in tissues.

We thank Doctors Ewert Linder, Veli-Pekka Lehto, and Klaus Hedman for their critical evaluation of the manuscript, and Ms. Hannele Laaksonen, Ms. Ritva Nurme-Helminen, and Ms. Liisa Pitkänen for their technical assistance.

*Received for publication 5 December 1977.*

### References

1. Vaheri, A., E. Ruoslahti, E. Linder, J. Wartiovaara, J. Keski-Oja, P. Kuusela, and O. Saksela. 1976. Fibroblast surface antigen (SF): molecular properties, distribution in vitro and in vivo, and altered expression in transformed cells. *J. Supramol. Struct.* 4:63.
2. Kuusela, P., E. Ruoslahti, E. Engvall, and A. Vaheri. 1976. Immunological interspecies cross-reactions of fibroblast surface antigen (fibronectin). *Immunochemistry.* 13:639.
3. Ruoslahti, E., and A. Vaheri. 1974. Novel human serum protein from fibroblast plasma membrane. *Nature (Lond.)*. 248:789.
4. Vaheri, A., R. Ruoslahti, B. Westermarck, and J. Pontén. 1976. A common cell-type specific surface antigen in cultured human glial cells and fibroblasts: loss in malignant cells. *J. Exp. Med.* 143:64.
5. Morrison, P. R., J. T. Edsall, and S. G. Miller. 1948. Preparation and properties of serum and plasma proteins. XVIII. The separation of purified fibrinogen from fraction I of human plasma. *J. Am. Chem. Soc.* 70:3103.
6. Mosesson, M. W., and R. A. Umfleet. 1970. The cold insoluble globulin of human plasma. I. Purification, primary characterization and relationship to fibrinogen and other cold insoluble fraction components. *J. Biol. Chem.* 245:5728.
7. Gahmberg, C. G., and S. Hakomori. 1973. Altered growth behaviour of malignant cells associated with changes in externally labeled glycoprotein and glycolipid. *Proc. Natl. Acad. Sci. U. S. A.* 70:3329.
8. Hogg, N. M. 1974. A comparison of membrane proteins of normal and transformed cells by lactoperoxidase labeling. *Proc. Natl. Acad. Sci. U. S. A.* 71:489.

9. Hunt, R. C., E. Gold, and J. C. Brown. 1975. Cell cycle dependent exposure of a high molecular weight protein on the surface of mouse L cells. *Biochim. Biophys. Acta.* 413:453.
10. Hynes, R. O. 1973. Alteration of cell-surface proteins by viral transformation and by proteolysis. *Proc. Natl. Acad. Sci. U. S. A.* 70:3170.
11. Keski-Oja, J., D. F. Mosher, and A. Vaheri. 1976. Cross-linking of a major fibroblast surface-associated glycoprotein (fibronectin) catalyzed by blood coagulation factor XIII. *Cell.* 9:29.
12. Ruoslahti, E., A. Vaheri, P. Kuusela, and E. Linder. 1973. Fibroblast surface antigen: a new serum protein. *Biochim. Biophys. Acta.* 322:352.
13. Keski-Oja, J., D. F. Mosher, and A. Vaheri. 1976. Dimeric character of fibronectin, a major fibroblast surface-associated glycoprotein. *Biochem. Biophys. Res. Commun.* 74:699.
14. Mosesson, M. W., A. B. Chen, and R. M. Huseby. 1975. The cold-insoluble globulin of human plasma: studies of its essential structural features. *Biochim. Biophys. Acta.* 386:509.
15. Mosher, D. F. 1975. Cross-linking of cold-insoluble globulin by fibrin-stabilizing factor. *J. Biol. Chem.* 250:6614.
16. Hedman, K., A. Vaheri, and J. Wartiovaara. 1977. Cell surface protein, fibronectin, of human fibroblast cultures has a membrane-associated and a predominant pericellular matrix form. *J. Cell Biol.* 76:748.
17. Stenman, S., J. Wartiovaara, and A. Vaheri. 1977. Changes in the distribution of a major fibroblast protein, fibronectin, during mitosis and interphase. *J. Cell. Biol.* 74:453.
18. Yamada, K. M., S. S. Yamada, and I. Pastan. 1975. The major cell surface glycoprotein of chick embryo fibroblasts is an agglutinin. *Proc. Natl. Acad. Sci. U. S. A.* 72:3158.
19. Linder, E., A. Vaheri, E. Ruoslahti, and J. Wartiovaara. 1975. Distribution of fibroblast surface antigen in the developing chick embryo. *J. Exp. Med.* 142:41.
20. Wartiovaara, J., S. Stenman, and A. Vaheri. 1976. Changes in expression of fibroblast surface antigen (SFA) in induced cytodifferentiation and in heterokaryon formation. *Differentiation.* 5:85.
21. Sainte-Marie, G. 1962. A paraffin embedding technique for studies employing immunofluorescence. *J. Histochem. Cytochem.* 10:250.
22. Lillie, R. D., and H. M. Fullmer. 1976. *Histopathologic Technic and Practical Histochemistry.* McGraw-Hill Book & Educational Services Group, New York. 4th edition.
23. Anderson, J. C. 1976. Glycoproteins of the connective tissue matrix. *Int. Rev. Connect. Tissue Res.* 7:251.
24. Nowack, H., S. Gay, G. Wick, U. Becker, and R. Timpl. 1976. Preparation and use in immunohistology of antibodies specific for type I and type III collagen and procollagen. *J. Immunol. Methods.* 12:117.
25. Pras, M., and L. E. Glynn. 1973. Isolation of a non-collagenous reticulin component and its primary characterization. *Br. J. Exp. Pathol.* 54:449.
26. Pras, M., G. D. Johnson, E. J. Holborow, and L. E. Glynn. 1974. Antigenic properties of a non-collagenous reticulin component of normal connective tissue. *Immunology.* 27:469.
27. Tan, E. M., and M. H. Kaplan. 1963. Immunological relation of basement membrane and a serum beta globulin in the mouse. *Immunology.* 6:331.
28. Engvall, E., and E. Ruoslahti. 1977. Binding of soluble form of fibroblast surface protein, fibronectin, to collagen. *Int. J. Cancer.* 20:1.

29. Pearlstein, E. 1976. Plasma membrane glycoprotein which mediates adhesion of fibroblasts to collagen. *Nature (Lond.)*. 262:497.
30. Stathakis, N. E., and M. W. Mosesson. 1977. Interaction among heparin, cold-insoluble globulin, and fibrinogen in formation of the heparin-precipitable fraction of plasma. *J. Clin. Invest.* 60:855.
31. Chen, L. B. 1973. Alteration in cell surface LETS protein during myogenesis. *Cell*. 10:393.
32. Vracko, R. 1974. Basal lamina scaffold-anatomy and significance for maintenance of orderly tissue structure. *Am. J. Pathol.* 77:314.