



Since January 2020 Elsevier has created a COVID-19 resource centre with free information in English and Mandarin on the novel coronavirus COVID-19. The COVID-19 resource centre is hosted on Elsevier Connect, the company's public news and information website.

Elsevier hereby grants permission to make all its COVID-19-related research that is available on the COVID-19 resource centre - including this research content - immediately available in PubMed Central and other publicly funded repositories, such as the WHO COVID database with rights for unrestricted research re-use and analyses in any form or by any means with acknowledgement of the original source. These permissions are granted for free by Elsevier for as long as the COVID-19 resource centre remains active.



Cardiothoracic Imaging

Chest CT findings of coronavirus disease 2019 (COVID-19): A comprehensive meta-analysis of 9907 confirmed patients

Ahmadreza Zarifian^{a,b}, Mohammad Ghasemi Nour^b, Arash Akhavan Rezayat^b, Reza Rahimzadeh Oskoei^b, Bitā Abbasi^{c,*}, Ramin Sadeghi^d^a Clinical Research Unit, Mashhad University of Medical Sciences, Mashhad, Iran^b Student Research Committee, Faculty of Medicine, Mashhad University of Medical Science, Mashhad, Iran^c Department of Radiology, Faculty of Medicine, Mashhad University of Medical Sciences, Mashhad, Iran^d Nuclear Medicine Research Center, Mashhad University of Medical Sciences, Mashhad, Khorasan Razavi, Iran

ARTICLE INFO

Keywords:

COVID-19

Coronavirus

Computed tomography

Thorax

Meta-analysis

ABSTRACT

Objectives: We performed a systematic review and meta-analysis of the prevalence of chest CT findings in patients with confirmed COVID-19 infection.

Methods: Systematic review of the literature was performed using PubMed, Scopus, Embase, and Google Scholar to retrieve original studies on chest CT findings of patients with confirmed COVID-19, available up to 10 May 2020. Data on frequency and distribution of chest CT findings were extracted from eligible studies, pooled and meta-analyzed using random-effects model to calculate the prevalence of chest CT findings.

Results: Overall, 103 studies (pooled population: 9907 confirmed COVID-19 patients) were meta-analyzed. The most common CT findings were ground-glass opacities (GGOs) (77.18%, 95%CI = 72.23–81.47), reticulations (46.24%, 95%CI = 38.51–54.14), and air bronchogram (41.61%, 95%CI = 32.78–51.01). Pleural thickening (33.35%, 95%CI = 21.89–47.18) and bronchial wall thickening (15.48%, 95%CI = 8.54–26.43) were major atypical and airway findings. Lesions were predominantly distributed bilaterally (75.72%, 95%CI = 70.79–80.06) and peripherally (65.64%, 95%CI = 58.21–72.36), while 8.20% (95%CI = 6.30–10.61) of patients had no abnormal findings and pre-existing lung diseases were present in 6.01% (95%CI = 4.37–8.23).

Conclusions: The most common CT findings in COVID-19 are GGOs with/without consolidation, reticulations, and air bronchogram, which often involve both lungs with peripheral distribution. However, COVID-19 might present with atypical manifestations or no abnormal findings in chest CT, which deserve clinicians' notice.

1. Introduction

Since the outbreak of coronavirus disease 2019 (COVID-19) – primarily known as 2019 novel coronavirus or 2019-nCoV – in December 2019, a global effort has been undertaken to make timely diagnosis and prevention of the disease possible. On the 30th of January 2020, the world health organization announced COVID-19 as a global health emergency [1]. As of April 25, 2020, COVID-19 has infected over five million patients with more than 342,000 confirmed deaths worldwide, and the WHO has characterized the situation as a pandemic [2,3].

Although real-time reverse transcription polymerase chain reaction (RT-PCR) is the only definitive diagnostic method and the current modality of choice for detection of COVID-19 infection, rapid spread of the disease mandates the healthcare system to look for a faster, easier, and

more available diagnostic tool. With the growing body of evidence on COVID-19 infection, chest CT is establishing its role in early diagnosis of the disease. Chest CT is now considered as an integral part in evaluation of suspected COVID-19 patients as a reliable, quick, and practical method for detection and assessment of COVID-19, particularly in the epidemic areas. Recent studies have shown superior sensitivity of CT scan in comparison with RT-PCR method for diagnosis of COVID-19 [4,5].

The typical chest CT finding of COVID-19 infection is reported to be multiple bilateral ground-glass opacities (GGOs) with a predominantly peripheral distribution. Although these imaging manifestations are believed to be the general picture of COVID-19, the disease may present with a variety of CT findings [6–8]. However, a dearth of comprehensive investigations to consolidate the emerging evidence is felt in this regard.

* Corresponding author at: Radiology Department, Imam Reza Hospital, Razi Sq., Mashhad 91379-13316, Iran.

E-mail address: AbbasiB@mums.ac.ir (B. Abbasi).

<https://doi.org/10.1016/j.clinimag.2020.10.035>

Received 10 August 2020; Received in revised form 26 September 2020; Accepted 17 October 2020

Available online 25 October 2020

0899-7071/© 2020 Elsevier Inc. All rights reserved.

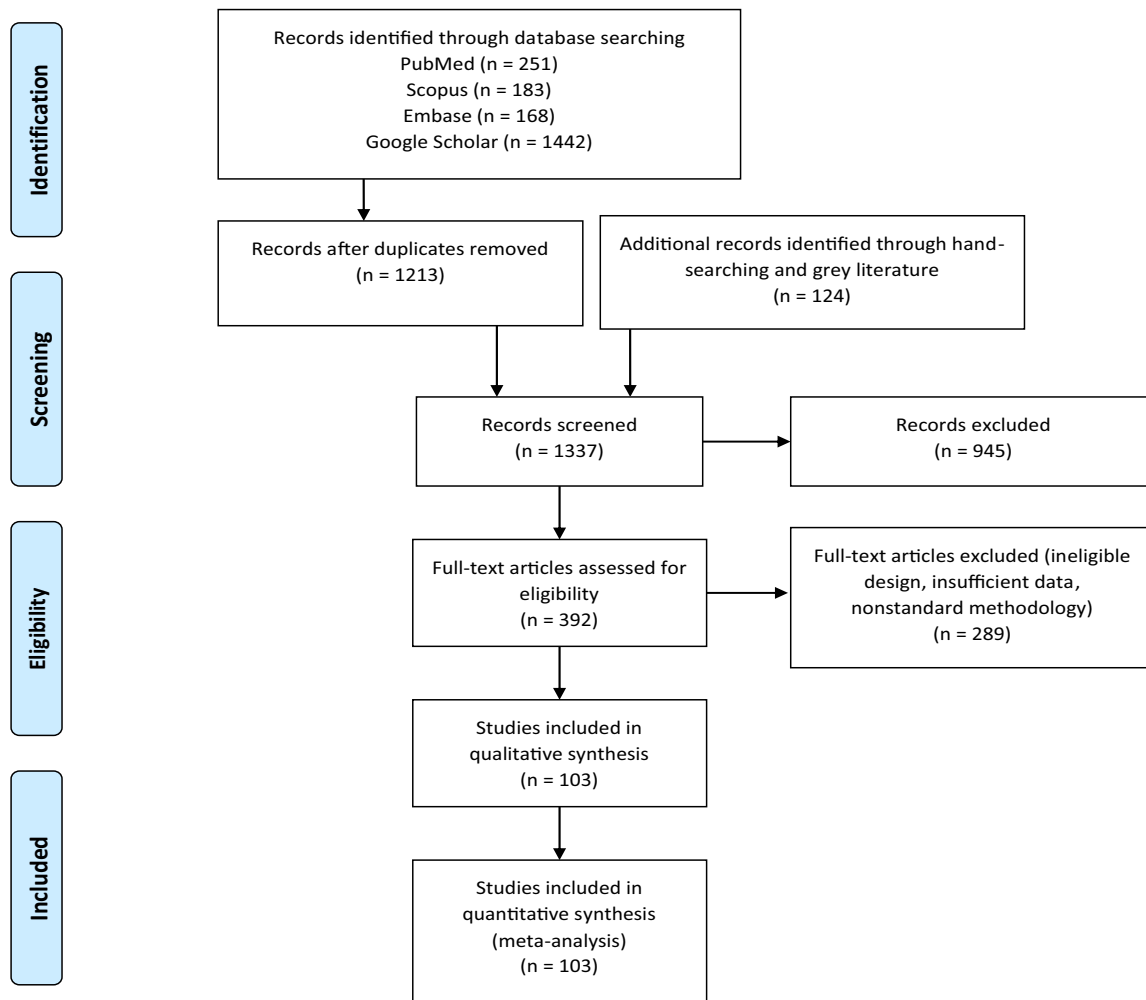


Fig. 1. PRISMA flow diagram of the study.

There are already a few systematic reviews within the literature evaluating the same topic, but they have a limited sample size, are affected by publication bias, and have not included more recent publications. Moreover, many of the published studies have used nonstandard (non-Fleischner Society) terms for describing lung abnormalities, which are included in the previous meta-analyses and have made the reported estimates somewhat inaccurate. In March 2020, a consensus statement of reporting CT findings was published by the Radiologic Society of North America (RSNA), which categorized the CT findings into typical and atypical [9]. This categorization was based on the frequency of findings reported in the literature published by the time. Since then, some reports indicated the frequency of atypical findings to be higher than what was previously thought. Herein, we systematically reviewed the available literature on the chest CT findings in patients with confirmed molecular diagnosis of COVID-19 infection, and evaluated the frequency of typical and atypical findings in a large sample size of over 9900 patients.

2. Methods

2.1. Data sources and search strategy

A computerized search was conducted to identify and to screen studies available online up to May 10, 2020, reporting the chest CT manifestations in patients with confirmed diagnosis of COVID-19. Three independent investigators (A.Z., R.R.O., and M.G.N.) searched the PubMed, Embase, and Scopus databases as well as Google Scholar search

engine. We searched the literature applying various combinations of Boolean operators and relevant keywords, using the following search strategy:

("COVID-19" OR "coronavirus disease 2019" OR "2019 novel coronavirus" OR "2019-nCoV" OR "coronavirus" OR "SARS-CoV-2" OR "SARS 2") AND ("Computed tomography" OR "computerized tomography" OR "chest computed" OR "chest computerized" OR "chest CT" OR "CT scan" OR "CT imaging").

All published studies in English language with an abstract or a full-text version containing any of the search terms relevant to our review were retrieved from the searched databases for further evaluation. Moreover, after selection of the eligible studies for inclusion in the review, their reference lists were manually checked for any possible missing relevant article.

2.2. Eligibility criteria

All studies containing data on chest CT findings of 10 or more patients with confirmed diagnosis of COVID-19 using RT-PCR were included in our study. We excluded articles of the following types: review, editorial, letter to editor, and reply to authors, unless they provided data on chest CT findings of 10 or more patients with confirmed COVID-19. Studies without sufficient information or those with no quantitative report of the frequency for chest CT findings were also excluded from the systematic review.

Moreover, studies that used nonstandard terminology for description of all their chest CT findings (those not compliant with Fleischner

Table 1
Pooled prevalence of chest CT findings in COVID-19 pneumonia.

Chest CT finding	N studies	N patients	Prevalence (%)	95%CI	I ²	
Typical findings	GGO with/without consolidation	66	6224	77.18	72.23–81.47	89.50
	Reticulation with/without GGO	41	2667	46.24	38.51–54.14	90.21
	Air bronchogram	28	1953	41.61	32.78–51.01	90.99
	Rounded GGO/consolidation	7	385	38.02	22.14–56.97	78.76
	Organizing pneumonia patterns	33	2557	36.85	28.94–45.53	92.25
	Consolidation	44	4397	35.56	28.84–42.91	96.06
	Halo sign	7	601	25.63	13.86–42.46	94.82
Central bronchial findings	Bronchial wall thickening	10	873	15.48	8.54–26.43	83.19
	Airway secretions (mucoid impaction)	1	121	0.83	0.05–11.32	0.00
Atypical findings	Pleural thickening	12	1392	33.35	21.89–47.18	88.18
	Nodules	32	2582	13.11	9.26–18.25	84.60
	Pleural effusion	48	3963	6.96	5.09–9.45	78.25
	Lymphadenopathy	39	3197	5.19	3.53–7.57	88.05
	Cavitation	11	641	1.1	0.41–2.92	0.00
	Pneumothorax	2	167	0.89	0.11–6.92	0.00
Pre-existing lung diseases	45	6259	6.01	4.37–8.23	92.10	
No findings (normal)	72	5936	8.20	6.30–10.61	83.57	

GGO: ground-glass opacity, 95%CI: 95% confidence interval.

Society standards for thoracic imaging [10]) were excluded. However, for studies in which only some of the reported findings were nonstandard, we only included the standard terminology.

2.3. Study selection

Two investigators (A.Z. and M.G.N.) independently reviewed the titles and abstracts of all obtained studies for eligibility screening. After excluding the duplicates and irrelevant studies, all remaining studies underwent full-text review.

Four investigators (A.Z., M.G.N., R.R.O., and A.A.R.) independently reviewed the full texts of all eligible studies and reached a joint consensus to determine final inclusion. The flow diagram of the review process is presented in Fig. 1.

If two studies were performed on similar patients from a single hospital with mutual authors and adjacent publication dates, the study with smaller sample size was excluded to reduce the chance of duplicate data. In order to reduce the risk of bias and duplicate data, only studies reporting chest CT findings on 10 or more patients were included in our meta-analysis.

2.4. Data extraction

Four investigators (A.Z., A.A.R., M.G.N., and R.R.O.) read the included full text articles to extract the study characteristics, demographic information, and chest CT findings. Extracted study characteristics were publication/acceptance date, first author, report origin (city and country from which the work originated), study design, and sample size. Extracted demographics of the patients included sex and age.

The frequency of each chest CT finding that was reported using standard terminology in patients with positive RT-PCR for COVID-19 was also extracted. Findings of the chest CT were organized according to the standard terminology for thoracic imaging provided by the Fleischner Society [10]. Accordingly, in an attempt to standardize the terminology we organized the reticular patterns including interlobular septal thickening and crazy paving in one single finding named “reticulation with/without GGO”. We also included nonspecific linear opacities (i.e. linear opacities, fibrotic stripes or streaks, and subpleural lines) and reverse halo sign in one single finding named “organizing pneumonia patterns”. We incorporated all pre-existing lung diseases reported by the studies, including chronic obstructive pulmonary disease, tuberculosis, bronchiectasis, malignancies, and asthma into one group of findings named “pre-existing lung diseases”. Besides, all chest CT patterns representing chronic lung diseases (e.g. usual interstitial pneumonia in idiopathic pulmonary fibrosis, and other interstitial lung

diseases) were also included in this group as a single finding named “pulmonary fibrosis”.

We categorized the findings into typical and atypical in an attempt to be in accordance with the Radiological Society of North America Expert consensus statement on reporting chest CT findings related to COVID-19 [11]. Typical findings included GGO with/without consolidation, reticulation with/without GGO, round GGO/consolidation, air bronchogram, consolidation, organizing pneumonia patterns, and halo sign. Atypical findings included pleural thickening, pulmonary nodules, pleural effusion, lymphadenopathy, pneumothorax, and cavitation. Bronchial wall thickening and airway secretions (mucoid impaction) were included in central bronchial findings category.

The frequency of normal CT (no findings) was also recorded for each study. Furthermore, the distribution of findings in terms of the involved lungs, respective lobes, and the dispersion of the lesions in the lung field were extracted.

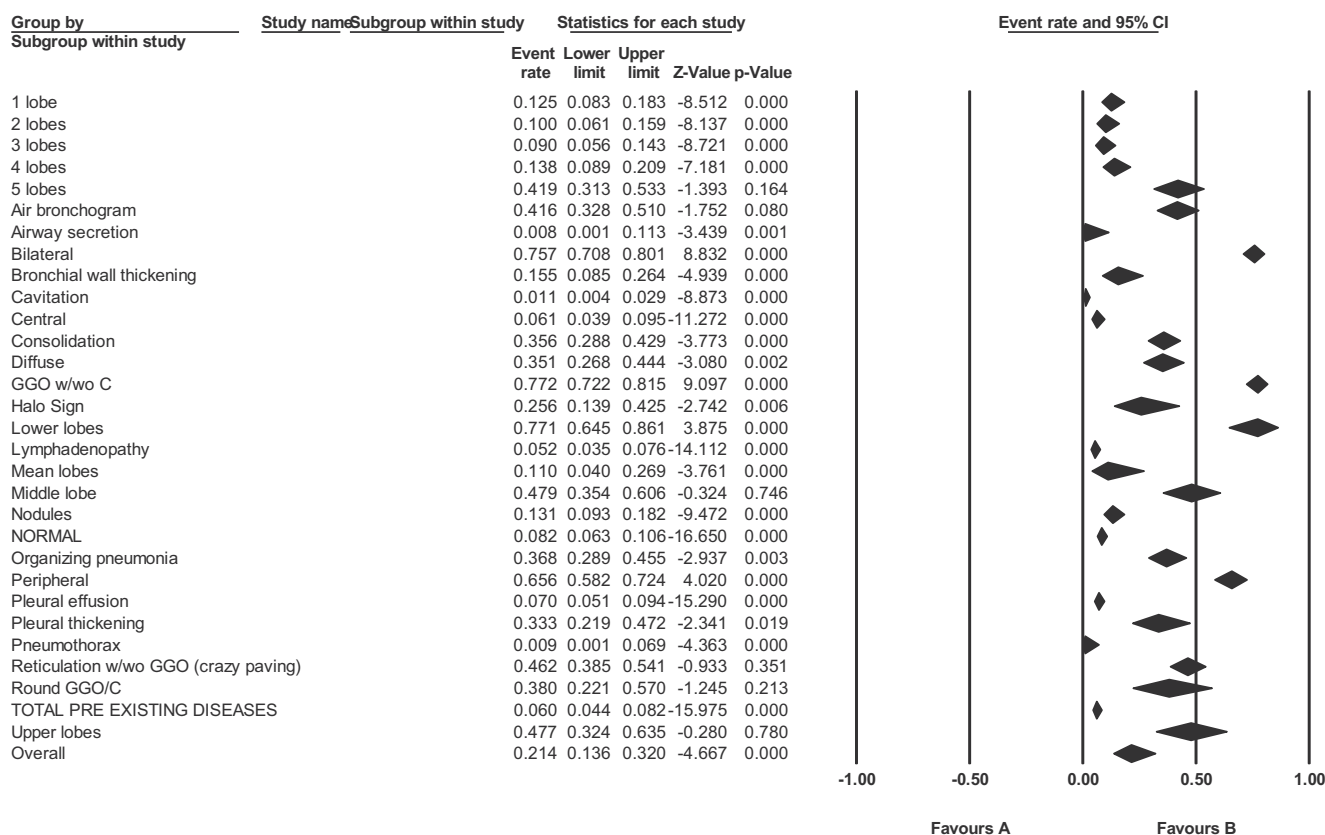
2.5. Quality assessment

All studies included in the meta-analysis underwent quality assessment. Quality appraisal of case series studies was performed using the institute of health economics (IHE) checklist and the critical appraisal tool to assess the quality of cross-sectional studies (AXIS) was used to assess the quality of the included cross-sectional studies [12,13]. In order to avoid score discrepancy between investigators, a single investigator (M.G.N.) evaluated all the included articles and scored them on a scale of 0–20.

The IHE quality appraisal tool for the evaluation of case series studies originally includes 20 items assessing the methodologic quality of case series studies to generate a score of 0 to 20. It provides an effective means to assess the quality of non-controlled studies, which constitute a major part of our study. In cases without repeated measurements, the study was awarded the scores for questions 11, 13 and 14, which are specific to studies with a repeated-measures design [13]. The AXIS is also a 20-item checklist developed for critical appraisal of the cross-sectional studies, scoring the quality of studies on a scale of 0 to 20 [12].

2.6. Publication bias

In an attempt to minimize the publication bias, we searched several databases and search engines. We also included gray literature and preprints in the systematic review. Moreover, we assessed publication bias using the trim and fill method, Egger’s test, and funnel plots.



Meta Analysis

Fig. 2. Cumulative forest plot of CT findings.

2.7. Statistical analysis

The prevalence data were pooled across included the studies using a random effects model. Data were summarized as frequency and 95% confidence interval (95%CI). Moreover, we assessed heterogeneity of the findings and provided its indicators including the I-squared (I^2) index.

All analyses were performed using comprehensive meta-analysis software, version 3.3.070 (Biostat, Englewood). We followed the preferred reporting items for systematic reviews and meta-analyses (PRISMA) checklist.

3. Results

3.1. Characteristics of the studies

Our primary search strategy identified 251 studies from PubMed, 168 studies from Embase, and 183 studies from Scopus databases. Google Scholar search engine was also searched and 1442 studies were found. Another 124 studies were obtained through hand searching of the references of included articles and unpublished or preprint studies.

After removing duplicates, 1337 studies underwent title and abstract review, of which 392 proved to be eligible for full-text review. Some full-text articles were excluded due to improper study design, nonstandard terminology for reporting thoracic findings, or lack of prevalence data on chest CT findings (289 records). Finally, 103 articles with a pooled sample size of 9907 patients with confirmed diagnosis of COVID-19 who underwent chest CT were included in the meta-analysis.

The PRISMA flow diagram is shown in Fig. 1. Characteristics and patient demographics for all studies included in the meta-analysis are shown in Supplementary Table 1.

3.2. Meta-analysis

Table 1 summarizes the pooled prevalence of all chest CT findings in patients with confirmed diagnosis of COVID-19 infection, according to the results of meta-analysis. A forest plot for all CT findings is presented in Fig. 2.

Among the typical findings, GGOs with/without consolidation was the most common manifestation with a prevalence of 77.18% (95%CI = 72.23–81.47) reported from 66 studies with a pooled population of 6224 patients. Reticulation with/without GGO was reported in 41 studies with total population of 2667 patients and had the second highest prevalence (46.24%, 95%CI = 38.51–54.14). The third most common finding was air bronchogram (41.61%, 95%CI = 32.78–51.01), which was mentioned in 28 studies with a pooled population of 1953 patients.

The main atypical finding was pleural thickening which was reported in 12 studies with an overall population of 1392 patients (33.35%, 95% CI = 21.89–47.18). Bronchial wall thickening was the most prevalent airway abnormality on chest CT (17.27%, 95%CI = 10.65–26.75), which was reported in six studies including 625 patients.

We also observed that the lesions are most likely to involve the lower lobes (77.07%, 95%CI = 64.55–86.13). It is worth noting that 8.20% of patients with COVID-19 (95%CI = 6.30–10.61) had no abnormal findings in their chest CT scan, as reported by 72 studies with a pooled population of 5936 patients.

Table 2
Distribution of chest CT findings in COVID-19 pneumonia.

Distribution	N studies	N patients	Prevalence (%)	95%CI	I ²
Bilateral involvement	70	5505	75.72	70.79–80.06	89.78
Peripheral involvement	43	3216	65.64	58.21–72.36	94.29
Diffuse involvement	28	2080	35.11	26.79–44.44	89.54
Central involvement	26	2160	6.11	3.89–9.47	91.73
Lower lobes	12	1265	77.07	64.55–86.13	95.46
Upper lobes	10	1155	47.70	32.37–63.48	95.57
Middle lobe	15	1487	47.87	35.40–60.60	94.44
1 lobe affected	23	1674	12.48	8.35–18.26	79.42
2 lobes affected	17	1154	10.01	6.15–15.88	68.57
3 lobes affected	17	1154	9.00	5.56–14.27	0.00
4 lobes affected	17	1154	13.81	8.86–20.89	28.38
5 lobes affected	19	1229	41.92	31.31–53.32	88.07

95%CI: 95% confidence interval.

Of the 103 studies included, 86 had assessed pre-existing diseases and elaborated on the respective details, of which 41 reported no pre-existing diseases in any of the patients. In the remaining 45 studies with a cumulative population of 6259 patients, pre-existing lung diseases were present in 6.01% of patients (95%CI = 4.37–8.23).

According to our analysis, most of the lesions were distributed peripherally (65.64%, 95%CI = 58.21–72.36) and involved both lungs (75.72%, 95%CI = 70.79–80.06). Table 2 shows the distribution of chest CT findings in COVID-19 patients.

3.3. Publication bias

Funnel plots regarding the publication bias for two major findings (GGOs and normal chest CT) are shown in Figs. 3 and 4. The results of

Egger’s test as well as trim and fill method for quantitative assessment of publication bias regarding several major findings of our study are illustrated in Table 3.

4. Discussion

This systematic review and meta-analysis was designed to analyze the reported chest CT findings in patients with COVID-19 pneumonia. Although chest radiograph is the first-line imaging modality in most patients with acute respiratory syndrome, lung CT is suggested as the subsequent study or even the imaging modality of choice in selected situations [117,118]. In spite of its relatively low specificity, chest CT has been reported to be a highly sensitive diagnostic tool for detection of COVID-19. CT scan has certain downsides like increased patient radiation, increased staff exposure, and time limitations in unstable patients. Taking these into account, CT scan is not considered the first diagnostic modality in many guidelines. The American College of Radiology has recommended chest CT only for hospitalized and symptomatic COVID-19 patients with specific clinical indications, not as the first-line diagnostic or screening tool. There has also been some issues regarding the risk for spreading infection with the use of imaging equipment and the latest guidelines have advised the clinicians to minimize visits of suspicious patients to healthcare facilities. Yet for a considerable number of patients, especially in the regions with limited PCR resources, some medical practitioners might require chest CT at the first visit to make decisions whether to test patients for COVID-19 infection, admit them or provide other treatments [119].

Accurate diagnosis and management of COVID-19 patients depend on knowledge of typical and atypical findings in chest CT scan and familiarity with the evolution of imaging manifestations. A comprehensive understanding of imaging manifestations of COVID-19 is particularly important since healthcare professionals are under increasing pressure to make rapid and reliable diagnoses [120]. Besides, radiologists should familiarize themselves with the CT appearance of

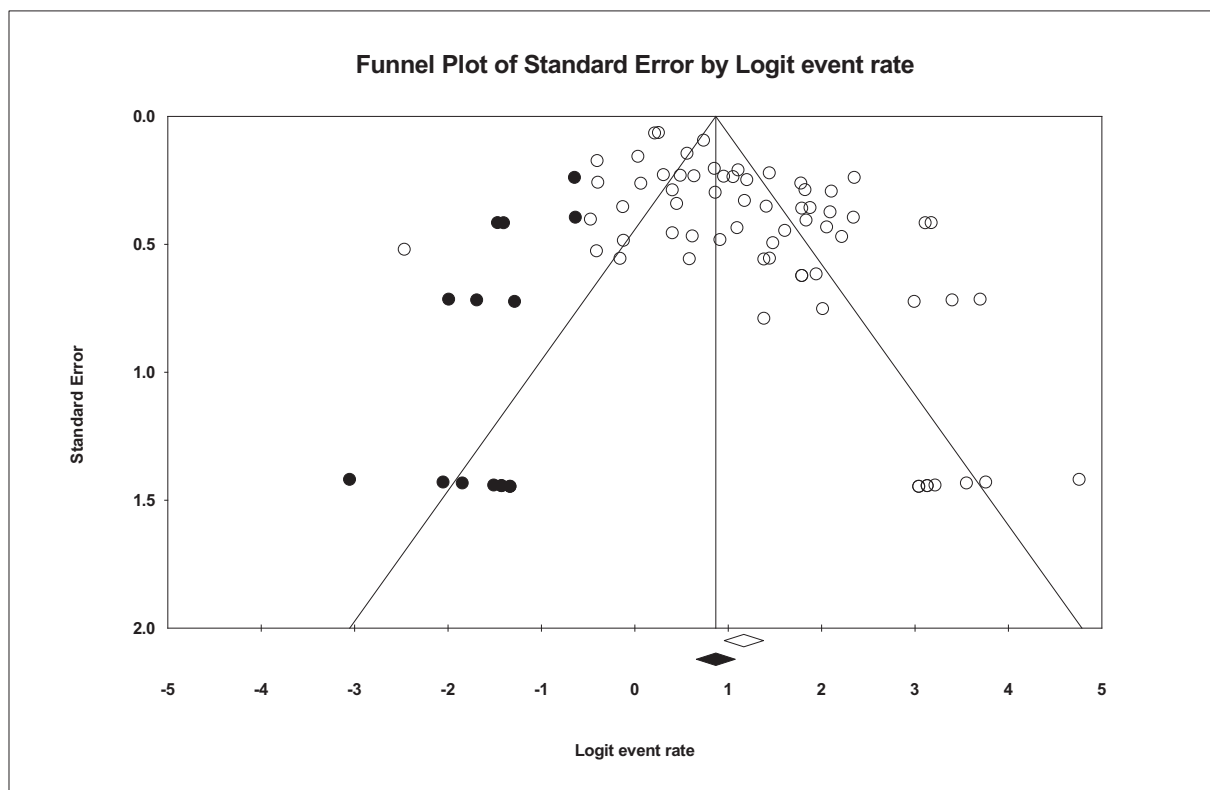


Fig. 3. Funnel plot for ground-glass opacity.

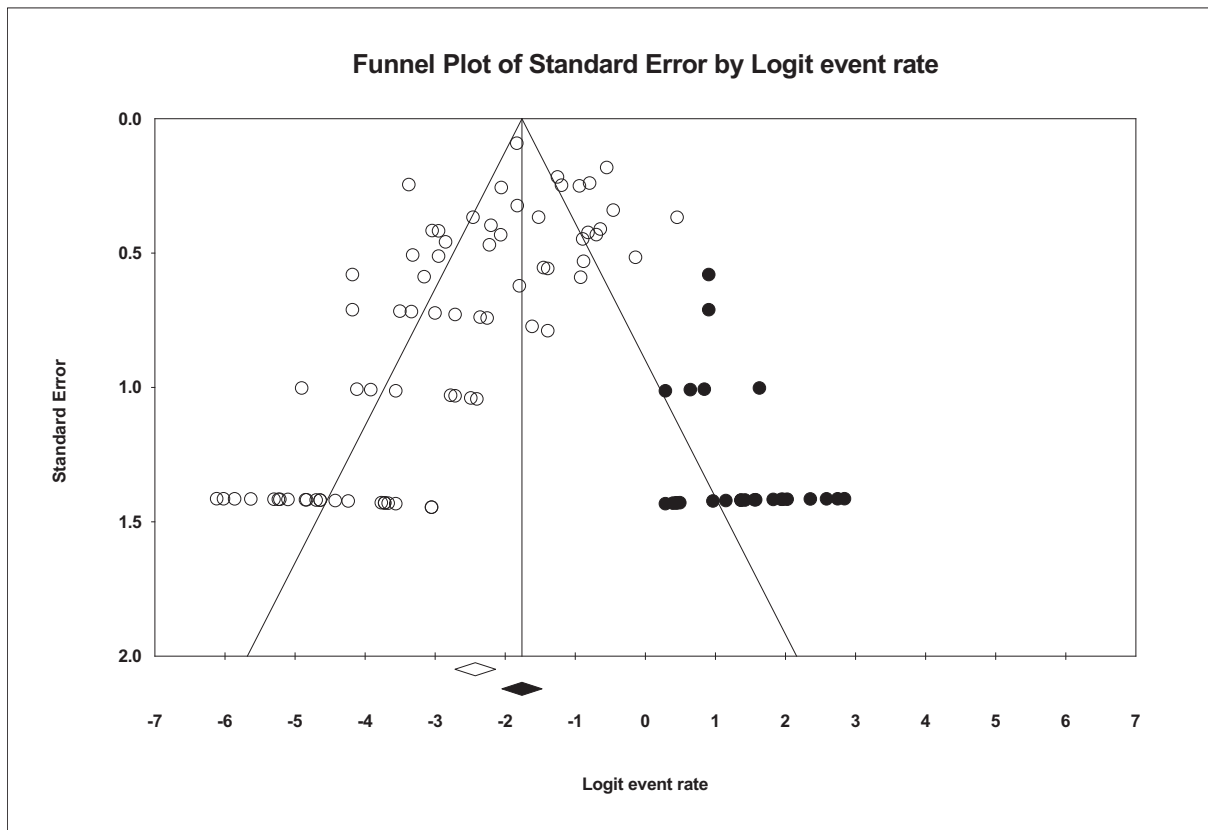


Fig. 4. Funnel plot for normal CT findings.

Table 3
Quantitative results of assessment for publication bias.

Finding/ distribution pattern	Egger's test		Trim and fill method		
	Egger's intercept	p value	Number of trimmed studies	Point estimate after trim	Change after trim
GGO w/wo consolidation	2.61	0.001	15	0.70	0.06
Reticulation w/wo GGO	-0.64	0.652	0	0.50	0
Air bronchogram	-1.90	0.319	2	0.39	0.02
Consolidation	-0.41	0.825	0	0.40	0.04
Organizing pneumonia pattern	-0.14	0.912	5	0.43	0.05
Pleural effusion	-2.17	0.001	15	0.10	0.03
Lymphadenopathy	-3.09	0.001	14	0.08	0.36
Nodules	-2.53	0.001	9	0.18	0.05
Normal	-1.88	0.001	26	0.15	0.07
Pre-existing lung diseases	-2.88	0.002	11	0.08	0.03
Bilateral	0.41	0.602	12	0.70	0.06
Central	-4.36	0.001	6	0.07	0.03
Diffuse	-2.65	0.069	3	0.40	0.04
Peripheral	4.25	0.002	6	0.61	0.05
Middle lobe	7.17	0.004	0	0.48	0

GGO: Ground-glass opacities; COPD: chronic obstructive pulmonary disease; w/wo: with/without.

COVID-19 infection in order to be able to identify findings consistent with infection in patients imaged for other reasons [121]. With respect to the call for studies on the clinical characteristics of COVID-19 from the WHO, in this systematic review and meta-analysis study, we have summarized all the available data on chest CT findings of around 10,000

patients with confirmed COVID-19 diagnosis derived from published and yet unpublished preprint reports from four countries. This is the first systematic review that evaluates the findings according to the RSNA categorization of typical and atypical CT features of COVID-19 infection.

We found that the vast majority (75.72%) of COVID-19 cases had bilateral involvement of lungs and most of the lesions were peripherally distributed (65.64%). A higher percentage of patients appeared to have involvements in all five lobes (41.92%). Moreover, lower lobes were more commonly involved (77.07%). A recent meta-analysis of 4121 patients with COVID-19 from 34 retrospective studies revealed relatively similar results, indicating predominance of bilateral (73.8%) and multilobar (67.3%) lung involvement [122].

The most common typical finding in chest CT of patients with COVID-19 was GGO with/without consolidation (77.18%), followed by reticulation with/without GGO (46.24%), and air bronchogram (41.61%). Other typical findings in the order of prevalence were rounded GGO/consolidation (38.02%), organizing pneumonia patterns (36.85%), consolidation (35.56%) and halo sign (25.63%). Bronchial wall thickening was also the most common airway finding in the patients (15.48%). Other relatively uncommon atypical findings were nodules (13.11%), pleura effusion (6.96%), lymphadenopathy (5.19%), cavitation (1.1%), and pneumothorax (0.89%). Overall, airway secretion (mucoïd impaction) was the rarest chest CT finding, with a prevalence of 0.83%. Pleural thickening, generally categorized as an uncommon finding, had a prevalence of 33.35%, which is much higher than expected. We found the prevalence of pre-existing respiratory diseases to be around 6% in patients with confirmed COVID-19 diagnosis, as reported in a large body of reviewed studies. This relatively low prevalence implies that the majority of reported abnormal chest CT findings in the patients can be mainly imputed to COVID-19 and not to the pre-existing conditions. However, as most of the included patients were symptomatic and of older age, some of the reported findings might inevitably be due to the aging-related respiratory conditions that were

not accurately reported by the studies. This can be the reason behind the high prevalence of some atypical findings in our study. For instance, the relatively high prevalence for pleural thickening, which is considered an atypical finding for COVID-19, can be because it is a non-specific finding and can be present in a variety of abnormal respiratory conditions. A study evaluating the incidence of new pleural thickening in patients with multiple CT studies could be helpful in clarifying this topic.

Relatively similar results were reported by a recent meta-analysis of 4121 patients with COVID-19. Zhu et al. reported the most common findings to be GGO (68.1%), air bronchogram (44.7%), crazy-paving pattern (35.6%), and consolidation (32.0%), respectively. They found pleural thickening to be present in 27.1%, while lymphadenopathy and pleural effusion were present in 5.4% and 5.3% of patients, respectively [122].

The typical findings in chest CT scans of patients with confirmed COVID-19 were generally comparable to those found in patients with other viral pneumonias, mainly severe acute respiratory syndrome and Middle East respiratory syndrome [21,98,123,124]. However, atypical and uncommon presentations on chest CT are also reported by some studies. Therefore, clinicians, particularly radiologists, should be aware of the uncommon findings as well, especially in cases with pulmonary comorbidities such as lung cancer [125–129].

Our meta-analysis showed an approximate 91.8% rate of abnormal CT manifestations, indicating an 8.2% rate of normal CTs. This is in line with the 8.4% prevalence of normal chest CTs in a recent meta-analysis [122]. Inconsistently, a recent meta-analysis of eight studies on COVID-19 patients, which is not published yet (preprint) reported a higher rate of 95.6% for incidence of abnormal chest CT findings [130]. Another published meta-analysis of 10 studies also reported a higher rate (96.6%) of abnormal chest CT findings in COVID-19 patients [131]. This inconsistency might be because the mentioned studies included fewer articles that were published early at the beginning of the outbreak, and focused mainly on critically symptomatic patients, who are more likely to present abnormal chest CT findings. Besides, it can be due to the difference in the time of performing CT scan in different studies. As reported in several studies, patients with initially normal chest CT scans in the first days of the disease can develop pulmonary lesions in the following days [36,132].

On the one hand, it is worth mentioning that although some patients with COVID-19 might not demonstrate abnormal findings in their initial chest CT studies during the first days of infection, they would probably develop pulmonary opacities in later stages. Therefore, it is recommended that the clinicians follow the patients, since normal chest CT does not unequivocally rule out COVID-19 [36]. On the other hand, initial RT-PCR testing might yield negative results in some patients who have presented with typical chest CT findings and clinical manifestations that raise the suspicion of COVID-19. Since repeated RT-PCR results might also be negative until the late stages of the disease, chest CT can be particularly helpful in such patients, in that it enables the clinicians to detect highly probable COVID-19 patients and take precautionary measures to isolate them and control the spread of the disease [126,133,134]. In patients who show negative specimen test, the clinicians should consider the possibility of false-negative results. Therefore, it can be recommended to use a combination of CT scan and RT-PCR test in patients with initially negative RT-PCR screening but high clinical suspicion of COVID-19 infection [5,135]. Early diagnosis of COVID-19 cases enables healthcare professionals to offer adequate clinical monitoring and necessary interventions for the patients, as well as taking precautionary actions to control the spread and prevent further transmission of the infection [136–139].

Regarding the assessment of publication bias, funnel plots showed asymmetry and the results of Egger's test confirmed the existence of publication bias for some of our findings. Although publication bias has inevitably affected our findings, quantified assessment using trim and fill method showed that it did not have a significant effect on the estimated prevalence of our findings, except for lymphadenopathy, which is

an atypical finding.

The results of this study can provide useful insights into the prevalence of CT findings in patients diagnosed with COVID-19 pneumonia. This can be helpful particularly in areas where routine RT-PCR testing is not available or for clinicians facing cases with high clinical suspicion of COVID-19 infection who still lack a confirmed molecular diagnosis.

This study has several limitations. For instance, there are still a limited number of studies available from outside China. In order to provide a more comprehensive understanding of chest CT findings of COVID-19, more studies from other parts of the world are required. Another limitation of our study is that although we incorporated reported respiratory comorbidities into our analyses, there is still an inevitable possibility that some findings might be related to chronic underlying conditions other than COVID-19, particularly because the disease severity tends to be higher in the older population who carry a higher rate of comorbidities. Possible selection bias in the included studies can also be a limitation, for it is quite likely that most of the imaged patients were selected from those with the worst clinical conditions. Besides, although we tried to minimize the duplicates by excluding small studies and those reporting similar patients from the same hospital in a limited period, our study inevitably carries a risk of including duplicate cases as most of the available studies are from a limited number of cities in China. Moreover, high levels of heterogeneity were observed regarding some of our findings, which can be possibly due to the heterogeneous characteristics of included populations and the difference in time of performing chest CT. The technical characteristics such as slice thickness and tube current of performed CT scans are not evaluated in this study due to the heterogeneity in the reviewed studies in this regard. This heterogeneity of the technical details may have some effect on the frequency of reported findings in different studies. Finally, only a few studies reported accurate time course of chest CT findings in COVID-19 patients and we could not incorporate this item in the meta-analysis. Further studies providing adequate data on accurate time of appearance for each chest CT finding in patients with COVID-19 infection are required to shed light on this important matter.

In conclusion, GGOs with or without consolidation, reticulation, and air bronchogram were the typical chest CT findings in COVID-19 pneumonia. Lesions often involve both lungs with peripheral distribution. In addition to these common findings, it should be considered that COVID-19 infection might present with a variety of manifestations in chest CT scanning. The alarm should sound for every first-line clinician when facing any of these CT manifestations, especially in areas with epidemic COVID-19 infection and limited access to RT-PCR. We recommend that future investigations focus on the changes in CT findings over time and the role of CT manifestations in the patients' prognosis.

Supplementary data to this article can be found online at <https://doi.org/10.1016/j.clinimag.2020.10.035>.

Declaration of competing interest

None.

References

- [1] World Health Organization. Statement on the second meeting of the International Health Regulations (2005) Emergency Committee regarding the outbreak of novel coronavirus (2019-nCoV). Retrieved, 2020.
- [2] WHO. Coronavirus disease 2019 (COVID-19) situation report. 2020. p. 126. Available from, https://www.who.int/docs/default-source/coronaviruse/situation-reports/20200525-covid-19-sitrep-126.pdf?sfvrsn=887dbd66_2.
- [3] WHO. Rolling updates on coronavirus disease (COVID-19). Available from: <https://www.who.int/emergencies/diseases/novel-coronavirus-2019/events-as-they-happen>; 2020.
- [4] Ai T, Yang Z, Hou H, Zhan C, Chen C, Lv W, et al. Correlation of chest CT and RT-PCR testing in coronavirus disease 2019 (COVID-19) in China: a report of 1014 cases. *Radiology* 2020;296(2):E32–40.

- [5] Jin YH, Cai L, Cheng ZS, Cheng H, Deng T, Fan YP, et al. A rapid advice guideline for the diagnosis and treatment of 2019 novel coronavirus (2019-nCoV) infected pneumonia (standard version). *Mil Med Res* 2020;7(1):4.
- [6] Kong W, Agarwal PP. Chest imaging appearance of COVID-19 infection. *Radiol Cardiothor Imaging* 2020;2(1):e200028.
- [7] Li X, Zeng X, Liu B, Yu Y. COVID-19 infection presenting with CT halo sign. *Radiol Cardiothor Imaging* 2020;2(1):e200026.
- [8] Ng M-Y, Lee EY, Yang J, Yang F, Li X, Wang H, et al. Imaging profile of the COVID-19 infection: radiologic findings and literature review. *Radiol Cardiothor Imaging* 2020;2(1):e200034.
- [9] Simpson S, Kay FU, Abbara S, Bhalla S, Chung JH, Chung M, et al. Radiological Society of North America expert consensus statement on reporting chest CT findings related to COVID-19. Endorsed by the Society of Thoracic Radiology, the American College of Radiology, and RSNA. *J Thorac Imaging* 2020;2(2).
- [10] Hansell DM, Bankier AA, MacMahon H, McLoud TC, Müller NL, Remy J. Fleischner Society: glossary of terms for thoracic imaging. *Radiology* 2008;246(3):697–722.
- [11] Simpson S, Kay FU, Abbara S, Bhalla S, Chung JH, Chung M, et al. Radiological Society of North America expert consensus statement on reporting chest CT findings related to COVID-19. Endorsed by the Society of Thoracic Radiology, the American College of Radiology, and RSNA. *Radiol Cardiothor Imaging* 2020;2(2):e200152.
- [12] Downes MJ, Brennan ML, Williams HC, Dean RS. Development of a critical appraisal tool to assess the quality of cross-sectional studies (AXIS). *BMJ Open* 2016;6(12):e011458.
- [13] Institute of Health Economics (IHE). Quality appraisal of case series studies checklist. Edmonton (AB): Institute of Health Economics; 2014. Available from, <http://www.ihe.ca/research-programs/rmd/cssqac/cssqac-about>.
- [14] W-j Guan, Ni Z-y, Hu Y, Liang W-h, C-q Ou, He J-x, et al., China Medical Treatment Expert Group for Covid-19. Clinical Characteristics of Coronavirus Disease 2019 in China. *New Engl J Med* 2020;382(18):1708–20.
- [15] Wang X, Fang J, Zhu Y, Chen L, Ding F, Zhou R, et al. Clinical characteristics of non-critically ill patients with novel coronavirus infection (COVID-19) in a Fangcang Hospital. *Clin Microbiol Infect* 2020;28(8):1063–8.
- [16] Liu W, Wang F, Li G, Wei Y, Li X, He L, et al. Analysis of 2019 novel coronavirus infection and clinical characteristics of outpatients: an epidemiological study from the fever clinic in Wuhan, China. *SSRN database* 2020. <https://doi.org/10.2139/ssrn.3539646>.
- [17] Yang Z, Shi J, He Z, Lu Y, Xu Q, Ye C, et al. Predictors for imaging progression on chest CT from coronavirus disease 2019 (COVID-19) patients. *Aging (Albany NY)* 2020;12(7):6037–48.
- [18] Colombi D, Bodini FC, Petrini M, Maffi G, Morelli N, Milanese G, et al. Well-aerated lung on admitting chest CT to predict adverse outcome in COVID-19 pneumonia. *Radiology* 2020;201433.
- [19] Dai H, Zhang X, Xia J, Zhang T, Shang Y, Huang R, et al. High-resolution chest CT features and clinical characteristics of patients infected with COVID-19 in Jiangsu, China. *Int J Infect Dis* 2020;95:106–12.
- [20] Li R, Tian J, Yang F, Lv L, Yu J, Sun G, et al. Clinical characteristics of 225 patients with COVID-19 in a tertiary hospital near Wuhan, China. *J Clin Virol* 2020;104363:127.
- [21] Bai HX, Hsieh B, Xiong Z, Halsey K, Choi JW, Tran TML, et al. Performance of radiologists in differentiating COVID-19 from viral pneumonia on chest CT. *Radiology* 2020;200823.
- [22] He R, Lu Z, Zhang L, Fan T, Xiong R, Shen X, et al. The clinical course and its correlated immune status in COVID-19 pneumonia. *J Clin Virol* 2020;127.
- [23] Cao M, Zhang D, Wang Y, Lu Y, Zhu X, Li Y, et al. Clinical features of patients infected with the 2019 novel coronavirus (COVID-19) in Shanghai, China. *medRxiv* 2020. <https://doi.org/10.1101/2020.03.04.20030395>.
- [24] Guo W, Li M, Dong Y, Zhou H, Zhang Z, Tian C, et al. Diabetes is a risk factor for the progression and prognosis of COVID-19. *Diabetes Metab Res Rev* 2020:e3319.
- [25] Zheng F, Tang W, Li H, Huang YX, Xie YL, Zhou ZG. Clinical characteristics of 161 cases of corona virus disease 2019 (COVID-19) in Changsha. *Eur Rev Med Pharmacol Sci* 2020;24(6):3404–10.
- [26] Caruso D, Zerunian M, Polici M, Pucciarelli F, Polidori T, Rucci C, et al. Chest CT features of COVID-19 in Rome, Italy. *Radiology* 2020;201237.
- [27] Fan N, Fan W, Li Z, Shi M, Liang Y. Imaging characteristics of initial chest computed tomography and clinical manifestations of patients with COVID-19 pneumonia. *Jpn J Radiol* 2020;38:533–8.
- [28] Yang W, Cao Q, Qin L, Wang X, Cheng Z, Pan A, et al. Clinical characteristics and imaging manifestations of the 2019 novel coronavirus disease (COVID-19): a multi-center study in Wenzhou city, Zhejiang, China. *J Infect* 2020;80(4):388–93.
- [29] Feng Z, Yu Q, Yao S, Luo L, Duan J, Yan Z, et al. Early prediction of disease progression in 2019 novel coronavirus pneumonia patients outside Wuhan with CT and clinical characteristics. *medRxiv* 2020. <https://doi.org/10.1101/2020.02.19.20025296>.
- [30] Zhang JJ, Dong X, Cao YY, Yuan YD, Yang YB, Yan YQ, et al. Clinical characteristics of 140 patients infected with SARS-CoV-2 in Wuhan, China. *Allergy* 2020;75(7):1730–41.
- [31] Wang D, Hu B, Hu C, Zhu F, Liu X, Zhang J, et al. Clinical characteristics of 138 hospitalized patients with 2019 novel coronavirus-infected pneumonia in Wuhan, China. *JAMA* 2020;323(11):1061–9.
- [32] Liu K, Fang YY, Deng Y, Liu W, Wang MF, Ma JP, et al. Clinical characteristics of novel coronavirus cases in tertiary hospitals in Hubei Province. *Chin Med J (Engl)* 2020. <https://doi.org/10.1097/CM9.0000000000000744>.
- [33] Li H, Xiang X, Ren H, Xu L, Zhao L, Chen X, et al. Serum Amyloid A is a biomarker of severe Coronavirus Disease and poor prognosis. *J Infect* 2020;80(6):646–55.
- [34] Li X, Zeng W, Li X, Chen H, Shi L, Li X, et al. CT imaging changes of corona virus disease 2019 (COVID-19): a multi-center study in Southwest China. *J Transl Med* 2020;18(1):154.
- [35] Cao W. Clinical features and laboratory inspection of novel coronavirus pneumonia (COVID-19) in Xiangyang, Hubei. *medRxiv* 2020. <https://doi.org/10.21203/rs.3.rs-15925/v1>.
- [36] Bernheim A, Mei X, Huang M, Yang Y, Fayad ZA, Zhang N, et al. Chest CT findings in coronavirus disease-19 (COVID-19): relationship to duration of infection. *Radiology* 2020;200463.
- [37] Zhang R, Ouyang H, Fu L, Wang S, Han J, Huang K, et al. CT features of SARS-CoV-2 pneumonia according to clinical presentation: a retrospective analysis of 120 consecutive patients from Wuhan city. *Eur Radiol* 2020;30:4417–26.
- [38] Zhao W, Zhong Z, Xie X, Yu Q, Liu J. CT scans of patients with 2019 novel coronavirus (covid-19) pneumonia. *Theranostics* 2020;10(10):4606–13.
- [39] Wang K, Kang S, Tian R, Zhang X, Wang Y. Imaging manifestations and diagnostic value of chest CT of coronavirus disease 2019 (COVID-19) in the Xiaogan area. *Clin Radiol* 2020;75(5):341–7.
- [40] Ding X, Xu J, Zhou J, Long Q. Chest CT findings of COVID-19 pneumonia by duration of symptoms. *Eur J Radiol* 2020;127:109009.
- [41] Zhao W, Zhong Z, Xie X, Yu Q, Liu J. Relation between chest CT findings and clinical conditions of coronavirus disease (COVID-19) pneumonia: a multicenter study. *AJR Am J Roentgenol* 2020:1–6.
- [42] Chen N, Zhou M, Dong X, Qu J, Gong F, Han Y, et al. Epidemiological and clinical characteristics of 99 cases of 2019 novel coronavirus pneumonia in Wuhan, China: a descriptive study. *Lancet (London, England)* 2020;395(10223):507–13.
- [43] Chen Z, Fan H, Cai J, Li Y, Wu B, Hou Y, et al. High-resolution computed tomography manifestations of COVID-19 infections in patients of different ages. *Eur J Radiol* 2020;108972:126.
- [44] Wang J, Xu Z, Feng R, An Y, Ao W, Gao Y, et al. CT characteristics of patients infected with 2019 novel coronavirus: association with clinical type. *Clin Radiol* 2020;75(6):408–14.
- [45] Qian GQ, Yang NB, Ding F, Ma AHY, Wang ZY, Shen YF, et al. Epidemiologic and clinical characteristics of 91 hospitalized patients with COVID-19 in Zhejiang, China: a retrospective, multi-centre case series. *Qjm* 2020;113(7):474–81.
- [46] Lu C, Yang W, Hu Y, Hui J, Zhou G, Shu J, et al. Coronavirus disease 2019 (COVID-19) pneumonia: early stage chest CT imaging features and clinical relevance. *SSRN database* 2020. <https://doi.org/10.2139/ssrn.3543606>.
- [47] Zhao XY, Xu XX, Yin HS, Hu QM, Xiong T, Tang YY, et al. Clinical characteristics of patients with 2019 coronavirus disease in a non-Wuhan area of Hubei Province, China: a retrospective study. *BMC Infect Dis* 2020;20(1):311.
- [48] Xu X, Yu C, Qu J, Zhang L, Jiang S, Huang D, et al. Imaging and clinical features of patients with 2019 novel coronavirus SARS-CoV-2. *Eur J Nucl Med Mol Imaging* 2020. <https://doi.org/10.1007/s00259-020-4735-9>.
- [49] Wang Y, Dong C, Li C, Zhang X, Ren Q, Shi H, et al. Temporal changes of CT findings in 90 patients with COVID-19 pneumonia: a longitudinal study. Available at SSRN 3546091. 2020.
- [50] Li K, Wu J, Wu F, Guo D, Chen L, Fang Z, et al. The clinical and chest CT features associated with severe and critical COVID-19 pneumonia. *Invest Radiol* 2020;55(6):327–31.
- [51] Shi H, Han X, Jiang N, Cao Y, Alwalid O, Gu J, et al. Radiological findings from 81 patients with COVID-19 pneumonia in Wuhan, China: a descriptive study. *Lancet Infect Dis* 2020;20(4):425–34.
- [52] Wu J, Wu X, Zeng W, Guo D, Fang Z, Chen L, et al. Chest CT findings in patients with corona virus disease 2019 and its relationship with clinical features. *Invest Radiol* 2020;55(5):257–61.
- [53] Wu J, Liu J, Zhao X, Liu C, Wang W, Wang D, et al. Clinical characteristics of imported cases of COVID-19 in Jiangsu Province: a multicenter descriptive study. *Clin Infect Dis* 2020:ciaa199.
- [54] Zhao X, Liu B, Yu Y, Wang X, Du Y, Gu J, et al. The characteristics and clinical value of chest CT images of novel coronavirus pneumonia. *Clin Radiol* 2020;75(5):335–40.
- [55] Li K, Fang Y, Li W, Pan C, Qin P, Zhong Y, et al. CT image visual quantitative evaluation and clinical classification of coronavirus disease (COVID-19). *Eur Radiol* 2020;30:4407–16.
- [56] Liu KC, Xu P, Lv WF, Qiu XH, Yao JL, Gu JF, et al. CT manifestations of coronavirus disease-2019: a retrospective analysis of 73 cases by disease severity. *Eur J Radiol* 2020;126:108941.
- [57] Chen X, Tang Y, Mo Y, Li S, Lin D, Yang Z, et al. A diagnostic model for coronavirus disease 2019 (COVID-19) based on radiological semantic and clinical features: a multi-center study. *Eur Radiol* 2020;30(9):4893–902.
- [58] Pan Y, Guan H, Zhou S, Wang Y, Li Q, Zhu T, et al. Initial CT findings and temporal changes in patients with the novel coronavirus pneumonia (2019-nCoV): a study of 63 patients in Wuhan, China. *Eur Radiol* 2020:1–4.
- [59] Xu XW, Wu XX, Jiang XG, Xu KJ, Ying LJ, Ma CL, et al. Clinical findings in a group of patients infected with the 2019 novel coronavirus (SARS-CoV-2) outside of Wuhan, China: retrospective case series. *BMJ* 2020;m606:368.
- [60] Zhou S, Wang Y, Zhu T, Xia LCT. Features of coronavirus disease 2019 (COVID-19) pneumonia in 62 patients in Wuhan, China. *AJR Am J Roentgenol* 2020:1–8.
- [61] Zhou Z, Guo D, Li C, Fang Z, Chen L, Yang R, et al. Coronavirus disease 2019: initial chest CT findings. *Eur Radiol* 2020;30(8):4398–406.
- [62] Liu H, Liu F, Li J, Zhang T, Wang D, Lan W. Clinical and CT imaging features of the COVID-19 pneumonia: focus on pregnant women and children. *J Infect* 2020;80(5):e7–13.
- [63] Meng H, Xiong R, He R, Lin W, Hao B, Zhang L, et al. CT imaging and clinical course of asymptomatic cases with COVID-19 pneumonia at admission in Wuhan, China. *J Infect* 2020;81(1):e33–9.

- [64] Lomoro P, Verde F, Zerboni F, Simonetti I, Borghi C, Fachinetti C, et al. COVID-19 pneumonia manifestations at the admission on chest ultrasound, radiographs, and CT: single-center study and comprehensive radiologic literature review. *Eur J Radiol Open* 2020;100231:7.
- [65] Zheng C, Wang J, Guo H, Lu Z, Ma Y, Zhu Y, et al. Risk-adapted treatment strategy for COVID-19 patients. *Int J Infect Dis* 2020;94:74–7.
- [66] Miao C, Jin M, Miao L, Yang X, Huang P, Xiong H, et al. Early chest computed tomography to diagnose COVID-19 from suspected patients: a multicenter retrospective study. *Am J Emerg Med* 2020. In press.
- [67] Guan CS, Lv ZB, Yan S, Du YN, Chen H, Wei LG, et al. Imaging features of coronavirus disease 2019 (COVID-19): evaluation on thin-section CT. *Acad Radiol* 2020;27(5):609–13.
- [68] Song F, Shi N, Shan F, Zhang Z, Shen J, Lu H, et al. Emerging 2019 novel coronavirus (2019-nCoV) pneumonia. *Radiology* 2020;295(1):210–7.
- [69] Fang Y, Zhang H, Xie J, Lin M, Ying L, Pang P, et al. Sensitivity of chest CT for COVID-19: comparison to RT-PCR. *Radiology* 2020;200432.
- [70] Liu L, Jian-ya G. Clinical characteristics of 51 patients discharged from hospital with COVID-19 in Chongqing, China. *medRxiv* 2020. <https://doi.org/10.1101/2020.02.20.20025536>.
- [71] Li Y, Xia L. Coronavirus disease 2019 (COVID-19): role of chest CT in diagnosis and management. *AJR Am J Roentgenol* 2020:1–7.
- [72] Xu T, Chen C, Zhu Z, Cui M, Chen C, Dai H, et al. Clinical features and dynamics of viral load in imported and non-imported patients with COVID-19. *Int J Infect Dis* 2020;94:68–71.
- [73] Lyu P, Liu X, Zhang R, Shi L, Gao J. The performance of chest CT in evaluating the clinical severity of COVID-19 pneumonia: identifying critical cases based on CT characteristics. *Invest Radiol* 2020;55(7):412–21.
- [74] Xu YH, Dong JH, An WM, Lv XY, Yin XP, Zhang JZ, et al. Clinical and computed tomographic imaging features of novel coronavirus pneumonia caused by SARS-CoV-2. *J Infect* 2020;80(4):394–400.
- [75] Xiong Y, Sun D, Liu Y, Fan Y, Zhao L, Li X, et al. Clinical and high-resolution CT features of the COVID-19 infection: comparison of the initial and follow-up changes. *Invest Radiol* 2020;55(6):332–9.
- [76] Huang C, Wang Y, Li X, Ren L, Zhao J, Hu Y, et al. Clinical features of patients infected with 2019 novel coronavirus in Wuhan, China. *Lancet (London, England)* 2020;395(10223):497–506.
- [77] Long C, Xu H, Shen Q, Zhang X, Fan B, Wang C, et al. Diagnosis of the coronavirus disease (COVID-19): rRT-PCR or CT? *Eur J Radiol* 2020;108961:126.
- [78] Fu H, Li H, Tang X, Li X, Shen J, Zhou Y, et al. Analysis on the clinical characteristics of 36 cases of novel coronavirus pneumonia in Kunming. *medRxiv* 2020. <https://doi.org/10.1101/2020.02.28.20029173>.
- [79] Lei S, Jiang F, Su W, Chen C, Chen J, Mei W, et al. Clinical characteristics and outcomes of patients undergoing surgeries during the incubation period of COVID-19 infection. *EclinicalMedicine* 2020;100331.
- [80] Zhu W, Xie K, Lu H, Xu L, Zhou S, Fang S. Initial clinical features of suspected Coronavirus Disease 2019 in two emergency departments outside of Hubei, China. *J Med Virol* 2020;92(9):1525–32.
- [81] Chen C, Cao M, Peng L, Guo X, Yang F, Wu W, et al. Coronavirus disease-19 among children outside Wuhan, China. 2020.
- [82] Zhang L, Zhu F, Xie L, Wang C, Wang J, Chen R, et al. Clinical characteristics of COVID-19-infected cancer patients: a retrospective case study in three hospitals within Wuhan, China. *Ann Oncol* 2020;31(7):894–901.
- [83] Kim ES, Chin BS, Kang CK, Kim NJ, Kang YM, Choi JP, et al. Clinical course and outcomes of patients with Severe Acute Respiratory Syndrome Coronavirus 2 infection: a preliminary report of the first 28 patients from the Korean Cohort Study on COVID-19. *J Korean Med Sci* 2020;35(13):e142.
- [84] Yuan M, Yin W, Tao Z, Tan W, Hu Y. Association of radiologic findings with mortality of patients infected with 2019 novel coronavirus in Wuhan, China. *PLoS ONE* 2020;15(3).
- [85] Tang A, Xu W, Chen P, Li G, Liu Y, Liu L. A retrospective study of the clinical characteristics of COVID-19 infection in 26 children. *medRxiv* 2020. <https://doi.org/10.1101/2020.03.08.20029710>.
- [86] Pan Y, Yu X, Du X, Li Q, Li X, Qin T, et al. Epidemiological and clinical characteristics of 26 asymptomatic SARS-CoV-2 carriers. *J Infect Dis* 2020;221(12):1940–7.
- [87] Zheng F, Liao C, Fan QH, Chen HB, Zhao XG, Xie ZG, et al. Clinical characteristics of children with coronavirus disease 2019 in Hubei, China. *Curr Med Sci* 2020;40(2):275–80.
- [88] Hu Z, Song C, Xu C, Jin G, Chen Y, Xu X, et al. Clinical characteristics of 24 asymptomatic infections with COVID-19 screened among close contacts in Nanjing, China. *Sci China Life Sci* 2020;63:706–11.
- [89] Jie B, Liu X, Suo H, Qiao G, Zheng Q, Xu W, et al. Clinical and dynamic computed tomography features of 24 patients with coronavirus disease 2019. *Can Assoc Radiol J = J Assoc Can Radiol* 2020 [846537120918834].
- [90] Chung M, Bernheim A, Mei X, Zhang N, Huang M, Zeng X, et al. CT imaging features of 2019 novel coronavirus (2019-nCoV). *Radiology* 2020;295(1):202–7.
- [91] Pan F, Ye T, Sun P, Gui S, Liang B, Li L, et al. Time course of lung changes on chest CT during recovery from 2019 novel coronavirus (COVID-19) pneumonia. *Radiology* 2020;200370.
- [92] Ng M-Y, Lee EYP, Yang J, Yang F, Li X, Wang H, et al. Imaging profile of the COVID-19 infection: radiologic findings and literature review. *Radiol Cardiothor Imaging* 2020;2(1):e200034.
- [93] Xu Z, Wu W, Jin Y, Pan A. Key points of clinical and CT imaging features of 2019 novel coronavirus (2019-nCoV) imported pneumonia based on 21 cases analysis. Available at SSRN 3543610. 2020.
- [94] Zhou Y, Han T, Chen J, Hou C, Hua L, He S, et al. Clinical and autoimmune characteristics of severe and critical cases with COVID-19. *Clin Transl Sci* 2020. In press.
- [95] Xu X, Han M, Li T, Sun W, Wang D, Fu B, et al. Effective treatment of severe COVID-19 patients with tocilizumab. *Proc Natl Acad Sci U S A* 2020;117(20):10970–5.
- [96] Xia W, Shao J, Guo Y, Peng X, Li Z, Hu D. Clinical and CT features in pediatric patients with COVID-19 infection: different points from adults. *Pediatr Pulmonol* 2020;55(5):1169–74.
- [97] Lei Z-Y, Cao H-J, Jie Y-S, Huang Z-L, Guo X-Y, Chen J-F, et al. Comparison of epidemiological and clinical features of patients with coronavirus disease (COVID-19) in Wuhan and outside Wuhan, China. 2020.
- [98] Zhao D, Yao F, Wang L, Zheng L, Gao Y, Ye J, et al. A comparative study on the clinical features of COVID-19 pneumonia to other pneumonias. *Clin Infect Dis* 2020;71(15):756–61.
- [99] Han X, Cao Y, Jiang N, Chen Y, Alwalid O, Zhang X, et al. Novel coronavirus pneumonia (COVID-19) progression course in 17 discharged patients: comparison of clinical and thin-section CT features during recovery. *Clin Infect Dis* 2020;71(15):723–31.
- [100] Li J, Li S, Cai Y, Liu Q, Li X, Zeng Z, et al. Epidemiological and clinical characteristics of 17 hospitalized patients with 2019 novel coronavirus infections outside Wuhan, China. *medRxiv* 2020. <https://doi.org/10.1101/2020.02.11.20022053>.
- [101] Zhou Y, Zhang Z, Tian J, Xiong S. Risk factors associated with disease progression in a cohort of patients infected with the 2019 novel coronavirus. *Ann Palliat Med* 2020;9(2):428–36.
- [102] Chen R, Zhang Y, Huang L, Cheng BH, Xia ZY, Meng QT. Safety and efficacy of different anesthetic regimens for parturients with COVID-19 undergoing cesarean delivery: a case series of 17 patients. *Can J Anaesth = J Can Anesth* 2020;67:655–63.
- [103] Li N, Han L, Peng M, Lv Y, Ouyang Y, Liu K, et al. Maternal and neonatal outcomes of pregnant women with COVID-19 pneumonia: a case-control study. *Clin Infect Dis* 2020. In press.
- [104] Xu T, Huang R, Zhu L, Wang J, Cheng J, Zhang B, et al. Epidemiological and clinical features of asymptomatic patients with SARS-CoV-2 infection. *J Med Virol* 2020;92(10):1884–9.
- [105] Zhu Y, Gao ZH, Liu YL, Xu DY, Guan TM, Li ZP, et al. Clinical and CT imaging features of 2019 novel coronavirus disease (COVID-19). *J Infect* 2020;81(1):147–78.
- [106] Lei P, Huang Z, Liu G, Wang P, Song W, Mao J, et al. Clinical and computed tomographic (CT) images characteristics in the patients with COVID-19 infection: what should radiologists need to know? *J Xray Sci Technol* 2020;28(3):369–81.
- [107] Zhang J, Liu Z-H, Luo X-H, Xi Y, Ren Z-Q, Li Y-N, et al. Clinical hallmarks of 13 COVID-19 patients revealing SAA biomarker. Available at SSRN 3546066. 2020.
- [108] Yang H, Sun G, Tang F, Peng M, Gao Y, Peng J, et al. Clinical features and outcomes of pregnant women suspected of coronavirus disease 2019. *J Infect* 2020;81(1):e40–4.
- [109] Chen J, Zhang ZZ, Chen YK, Long QX, Tian WG, Deng HJ, et al. The clinical and immunological features of pediatric COVID-19 patients in China. *Genes Dis* 2020. In press.
- [110] Chate RC, Fonseca EKUN, Passos RBD, da Silva Teles GB, Shoji H, Szarf G. Presentation of pulmonary infection on ct in covid-19: initial experience in Brazil. *J Bras Pneumol* 2020;46(2).
- [111] Cheng Z, Lu Y, Cao Q, Qin L, Pan Z, Yan F, et al. Clinical features and chest CT manifestations of coronavirus disease 2019 (COVID-19) in a single-center study in Shanghai, China. *AJR Am J Roentgenol* 2020:1–6.
- [112] Zhu L, Wang J, Huang R, Liu L, Zhao H, Wu C, et al. Clinical characteristics of a case series of children with coronavirus disease 2019. *Pediatr Pulmonol* 2020;55(6):1430–2.
- [113] Xia XY, Wu J, Liu HL, Xia H, Jia B, Huang WX. Epidemiological and initial clinical characteristics of patients with family aggregation of COVID-19. *J Clin Virol* 2020;127:104360.
- [114] Qiu L, Liu X, Xiao M, Xie J, Cao W, Liu Z, et al. SARS-CoV-2 is not detectable in the vaginal fluid of women with severe COVID-19 infection. *Clin Infect Dis* 2020;71(15):813–7.
- [115] Lo IL, Lio CF, Cheong HH, Lei Cl, Cheong TH, Zhong X, et al. Evaluation of SARS-CoV-2 RNA shedding in clinical specimens and clinical characteristics of 10 patients with COVID-19 in Macau. *Int J Biol Sci* 2020;16(10):1698–707.
- [116] Agostini A, Floridi C, Borgheresi A, Badaloni M, Esposto Pirani P, Terilli F, et al. Proposal of a low-dose, long-pitch, dual-source chest CT protocol on third-generation dual-source CT using a tin filter for spectral shaping at 100 kVp for Coronavirus Disease 2019 (COVID-19) patients: a feasibility study. *Radiol Med* 2020;125(4):365–73.
- [117] Jocker C, Chung JH, Ackman JB, Carter B, Colletti PM, Crabtree TD, et al. ACR Appropriateness Criteria® acute respiratory illness in immunocompetent patients. *J Am Coll Radiol* 2018;15(11s):S240–s51.
- [118] McComb BL, Chung JH, Crabtree TD, Heitkamp DE, Iannettoni MD, Jocker C, et al. ACR Appropriateness Criteria® routine chest radiography. *J Thorac Imaging* 2016;31(2):W13–5.
- [119] ACR recommendations for the use of chest radiography and computed tomography (CT) for suspected COVID-19 infection. Available from <http://www.acr.org/Advocacy-and-Economics/ACR-Position-Statements/Recommendations-for-Chest-Radiography-and-CT-for-Suspected-COVID19-Infection>; 2020.
- [120] Zu ZY, Jiang MD, Xu PP, Chen W, Ni QQ, Lu GM, et al. Coronavirus disease 2019 (COVID-19): a perspective from China. *Radiology* 2020;200490.

- [121] ACR recommendations for the use of chest radiography and computed tomography (CT) for suspected COVID-19 infection. Available from, <http://www.acr.org/Advocacy-and-Economics/ACR-Position-Statements/Recommendations-for-Chest-Radiography-and-CT-for-Suspected-COVID19-Infection>; 2020.
- [122] Zhu J, Zhong Z, Li H, Ji P, Pang J, Li B, et al. CT imaging features of 4121 patients with COVID-19: a meta-analysis. *J Med Virol* 2020;92(7):891–902.
- [123] Al-Tawfiq JA, Memish ZA. Diagnosis of SARS-CoV-2 infection based on CT scan vs. RT-PCR: reflecting on experience from MERS-CoV. *J Hosp Infect* 2020;105(2):154–5.
- [124] Hosseiny M, Kooraki S, Gholamrezanezhad A, Reddy S, Myers L. Radiology perspective of Coronavirus Disease 2019 (COVID-19): lessons from Severe Acute Respiratory Syndrome and Middle East Respiratory Syndrome. *AJR Am J Roentgenol* 2020;1–5.
- [125] Albarello F, Pianura E, Di Stefano F, Cristofaro M, Petrone A, Marchioni L, et al. 2019-novel Coronavirus severe adult respiratory distress syndrome in two cases in Italy: an uncommon radiological presentation. *Int J Infect Dis* 2020;93:192–7.
- [126] Hao W. Clinical features of atypical 2019 novel coronavirus pneumonia with an initially negative RT-PCR assay. *J Infect* 2020;80(6):671–93.
- [127] Hao W, Li M, Huang X. First atypical case of 2019 novel coronavirus in Yan'an, China. *Clin Microbiol Infect* 2020;26:952–3 [S1198-743X(20)30091-4].
- [128] Qu J, Yang R, Song L, Kamel IR. Atypical lung feature on chest CT in a lung adenocarcinoma cancer patient infected with COVID-19. *Ann Oncol* 2020;31(6):825–6.
- [129] Wang W-G, Hu H, Song L, Gong X-M, Qu Y-J, Lu Z-Y. Image of pulmonary and diagnosis of atypical novel coronavirus (2019-nCoV) infected pneumonia: case series of 14 patients. *New Med* 2020;30(1):7–9.
- [130] Sun P, Qie S, Liu Z, Ren J, Xi J. Clinical characteristics of 5732 patients with 2019-nCoV infection. Available at SSRN (accessed March 17, 2020). 2020.
- [131] Sun P, Qie S, Liu Z, Ren J, Li K, Xi J. Clinical characteristics of hospitalized patients with SARS-CoV-2 infection: a single arm meta-analysis. *J Med Virol* 2020. <https://doi.org/10.1002/jmv.25735>.
- [132] Wang Y, Dong C, Hu Y, Li C, Ren Q, Zhang X, et al. Temporal changes of CT findings in 90 patients with COVID-19 pneumonia: a longitudinal study. *Radiology* 2020;200843.
- [133] Huang P, Liu T, Huang L, Liu H, Lei M, Xu W, et al. Use of chest CT in combination with negative RT-PCR assay for the 2019 novel coronavirus but high clinical suspicion. *Radiology* 2020;200330.
- [134] Xie X, Zhong Z, Zhao W, Zheng C, Wang F, Liu J. Chest CT for typical 2019-nCoV pneumonia: relationship to negative RT-PCR testing. *Radiology*. 2020;200343.
- [135] Zhu N, Zhang D, Wang W, Li X, Yang B, Song J, et al. A novel coronavirus from patients with pneumonia in China, 2019. *N Engl J Med* 2020;382(8):727–33.
- [136] Holshue ML, DeBolt C, Lindquist S, Lofy KH, Wiesman J, Bruce H, et al. First case of 2019 novel coronavirus in the United States. *N Engl J Med* 2020;382(10):929–36.
- [137] Lai CC, Shih TP, Ko WC, Tang HJ, Hsueh PR. Severe acute respiratory syndrome coronavirus 2 (SARS-CoV-2) and coronavirus disease-2019 (COVID-19): the epidemic and the challenges. *Int J Antimicrob Agents* 2020;55(3):105924.
- [138] Bernard Stoecklin S, Rolland P, Silue Y, Mailles A, Campese C, Simondon A, et al. First cases of coronavirus disease 2019 (COVID-19) in France: surveillance, investigations and control measures, January 2020. *Euro Surveill* 2020;25(6):2000094.
- [139] Hellewell J, Abbott S, Gimma A, Bosse NI, Jarvis CI, Russell TW, et al. Feasibility of controlling COVID-19 outbreaks by isolation of cases and contacts. *Lancet Glob Health* 2020;8(4):e488–48s96.