



Case report

Pediatric huaiyangshan virus infection: A case report with literature review

Chun-Hui Zhu^a, Dong Xu^b, Wei Liu^c, Di Guo^b, Qin Ning^b, Guang Chen^{b,*}^a Department of Infectious Disease, Children's Hospital of Jiangxi Province, Nanchang, China^b Department of Infectious Disease, Tongji Hospital of Tongji Medical College, Huazhong University of Science and Technology, Wuhan, China^c The Public Health Department, Tongji Hospital of Tongji Medical College, Huazhong University of Science and Technology, Wuhan, China

ARTICLE INFO

Keywords:

Children

Novel bunyavirus

Severe fever with thrombocytopenia syndrome

ABSTRACT

To define the clinical manifestations and laboratory characteristics of pediatric severe fever with thrombocytopenia syndrome (SFTS) case caused by a novel bunyavirus, we retrospectively analyzed a pediatric case of viral SFTS in a 13 year old successfully managed and confirmed to be due to the novel bunyavirus now referred to as Huaiyangshan virus. A literature review of related cases was performed. Our pediatric case was a 13.3-year-old middle school student with no underlying disease. Major clinical features included a fever with chills, headache, and dizziness. The patient's epidemiology showed he had close contact with his grandfather who had a confirmed, novel bunyavirus infection. Symptomatic therapy was given at admission. The patient's temperature and platelet count returned to normal by days 7 and 10, respectively, and he was discharged from the hospital with an improved condition. A literature search was performed using "severe fever with thrombocytopenia syndrome" and "bunyavirus" as keywords, but few relevant reports were found. Novel bunyavirus infection can be transmitted through close contact. Confirmed cases should be kept in isolation. Clinical manifestations were characterized by aspecific symptoms, such as fever and chills. In some cases, platelet counts may remain normal in the early phase of the disease, and fever may not present throughout the entire illness period. Thus, misdiagnosis is possible. Surveillance and vigorous follow-up should be carried out in children with tick bites or in close contact with an index patient in high-risk areas during peak season.

Introduction

Reports of severe fever with thrombocytopenia syndrome (SFTS) induced by Huaiyangshan virus infection have mostly been focused on adult cases. A high incidence of bunyavirus infection has been observed recently in China, accompanied by rather severe and fatal cases. However, pediatric cases are rarely found over the same period. Herein, we describe a pediatric case with Huaiyangshan virus infection, as well as speculate on the route of transmission and possible factors which play a role in the different clinical manifestations between adult and pediatric cases. Studies on Huaiyangshan virus infection and SFTS previously reported in the literature were also reviewed.

Case presentation

A 13-year-old, male, middle school student presented with sudden onset of fever on September 29, 2014, with a high temperature of 40 °C, accompanied by chills, pharyngeal discomfort, headache, dizziness, weakness, and loss of appetite. No cough, sputum production, vomiting, diarrhea, myalgias or urinary irritation were observed. According to his

parents, he had no prior positive medical history except for a high fever at 6-year-old. Additionally, he had not recently consumed seafood or raw meat, nor had he been exposed to indoor renovation or painting, close contact with domesticated animals, or tick bite. He was brought to an outpatient clinic on September 30, where he was given a preliminary diagnosis of an upper respiratory infection. However, his fever did not regress after treatment with an oral cephalosporin antimicrobial for 3 days, and he was admitted to the Puai Hospital in Wuhan city on October 2 for further treatment. Physical examination upon outpatient visit revealed harsh breathing sounds. No positive findings were found by routine blood exam and chest X-ray. He was diagnosed with bronchitis and treated with Azithromycin (10 mg/kgd) via intravenous drip from October 2 to October 4. However, his condition did not ameliorate. Therefore, he was hospitalized 7 d after disease onset (October 4, 2014).

Physical examination upon admission revealed a 39.9 °C fever, pulse of 105 beats/min, respiration rate of 22 breaths/min, and blood pressure of 101/51 mmHg. Swollen lymph nodes were palpable in the axillary regions. No petechiae or ecchymosis were observed, nor was there any overt sign of jaundice, and neurological tests were negative.

* Corresponding author at: Department of Infectious Disease, Tongji Hospital of Tongji Medical College, Huazhong University of Science and Technology, Wuhan 430000, China.
E-mail address: widchain@163.com (G. Chen).

Laboratory tests indicated thrombocytopenia (26×10^9 platelets/L), slightly increased alanine aminotransferase (66 U/L), aspartate aminotransferase (53 U/L), and high sensitive C-reaction protein (110.9 mg/L) levels. CT scan of the chest showed swollen lymph nodes in the axillae, little pleural effusion in interpleural space. Ultrasound imaging demonstrated gall bladder wall edema. EKG was normal. Given his clinical manifestations and laboratory results, cefotaxime sodium and sulbactam sodium(150 mg/kgd)and magnesium isoglycyrrhizinate (0.1 g/d) were prescribed to control the infection, protect the liver, and lower transaminase levels. Dexamethasone (5 mg, once a day for 5 d) was given to control inflammation after bone marrow puncture (after receiving informed consent), along with amino acid injection(12.5 g, once/day) and pantoprazole sodium(40 mg, once/day) intravenous infusion for supportive and symptomatic treatments.

The second day after admission, the patient's platelet count reached a nadir at 18×10^9 platelets/L. Four days after admission, his platelet count began to rise. Bone marrow cell morphology suggested hyperplasia, a normal neutrophil ratio, slightly elevated lymphocyte ratio (21%, all mature lymphocytes) and platelets scattered in small clusters. After further inquiry, the mother added that the patient's grandfather had a fever approximately 1 month prior; the grandfather's condition continued to deteriorate progressively after hospitalization (he eventually died). The grandfather had always collected tea leaves before his illness onset, and skin damage was found at admission. The parents pointed that SFTS was the grandfather's suspected diagnosed, and the Hubei Province Center for Disease Control and Prevention (CDC) were notified to collect specimens of the grandfather. Our patient visited his grandfather once, was in close contact with him during his hospitalization, and helped clean his grandfather's clothes 4 d before the pediatric case illness onset. We alerted the CDC and exert bedside isolation immediately. The pediatric patient began to recover in the following days; his ALT recovered to normal levels by October 8, fever subsided by October 10, coagulation function returned to normal on October 12, and platelet counts recovered by October 13 (Figs. 1 and 2).

During hospitalization of the pediatric patient, the grandfather's novel bunyavirus infection was confirmed by reverse transcription PCR. Seventeen days after admission, the boy was discharged at the request of his parents. Subsequent clinical visits at 4, 8, and 24 weeks revealed complete recovery of the pediatric patient without sequelae after being released. One month after discharge, the novel bunyavirus was isolated from acute-phase serum of the boy, further corroborating the diagnosis.

Discussion

The novel bunyavirus which induced SFTS in our patient was classified as a new member of genus Phlebovirus, family Bunyaviridae. So far, surveillance data show bunyaviral SFTS infection mainly occurs in foothills of several provinces in central and north-eastern of China, as well as in Japan and South Korea. Wild birds infected with bunyavirus or carrying bunyavirus-infected ticks might

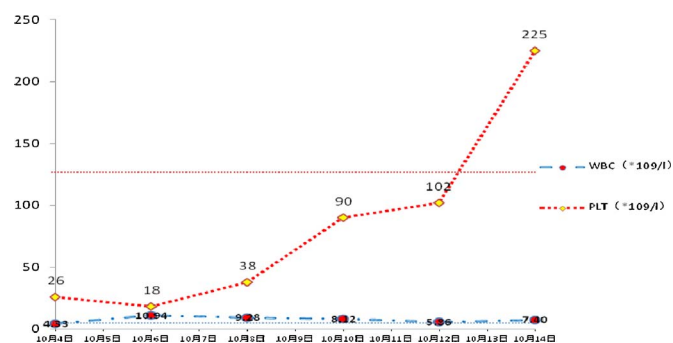


Fig. 1. Dynamic profiles of laboratory parameters (white blood cell and platelet counts) in the pediatric patient. The normal ranges of laboratory parameters are delineated as horizontal dotted line of corresponding color.

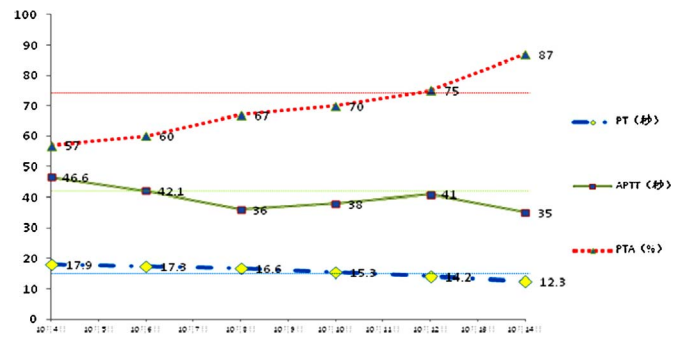


Fig. 2. Dynamic profiles of laboratory parameters (plasma thromboplastin, activated partial thromboplastin time, and prothrombin activity) in the pediatric patient. The normal ranges of laboratory parameters are delineated as horizontal dotted line of corresponding color.

contribute to the long-distance spread of bunyavirus via migratory flyways [1]. Infection cases are mostly reported from March to November and peak between April and July. Those adults performing outdoor activities or field work have a greater chance of being infected [2–4]. In severe cases, the patient's condition deteriorates rapidly with respiratory failure, nervous system damage, diffuse intravascular clotting, and eventual death. The fatality rate ranges from 12 to 30% [5], with severe economic and social consequences. Recently more and severer cases have been admitted to our hospital than in previous years, which should be given considerable attention.

Herein, we described a pediatric case of novel bunyavirus infection exhibiting chills, headache, dizziness, and pharyngeal discomfort. The patient's condition did not improve after 1 week, and viral upper respiratory infection by influenza or rhinoviruses could not explain his symptoms. Treatment with a cephalosporin and azithromycin did not alleviate his fever, thereby ruling out community acquired pneumonia. Moreover, Kawasaki disease was excluded based on physical examination. Meanwhile, epidemiological investigation alluded to a suspected novel bunyavirus infection. With timely, supportive, and symptomatic treatment, aminotransferase levels, coagulation function, and platelet counts returned to normal 11, 15, and 17 d after admission, respectively, and the patient was discharged on day 18. Finally, viral nucleic acid detection provided a definitive diagnosis of viral SFTS.

Until now, there have only been five pediatric cases of this novel bunyavirus infection reported in detail. Our patient did not present with neurological manifestations, hemorrhagic symptoms and impaired renal function, which is consistent with the results reported by Ma [6] and Wang [7]. Of the now six reported pediatric patients, two experienced tick bites, while the other four had been in close contact with novel bunyavirus infected family members. All six pediatric patients experienced sudden onset fever and thrombocytopenia with/without leukopenia. Moreover, their clinical manifestation was milder than that of the adult patients, and they had a better prognosis. Given that our pediatric case was infected by the same virus strain as his grandfather, are there influencing factors contribute to the contradictory clinical outcomes other than differences in virus loading, antigen drift, and/or up- or downregulation of some genes or proteins. Furthermore, why pediatric cases are rare, regardless of season and region, remains unknown. Possible factors underlying the milder clinical symptoms and better prognosis of pediatric versus adult patients are discussed below.

Previous epidemiological field investigations and ecological surveys have suggested viral SFTS can be detected in the serum of domesticated animals surrounding index patients, such as cattle, dogs, chickens, goats and pigs [8]. Viral SFTS isolated from *Apodemus agrarius* parasitic mites and *Tabanus bovinus* nearby shared high sequence homology with those isolated from the index patients [9,10], suggesting tick, mite, and *Tabanus bovinus* are not only a host reservoir, but also biological vectors. Therefore, restricting the amount of time spent on working in

Table 1
Main clinical and laboratory parameters at admission for SFTS patients.

Characteristics	Pediatric patients			Adult patients	
	this case	Ma et al. [6] (n = 1)	Wang et al. [7] (n = 4)	Yu et al. [12] (n = 154)	Zhou et al. [13] (n = 68)
Demographic features	(case number)				
Sex(M:F)	1/0	0/1	2/2	68/86	33/35
Tick bite	0	0	2		4
Close contact with index SFTS patient	1	0	2		5
Other biological vector bite	0	0	0		22
Field work	0	0	0		25
positive medical history	0	0	0		27
Clinical manifestations on admission	(n = 81)				
	(case number with positive syndrome/total case number)				
Fever	1/1	1/1	4/4	81/81	68/68
Throat congestion	1/1	1/1		10/81	
Fatigue	1/1	0/1	4/4	53/81	68/68
Dizziness	1/1	0/1	0/4		
Myalgia	0/1	0/1	0/4	22/81	62/68
Headache	1/1	0/1	0/4	10/81	28/68
Coma	0/1	0/1	0/4	4/69	13/68
Nausea	0/1	0/1	2/4	56/81	48/68
Vomiting	0/1	0/1	1/4	38/81	36/68
Diarrhea	0/1	0/1	1/4	34/81	36/68
Cough	0/1	0/1	0/4	8/81	
Lymphadenopathy	1/1	0/1	1/4	23/69	30/68
Petechiae	0/1	0/1	0/4	5/69	
Melena	0/1	0/1	0/4	4/19	32/68
Consciousness disorder	0/1	0/1	0/4	22/69	27/68
laboratory findings in patients with SFTS on admission	(case number with positive result/total case number)				
thrombocytopenia	1/1	1/1	3/4	69/73	68/68
leukocytopenia	0/1	0/1	4/4	64/74	55/68
elevated ALT	1/1	1/1	2/4	53/64	62/68
elevated AST	1/1	1/1	1/4	59/63	62/68
elevated LDH	0/1	0/1	3/4	49/51	68/68
elevated CK	0/1	0/1	2/4	25/49	
elevated CK MB	0/1	0/1		28/47	
Prolonged APTT	1/1			5/12	
proteinuria	0/1	0/1	0/4	36/43	64/68
hematuria	0/1	0/1	0/4	27/46	41/68
Outcome	(case number/total case number)				
Relapse	1/1	1/1	1/1		
Death	0/1	0/1	0/1	21/171	13/68

the field, stock farming, and animal husbandry, as well as greater attention to precautionary measures, will reduce the environmental risk of viral infection.

A retrospective study of 66 viral SFTS-infected adult patients from January 2012 to December 2015 exhibiting similar hemorrhagic tendency and neurological deficits showed elevated levels of lactate dehydrogenase (LDH; 95.5%), creatine kinase (CK; 68.2%), blood urea nitrogen (31.8%), and creatinine (42.4%) [unpublished results]. All patients were positive for urine proteins, which is in agreement with results reported by Xia et al. [11]. LDH, CK, CK-MB isoenzyme fraction, troponin, and myohemoglobin maintained normal levels in our pediatric case, while urine protein remains negative. Of the five pediatric cases discussed in the previous section, LDH and CK levels were elevated in three (50%) and two (33.3%) cases, respectively, but the average levels were lower than that in adult patients. Blood urea

nitrogen and creatinine were normal in all six pediatric cases, and urine protein was positive in only one case (Table 1). We speculate that the different virulence of different viral strains, together with no underlying diseases, no smoking or drinking addiction, better nutritional intake, and more rest are possible reasons for the milder symptoms and better prognosis seen in pediatric patients.

After invasion of host cells, SFTS replicates and amplifies using complementary RNA as a template after initial transcription protein synthesis. Meanwhile, host signal pathways are immediately activated, which upregulate synthesis of interferon (IFN)-α4 and IFN-β. IFNs are cytokines known to act as a first line of defense against pathogens through the adaptive immune response. Appropriate upregulation of IFNs at the transcriptional level leads to production of antiviral proteins [14]. With respect to bunyavirus, nonstructural viral proteins encoded on the S-segment efficiently inhibit IFN-α/β synthesis [15]. Bunyavirus has been shown to suppress activation of nuclear factor-κB and reduce production of type I IFNs [16]. After the viral infection, the battle between immune clearance and viral evasion results in the release of proinflammatory or toxic compounds, which recruits large quantities of chemokines, a cascading effect that leads ultimately to various clinical symptoms with different degrees of severity. Because the immune system is still relatively immature in children, repeated antigenic stimulation is required to achieve a complex maturation stage upon viral infection [17]. In the same way, damaged liver function rarely occurs in children with hepatitis B virus infection. Maybe more limited quantity or lower virulence the virus produces less fragments and components during the host defense, smaller quantities of proinflammatory or toxic compounds are released, milder clinic manifestation and better outcome. The exact mechanism remains to be clarified by further research.

In our case, aspecific symptoms, such as fever, headache, etc., and a normal platelet count in the early phase made it difficult to precisely diagnose the patient. A report by Ye et al. [18] describes a patient who never developed a fever during the entire pathogenic process; therefore, epidemiological tracing and a detailed history are especially important. Until now, there has been no specific treatment for viral SFTS other than supportive and symptomatic treatments, such as plenty of rest, as well as monitoring patient consciousness, hemorrhagic tendency, fever, respiratory rate, urinary volume, blood pressure, platelet count, coagulation and kidney function, blood gas, lactic acid, and myocardial enzyme levels. In addition, hypothermal measures and fluid replacement therapy are recommended. Glucocorticoid treatment seemed to produce clinical improvement in our pediatric case, as well as in adult patients. However, there are currently no guidelines or consensus regarding the indication, timing, or drug type and dosage, and randomized controlled trials with large sample numbers are required.

Herein, the patient's platelet count remained normal in the early phase of infection, began to drop after 7 d, and quickly rose back to normal levels after supportive treatment. Hence, the decline in platelet counts observed in the current study may be transitory. Above all, the patient's history should be extensively reviewed, together with careful physical examination, epidemiological tracing, and monitoring of platelet counts when fever and/or thrombocytopenia occurs in children during the peak season. Furthermore, suspected cases should be isolated and promptly reported to the CDC. Strengthening the management of patient visits and providing timely and vigorous symptomatic and supportive therapy is very important to the prevention and treatment of pediatric cases of bunyavirus infection.

Funding

No funding was provided by any research institute.

Ethical approval

None.

Competing interests

We have no conflicts of interest to declare.

Acknowledgments

This study was supported in part by the Organization Department of the Central Committee of the Communist Party of China 2015 “sunshine of the west” visiting scholar program. The views expressed are those of the authors.

References

- [1] Li Z, Bao C, Hu J, Liu W, Wang X, Zhang L, et al. Ecology of the tick-borne phlebovirus causing severe fever with thrombocytopenia syndrome in an endemic area of China. *PLoS Negl. Trop. Dis.* 2016;10(4):e0004574. <http://dx.doi.org/10.1371/journal.pntd.0004574>.
- [2] You AG, Yang JH, et al. Analysis of the epidemiological and pathogenic characteristics of severe fever with thrombocytopenia syndrome (SFTS) in Henan Province of China, 2012–2013. *J. Pathol. Biol.* 2014;9(6):552–5.
- [3] Zhang HL, Sung Y, Wang JJ. Investigation on foci severe fever with thrombocytopenia syndrome and human granulocytic anaplasmosis in Lujiang County. *Chin. J. Dis. Control Prev.* 2015;19(3):273–6.
- [4] Hu BS, Hu HP. Analysis on epidemiological features of severe fever with thrombocytopenia syndrome among 77 cases. *Chin. Prev. Med.* 2014;15(6):601–3.
- [5] Li Y, Zhou H, Mou D, et al. Epidemiological characteristics of severe fever with thrombocytopenia syndrome in China from 2011 to 2013. *Clin. J. Epidemiol.* 2015;36(6):598–602.
- [6] Ma T, Sun JM, Chen LF, et al. A pediatric case of severe fever with thrombocytopenia syndrome in Zhejiang Province, China. *J. Clin. Virol.* 2015;72:85–7.
- [7] Wang LY, Cui N, Lu QB, et al. Severe fever with thrombocytopenia syndrome in children: a case report. *BMC Infect. Dis.* 2014;14:366.
- [8] Niu GY, Li JD, Liang MF, et al. Severe fever with thrombocytopenia syndrome virus among domesticated animals, China. *Emerg. Infect. Dis.* 2013;19(5):756–63.
- [9] Nia HX, Yang F, Li YD, et al. Apodemusagrarius is a potential natural host of severe fever with thrombocytopenia syndrome (SFTS)-causing novel bunyavirus. *J. Clin. Virol.* 2015;71:82–8.
- [10] Wang QQ, Ge HM, Li ZF, et al. Vector research of severe fever with thrombocytopenia syndrome virus in gamasid mites and chigger mites. *Chin. J. Vector Biol. Control* 2012;23(5):452–4.
- [11] Xia LL, Xie QX, Li X. Clinical analysis of 26 cases of fever with thrombocytopenia syndrome in new bunyavirus infection patients. *Anhui Med. J.* 2015;36(1):59–61.
- [12] Yu XJ, Liang MF, Zhang SY, et al. Fever with thrombocytopenia associated with a novel bunyavirus in China. *N. Engl. J. Med.* 2011;364(16):1523–32.
- [13] Zhou LL, Liu B, Chang An, et al. Clinical characteristics and prognosis of novel bunyavirus infection: 68-case report. *Clin. J. Infect. Dis.* 2015;33(2):75–8.
- [14] Qu B, Qi X, Wu X, et al. Suppression of the interferon and NF- κ B responses by Severe fever with thrombocytopenia syndrome virus. *J. Virol.* 2012;86(16):8388–401.
- [15] Blakqori G, Delhaye S, Habjan M, et al. La Crosse bunyavirus nonstructure protein NSs serves to suppress the type I interferon system of mammalian hosts. *J. Virol.* 2007;81(10):4991–9.
- [16] Santiago FW, Covaleda LM, Sanchez-Aparicio MT, et al. Hijacking of RIG-I signaling proteins into virus-induced cytoplasmic structures correlates with the inhibition of type I interferon responses. *J. Virol.* 2014;88(8):4572–85.
- [17] Ozsurekci Y, Arasli M, Karadag Oncel E, et al. Can the mild clinical course of Crimean-Congo hemorrhagic fever in children be explained by cytokine responses? *J. Med. Virol.* 2013;85(11):1955–9.
- [18] Ye L, Shang XP, Wang ZF, et al. A case of severe fever with thrombocytopenia syndrome caused by a novel bunyavirus in Zhejiang, China. *Int. J. Infect. Dis.* 2015;33:199–201.