

Case Report

Thrombosis and Recanalization of Small Saccular Cerebral Aneurysm : Two Case Reports and a Suggestion for Possible Mechanism

Hyung Jun Kim, M.D., Jae Hoon Kim, M.D., Duk Ryung Kim, M.D., Hee In Kang, M.D.

Department of Neurosurgery, Eulji University, Eulji Hospital, Seoul, Korea

Reports of thrombosis and recanalization of cerebral aneurysm are rare. We report two cases of small, saccular aneurysms in which spontaneous thrombosis had occurred during the preparation for endovascular coiling. Also, we review reported cases and propose the presumed pathogenesis.

Key Words : Aneurysm · Recanalization · Thrombosis.

INTRODUCTION

The incidence of spontaneous thrombosis of cerebral aneurysm is about 1–2% of ruptured aneurysms⁷⁾. Spontaneous thrombosis of cerebral aneurysm is considered as a hemodynamically unstable status, and the natural history of giant or large aneurysm has been suggested (growth, recanalization, and even rupture or thromboembolic event)^{3,5,6,16)}. However, the reports on recanalization of small aneurysm after spontaneous thrombosis are rare, and the natural history is still unknown.

We present two cases of spontaneous thrombosis and recanalization of small saccular aneurysms, and suggest a presumed mechanism, and its clinical significance²³⁾.

CASE REPORT

Case 1

A 52-year-old woman presented to the emergency room with a sudden-onset stuporous mentality. The medical history was significant for hypertension and diabetes, for which the patient was taking oral medications. In addition, the patient was suffering from angina, and was taking 100 mg of aspirin daily.

Brain computed tomographic (CT) scans revealed a subarachnoid hemorrhage (SAH) at the basal cistern and both sylvian fissures, mainly on the left side. Three-dimensional (3D) CT re-

construction revealed an aneurysm at the basilar bifurcation and at left anterior choroidal artery. The basilar bifurcation aneurysm was 10×10 mm in size, with a broad neck (9 mm). The left anterior choroidal artery aneurysm was 3×6 mm in size, with an irregular shape (Fig. 1A). Based on the distribution of the hematoma and the shaped of aneurysms, we considered the left anterior choroidal artery aneurysm to be ruptured and decided to perform an emergency endovascular coil embolization on the day of admission.

Under general anesthesia, we performed induced hypotension below 60 mm Hg of mean arterial pressure. Baseline cerebral angiography revealed that the left anterior choroidal artery aneurysm had decreased in size compared to that found in the 3D angiography (Fig. 1B, C). Additionally, we could not observe contrast filling from the distal part of the aneurysm. Because partial occlusion of the aneurysm might increase the risk of rebleeding after thrombolysis, we decided not to perform coil embolization¹⁴⁾. Also, given the patient's conditions (aspirin medication and pulmonary edema combined with pneumonia), we could not perform aneurysm clipping at early stage.

Follow-up angiography 7 days later demonstrated complete recanalization of the distal part of the aneurysm (Fig. 1D, E). Accordingly, we performed surgical clipping, and the patient recovered and was discharged with a Glasgow outcome scale (GOS) score of 5.

• Received : October 4, 2013 • Revised : December 23, 2013 • Accepted : May 15, 2014

• Address for reprints : Jae Hoon Kim, M.D.

Department of Neurosurgery, Eulji University, Eulji Hospital, 14 Hangeulbiseok-gil, Nowon-gu, Seoul 139-872, Korea

Tel : +82-2-970-8266, Fax : +82-2-979-8268, E-mail : grimi2@hanmail.net

• This is an Open Access article distributed under the terms of the Creative Commons Attribution Non-Commercial License (<http://creativecommons.org/licenses/by-nc/3.0>) which permits unrestricted non-commercial use, distribution, and reproduction in any medium, provided the original work is properly cited.

Case 2

A 58-year-old man was admitted to our neurosurgical department for the evaluation of headache and dizziness that occurred several months earlier. The patient's past medical history was unremarkable. On admission, the patient had no neurological signs or abnormal hematological findings including coagulation time.

Brain 3D CT angiography revealed a 3×1.7 mm aneurysm in the basilar bifurcation, and a 3×1.5 mm aneurysm in the proximal middle cerebral artery (MCA). We decided to perform endovascular coil embolization with consent from family members.

Under general anesthesia, we performed endovascular coiling. Baseline angiography revealed small aneurysm in the proximal MCA (Fig. 2A). We placed a guiding catheter into the proximal internal cerebral artery, and the microcatheter was placed in the proximal MCA. Subsequent road map and angiography revealed complete disappearance of the right MCA aneurysm without evidence of vasospasm (Fig. 2B). Therefore, we only performed a coil embolization of the basilar bifurcation aneurysm.

The follow-up angiography 48 days later confirmed complete recanalization of the right MCA aneurysm (Fig. 2C). We performed coil embolization without any complications.

DISCUSSION

Several mechanisms have been reported to contribute to spontaneous thrombosis of cerebral aneurysms. We show a summary of reported cases of spontaneous thrombosis (Table 1). It is well known that spontaneous thrombosis in giant or large aneurysm is related to the ratio of aneurysm volume to neck size, as have been demonstrated in an animal model of aneurysm¹⁾. The blood flow within giant or large aneurysms is slow and turbulent, which may induce spontaneous thrombosis³⁾.

However, hemodynamic or local factors seem to be more important in spontaneous thrombosis of small aneurysms. Spetzler et al.²⁰⁾ reported a case of small aneurysm that disappeared and reappeared. They did refer to the possible effect of anti-fibrinolytic agent or vasospasm. The angiographic procedure itself has been also proposed. Non-ionic contrast media has been reported

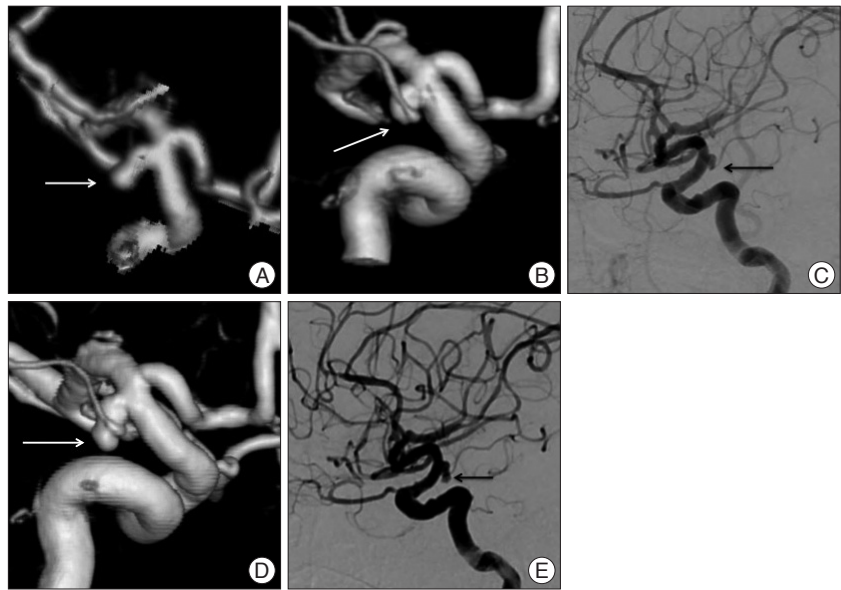


Fig. 1. Brain 3-dimensional computed tomographic scan (A) reveals left anterior choroidal artery aneurysm, 3×6 mm in size (white arrow). Rotational angiography (B) and left lateral internal carotid artery angiography (C) shows a partial thrombosis of the distal part of the aneurysm (black and white arrow) compared to the findings of previous angiography. Follow up angiography (D and E) 7 days later demonstrates recanalization of the thrombosed aneurysm (black and white arrow).

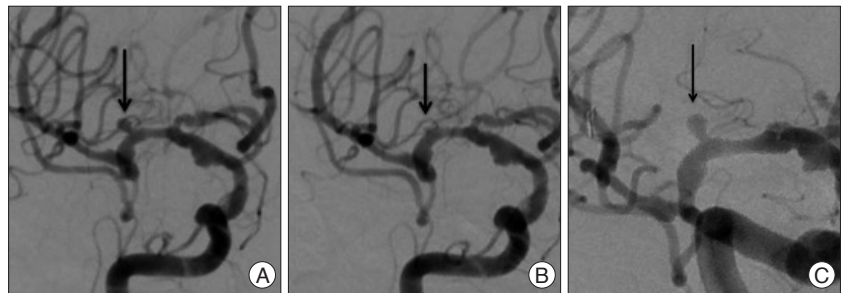


Fig. 2. Cerebral angiography (A) reveals proximal middle cerebral artery aneurysm, 3×1.5 mm in size (black arrow). Subsequent angiography (B) shows complete disappearance of the aneurysm (black arrow). Follow up angiography (C) seven weeks later demonstrates complete recanalization of the aneurysm (black arrow).

to have thrombogenic potential⁸⁾. Systemic hypotension was postulated as a potential mechanism for spontaneous thrombosis²⁾. Nakajima et al.¹⁷⁾ suggested aneurysmal shape and the surrounding clot as putative factors related to the intermittent appearance of the aneurysm.

In this report, we were uncertain as to the mechanism of spontaneous thrombosis in these small aneurysms, but have considered two possibilities. Induced hypotension under general anesthesia might have played some role in the spontaneous thrombosis. We usually adopt systemic hypotension (mean arterial pressure below 60 mm Hg) after the induction of general anesthesia in the patient with ruptured intracranial aneurysm. We presumed that sudden decrease of blood pressure might result in circulatory delay and spontaneous thrombosis of ruptured aneurysm under increased intracranial pressure. Bohmfalk and Stroy²⁾ postulated systemic hypotension as a possible mechanism for angiographic disappearance of aneurysm. The other was the

Table 1. Presumed mechanisms of spontaneous thrombosis of cerebral aneurysms in published reports

Years (author)	Size and location of the aneurysm	Pathogenesis of spontaneous thrombosis	
		Ruptured aneurysm	Unruptured aneurysm
1974 (Spetzler et al.) ²⁰⁾	Small, frontopolar artery	Anti-fibrinolytics/vasospasm	
1980 (Bohmalk and Story) ²⁾	Small, ACA	Systemic hypotension	
1992 (Hamilton and Dold) ¹⁰⁾	Small, A-com artery	Vasospasm	
1995 (Brownlee et al.) ³⁾	Large, A-com artery		Large volume to orifice ratio
2000 (Nakajima et al.) ¹⁷⁾	Small, distal ACA	Aneurysmal shape/the surrounding clot	
2001 (Ohta et al.) ¹⁹⁾	Large, distal SCA		Large volume to orifice ratio
2003 (Cohen et al.) ⁶⁾	Large, MCA	Surrounding hematoma	
2004 (Hans et al.) ¹¹⁾	Small, ICA		Change in cerebral hemodynamics
2007 (Cohen et al.) ⁵⁾	Small, PICA		Not commented
	Small, P-com artery		
	Large, A-com artery		
2007 (Greenberg et al.) ⁹⁾	Small, MCA	Not commented	
2007 (Nakau et al.) ¹⁸⁾	Small, SCA	Clot formation within the aneurysm	
2007 (Jayakumar et al.) ¹³⁾	Large, P-com artery (R)	Endothelial injury due to contrast media/vasospasm	Endothelial injury due to contrast media/vasospasm of parent artery due to mass effect of thrombosed aneurysm
	Small, basilar artery (UR)		
	Giant, ICA (UR)		
	Small, basilar artery (R)		
2009 (Hassan et al.) ¹²⁾	Small, ACA	Angiography procedure	
2009 (Su et al.) ²¹⁾	Small, A-com artery	Sluggish intra-aneurysmal flow	
2012 (Choi et al.) ⁴⁾	Small, MCA		Angle of inclination between aneurysm and neck
2012 (Kim et al.) ¹⁵⁾	Large, MCA		Large volume to orifice ratio
Our case	Small, Acho artery (R)	Induced hypotension during general anesthesia	Blood flow stagnation due to catheter
	Small, MCA (UR)		

ACA : anterior cerebral artery, A-com : anterior communicating, SCA : superior cerebellar artery, MCA : middle cerebral artery, ICA : internal carotid artery, PICA : posterior inferior cerebellar artery, P-com : posterior communicating, R : ruptured, UR : unruptured, Acho : anterior choroidal

result of blood flow stagnation from the microcatheter during endovascular procedure. In case 2, spontaneous thrombosis occurred before the selection of the aneurysm by microcatheter and microguidewire. Also, there was no angiographic evidence of vasospasm. Accordingly, we presumed that blood flow stagnation due to the microcatheter caused spontaneous thrombosis in small aneurysm. Szajner et al.²²⁾ suggested vasospasm in addition to flow arrest from microcatheter and microguidewire during coil embolization as a possible etiology of spontaneous thrombosis in small aneurysms.

In summary, spontaneous thrombosis in ruptured small saccular aneurysms may attribute to anti-fibrinolytic agent, vasospasm, systemic hypotension, surrounding clot, and contrast media. The contrast media and blood flow stagnation may be possible etiologies in unruptured cases. Especially, spontaneous thrombosis of ruptured small aneurysms may occur during the early period after SAH and could be recanalized within the next few weeks^{9,17)}.

CONCLUSION

Spontaneous thrombosis of small saccular aneurysm is attrib-

uted to a number of factors. Induced hypotension and endovascular instruments may play a role in the occurrence of spontaneous thrombosis in small aneurysm.

References

- Black SP, German WJ : Observations on the relationship between the volume and the size of the orifice of experimental aneurysms. *J Neurosurg* 17 : 984-990, 1960
- Bohmalk GL, Story JL : Intermittent appearance of a ruptured cerebral aneurysm on sequential angiograms. Case report. *J Neurosurg* 52 : 263-265, 1980
- Brownlee RD, Tranmer BI, Sevick RJ, Karmy G, Curry BJ : Spontaneous thrombosis of an unruptured anterior communicating artery aneurysm. An unusual cause of ischemic stroke. *Stroke* 26 : 1945-1949, 1995
- Choi CY, Han SR, Yee GT, Lee CH : Spontaneous regression of an unruptured and non-giant intracranial aneurysm. *J Korean Neurosurg Soc* 52 : 243-245, 2012
- Cohen JE, Itshayek E, Gomori JM, Grigoriadis S, Raphaeli G, Spektor S, et al. : Spontaneous thrombosis of cerebral aneurysms presenting with ischemic stroke. *J Neurol Sci* 254 : 95-98, 2007
- Cohen JE, Rajz G, Umansky F, Spektor S : Thrombosis and recanalization of symptomatic nongiant saccular aneurysm. *Neurol Res* 25 : 857-859, 2003
- Edner G, Forster DM, Steiner L, Bergvall U : Spontaneous healing of intracranial aneurysms after subarachnoid hemorrhage. Case report. *J*

- Neurosurg* 48 : 450-454, 1978
8. Fareed J, Walenga JM, Saravia GE, Moncada RM : Thrombogenic potential of nonionic contrast media? *Radiology* 174 : 321-325, 1990
 9. Greenberg E, Janardhan V, Katz JM, Riina H, Zimmerman R, Gobin YP : Disappearance and reappearance of a cerebral aneurysm : a case report. *Surg Neurol* 67 : 186-188; discussion 188-189, 2007
 10. Hamilton MG, Dold ON : Spontaneous disappearance of an intracranial aneurysm after subarachnoid hemorrhage. *Can J Neurol Sci* 19 : 389-391, 1992
 11. Hans FJ, Krings T, Reinges MH, Mull M : Spontaneous regression of two supraophthalmic internal cerebral artery aneurysms following flow pattern alteration. *Neuroradiology* 46 : 469-473, 2004
 12. Hassan F, Taschner CA, Thines L, Lejeune JB, Pruvo JP, Leclerc X : Spontaneous thrombosis of a recurrent clipped intracranial aneurysm. *J Neuroradiol* 36 : 153-157, 2009
 13. Jayakumar PN, Ravishankar S, Balasubramaya KS, Chavan R, Goyal G : Disappearing saccular intracranial aneurysms : do they really disappear? *Interv Neuroradiol* 13 : 247-254, 2007
 14. Johnston SC, Dowd CF, Higashida RT, Lawton MT, Duckwiler GR, Gress DR, et al. : Predictors of rehemorrhage after treatment of ruptured intracranial aneurysms : the Cerebral Aneurysm Rerupture After Treatment (CARAT) study. *Stroke* 39 : 120-125, 2008
 15. Kim BJ, Kim JS, Jeon KD, Lee SI : Spontaneous complete occlusion of middle cerebral artery aneurysm : case report. *J Cerebrovasc Endovasc Neurosurg* 14 : 309-314, 2012
 16. Lee KC, Joo JY, Lee KS, Shin YS : Recanalization of completely thrombosed giant aneurysm : case report. *Surg Neurol* 51 : 94-98, 1999
 17. Nakajima Y, Yoshimine T, Mori H, Nakamuta K, Fujimura I, Sakashita K, et al. : Spontaneous disappearance and reappearance of a ruptured cerebral aneurysm : one case found in a group of 33 consecutive patients with subarachnoid hemorrhage who underwent repeat angiography. *Neurol Res* 22 : 583-587, 2000
 18. Nakau H, Nagatani H, Nakau R, Ametani T : Acute disappearance of ruptured aneurysm located near the origin of the superior cerebellar artery - case report - . *Neurol Med Chir (Tokyo)* 47 : 468-470, 2007
 19. Ohta H, Sakai N, Nagata I, Sakai H, Shindo A, Kikuchi H : Spontaneous total thrombosis of distal superior cerebellar artery aneurysm. *Acta Neurochir (Wien)* 143 : 837-842; discussion 842-843, 2001
 20. Spetzler RF, Winestock D, Newton HT, Boldrey EB : Disappearance and reappearance of cerebral aneurysm in serial arteriograms. Case report. *J Neurosurg* 41 : 508-510, 1974
 21. Su TM, Hsu SW, Chen WF, Lee TC, Cheng CH : Acute thrombosis and recanalization of a ruptured anterior communicating artery aneurysm. *J Clin Neurosci* 16 : 1077-1079, 2009
 22. Szajner M, Jargiello T, Trojanowski T, Szczerbo-Trojanowska M : Spontaneous thrombosis of the pseudoaneurysm of right SCA after an attempt at embolisation. A case report. *Interv Neuroradiol* 8 : 205-208, 2002
 23. Wiebers DO, Whisnant JP, Huston J 3rd, Meissner I, Brown RD Jr, Piepgras DG, et al. : Unruptured intracranial aneurysms : natural history, clinical outcome, and risks of surgical and endovascular treatment. *Lancet* 362 : 103-110, 2003