

Atrial Fibrillation as an Initial Presentation of Apathetic Thyroid Storm

Hassam Ali ¹, Shiza Sarfraz ², Lareb Hassan ³, Hadeera Ali ⁴

1. Internal Medicine, East Carolina University, Vidant Medical Center, Greenville, USA 2. Anesthesiology, Bahawal Victoria Hospital, Quaid-E-Azam Medical College, Bahawalpur, PAK 3. Medicine and Surgery, Quaid-e-Azam Medical College, Bahawalpur, PAK 4. Internal Medicine, CMH Institute of Medical Sciences, Bahawalpur, PAK

Corresponding author: Hassam Ali, alih20@ecu.edu

Abstract

Atrial fibrillation as an initial presenting symptom of an apathetic thyroid storm is under-reported, especially in the setting of undiagnosed hyperthyroidism. Very rarely, thyroid storm can present with apathetic symptoms. The author presents a case of apathetic thyrotoxicosis with atrial fibrillation. The patient had a generalized weakness, lethargy, and weight loss as initial symptoms and was found to have atrial fibrillation, which was initially thought to be the inciting event. However, further evaluation revealed a new diagnosis of apathetic thyroid storm secondary to uncontrolled Graves' disease. She was managed medically for thyroid storm with hopes to control the tachyarrhythmia by controlling the underlying etiology. Subsequently, her symptoms resolved, and she came back to baseline except for continued atrial fibrillation, which was rate controlled. Early recognition of an apathetic thyroid storm can prevent mortality and morbidity as it can often be missed due to atypical symptoms.

Categories: Cardiology, Endocrinology/Diabetes/Metabolism, Internal Medicine

Keywords: graves' disease, atrial fibrillation, apathetic hyperthyroidism, thyroid-storm, thyrotoxicosis

Introduction

A thyroid storm is a complication of thyrotoxicosis. It has a high mortality rate of up to 30% if left untreated and is characterized by tachycardia or tachyarrhythmias, thermal dysregulation, and altered mental status. Thyroid storm may have an apathetic presentation, but this can either be missed or is underreported [1]. Lahey first described apathetic hyperthyroidism in 1931, with the main clinical characteristics being fatigue, weakness, apathy, and depression [2]. Atrial fibrillation as a presenting symptom for apathetic hyperthyroidism-related thyroid storm has rarely been reported in the literature. This is the first case with atrial fibrillation as an initial presentation of an apathetic hyperthyroidism-related thyroid storm to the best of our knowledge.

Case Presentation

A 65-year-old female presented with a complaint of fatigue for the last two weeks. Her past medical history is significant for type II diabetes and peripheral arterial disease. The patient complained of generalized tiredness, poor appetite, nausea, and vomiting with low-grade fever. She denied heat intolerance, tremors, palpitations, or increased perspiration. In the emergency department, she was tachycardiac to 180s, and an electrocardiogram (ECG) showed atrial fibrillation with rapid ventricular rate (Figure 1). Her physical exam was negative for graves' ophthalmopathy, pretibial myxedema, or thyroid acropachy. Her neurological exam showed bradyphrenia. Initially, she was started on a diltiazem drip by cardiology as a bedside echocardiogram revealed an ejection fraction of more than 50%. On returning basic labs, significant findings included a thyroid-stimulating hormone (TSH) of less than 0.01 and elevated free T4 of 3.77. The free T3 was also elevated > 20. The TSH one month ago was within normal limits. No new medications were added to her regimen except semaglutide. Diltiazem drip was stopped, and endocrinology was consulted, and her Burch-Wartofsky Point Scale (BWPS) for thyrotoxicosis score was greater than 45, highly suggestive of thyroid storm. On the endocrinologist's recommendation, the patient was started on propylthiouracil, hydrocortisone, potassium iodide drops, and propranolol. The patient was later transitioned to methimazole.

Review began 08/31/2021

Review ended 09/04/2021

Published 09/07/2021

© Copyright 2021

Ali et al. This is an open access article distributed under the terms of the Creative Commons Attribution License CC-BY 4.0., which permits unrestricted use, distribution, and reproduction in any medium, provided the original author and source are credited.

How to cite this article

Ali H, Sarfraz S, Hassan L, et al. (September 07, 2021) Atrial Fibrillation as an Initial Presentation of Apathetic Thyroid Storm. Cureus 13(9): e17786. DOI 10.7759/cureus.17786

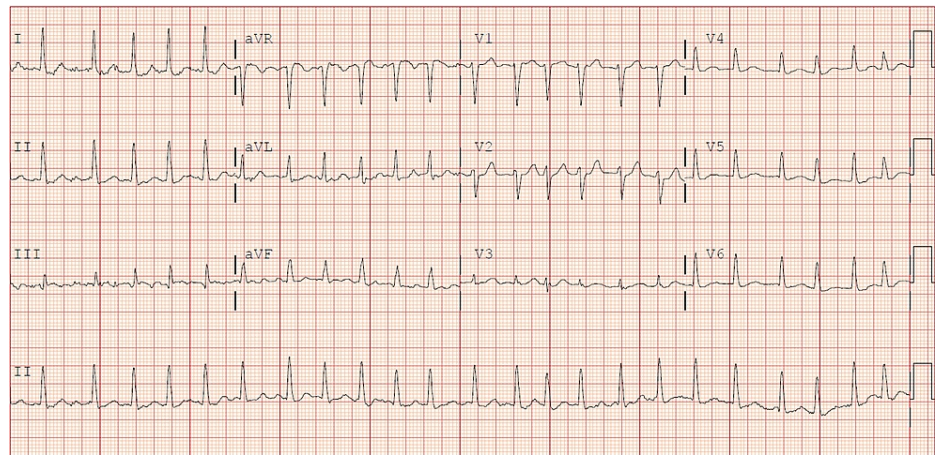
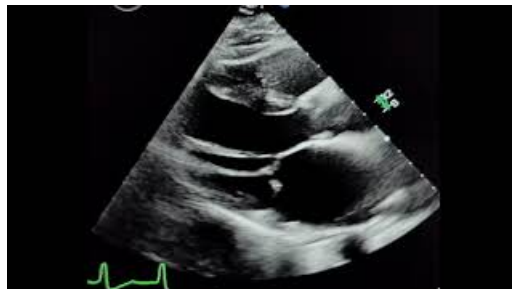

FIGURE 1: ECG showing irregular rhythm without P waves, consistent with a diagnosis of atrial fibrillation

ECG - electrocardiogram

The patient continued to remain in atrial fibrillation, which was rate controlled. The patient was also started on apixaban for anticoagulation. Her subsequent echocardiogram showed new-onset heart failure with a reduced ejection fraction of 35 to 40% and left atrial dilation (Video 1). The patient underwent a thyroid ultrasound which revealed a multinodular goiter with a dominant nodule in the isthmus. Her autoimmune work-up showed a positive thyroid receptor antibody test. Her thyroid-stimulating immunoglobulins were also elevated to 506%. Cardiology deferred direct current cardioversion (DCCV), and the patient was scheduled for an outpatient radioiodine thyroid uptake scan with the possible need of a fine needle aspiration (FNA) biopsy for further evaluation. A follow-up echocardiogram in two months did not show any decline of ejection fraction, and the patient was medically managed for hyperthyroidism and atrial fibrillation with rate control.



VIDEO 1: Atrial fibrillation with reduced ejection fraction and left atrial dilation

View video here: <https://www.youtube.com/watch?v=j3VzjOxGi54>

Discussion

Hyperthyroidism can present as an acute exacerbation with symptoms of thyrotoxicosis resulting in acute clinical deterioration (thyroid storm) [3]. A thyroid storm refers to the inability of a patient to maintain adequate metabolic, cardiovascular, or thermoregulatory control. BWPS for thyrotoxicosis is now widely used to predict biochemical thyrotoxicosis's likelihood of thyroid storm [4]. A BWPS score of ≥ 45 is highly suggestive of a thyroid storm, 25-44 of an impending thyroid storm, and a score of < 25 is unlikely to be a thyroid storm [2]. In an apathetic thyroid storm, the presentation of apathy is associated with weight loss, dry skin, tachyarrhythmias, and congestive cardiac failure [5]. Typical features of Graves' disease, like hand tremor and ophthalmopathy, may be absent, as in our case, and physical exam may be unrevealing [5].

In general, the pathophysiology behind apathy is not well known. It has been hypothesized that lack of typical hyperthyroidism symptoms could be secondary to decreased circulatory amines (catecholamines) or depletion of the body's stores of amines. It could also be secondary to the inability of the body at the receptor level to respond to these amines [5]. Interestingly, a paradoxical improvement was observed when adrenergic blockade in patients with the apathetic crisis was employed [5]. Thyrotropin-releasing hormone

(TRH) has an antidepressant effect when administered to severely depressed euthyroid patients [6]. This could be either due to increasing dopaminergic receptor sensitivity or altering the metabolism of dopamine in such a way as to increase the concentration of active dopamine in the brain. TRH has also been shown to reinforce the behavioral effects of levodopa in mice and is equally active in hypophysectomized animals [7]. However, whether it is depletion of TRH or catecholamines or receptor unresponsiveness, overlap with senile dementia could also mask the symptoms.

Although atrial fibrillation is a common cardiac complication of hyperthyroidism, it has been underreported as a presenting symptom of apathetic hyperthyroidism or a herald of thyroid storm in cases of apathetic hyperthyroidism. The incidence of atrial fibrillation also increases with advancing age [8]. Effects of thyroid hormones on ion channels of atrial myocytes contribute to the development of atrial fibrillation. Hyperthyroidism can result in shortened action potential duration, resulting in a higher inclination for the heart to go in atrial fibrillation [9]. Despite having an atypical presentation, thyroid storm associated with apathetic hyperthyroidism has increased T4/T3 activity leading to activation of these atrial myocytes and atrial fibrillation. Because of the apathetic symptoms, especially in the elderly, the diagnosis of hyperthyroidism is often overlooked, and only atrial fibrillation itself could be the presenting symptom, as in our case. The patients may have no prior history of hyperthyroidism.

Conclusions

Our case highlights the occurrence of tachyarrhythmias, particularly atrial fibrillation, as an initial presenting symptom of an Apathetic thyroid storm in the setting of undiagnosed hyperthyroidism. Previously atrial fibrillation has been observed in conjunction with thyrotoxicosis, and the effect of thyroid hormone-mediated atrial myocyte stimulation is the reason behind it. Nausea, vomiting, and lethargy are directly related to apathetic thyrotoxicosis and can mask underlying hyperthyroidism, as these are not typical presentations. Atrial fibrillation is usually resolved after underlying thyroid function normalizes. The recognition of an apathetic thyroid storm is essential and can present as a diagnostic challenge.

Additional Information

Disclosures

Human subjects: All authors have confirmed that this study did not involve human participants or tissue.

Conflicts of interest: In compliance with the ICMJE uniform disclosure form, all authors declare the following: **Payment/services info:** All authors have declared that no financial support was received from any organization for the submitted work. **Financial relationships:** All authors have declared that they have no financial relationships at present or within the previous three years with any organizations that might have an interest in the submitted work. **Other relationships:** All authors have declared that there are no other relationships or activities that could appear to have influenced the submitted work.

References

1. Dodd MJ, Blake DR: A case of apathetic thyrotoxicosis simulating malignant disease . *Postgrad Med J.* 1980, 56:359-60. [10.1136/pgmj.56.655.359](#)
2. Parker KI, Loftley A, Charles C, Hermayer K: A case of apathetic thyroid storm with resultant hyperthyroidism-induced hypercalcemia. *Am J Med Sci.* 2013, 346:338-40. [10.1097/MAJ.0b013e31828ffcbc](#)
3. de los Santos ET, Mazzaferri EL: Thyrotoxicosis. Results and risks of current therapy . *Postgrad Med.* 1990, 87:277-94. [10.1080/00325481.1990.11704643](#)
4. Bacuzzi A, Dionigi G, Guzzetti L, De Martino AI, Severgnini P, Cuffari S: Predictive features associated with thyrotoxic storm and management. *Gland Surg.* 2017, 6:546-51. [10.21037/gs.2017.07.01](#)
5. Arnold BM, Casal G, Higgins HP: Apathetic thyrotoxicosis. *Can Med Assoc J.* 1974, 111:957-8.
6. Joffe RT: Hormone treatment of depression. *Dialogues Clin Neurosci.* 2011, 13:127-38. [10.31887/dcms.2011.13.1/rjoffe](#)
7. Prange AJ, Lara PP, Wilson IC, et al.: Effects of thyrotropin-releasing hormone in depression. *Lancet.* 1972, 2:999-1002. [10.1016/s0140-6736\(72\)92407-5](#)
8. Parmar MS: Thyrotoxic atrial fibrillation. *MedGenMed.* 2005, 7:74.
9. N J, Francis J: Atrial fibrillation and hyperthyroidism. *Indian Pacing Electrophysiol J.* 2005, 5:305-11.