



CANADIAN SOCIETY FOR  
AESTHETIC (COSMETIC) PLASTIC SURGERY

SOCIÉTÉ CANADIENNE  
DE CHIRURGIE PLASTIQUE ESTHÉTIQUE



## Facial Surgery

### Special Topic

# The Facial Aging Process From the “Inside Out”

Arthur Swift, MD; Steven Liew, MD; Susan Weinkle, MD;  
Julie K. Garcia, PhD; and Michael B. Silberberg, MD, MBA

Aesthetic Surgery Journal  
2021, Vol 41(10) 1107–1119

© 2020 The Aesthetic Society.

This is an Open Access article distributed under the terms of the Creative Commons Attribution-NonCommercial License (<http://creativecommons.org/licenses/by-nc/4.0/>), which permits non-commercial re-use, distribution, and reproduction in any medium, provided the original work is properly cited. For commercial re-use, please contact [journals.permissions@oup.com](mailto:journals.permissions@oup.com)  
DOI: 10.1093/asj/sjaa339  
[www.aestheticsurgeryjournal.com](http://www.aestheticsurgeryjournal.com)

**OXFORD**  
UNIVERSITY PRESS

### Abstract

The normal course of aging alters the harmonious, symmetrical, and balanced facial features found in youth, not only impacting physical attractiveness but also influencing self-esteem and causing miscommunication of affect based on facial features. With this evidence-based paper, the authors aim to provide a comprehensive overview of the latest research on the etiology and progression of facial aging by explaining the aging process from the “inside out,” that is, from the bony platform to the skin envelope. A general overview of the changes occurring within each of the main layers of the facial anatomy is presented, including facial skeleton remodeling, fat pad atrophy or repositioning, changes in muscle tone and thickness, and weakening and thinning of the skin. This is followed by an in-depth analysis of specific aging regions by facial thirds (upper, middle, and lower thirds). This review may help aesthetic physicians in the interpretation of the aging process and in prioritizing and rationalizing treatment decisions to establish harmonious facial balance in younger patients or to restore balance lost with age in older patients.

### Resumen

El curso normal del envejecimiento altera las características faciales armoniosas, simétricas y equilibradas que se encuentran en la juventud, lo que no sólo afecta el atractivo físico, sino que también influye en la autoestima y causa una comunicación equivocada del afecto con base en pistas faciales confundidas. Con este paper basado en evidencias, los autores buscan ofrecer una descripción integral de las más recientes investigaciones sobre la etiología y la progresión del envejecimiento facial explicando el proceso del envejecimiento de “dentro hacia fuera”, es decir, de la plataforma ósea a la envoltura de la piel. Se presenta una descripción general de los cambios que ocurren dentro de cada una de las capas principales de la anatomía facial, entre ellos el remodelado del esqueleto facial, la atrofia o reposicionamiento de las capas de grasa, los cambios en el tono y grosor de los músculos, y el debilitamiento y adelgazamiento de la piel. A esto le sigue un análisis a fondo de las regiones específicas del envejecimiento por tercios faciales (tercios superior, medio e inferior). Esta revisión puede ayudar a los médicos estéticos en la interpretación del proceso de envejecimiento y en la priorización y racionalización de las decisiones de tratamiento para establecer un equilibrio facial armonioso en pacientes más jóvenes o para restaurar el equilibrio perdido con la edad en pacientes mayores.

Editorial Decision date: September 22, 2020; online publish-ahead-of-print December 16, 2020.

Dr Swift is director at the Westmount Institute of Plastic Surgery in Montréal, QC, Canada. Dr Liew is a specialist plastic surgeon and medical director at the Shape Clinic in Darlinghurst, NSW, Australia. Dr Weinkle is an affiliate clinical professor of Dermatology at the University of South Florida, Tampa, FL, USA. Dr Garcia is manager of Health Economics Outcomes Research at Allergan plc, an AbbVie Company, Irvine, CA, USA. Dr Silberberg is executive medical

director at Allergan Ltd, an AbbVie Company, Parkway, Marlow, Buckinghamshire, United Kingdom.

### Corresponding Author:

Dr Arthur Swift, Westmount Institute of Plastic Surgery, 4141 Sherbrooke Street West, Suite 420, Montreal, Canada H3Z 1B7.  
E-mail: [drswift@drarthurswift.com](mailto:drswift@drarthurswift.com)

Signs of facial aging, such as wrinkles and folds, poor skin tone and texture, and an imbalanced distribution of soft tissue, can have deleterious psychological, emotional, and social effects because facial aging alters self-perception and how individuals are seen by others.<sup>1,3</sup> Signs of aging may affect interpersonal relationships by influencing perceived character or personality traits<sup>3</sup> or by contributing to erroneously projected emotions (eg, anger, tiredness, or sadness) that do not reflect the individual's true feelings.<sup>1,2,4</sup> A youthful face, commonly defined as a blend of harmonious, symmetrical, and balanced features, is likely to convey more positive feelings. Therefore, successful treatment of facial aging that achieves attractive, natural-looking results may have a substantial positive impact on an individual's self-image and on how one is perceived by those with whom one has social interactions.<sup>1,3</sup>

Key features of primarily non-Asian youthful faces include large almond-shaped eyes, cheek fullness, a curvilinear profile, slightly protrusive and full lips, an adequately projecting chin, a defined jawline, and homogeneous skin tone.<sup>5</sup> Senescence alters these features as bone remodels, fat pads atrophy or reposition, and skin wrinkles and sags.<sup>6</sup> Aging gracefully may be synonymous with retaining fullness of features, smooth facial contours, gradual transitions between facial areas, and proper proportions in 3 dimensions while showing only a modicum of lines, blemishes, hollows, and shadows.

Knowledge regarding the etiology of facial aging changes has developed considerably, advancing from a simple focus on gravity and skin laxity to an increasing understanding that aging is a complex, dynamic, integrated process involving all layers of the facial anatomy. Although the sequence of facial aging is similar regardless of gender or race/ethnicity, the extent and rate of change of facial characteristics differs between individuals.<sup>7,8</sup> Rates of bone remodeling, photodamage, wrinkle development, and soft tissue redistribution vary between races and ethnicities, and people with skin of color may have distinct pigmentation concerns. However, age-related changes in skin texture, pigment, and bone structure affect all populations.<sup>9</sup>

Our goal with this evidence-based literature review is to provide a comprehensive overview of the latest data on the etiology and progression of facial aging by explaining the aging process from the "inside out," that is, from the bone to the skin envelope. We begin with a general overview of the changes that occur within each of the main layers of the facial anatomy—bone, fat, muscle, and skin—then provide an in-depth analysis of specific aging regions by facial thirds (upper, middle, and lower thirds) that complements how aesthetic clinicians generally evaluate and treat the face.

## FACIAL AGING BY LAYERS

Facial aging is a composite, interrelated, 3-dimensional process involving changes to the bone, soft tissue, and

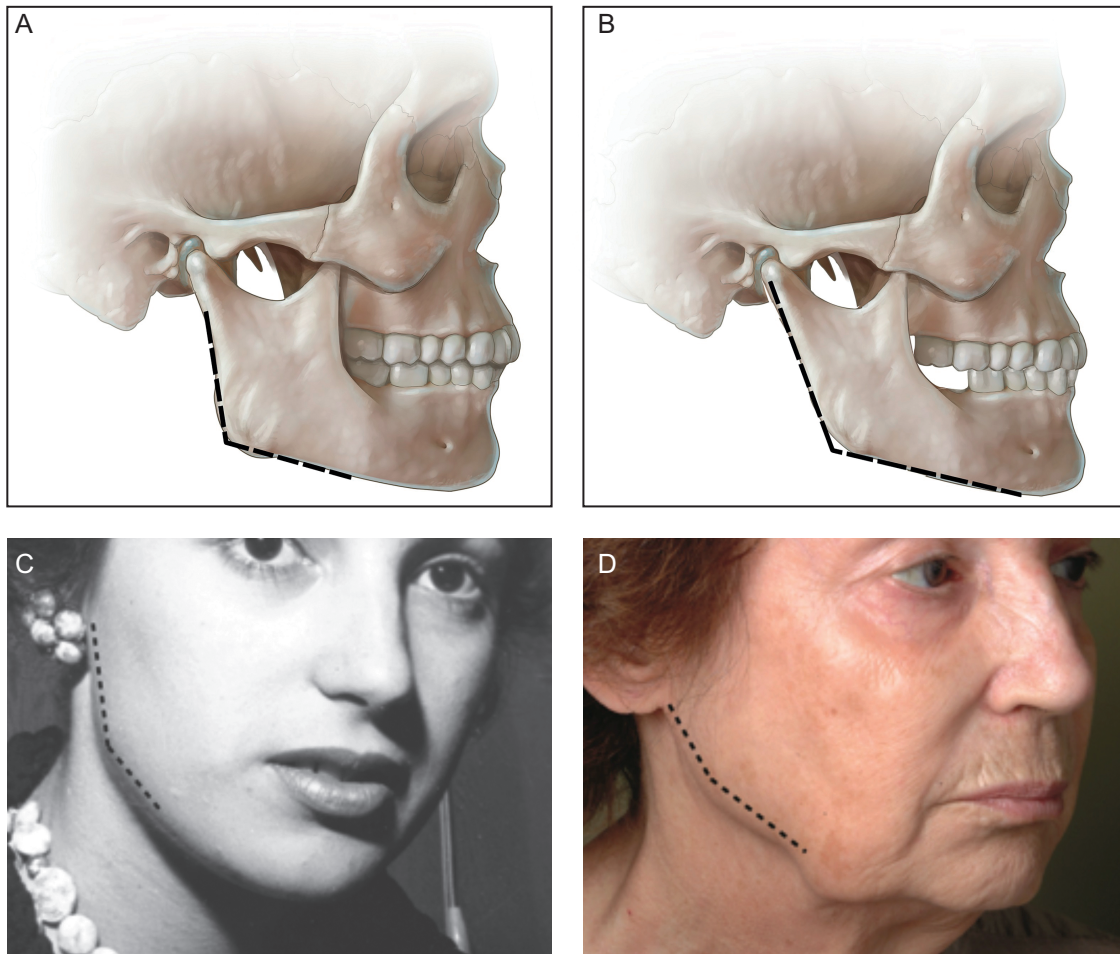
skin.<sup>6</sup> While each anatomical layer undergoes an aging process of its own, dependency of the more superficial structures on deeper layers also exists. It is a complex, multifaceted process wherein a change in 1 layer often causes a cascade of changes to adjacent layers.

## Bone

The facial bones are the framework for the attachment of overlying soft tissue, providing stability, structure, and definition. Support from this platform diminishes as the bones recede and remodel with age, resulting in the recession and repositioning of the overlying soft tissue. This results in an inferior and medial repositioning of fat pads and muscles as they realign over the shifting bony foundation.<sup>10,11</sup> Craniofacial skeletal remodeling occurs between adolescence and middle adulthood and beyond and includes the lengthening or rotation of the mandible, with a subsequent increase in mandibular angle,<sup>10,12</sup> notably the L to I phenomenon in women, which eventually leads to changes in chin projection and jawline (Figure 1).<sup>2,13,14</sup> Resorption of bone from the inferior portion of the mandible with aging and loss of dentition or dentoalveolar regression may result in an increase in the angle of the mandible and a decrease in the height of the chin.<sup>10,14,15</sup> Between the 30s and 50s, the lower forehead may begin to flatten as the glabellar angle decreases; pyriform and maxillary recession causes the nasal tip to droop, with retraction of the columella and alar base widening.<sup>16</sup> In the 30s, individuals also may begin to experience dentoalveolar regression<sup>10</sup> and maxillary retrusion, which contribute to flattening and hollowing in the cheeks, deepening of the nasolabial groove, and lengthening of the cutaneous upper lip (ergotrid), with rolling in of the vermilion.<sup>17</sup> Midface bone remodeling with aging causes an imbalance in the upper, middle, and lower thirds of the face, predominance of bony orbits in the midface reflecting a teardrop shape, enlargement of the pyriform aperture, and shortening of the upper jaw.<sup>17</sup> Superomedial and inferolateral portions of the orbital bone also undergo resorption with age, manifesting in increased prominence of the medial brow, fat pad, and lid-cheek junction (Figure 2); thus, the eyes appear smaller and rounder (senile enophthalmos) with deeper tear troughs.<sup>4,10,18,19</sup> From a right lateral view, these changes cause a clockwise rotation of the face relative to the cranial base; that is, the glabella, orbit, pyriform aperture, and maxilla rotate inferiorly, causing flattening of facial angles.<sup>20,21</sup> These bony changes are generally small (ie, millimeters).<sup>22</sup> Despite the small magnitude of the bony changes occurring at the deepest level of the facial anatomy, the effects are often dramatic, as if through amplification of overlying structures.<sup>19</sup>

## Fat

The fat compartments in the face (Figure 3) are broadly characterized as superficial or deep relative to the superficial musculoaponeurotic system.<sup>23</sup> Three superficial fat

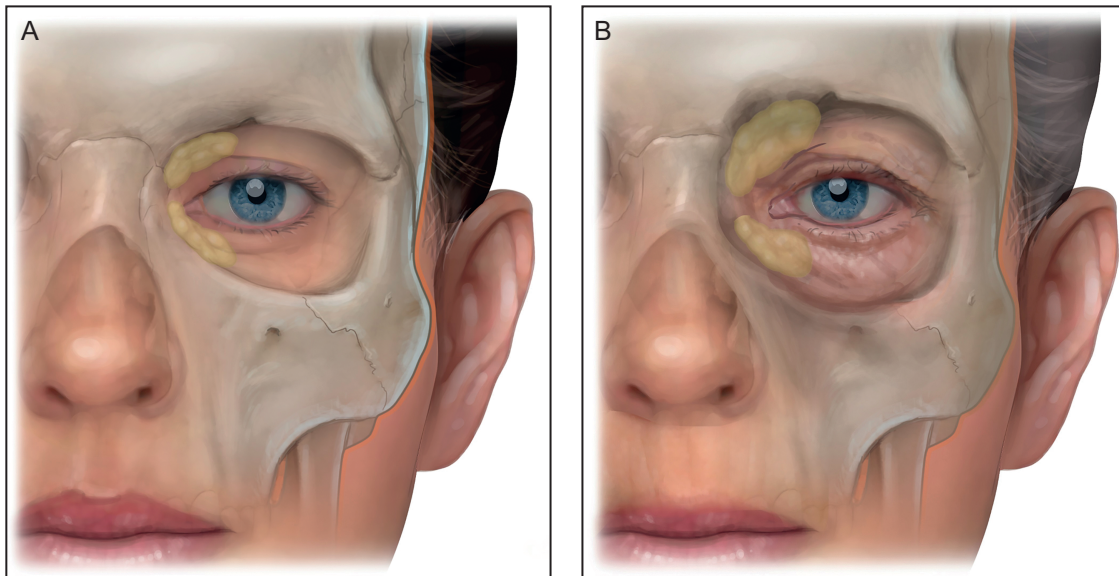


**Figure 1.** Progressive bony remodeling occurs with age in areas that resorb in a specific and predictable manner. The mandibular angle in females increases, as does the anterior projection of the chin. Images show this process in a young female (A) vs older (B) adult. Panel C shows the clinical presentation during young adulthood in this female patient at 22 years of age, whereas panel D reflects changes secondary to bony remodeling of the mandible with aging in the same patient at 70 years of age. Dashed lines represent areas of the chin and jawline visibly impacted by bony remodeling of the mandible. Patient images in panels A and B provided by Arthur Swift, MD. Patient images in panels C and D provided by B. Kent Remington, MD, owner of these original images, who has granted permission to publish them.

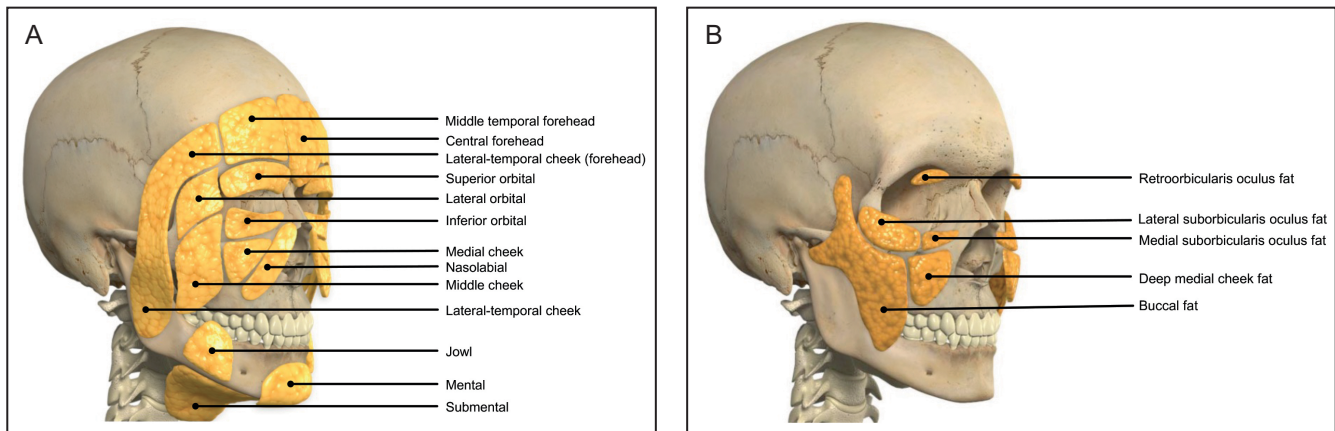
compartments (Figure 3A) are located in the forehead—the central, middle temporal, and lateral-temporal cheek.<sup>24</sup> The middle temporal compartments are on both sides of the central fat compartment, and the lateral-temporal cheek compartment of the forehead is continuous with the lateral-temporal cheek and cervical fat.<sup>25</sup> In the middle third of the face are the medial, middle, and lateral-temporal cheek superficial fat compartments and the nasolabial fat.<sup>25</sup> Jowl fat makes up the superficial fat layer of the lower third of the face together with the mental and submental fat.<sup>26-28</sup> Jowl fat is medial to lateral-temporal cheek fat, lateral to nasolabial fat, medial to middle cheek fat, and superior to the mandible.<sup>29</sup> The 3 superficial periorbital fat compartments comprise the superior, inferior, and lateral fat.<sup>25</sup> The fat lobules that make up the superficial fat pad compartments are small and distributed continuously in tight,

uniform arrangement.<sup>30</sup> Deep fat compartments (Figure 3B) include deep medial cheek fat, buccal fat, medial and lateral suborbicularis oculi fat (SOOF), and retro-orbicularis oculi fat.<sup>11,23,31,32</sup> These compartments comprise fat lobules that are larger and more loosely arranged and tend to occur in a more chaotic pattern.<sup>30</sup> Deep fat is immobile because it is firmly anchored to the underlying bone and helps to provide contour, support of overlying fat compartments, and a gliding plane for muscle movement.<sup>11,23,33</sup> The superficial fat compartments are more mobile and are subject to both the resting and dynamic tension of the mimetic muscles.<sup>11</sup>

Although in general it is believed that deep fat atrophies and superficial fat tends to reposition or hypertrophy,<sup>23,35</sup> fat atrophy has been commonly observed in the superficial fat compartments of the forehead and in the periorbital and perioral regions.<sup>36</sup> Because facial fat is highly



**Figure 2.** Orbital bone resorption occurs mainly in the inferolateral and superomedial regions. Images depict the integrity of the medial cheek fat pad, periorbital bone, medial brow, and lid-cheek junction in a young adult (A) vs the age-related changes in an older adult (B), including exaggeration of the brow and tear troughs as well as smaller, rounder-looking eyes. This previously unpublished, new illustration was created by Allergan Aesthetics, an AbbVie Company (Irvine, CA) who granted permission to publish it.



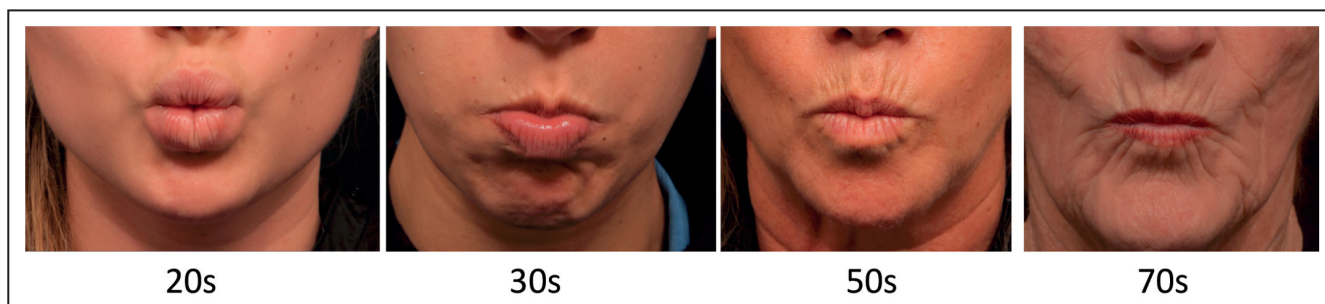
**Figure 3.** Fat compartments in the face are broadly characterized as superficial (A) or deep (B). Superficial fat compartments (A) are separated by fascia and septae that meet at adjacent compartments, where retaining ligaments reside, with each component found in varied amounts, proportions, and arrangements in different regions of the face.<sup>24,29,34</sup> Deep fat compartments (B) comprise retro-orbicularis oculus fat, lateral and medial suborbicularis oculus fat, buccal fat, and deep medial cheek fat, which has medial and lateral parts.<sup>23,25,31,32</sup> This previously unpublished, new illustration was created by Allergan Aesthetics, an AbbVie Company (Irvine, CA) who granted permission to publish it.

compartmentalized, these changes do not tend to occur as a confluent mass.<sup>37</sup> Conventionally, it is thought that fat pad repositioning tends to occur in the periorbital, midface, and lower jaw area. Shifting occurs from bony remodeling as the fat pads move with the bony changes and from weakening of the supporting ligaments.<sup>38,39</sup> As such, fat may reposition or shift within compartments from gravity,<sup>39</sup> causing an inferomedial displacement of the overlying skin envelope. This movement tends to increase hollows in the cheeks and flatten angles of the face<sup>39</sup> as well as contribute to hollowing

of the temple.<sup>40</sup> Fat redistribution and protrusion are mainly seen submentally in the jowl, lateral nasolabial fold, and lateral labiomental crease.<sup>6,36</sup>

## Muscle

Signs of senescence related to facial muscle aging result from repetitive muscle contraction and muscle tone changes. A typical occurrence in the aging process is that of repetitive muscle contraction resulting in the appearance



**Figure 4.** Perioral dynamic discord is illustrated across the ages. With aging, the skin envelope deteriorates faster than the muscle strength, leading to the orbicularis oris overwhelming the perioral skin. Images provided by Steven Liew, MD.

of superficial and deep dynamic wrinkles during animation.<sup>38</sup> Facial mimetic muscles insert into the dermis, thus playing an important role in both the suspension and structural integrity of the soft tissue envelope, thereby affecting the volume and contour of the region.<sup>6,41-43</sup> A recent concept of “dynamic discord with aging” relates to the interplay between mimetic facial muscles and the overlying deteriorating skin envelope.<sup>44</sup> Although muscles may weaken with age, their relative pull is greater on the less resistant tissues and dermis and can result in hyperdynamic expressions, creating caricatures that grimace rather than smile. **Figure 4** illustrates dynamic discord in the perioral region. The orbicularis oris muscle overwhelms the perioral skin, resulting in puckered lips in the youthful face but resembling tense, pursed lips with aging.

## Skin

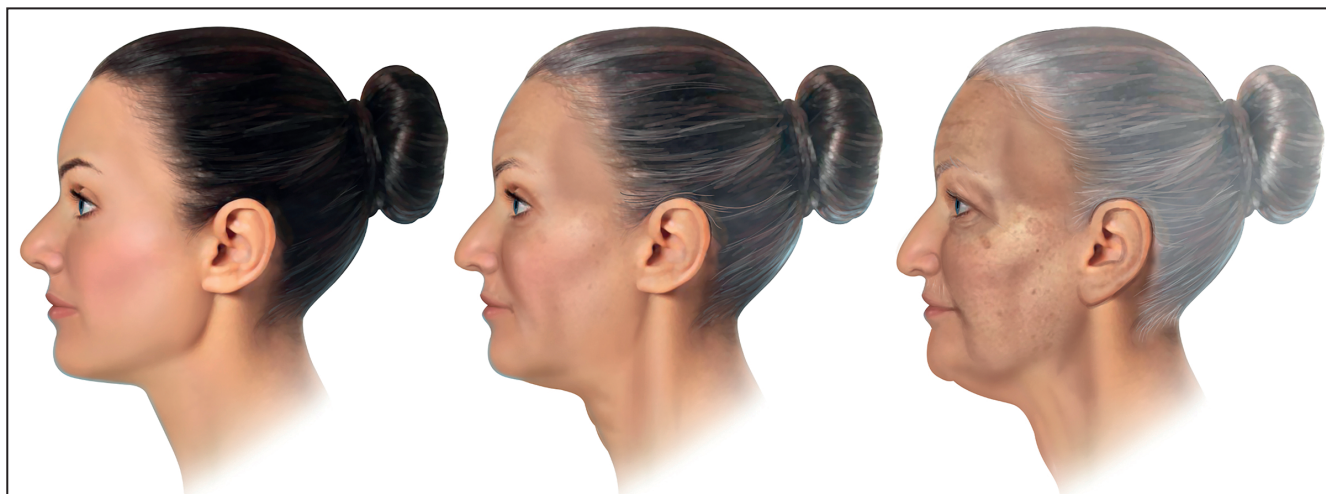Both intrinsic and extrinsic factors are crucial determinants of the appearance of aged skin. Intrinsic aging is due to the passage of time and affects individuals at variable rates.<sup>10,45,46</sup> The main extrinsic environmental influences affecting skin are cumulative sun exposure (photoaging) and smoking.<sup>46</sup> In addition, recent studies have shown how other environmental factors, such as air pollution (outdoor and indoor), are associated with skin aging.<sup>47,48</sup> Intrinsically aged skin slowly develops fine wrinkles, with the occasional exaggerated expression lines; on the other hand, extrinsically aged skin tends to develop more coarse wrinkling.<sup>46</sup> Both types of aging display hyperpigmentation, but intrinsically aged skin develops an even distribution of pigmented spots, whereas extrinsically aged skin develops a more mottled complexion.<sup>46</sup> Other characteristic signs of extrinsically aged skin include rough texture, dryness, telangiectasia (“spider veins”), and yellowish discoloration.<sup>10,46,49</sup> Because most individuals incur some sun damage throughout their lives, the effects occurring from extrinsic aging are superimposed on those of intrinsic aging.<sup>50</sup>

The resilience of the skin resides primarily in the dermis, because this layer is composed of collagen that contributes to the bulk and strength of the skin, elastin that contributes to elasticity, and glycosaminoglycans that play a key role in skin hydration.<sup>45,46,51,52</sup> In healthy, youthful skin, elastic

microfibril bundles bound to an elastin core form a network in the extracellular matrix that allows skin to stretch and spring back when relaxed, giving it pliability.<sup>52</sup> With intrinsic aging, the skin thins and weakens as the dermis atrophies from changes related to deterioration of these components. The rate of collagen breakdown increases, whereas the rate of collagen synthesis decreases. At 40 to 50 years of age, elastin biosynthesis begins to decline steeply, and elastin is lost through natural degradation.<sup>52</sup> The skin loses elasticity as the elastic fiber network disintegrates,<sup>46</sup> and water is lost as the hygroscopic glycosaminoglycans degrade.<sup>52</sup> In extrinsically aged skin, these same components of the dermis are affected but in slightly different ways and to a greater extent.<sup>50</sup> In addition to the increased breakdown of collagen and decreased collagen production,<sup>50</sup> the collagen fibers in extrinsically aged skin become disorganized,<sup>50</sup> which further impairs the structural integrity of the dermis. Glycosaminoglycans increase as opposed to degrade, but they accumulate in disorganized aggregates and become unable to regulate hydration, causing the skin to appear leathery.<sup>10,45</sup> The most profound effect of extrinsic facial aging occurs with elastin and is termed solar elastosis.<sup>38</sup> The amount and thickness of abnormal, disordered elastic fibers increase initially<sup>38,50</sup> and, with more damage, the elastic fiber network eventually starts to degrade.<sup>38</sup> As noted above, these changes to the elastic fiber network result in a loss of tissue compliance and resilience,<sup>2</sup> manifested as both static wrinkles and dynamic folds as the skin succumbs to the underlying pull of the mimetic muscles.<sup>6</sup> At a molecular level, increased expression of matrix metalloproteinase and upregulation of reactive oxygen species activity, driven primarily by ultraviolet radiation, degrade the dermal matrix over time.<sup>53</sup> Other factors contributing to aging include progressive reduction in cell number and function, including in melanocytic and Langerhans cells, and decreases in hormones that impact skin physiology.<sup>9</sup>

## IN-DEPTH ANALYSIS BY FACIAL THIRDS

As aging progresses, the face undergoes a spectrum of changes resulting from deflation, deterioration, and descent.<sup>6,37</sup> The predominant appearance may be hollow



**Figure 5.** Superficial temporal compartment: volume and size by age group. Mean height increases from 2.9 cm to 12.2 cm with increasing age, and mean volume increases by 35.5% from the youngest to the oldest group.<sup>40</sup> This previously unpublished, new illustration was created by Allergan Aesthetics, an AbbVie Company (Irvine, CA) who granted permission to publish it.

or sunken (“sinkers”); alternatively, tissue droop and fat bulges may be predominant (“saggers”). However, most patients will present with a mixture of aging signs that reflect the underlying facial anatomy.

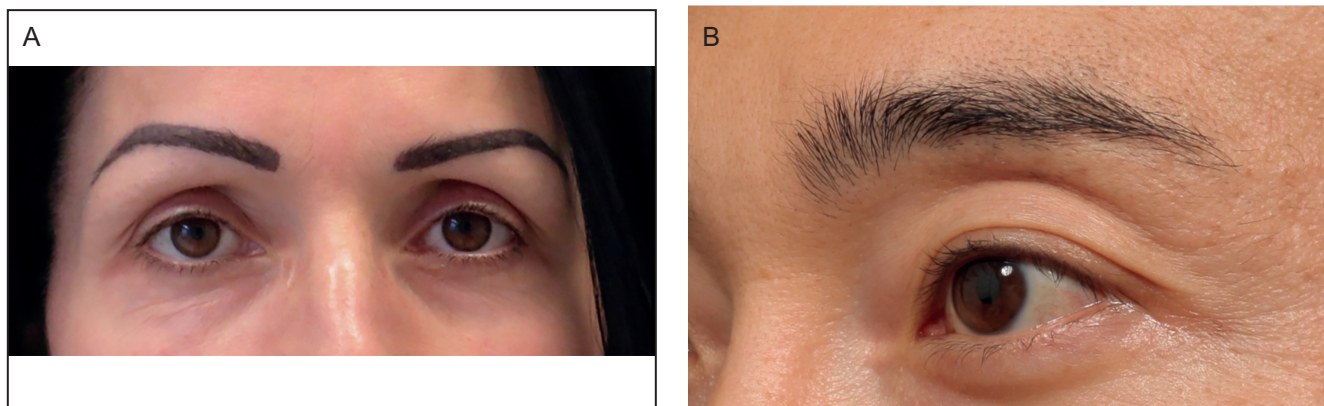### Upper Third: Forehead and Glabellar Area, Temporal Region, Eyebrow Position

In the forehead and glabellar area, the main signs of aging include wrinkle formation<sup>7,8</sup> and the nasofrontal angle increase that flattens and decreases projection.<sup>16</sup> This angle increase occurs as the orbital rim and nasion recede.<sup>16</sup> Increased craniofacial convexity typically occurs during the 50s or later.<sup>10</sup> Wrinkle formation occurs from muscle contraction<sup>38</sup> and may be compounded by fat loss.<sup>35</sup> Transverse forehead wrinkles are due to contraction of the frontalis muscle, perpendicular to muscle excursion, whereas more vertical wrinkles are related to “sleep crunch lines.” In a cross-sectional study, moderate or severe forehead wrinkles were reported to have an earlier onset (at 18-29 years of age) in Caucasian and Hispanic men vs Asian or African American men (onset at 40 years and older).<sup>7</sup> Moderate or severe glabellar lines had the earliest onset among Hispanic men (at 40 years of age and older).<sup>7</sup> Glabellar creases and nasal root transverse lines are primarily caused by contraction of the corrugator supercilii and procerus muscles, respectively.

The temporal region undergoes age-related change in superficial fat pads, resulting in a decrease in bi-temporal width and a scalloped appearance.<sup>54,55</sup> Clinicians often observe concave temples over a wide range of ages, and a

magnetic resonance imaging study confirmed that the soft-tissue thickness of the temporal region decreases on average 3.4 mm in depth throughout adulthood.<sup>54</sup> Loss of fat occurring in this region can be dramatic; the temples have been reported to incur the greatest percentage of volume loss of the entire face.<sup>54</sup> This was demonstrated using a facial averaging technique in more than 200 women ranging in age from 20 to 91 years.<sup>56</sup> A second magnetic resonance imaging study suggests that fat loss in the temple may be due to a shift in position of fat within the superficial temporal fat compartment rather than an overall loss of volume.<sup>40</sup> As a whole, the superficial temporal fat compartment increases in mean height and volume from youth to old age (Figure 5). However, the upper and middle thirds of the compartment thin with age while the lower third becomes progressively thicker.

Age-related changes to the eyebrow position vary considerably, with some individuals experiencing brow ptosis and others exhibiting brow elevation.<sup>2,57</sup> Recession of the superior orbital rim contributes to brow ptosis as the loss of bony support causes the eyebrows to drop below the receded rim.<sup>16</sup> Decreased recruitment of the frontalis muscle (a brow elevator) may also occur, coupled with normal or increased tone of the orbicularis oculi muscles (brow depressors), resulting in a strong, downward force that contributes to sagging of the eyebrows.<sup>2,58</sup> The lateral portion of the eyebrows may sag disproportionately because the lateral edge of the frontalis muscle is medial to the temporal fusion line and, as such, does not have a direct point of insertion. This anatomical feature results in less support for the lateral eyebrow. The lateral eyebrow also may sag from the downward force created from the descent of the preseptal and galeal



**Figure 6.** Typical A-frame deformity in this 49-year-old Caucasian female (A) and sunken eye appearance in this 45-year-old Asian male (B). Images in panels A and B provided by Arthur Swift, MD, and Steven Liew, MD, respectively.

fat pads.<sup>58</sup> A decline in the height of the lateral eyebrow with age has been reported in both men and women, but with a consistently higher tail in women across ages.<sup>59</sup> The drooping of the brows may be more pronounced in people of Latin American descent, with greater sagging of the tail.<sup>60</sup> Brow ptosis also may result from increased skin laxity or eyelid ptosis that pulls the brows downward.<sup>2</sup> On the other hand, brow elevation may be attributed to a chronic overactive frontalis muscle<sup>4</sup> or unconscious contraction of the frontalis to elevate the brow to reduce visual obstruction from excess upper eyelid skin or ptotic lids, also contributing to forehead wrinkling.<sup>57</sup>

### Middle Third: Periorbital Area, Nose, Midface, Nasolabial Folds

The earliest signs of facial aging are often visible in the periorbital area, with changes in skin color and appearance.<sup>10,61</sup> Opposing theories abound regarding the appearance of “under-eye bags” as cause (loss of support) or effect (stretching of Lockwood’s ligament, resulting in a descent of the globe, pushing the intraorbital fat forward), but the eventual result is the same: the eyes appear smaller and rounder overall.<sup>4,38,62,63</sup> A major change occurring in this area is bony recession of the orbital rim, causing the orbital aperture to increase in width and area.<sup>11,38</sup> Specifically, the height of the superior orbital rim increases medially and the inferior orbital rim recedes laterally among females, whereas men experience recession of the entire inferior orbital rim.<sup>64</sup> The appearance of the periorbital region is also highly dependent on fat pad volume. There is consistent loss of fat of the superomedial orbit, nasojugal groove, and palpebral-malar junction, averaging 0.8 cc when comparing mothers and daughters with an average difference of 28 years.<sup>65</sup> The descent of the lateral canthus with orbital remodeling leads to a loss of the youthful upslope medial to the lateral canthal tilt. This phenomenon

is more predominant in African American women than in Caucasian women.<sup>66</sup>

Globe retraction (ie, senile enophthalmos) causes the eye to appear to be deep-seated or sunken and narrows the palpebral fissure.<sup>62</sup> Senile enophthalmos may occur from a variety of causes, including the position of the eye within the orbit shifting as the diameter of the orbital rim increases with age, orbital and periorbital fat atrophy, and stretching of the suspensory ligament of the eye.<sup>11,62</sup> The globe itself does not change in size with age.

The spectrum of age-related changes of the upper and lower eyelids ranges from soft tissue sagginess to under-eye bags to hollowness. The upper eyelids descend with age, causing elongation of the upper lid length, loss of alignment of the upper eyelid fold and upper lid margin, projection of the tarsal region, and increased visibility of the pretarsal region.<sup>2</sup> This descent is most commonly caused by age-related levator dehiscence, which is when the tendon of the levator muscle of the eyelid loosens or detaches.<sup>2</sup> It may also be caused by excessive eyelid skin from loss of elasticity and deflation of the upper eyelid subcutaneous tissue.<sup>2</sup> With supraorbital fat loss, the upper eyelid arc changes, with its peak moving from medial to a more central location (the typical A-frame deformity) in Caucasians (Figure 6A).<sup>4,67</sup> Asian individuals tend to show more of a pan-eyelid loss of upper lid volume (ie, sunken eyes) as an early sign of upper eyelid aging compared with Caucasians, owing to fuller upper eyelids and shorter bony orbits (Figure 6B).<sup>68,69</sup>

The lower eyelids also descend, leading to fat accumulation and scleral show. Infraorbital fat herniates forward, as the inferior orbital rim recedes and inadequate skeletal support fails to maintain the attenuated soft tissues in their proper location.<sup>21,70</sup> In addition, volume loss of the deep cheek fat compartments allows excess traction on the lower eyelid, leading to scleral show.<sup>20</sup> Sagging of the lower eyelid especially occurs in men.<sup>71</sup> The presence of

infraorbital malar mounds or crescents complicates the aging periorbital picture and may result from a combination of SOOF prolapse and weakening in the orbital supporting structures, causing insufficient pumping of fluid and resulting in lymphatic overload.<sup>72</sup> These findings are contradicted by an analysis using a facial averaging technique showing that the lower eyelid rises with age.<sup>56</sup> In Caucasian individuals, lower lids lengthen with aging, whereas African American or Latino/Hispanic individuals experience lower lid fat herniation.<sup>73</sup>

Crow's feet lines form in the lateral canthal area. These wrinkles mainly occur from repetitive contraction of the lateral orbicularis oculi muscles when smiling.<sup>4,74</sup> The prominence of crow's feet lines increases with fat loss and thinning of overlying skin.<sup>16,35</sup> These wrinkles are often described as exhibiting a fan pattern extending anywhere from the lower brow to the cheek (in full, lower, central, or upper fan patterns).<sup>74</sup> In 1 study, strong associations were reported between age and progression of the fan pattern, with younger participants showing a central fan pattern and older participants exhibiting a full fan pattern.<sup>74</sup> Substantial difference between genders was also reported, with men predominately displaying a lower fan pattern.<sup>74</sup> Heterogeneity in fan patterns may result from different functional patterns of facial muscle recruitment when smiling.<sup>74</sup> Caucasian men report earlier and more severe crow's feet lines occurring with aging than Asian, Hispanic, and, particularly, African American men.<sup>7</sup>

Eyelash changes include a reduction in length, thickness, and darkness (eyelash hypotrichosis).<sup>75</sup> Whereas age-related hair changes are well documented for scalp hair loss, less is known about eyelashes. It has been speculated that age-related hair follicle changes will be similar, regardless of location.<sup>75</sup> Therefore, as with scalp hair loss, aging may affect the density, volume, and pigmentation of eyelashes as the hair production cycle changes.<sup>75</sup> With age, new hair growth is reduced as the proportion of hair follicles in the catagen phase (the latent growth period) increases while those in the anagen phase (the new hair growth period) decrease.<sup>76</sup> In addition, the hair follicle may shrink, leading to a reduction in the diameter of the hair.<sup>76</sup> These 2 changes cause loss of hair density and volume. Age-related loss of hair color is caused by a reduction of melanocyte activity in the hair follicle.

The tear trough often refers to the hollow between the eye area and the upper medial cheek, extending to slightly below the orbital rim. It comprises the medial third of the nasojugal groove, where the orbicularis muscle is firmly anchored to the underlying bone. The lid-cheek junction comprises that portion of the nasojugal groove that extends below the orbital rim. Tear troughs become more visible with age, mainly from deflation of soft tissue, fat atrophy, and fat descent.<sup>39,77</sup> The tear trough's muscular and bony anatomy is then unmasked as the deep periorbital

fat atrophies, in particular the SOOF.<sup>4,78</sup> The tear trough appears concave and indented because the skin under the eye is thinner than the cheek skin.<sup>23,77</sup> Moreover, tear trough severity increases with loss of midface volume in aging.<sup>79</sup> Deflation of the deep medial cheek fat coupled with the attenuation of the zygomatic-cutaneous and orbitomalar retaining ligaments lead to loss of support and descent of the overlying nasolabial and superficial cheek fat.<sup>38</sup> This fat descent pulls the skin downward and worsens the appearance of the tear trough.<sup>38</sup> Tear trough severity with aging was shown to be significantly greater ( $P \leq 0.035$ ) for Caucasian vs African American, Asian, and Latino/Hispanic women and was significantly greater ( $P \leq 0.005$ ) for Caucasian vs African American men.<sup>79</sup>

Bulging of the superficial fat pads in the tear trough area (ie, the characteristic bags under the eyes) may result from displacement of the globe within the orbit pushing fat forward<sup>70</sup> and/or retaining ligaments in the periorbital area weakening and no longer adequately supporting the soft tissue.<sup>80</sup> Another theory suggests this may occur because infraorbital fat has a unique fatty acid composition prone to hypertrophy.<sup>70</sup> A contrasting theory suggests that the position of fat in this area is relatively stable, and the illusion of descent is caused by the bulging of the superficial infraorbital fat that creates a shadow, exaggerating the indentation at the lid-cheek junction.<sup>77</sup> Concomitantly, the pigmented lower eyelid skin thins and darkens, increasing the contrast in this area.<sup>77</sup>

Attenuation of the supportive structures of the nose may cause a droopy, more prominent tip and nasal lengthening as an individual ages.<sup>2,81</sup> The bony changes related to nasal tip ptosis include recession of the pyriform fossa that causes the alar base to be repositioned superiorly and upper maxillary resorption that results in a narrowing of the nasolabial angle.<sup>6</sup> Tip ptosis is also caused by flattening of the lower lateral cartilages (alar cartilages) and weakening of the interdomal ligaments and the fibrous attachments separating these cartilages from the upper lateral cartilages.<sup>2</sup> Additionally, an active depressor septi nasi muscle can accentuate drooping.<sup>82</sup> Tip ptosis causes nasal lengthening and may give the illusion of a dorsal hump or supratip septal prominence.<sup>2,83</sup> In some individuals, the tip may take on a fuller appearance as a result of increased density of sebaceous glands and thickening of the nasal cartilage, which is especially prominent in men.<sup>83</sup> In others, the skin and subcutaneous tissues may thin, causing the cartilage and bone of the nose to become more visible and appear skeletonized.<sup>2</sup> Increased nasal tip projection may be more pronounced in Caucasian men and women vs those of other races, such as Latinos/Hispanics and African Americans, who tend to have a broader nasal base.<sup>73</sup>

In the midface, the cheek loses projection as the ogee curve flattens, and the submalar region becomes increasingly concave.<sup>55</sup> The major bony changes that contribute



to this flattening include a decrease in maxillary angle and height, which is especially prominent in women, and recession of the inferior rim of the orbit.<sup>21</sup> Tooth loss and dentoalveolar regression in the lateral areas of the jawbone further contribute to the increased concavity in the mid to lower cheek.<sup>10</sup> However, the primary determinant of midface aging is deflation of the deep fat pads followed by an inferior shift of the overlying superficial fat pads.<sup>33,38</sup> In particular, as the deep medial and buccal fat pads deflate, the superficial medial cheek fat descends. In addition, deflation of the superficial lateral temporal fat pads contributes to lateral cheek atrophy.<sup>33</sup> Attenuation of the retaining ligaments of the face, such as the orbicularis and zygomatic ligaments, and/or the superficial musculoaponeurotic system attachments also may contribute to this fat descent.<sup>39</sup> These changes to the midface fat pads cause the cheeks to have diminished projection and a drooping appearance.<sup>39</sup> Because the deep fat of the midface is compartmentalized in a fashion similar to the overlying superficial fat, volume loss of the deep fat compartments leads to predictable changes in the midface, as seen from the surface of the skin.<sup>33</sup> Race may significantly affect midface volume deficit; in 1 study, African American women and men had significantly greater midface volume than Caucasian individuals, regardless of age ( $P < 0.001$ ).<sup>79</sup>

Nasolabial folds are formed during smiling as the levator muscles of the lip contract, causing tissue expansion pressure within the overlying superficial nasolabial fat pad.<sup>51</sup> A few theories attempt to explain why these folds become more prominent with age. The nasolabial fat pad (ie, the inferolateral section of what was previously termed the malar fat pad) may descend from loss of support as the maxilla and mandible bones recede<sup>11,19,30,35</sup> and/or the lateral deep medial cheek fat pad atrophies.<sup>39</sup> This descent may be exacerbated from loss of support from weakening of the malar and orbital ligaments<sup>84</sup> and stretching of the fascial septa within the nasolabial fat pad.<sup>85</sup> Increasing severity of nasolabial folds is also associated with midface volume loss,<sup>79</sup> suggesting that nasolabial folds develop secondary to selective hypertrophy of the superior portion of the cheek fat pads.<sup>86</sup> Caucasian women have shown significantly greater nasolabial fold severity than African American and Asian women ( $P \leq 0.029$ ), and Caucasian men have shown significantly greater nasolabial fold severity than Asian men ( $P = 0.005$ ).<sup>79</sup>

### Lower Third: Perioral Region, Chin, Jawline

The perioral region loses definition, shape, and fullness as the lips flatten and retrude, the ergotrid lengthens, the vermilion border and Cupid's bow become less pronounced, the Cupid's peaks widen, and perioral wrinkles and folds form.<sup>2,51,87,88</sup> Changes to the orbicularis oris muscle

represent the most important factor affecting this area.<sup>88</sup> In youth, this muscle has well-defined bundles and fascicles surrounded by a thin layer of connective tissue, but with age, the muscle thins and weakens and the connective tissue thickens. These changes cause the forward curve of the muscle to decrease,<sup>89</sup> and as the shape of the muscle changes, structural support beneath the lips diminishes, causing lip retrusion and the lengthening and thinning of the vermilion border (loss of the upper lip pout).<sup>87,88,90</sup> Bony changes in the perioral region include a shrinkage of the mandible with an overall reduction in the bony bulk of the mandible and dentoalveolar regression,<sup>10</sup> resulting in a change in the structural foundation of the mandible from an L shape to a thinner and more slanted I shape. This, together with maxillary retrusion, causes a dramatic shift of the overlying soft tissue.<sup>38</sup> Some research suggests that atrophy and/or repositioning of the superficial and deep fat pads may also impact the signs of aging in the perioral area.<sup>49,84</sup> For instance, atrophy of the suborbicularis fat diminishes the vermilion border, and atrophy of deep fat pads of the lip causes lip retrusion and flattening.<sup>11,33,91</sup>

The loss of support from changes to the underlying structures of the perioral region creates skin laxity, contributing to the development of perioral lines and folds.<sup>51</sup> Vertical lip lines (called bar code lines or lipstick bleed lines) are wrinkles that develop in the skin perpendicular to the direction of contraction of the orbicularis oris muscle, radiating superiorly from the vermilion border of the upper lip or inferiorly from the lower lip. These lines often develop in response to repetitive pursing of the lips and are most evident in smokers. Most vertical lip lines form perpendicular to the orbicularis oris muscle.<sup>51</sup> In addition, contraction of the levator labii superioris and depressor septi nasi muscles may create unsightly horizontal lines. Other prominent signs of aging in the perioral area include drooping of the oral commissures and formation of labiomandibular folds, also known as marionette lines.<sup>92</sup> As the oral commissures droop into the chasms created by chin zone volume loss and the labiomandibular folds become more prominent with age, an individual may appear sad.<sup>4,51</sup> Both of these age-related features are caused by hyperactivity of the depressor anguli oris and platysma.<sup>63</sup> Labiomandibular folds may be exacerbated by the loss of cheek support as buccal fat comes to overlie the anterior border of the lower masseter<sup>34</sup> and by an inferior pull from jowl fat.<sup>78</sup> In 1 study, African American men reported notably less severe perioral lines and lip fullness loss with aging than Asian, Caucasian, or Hispanic individuals.<sup>7</sup>

The chin zone is a 3-dimensional entity, having height, width, and projection. The major signs of chin aging include alterations in the shape and projection of the chin.<sup>6</sup> Women tend to have decreased chin projection, as their mandibles rotate inferiorly and backwards toward the skull, whereas men tend to have increased chin

**Table 1.** Major Manifestations of Aging by Decade of Life

Age (y)	Changes
30s or earlier	• Forehead and glabellar lines appear <sup>2,7,8</sup>
	• Eyebrows may begin to descend <sup>2</sup>
	• Upper eyelid skin increases, and eyes appear smaller <sup>2</sup>
	• Fine lines around the lower eyelids and crow's feet emerge <sup>7,8,10</sup>
	• Tear trough lines and infraorbital fat become more prominent <sup>6-8</sup>
	• Midface aging begins <sup>6,7</sup>
	• Nasolabial folds form <sup>2,7,8</sup>
	• Lip thinning begins <sup>10</sup>
	• Alterations in skin texture and pigmentation appear <sup>39</sup>
40s	• Forehead, glabellar, and crow's feet lines deepen <sup>2</sup>
	• Eyebrows may continue to descend <sup>10</sup>
	• Upper eyelid skin increases in laxity and descends <sup>2,10</sup>
	• Tear trough elongates and the inferior orbital rim becomes visible <sup>39</sup>
	• Midface loses projection, hollows, and appears to descend <sup>39</sup>
	• Nasolabial folds deepen <sup>39</sup>
	• Lips thin and perioral lines develop <sup>10</sup>
	• Oral commissures and marionette lines become noticeable <sup>10</sup>
	• Chin begins to rotate/elongate <sup>10</sup>
• Jawline loses definition <sup>2,10</sup>	
50s	• Dynamic glabellar and forehead lines deepen and remain noticeable in repose <sup>2,10</sup>
	• Upper eyelid drooping increases <sup>10</sup>
	• Tear trough and lower eyelid scleral show worsens <sup>2,10,20</sup>
	• Nose begins to droop <sup>2</sup>
	• Midface structures noticeably descend <sup>2</sup>
	• If tooth loss occurs, the cheeks may appear hollow <sup>10</sup>
	• Nasolabial folds are increasingly prominent <sup>2,10</sup>
	• Lips thin out and perioral lines become more visible <sup>2</sup>
	• Jawline has diminished firmness and jowls may develop <sup>2,10</sup>

**Table 1.** Continued

Age (y)	Changes
60s and older	• Eyes appear small and round <sup>2</sup>
	• Nose elongates <sup>10</sup>
	• Jowls are increasingly prominent <sup>10</sup>
	• Skin thins, loses elasticity, and sags significantly <sup>2,10</sup>
	• All previously noted changes are exaggerated <sup>10</sup>

projection, as their mandibles undergo more forward rotation.<sup>12</sup> The chins of Asian and Latino/Hispanic individuals may recede more compared with people of other races.<sup>73</sup> The mandible predictably recedes on either side of the mentum, causing anterior mandibular grooves to form and contribute to the formation of the pre-jowl sulci (indentations on either side of the chin).<sup>93</sup> Fat loss in this area may increase the prominence of pre-jowl sulci and may contribute to chin ptosis.<sup>84</sup> Other changes in the chin area include a more prominent labiomental crease (a horizontal groove below the lower lip and above the chin prominence) caused by repetitive action of the mentalis muscle, and the appearance of peau d'orange (dimpling rhytids on the chin) from visible dermal attachments of the corrugator-like mentalis muscle.<sup>51</sup>

The jawline loses definition as fat in the jowls becomes more prominent with age and the cervicomental angle, or the break point of the vertical portion of the neck and the transverse portion of the submandibular region, increases.<sup>2</sup> The main bony change contributing to a loss of jawline definition is mandible recession; specifically, there is a loss of mandibular volume and the formation of the anterior mandibular groove (bone resorption in the mandible inferior to the mental foramen).<sup>93</sup> Skin laxity coupled with deflation of the superior and inferior jowl fat compartments extending inferiorly from the nasolabial fold, and weakening of the mandibular septum holding these fat compartments in place, cause fat in the jowls to sag and become more pronounced.<sup>2,6</sup> The upper border of the jowl is formed from the mandibular retaining ligament,<sup>80</sup> which may cause skin indentations where it extends into the subcutaneous plane as it stretches to support the jowl fat compartments.<sup>80</sup> Jowls tend to be a distinct feature of the aged Caucasian face, although people with skin of color may also experience this sign of aging.<sup>73</sup> Downward pull from the contraction of the platysma may also contribute to loss of definition in the jawline, as the anterior border and dorsal boundary of the jowl are formed by the platysma-mandibular retaining ligaments.<sup>6,26</sup> **Table 1** provides an overview of the major changes by decade of life.

## CONCLUSIONS

Facial aging is an intricate process involving interrelated changes to bone, muscle, fat, and skin. It is typified by deterioration of skin tone and texture, deflation due to loss of bone and fat, descent of soft tissues due to loss of muscle tone and skin elasticity, disproportion as hollowing and/or hypertrophy occur in different facial areas at different rates and chronological times, and dynamic discord, or loss of balance between interacting muscles. Too often, clinicians treat these signs of aging without a real understanding of their etiology. Recognizing the anatomical alterations that underlie the changing appearance of specific facial areas may enable clinicians to treat patients more precisely and effectively to achieve optimal outcomes. Although there are still unanswered questions and opposing theories in the literature regarding the effects of aging on specific facial areas, there is, nonetheless, strong scientific evidence for understanding how changes to underlying tissue alter the aging face. Knowledge of the etiology of facial aging should inform aesthetic treatment, enhancing clinicians' ability to restore the harmonious facial balance that may be lost as their patients age.

## Disclosures

A. Swift has served as a consultant for Allergan plc, an AbbVie Company, Croma, Galderma, and Merz Aesthetics. S. Liew has served on an advisory board and speakers' bureau and as a remunerated consultant for, and has received honoraria from, Allergan plc, an AbbVie Company, and Galderma. S.H. Weinkle has served as a lecturer and advisory board member for, and received research grants from, Allergan plc, an AbbVie Company. J.K. Garcia and M.B. Silberberg are employees of Allergan plc, an AbbVie Company, and own stock or stock options in the company.

This research was supported by Allergan plc, prior to its acquisition by AbbVie, Allergan plc provided writing and editorial support for this manuscript, and employees of Allergan plc participated in the research, the interpretation of data, the review of the manuscript, and the decision to submit for publication.

## Funding

This research was funded by Allergan plc, prior to its acquisition by AbbVie, Dublin, Ireland. Writing and editorial support was provided by Peloton Advantage, LLC, an OPEN Health company, and funded by Allergan plc, prior to its acquisition by AbbVie. The opinions expressed in this article are those of the authors. The authors received no honoraria related to the development of this article.

## REFERENCES

- Gupta MA, Gilchrist BA. Psychosocial aspects of aging skin. *Dermatol Clin*. 2005;23(4):643-648.
- Friedman O. Changes associated with the aging face. *Facial Plast Surg Clin North Am*. 2005;13(3):371-380.
- Reilly MJ, Tomsic JA, Fernandez SJ, Davison SP. Effect of facial rejuvenation surgery on perceived attractiveness, femininity, and personality. *JAMA Facial Plast Surg*. 2015;17(3):202-207.
- Fitzgerald R. Contemporary concepts in brow and eyelid aging. *Clin Plast Surg*. 2013;40(1):21-42.
- Hoefflin SM. *The Beautiful Face: The First Mathematical Definition, Classification, and Creation of True Facial Beauty*. Santa Monica, CA: Steven M. Hoefflin, MD; 2002.
- Coleman SR, Grover R. The anatomy of the aging face: volume loss and changes in 3-dimensional topography. *Aesthet Surg J*. 2006;26(1S):S4-S9.
- Rossi AM, Eviatar J, Green JB, et al. Signs of facial aging in men in a diverse, multinational study: timing and preventive behaviors. *Dermatol Surg*. 2017;43(Suppl 2):S210-S220.
- Alexis AF, Grimes P, Boyd C, et al. Racial and ethnic differences in self-assessed facial aging in women: results from a multinational study. *Dermatol Surg*. 2019;45(12):1635-1648.
- Venkatesh S, Maymone MBC, Vashi NA. Aging in skin of color. *Clin Dermatol*. 2019;37(4):351-357.
- Albert AM, Ricanek K Jr, Patterson E. A review of the literature on the aging adult skull and face: implications for forensic science research and applications. *Forensic Sci Int*. 2007;172(1):1-9.
- Kahn DM, Shaw RB. Overview of current thoughts on facial volume and aging. *Facial Plast Surg*. 2010;26(5):350-355.
- Pecora NG, Baccetti T, McNamara JA Jr. The aging craniofacial complex: a longitudinal cephalometric study from late adolescence to late adulthood. *Am J Orthod Dentofacial Orthop*. 2008;134(4):496-505.
- Shaw RB Jr, Katzel EB, Koltz PF, Kahn DM, Giroto JA, Langstein HN. Aging of the mandible and its aesthetic implications. *Plast Reconstr Surg*. 2010;125(1):332-342.
- Toledo Avelar LE, Cardoso MA, Santos Bordoni L, de Miranda Avelar L, de Miranda Avelar JV. Aging and sexual differences of the human skull. *Plast Reconstr Surg Glob Open*. 2017;5(4):e1297.
- Ozturk CN, Ozturk C, Bozkurt M, Uygur HS, Papay FA, Zins JE. Dentition, bone loss, and the aging of the mandible. *Aesthet Surg J*. 2013;33(7):967-974.
- Shaw RB Jr, Kahn DM. Aging of the midface bony elements: a three-dimensional computed tomographic study. *Plast Reconstr Surg*. 2007;119(2):675-681, discussion 682.
- Truswell WHT. Aging changes of the periorbital, cheeks, and midface. *Facial Plast Surg*. 2013;29(1):3-12.
- Mendelson B, Wong CH. Changes in the facial skeleton with aging: implications and clinical applications in facial rejuvenation. *Aesthetic Plast Surg*. 2012;36(4):753-760.
- Shaw RB Jr, Katzel EB, Koltz PF, et al. Aging of the facial skeleton: aesthetic implications and rejuvenation strategies. *Plast Reconstr Surg*. 2011;127(1):374-383.
- Pessa JE. An algorithm of facial aging: verification of Lambros's theory by three-dimensional stereolithography, with reference to the pathogenesis of midfacial aging, scleral show, and the lateral suborbital trough deformity.

- Plast Reconstr Surg.* 2000;106(2):479-488, discussion 489.
21. Richard MJ, Morris C, Deen BF, Gray L, Woodward JA. Analysis of the anatomic changes of the aging facial skeleton using computer-assisted tomography. *Ophthalmic Plast Reconstr Surg.* 2009;25(5):382-386.
  22. Forsberg CM, Eliasson S, Westergren H. Face height and tooth eruption in adults—a 20-year follow-up investigation. *Eur J Orthod.* 1991;13(4):249-254.
  23. Wan D, Amirlak B, Rohrich R, Davis K. The clinical importance of the fat compartments in midfacial aging. *Plast Reconstr Surg Glob Open.* 2013;1(9):e92.
  24. Prendergast PM. Anatomy of the face and neck. In: Shiffman MA, di Giuseppe A, eds. *Cosmetic Surgery.* Berlin, Germany: Springer-Verlag; 2012:29-45.
  25. Rohrich RJ, Pessa JE. The fat compartments of the face: anatomy and clinical implications for cosmetic surgery. *Plast Reconstr Surg.* 2007;119(7):2219-2227, discussion 2228.
  26. Pils U, Anderhuber F. The chin and adjacent fat compartments. *Dermatol Surg.* 2010;36(2):214-218.
  27. Kenkel JM, Jones DH, Fagien S, et al. Anatomy of the cervicomenal region: insights from an anatomy laboratory and roundtable discussion. *Dermatol Surg.* 2016;42(Suppl 1):S282-S287.
  28. Rohrich RJ, Rios JL, Smith PD, Gutowski KA. Neck rejuvenation revisited. *Plast Reconstr Surg.* 2006;118(5):1251-1263.
  29. Schenck TL, Koban KC, Schlattau A, et al. The functional anatomy of the superficial fat compartments of the face: a detailed imaging study. *Plast Reconstr Surg.* 2018;141(6):1351-1359.
  30. Raskin E, Latrenta GS. Why do we age in our cheeks? *Aesthet Surg J.* 2007;27(1):19-28.
  31. Hwang SH, Hwang K, Jin S, Kim DJ. Location and nature of retro-orbicularis oculi fat and suborbicularis oculi fat. *J Craniofac Surg.* 2007;18(2):387-390.
  32. Fitzgerald R, Rubin AG. Filler placement and the fat compartments. *Dermatol Clin.* 2014;32(1):37-50.
  33. Rohrich RJ, Pessa JE, Ristow B. The youthful cheek and the deep medial fat compartment. *Plast Reconstr Surg.* 2008;121(6):2107-2112.
  34. Mendelson B, Wong CH. Anatomy of the aging face. In: Neligan PC, ed. *Plastic Surgery.* Toronto, Canada: Elsevier; 2013:78-92.
  35. Ilankovan V. Anatomy of ageing face. *Br J Oral Maxillofac Surg.* 2014;52(3):195-202.
  36. Donofrio LM. Fat distribution: a morphologic study of the aging face. *Dermatol Surg.* 2000;26(12):1107-1112.
  37. Rohrich RJ, Pessa JE. The retaining system of the face: histologic evaluation of the septal boundaries of the subcutaneous fat compartments. *Plast Reconstr Surg.* 2008;121(5):1804-1809.
  38. Farkas JP, Pessa JE, Hubbard B, Rohrich RJ. The science and theory behind facial aging. *Plast Reconstr Surg Glob Open.* 2013;1(1):e8-e15.
  39. Wulc AE, Sharma P, Czyz CN. The anatomic basis of midfacial aging. In: Hartstein ME, Wulc AE, Holck DE, eds. *Midfacial Rejuvenation.* New York, NY: Springer New York; 2012:15-29.
  40. Foissac R, Camuzard O, Piereschi S, et al. High-resolution magnetic resonance imaging of aging upper face fat compartments. *Plast Reconstr Surg.* 2017;139(4):829-837.
  41. Papageorgiou KI, Mancini R, Garneau HC, et al. A three-dimensional construct of the aging eyebrow: the illusion of volume loss. *Aesthet Surg J.* 2012;32(1):46-57.
  42. Yun S, Son D, Yeo H, et al. Changes of eyebrow muscle activity with aging: functional analysis revealed by electromyography. *Plast Reconstr Surg.* 2014;133(4):455e-463e.
  43. Friedman T, Davidovitch N, Schefflan M. Comparative double blind clinical study on round versus shaped cohesive gel implants. *Aesthet Surg J.* 2006;26(5):530-536.
  44. Swift A, Remington BK. The mathematics of facial beauty. In: Jones DH, Swift A, eds. *Injectable Fillers: Facial Shaping and Contouring.* 2nd ed. Hoboken, NJ: Wiley Blackwell; 2019:29-62.
  45. Naylor EC, Watson RE, Sherratt MJ. Molecular aspects of skin ageing. *Maturitas.* 2011;69(3):249-256.
  46. Langton AK, Sherratt MJ, Griffiths CE, Watson RE. A new wrinkle on old skin: the role of elastic fibres in skin ageing. *Int J Cosmet Sci.* 2010;32(5):330-339.
  47. Vierkötter A, Schikowski T, Ranft U, et al. Airborne particle exposure and extrinsic skin aging. *J Invest Dermatol.* 2010;130(12):2719-2726.
  48. Li M, Vierkötter A, Schikowski T, et al. Epidemiological evidence that indoor air pollution from cooking with solid fuels accelerates skin aging in Chinese women. *J Dermatol Sci.* 2015;79(2):148-154.
  49. Talakoub L, Wesley NO. Differences in perceptions of beauty and cosmetic procedures performed in ethnic patients. *Semin Cutan Med Surg.* 2009;28(2):115-129.
  50. El-Domyati M, Attia S, Saleh F, et al. Intrinsic aging vs. photoaging: a comparative histopathological, immunohistochemical, and ultrastructural study of skin. *Exp Dermatol.* 2002;11(5):398-405.
  51. Ali MJ, Ende K, Maas CS. Perioral rejuvenation and lip augmentation. *Facial Plast Surg Clin North Am.* 2007;15(4):491-500, vii.
  52. Uitto J. The role of elastin and collagen in cutaneous aging: intrinsic aging versus photoexposure. *J Drugs Dermatol.* 2008;7(2 Suppl):s12-s16.
  53. Jenkins G. Molecular mechanisms of skin ageing. *Mech Ageing Dev.* 2002;123(7):801-810.
  54. Wysong A, Joseph T, Kim D, Tang JY, Gladstone HB. Quantifying soft tissue loss in facial aging: a study in women using magnetic resonance imaging. *Dermatol Surg.* 2013;39(12):1895-1902.
  55. Swift A, Remington K. BeautiPHlcation™: a global approach to facial beauty. *Clin Plast Surg.* 2011;38(3):347-77, v.
  56. Lambros V, Amos G. Three-dimensional facial averaging: a tool for understanding facial aging. *Plast Reconstr Surg.* 2016;138(6):980e-982e.
  57. Matros E, Garcia JA, Yaremchuk MJ. Changes in eyebrow position and shape with aging. *Plast Reconstr Surg.* 2009;124(4):1296-1301.
  58. Knize DM. An anatomically based study of the mechanism of eyebrow ptosis. *Plast Reconstr Surg.* 1996;97(7):1321-1333.

59. Glass LR, Lira J, Enkhbold E, et al. The lateral brow: position in relation to age, gender, and ethnicity. *Ophthalmic Plast Reconstr Surg*. 2014;30(4):295-300.
60. Plowes Hernandez O, Montes Bracchini JJ. Management of the heavy brows: long-term surgical options. *Facial Plast Surg*. 2018;34(1):36-42.
61. Hirmand H. Anatomy and nonsurgical correction of the tear trough deformity. *Plast Reconstr Surg*. 2010;125(2):699-708.
62. Athanasiov PA, Prabhakaran VC, Selva D. Non-traumatic enophthalmos: a review. *Acta Ophthalmol*. 2008;86(4):356-364.
63. Coleman KR, Carruthers J. Combination therapy with BOTOX and fillers: the new rejuvenation paradigm. *Dermatol Ther*. 2006;19(3):177-188.
64. Kahn DM, Shaw RB Jr. Aging of the bony orbit: a three-dimensional computed tomographic study. *Aesthet Surg J*. 2008;28(3):258-264.
65. Camp MC, Wong WW, Filip Z, Carter CS, Gupta SC. A quantitative analysis of periorbital aging with three-dimensional surface imaging. *J Plast Reconstr Aesthet Surg*. 2011;64(2):148-154.
66. Odunze M, Rosenberg DS, Few JW. Periorbital aging and ethnic considerations: a focus on the lateral canthal complex. *Plast Reconstr Surg*. 2008;121(3):1002-1008.
67. Liew S, Nguyen DQ. Nonsurgical volumetric upper periorbital rejuvenation: a plastic surgeon's perspective. *Aesthetic Plast Surg*. 2011;35(3):319-325.
68. Choi HS, Whipple KM, Oh SR, et al. Modifying the upper eyelid crease in Asian patients with hyaluronic acid fillers. *Plast Reconstr Surg*. 2011;127(2):844-849.
69. Eckstein LA, Shadpour JM, Menghani R, Goldberg RA. The relationship of the globe to the orbital rim. *Arch Facial Plast Surg*. 2011;13(1):51-56.
70. Lee JM, Lee H, Park M, Lee TE, Lee YH, Baek S. The volumetric change of orbital fat with age in Asians. *Ann Plast Surg*. 2011;66(2):192-195.
71. van den Bosch WA, Leenders I, Mulder P. Topographic anatomy of the eyelids, and the effects of sex and age. *Br J Ophthalmol*. 1999;83(3):347-352.
72. Kpodzo DS, Nahai F, McCord CD. Malar mounds and festoons: review of current management. *Aesthet Surg J*. 2014;34(2):235-248.
73. Vashi NA, de Castro Maymone MB, Kundu RV. Aging differences in ethnic skin. *J Clin Aesthet Dermatol*. 2016;9(1):31-38.
74. Kane MA, Cox SE, Jones D, Lei X, Gallagher CJ. Heterogeneity of crow's feet line patterns in clinical trial subjects. *Dermatol Surg*. 2015;41(4):447-456.
75. Glaser DA, Jones D, Carruthers J, et al. Epidemiologic analysis of change in eyelash characteristics with increasing age in a population of healthy women. *Dermatol Surg*. 2014;40(11):1208-1213.
76. Courtois M, Lousouarn G, Hourseau C, Grollier JF. Ageing and hair cycles. *Br J Dermatol*. 1995;132(1):86-93.
77. Lambros V. Observations on periorbital and midface aging. *Plast Reconstr Surg*. 2007;120(5):1367-1376, discussion 1377.
78. Gierloff M, Stöhring C, Buder T, Wiltfang J. The subcutaneous fat compartments in relation to aesthetically important facial folds and rhytides. *J Plast Reconstr Aesthet Surg*. 2012;65(10):1292-1297.
79. Glaser DA, Lambros V, Kolodziejczyk J, Magyar A, Dorries K, Gallagher CJ. Relationship between midface volume deficits and the appearance of tear troughs and nasolabial folds. *Dermatol Surg*. 2018;44(12):1547-1554.
80. Alghoul M, Codner MA. Retaining ligaments of the face: review of anatomy and clinical applications. *Aesthet Surg J*. 2013;33(6):769-782.
81. Quatela VC, Pearson JM. Management of the aging nose. *Facial Plast Surg*. 2009;25(4):215-221.
82. Rohrich RJ, Huynh B, Muzaffar AR, Adams Jr WP, Robinson Jr JB. Importance of the depressor septi nasi muscle in rhinoplasty: anatomic study and clinical application. *Plast Reconstr Surg*. 2000;105(1):376-383, discussion 384-378.
83. Rohrich RJ, Hollier LH Jr, Janis JE, Kim J. Rhinoplasty with advancing age. *Plast Reconstr Surg*. 2004;114(7):1936-1944.
84. Perkins SW, Sandel HD 4th. Anatomic considerations, analysis, and the aging process of the perioral region. *Facial Plast Surg Clin North Am*. 2007;15(4):403-407, v.
85. Owsley JQ, Roberts CL. Some anatomical observations on midface aging and long-term results of surgical treatment. *Plast Reconstr Surg*. 2008;121(1):258-268.
86. Gosain AK, Klein MH, Sudhakar PV, Prost RW. A volumetric analysis of soft-tissue changes in the aging midface using high-resolution MRI: implications for facial rejuvenation. *Plast Reconstr Surg*. 2005;115(4):1143-1152, discussion 1153.
87. Bishara SE, Treder JE, Jakobsen JR. Facial and dental changes in adulthood. *Am J Orthod Dentofacial Orthop*. 1994;106(2):175-186.
88. Iblher N, Stark GB, Penna V. The aging perioral region - do we really know what is happening? *J Nutr Health Aging*. 2012;16(6):581-585.
89. Penna V, Stark GB, Eisenhardt SU, Bannasch H, Iblher N. The aging lip: a comparative histological analysis of age-related changes in the upper lip complex. *Plast Reconstr Surg*. 2009;124(2):624-628.
90. Akgül AA, Toygar TU. Natural craniofacial changes in the third decade of life: a longitudinal study. *Am J Orthod Dentofacial Orthop*. 2002;122(5):512-522.
91. Rohrich RJ, Pessa JE. The anatomy and clinical implications of perioral submuscular fat. *Plast Reconstr Surg*. 2009;124(1):266-271.
92. Perkins NW, Smith SP Jr, Williams EF 3rd. Perioral rejuvenation: complementary techniques and procedures. *Facial Plast Surg Clin North Am*. 2007;15(4):423-432, vi.
93. Romo T, Yalamanchili H, Sclafani AP. Chin and prejowl augmentation in the management of the aging jawline. *Facial Plast Surg*. 2005;21(1):38-46.