

## Original Article

# The Effect of Different Doses of *Mesobuthus eupeus* (Scorpionida: Buthidae) Scorpion Venom on the Production of Liver Necrosis in Nmri Mice

Sara Mojdegani-Fard<sup>1</sup>; \*Sohrab Imani<sup>1,2</sup>; Mahmoud Shojaei<sup>1</sup>

<sup>1</sup>Department of Entomology, Science and Research Branch, Islamic Azad University, Tehran, Iran

<sup>2</sup>Department of Parasitology and Toxicology, School of Medicine, Semnan University of Medical Science, Semnan, Iran

\*Corresponding author: Dr Sohrab Imani, E-mail: Imanisohrab@gmail.com

(Received 27 Nov 2015; accepted 22 Jan 2017)

## Abstract

**Background:** Scorpion venom has a variety of different components considerably. Some of these compounds are proteins such as Phospholipase A2 which is one of the most important. Use of scorpion venom for the treatment of any disease requires an initial study to determine the therapeutic dose or safe dose. Therefore, due to the necessity of studying scorpion venom, it is of special importance to study the effects of its dose response in animal tissues.

**Methods:** To determine the inflammatory effects of scorpion's venom (*Mesobuthus eupeus*), 50 Nmri mice with an average weight of  $24 \pm 7$ g were selected for investigation in two experiments. In first-round 25 of them were divided into 5 groups and were exposed to different doses of venom injection paralleling the control group. Single-injection of various doses on 25 mice was performed and results were compared.

**Results:** There was a significant differences between the test and control groups (in most groups). Liver necrosis was one of the important symptoms in this study, the severity of which was measured and statistically analyzed.

**Conclusion:** It was determined that 0.05ppm is a safe dose and sub-lethal doses can use for the investigation of therapeutic effects of venom on cancer, diabetes, dermatitis, and so on.

**Keywords:** Dose-response; Liver necrosis; Nmri mice; Scorpion's venom

## Introduction

Animal products' (such as poison, enzyme and so on) usage for treating some diseases have a good background in history, and in recent years these components have been draw more attention, and several studies have been done worldwide. In various studies, some researches have been investigated on the effects of bees and scorpions' venom on Insulin secretion and blood glucose in Wistar male rats. melittin polypeptide- the main component in bee venom- has been stimulated Insulin secretion from Langerhans islands in Nmri mice in laboratory conditions. Melittin is recommended as a valuable factor for further studies on  $\beta$ -cell's plasma membrane which has a role in insulin secretion regulation (1-3).

In insulin-resistant mice, direct activation of

Phospholipase A2 by Melittin caused Insulin output from Langerhans islands. Phospholipase A2 activation has a role in the compensation for insulin resistance in Langerhans islands (4). Additionally, treatment with honey bee phospholipase A2 causes the release of Insulin from cells and Insulin secretion to blood (5). Anti-cancer effects of the compounds of *Mesobuthus marthensis* scorpion's venom were evaluated in Iran. It has been shown that venom can inhibit cancer cell growth significantly and induces cell death. It also prevented glioma cell growth by inhibition of their ion canals (6).

These animal's venom substances can act as potential anti-tumor agents. Scorpions with a 300 million years history are one of the oldest animals on the earth and the oldest fossils

belong to them as arachnids and arthropods. It is proven by the existence of some basic anatomical features such as single nerve chain nodes. In some cultures and human civilization, there are some documents for using natural toxin for some diseases treatment with the special rank for scorpion's venom (7). *Mesobuthus eupeus* from the family Buthidae is known as a spotted yellow scorpion. Water-soluble compounds of Scorpion's venom with pH from neutral to Alkaline generally made of mucus, Oligopeptides, nucleotides, amino acids, and other organic compounds also from some enzymes such as phospholipase, hyaluronidase and some molecules with relatively low molecular weight like serotonin, histamine, protease inhibitors and histamine releasers (8). high molecular weight compounds such as hyaluronidase and phospholipase A2 can stimulate immune responses.

In this study, the effects of different sublethal doses of *M. eupeus* venom was used to check for necrotic responses and other effects on Nmri hepatic cells.

## Materials and Methods

Scorpion collection was conducted using black light at night time from July to October 2015 in the suburbs of Omidiyeh and Aghajari Cities in Khuzestan Province, Iran. Out of about 1500 collected scorpions, 362 *M. eupeus* scorpions have been identified. This scorpion with a yellow body and a size of about 6cm with 3–5 rows of dark longitudinal spots in the dorsal region of the pre-abdomen is called the spotted yellow scorpion.

Venom extracting was performed by an electroshock device by electrodes attaching to the scorpion's body and venom gland. A weak electrical current has passed through the scorpion's body in a short time causing shock. As a result, it leads to the excretion of venom, which was collected by holding a micro-tube at the end of the sting. Usually, the voltages used were 6 to 7.5 volts, depending on the size of the scorpion. After extracting, the venom was dried us-

ing a freeze-dryer and stored in the refrigerator at 2–4 °C (9).

In this study, a total of 50 non-infected adult male Nmri mice weighing 24±7g were randomly divided into 10 experimental groups including treatment and control groups under different doses of venom. They were kept in animal house of the Islamic Azad University of Tehran, Science and Research Unit under the following conditions: 12/12h daylight/ darkness, temperature around 22±2 °C, adequate humidity and freely used the usual dry diet with water (9, 10). The research was conducted in two stages of experimentation as follows:

**The first stage:** Studying the effects of *M. eupeus* scorpion venom:

During this stage, injections were performed 6 times in the groin and each time at intervals of one day, and the mice were anesthetized with diethyl ether and dissected one day after the last injection, and the liver and some other organs were studied.

- 1) Control group: used the usual dry diet with water and healthy mice received sterile distilled water by injection equivalent to the volume of injected venom. Sterile distilled water was also used to dissolve the venom. The treatment groups were received different doses as follows:
- 2) The first group received a dose of 0.5ppm
- 3) The second group received a dose of 0.2ppm
- 4) The third group received a dose of 0.1ppm
- 5) The fourth group received a dose of 0.05ppm

**The Second stage:** Investigation of the effects of *M. eupeus* scorpion venom:

At this stage, the mice were injected at a set dose at one stage, and the next day they were dissected and their livers were removed.

At this stage, the same number of mice with the same grouping was considered.

- 1) Control group: operated by the method of the previous control group.
- 2) The first group received a dose of 1ppm
- 3) The second group received a dose of 0.4ppm
- 4) The third group received a dose of 0.2ppm
- 5) The fourth group received a dose of 0.1ppm

After removal of the organs, fixing, and tissue preparation, staining was performed by Eosin-Harris hematoxylin staining method for liver tissue. The slides prepared in this way were examined by light microscope with 40X magnification and necrosis spots were identified in them. The area and size of the spots and their frequency in 100 fields of view were measured by an image analyzer and Leica Qwin software.

## Results

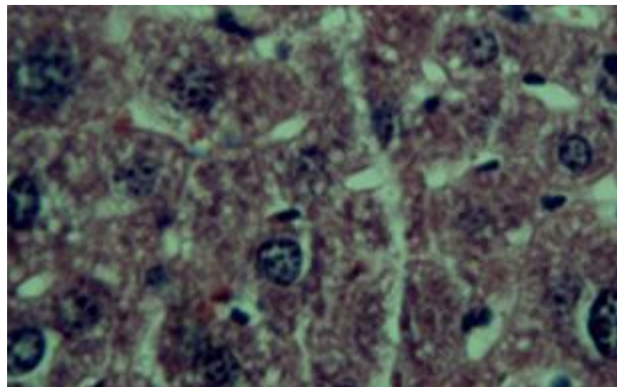
At the first round of experiment by four sub-lethal doses, we observed that three of them had visible symptoms associated with liver necrosis except for the 0.05ppm (Table 1). At the highest dose, in addition to being more frequent, it showed a completely different pattern in terms of color intensity with other samples. Table 2 shows the frequency of stains in terms of necrosis severity. In this case, the color intensity of the stains is considered and according to the quality of the stains, which were sometimes very dark and sometimes very light, they are divided into three categories: mild, moderate, and severe. Table 2 shows the number of color intense spot and severe necrosis observed in each microscopic field by 40X magnitude. As the concentration increased, the surface area of the spots initially increased, but was not an absolute trend, so that at concentrations of 0.5 to 1ppm, the surface area of the spots did not increase, but their intensity increased in terms of

turbidity (Fig. 2). also the tables and diagrams show that at the highest concentration, severe spots were not seen, but the frequency of spots in this concentration was much higher than other concentrations and statistically, the difference was significant. There is a 99% probability with other concentrations (Figs. 3–6).

In the second period of experiments, as shown in Table 3, signs of liver necrosis were observed in all doses. As observed in the experiments of the first stage, an increase in the size of the spots was seen with an increase in dose, but this was not an absolute trend.

Also, in Figure 3, the frequency of data is given so that at higher doses the size of the spots is smaller but their number and amount of staining is increased, as shown in Table 4, at the dose of 1ppm the highest number of severe spots were seen and Figure 4 is comparing the number of color intensity of necrotic stains in sub-lethal dose of *Mesobuthus eupeus* venom on Nmri liver tissue in the first round of test

As shown in Figure 1, no signs of necrosis were observed in the liver tissue sample of the control group, but in other images in Figure 2, in the liver tissue of mice receiving sub-lethal doses (0.1, 0.2, 0.4, 0.5 and 1ppm), necrosis is observed with a change in the size of the spots along with a change in the intensity of their staining. In images A and B, the spot level was larger, and in images C and D, the area was smaller and the color intensity was different.



**Fig. 1.** Liver image of healthy mice receiving sterile distilled water equivalent to the volume of the injected toxin

**Table 1.** Average area of necrotic stains in sub-lethal doses of *Mesobuthus eupeus* venom on Nmri hepatic tissue in the first round

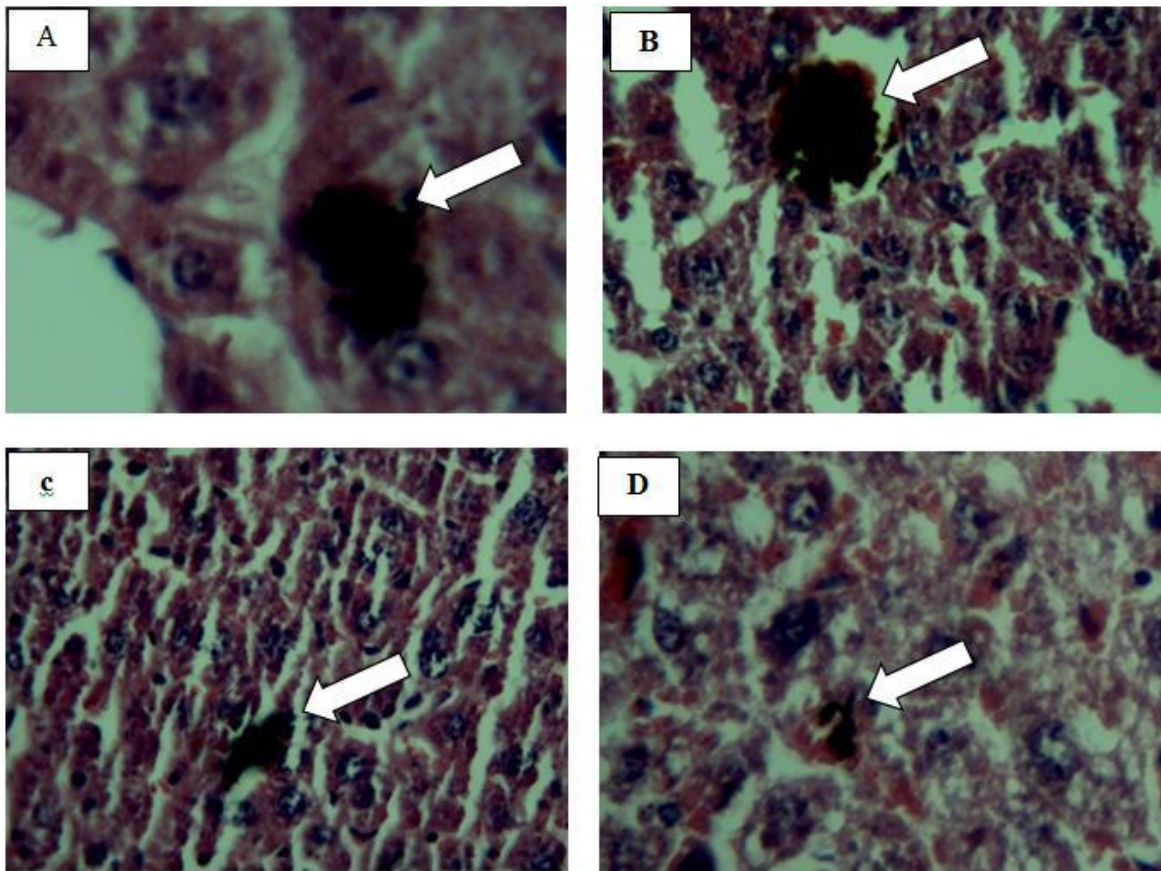
The intensity of the color of stains	Dose (ppm)/ number of necrotic stain				
	Control	0.5	0.2	0.1	0.05
	0	118.924	29.41	26.185	0

**Table 2.** Number of Color intense spot and severe necrosis in sub-lethal doses of *Mesobuthus eupeus* venom on Nmri hepatic tissue in the first round

The intensity of the color of stains	Dose (ppm)/ number of necrotic stain				
	Control	0.5	0.2	0.1	0.05
Mild	0	7	2	2	0
Moderate	0	23	2	0	0
Severe	0	0	0	0	0

**Table 3.** Average area of necrotic stains in sub-lethal doses of *Mesobuthus eupeus* venom on Nmri hepatic tissue in the second period

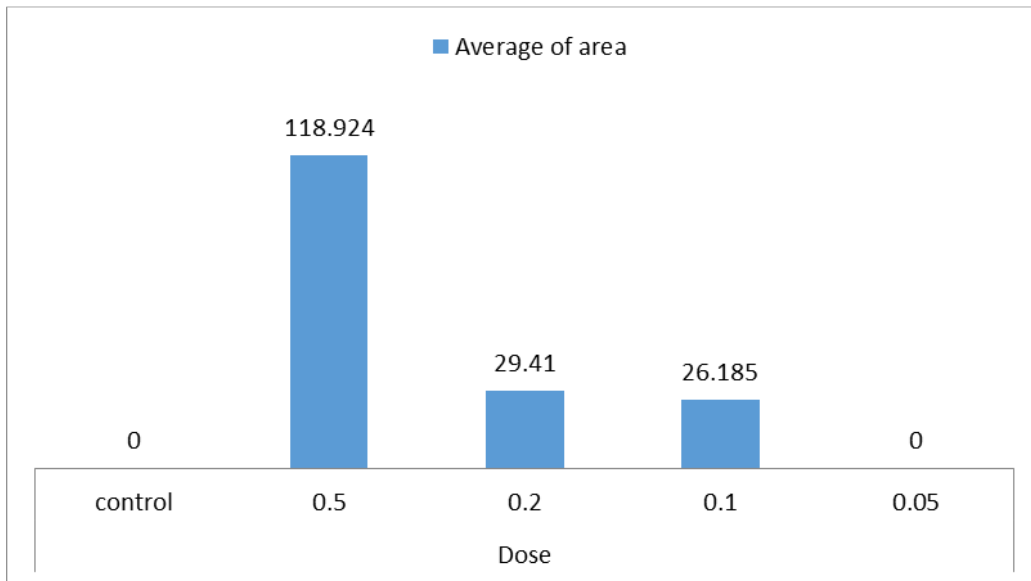
The intensity of the color of stains	Dose (ppm)/ number of necrotic stain				
	Control	1	0.4	0.2	0.1
	0	75.518	93.781	60.738	31.176



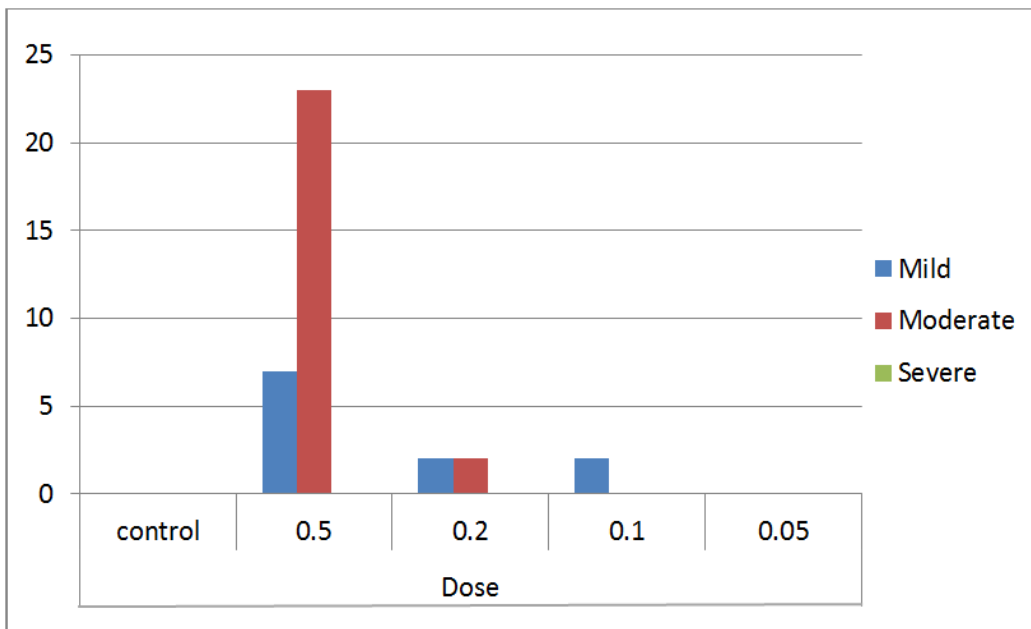
**Fig. 2.** Symptoms of liver necrosis due to effect of sub-lethal dose of scorpion venom of *Mesobuthus eupeus* changes in the images of A–D represent the different intensity of staining

**Table 4.** Number of Color intense spot and severe necrosis in sub-lethal doses of *Mesobuthus eupeus* venom on Nmri hepatic tissue in the second period

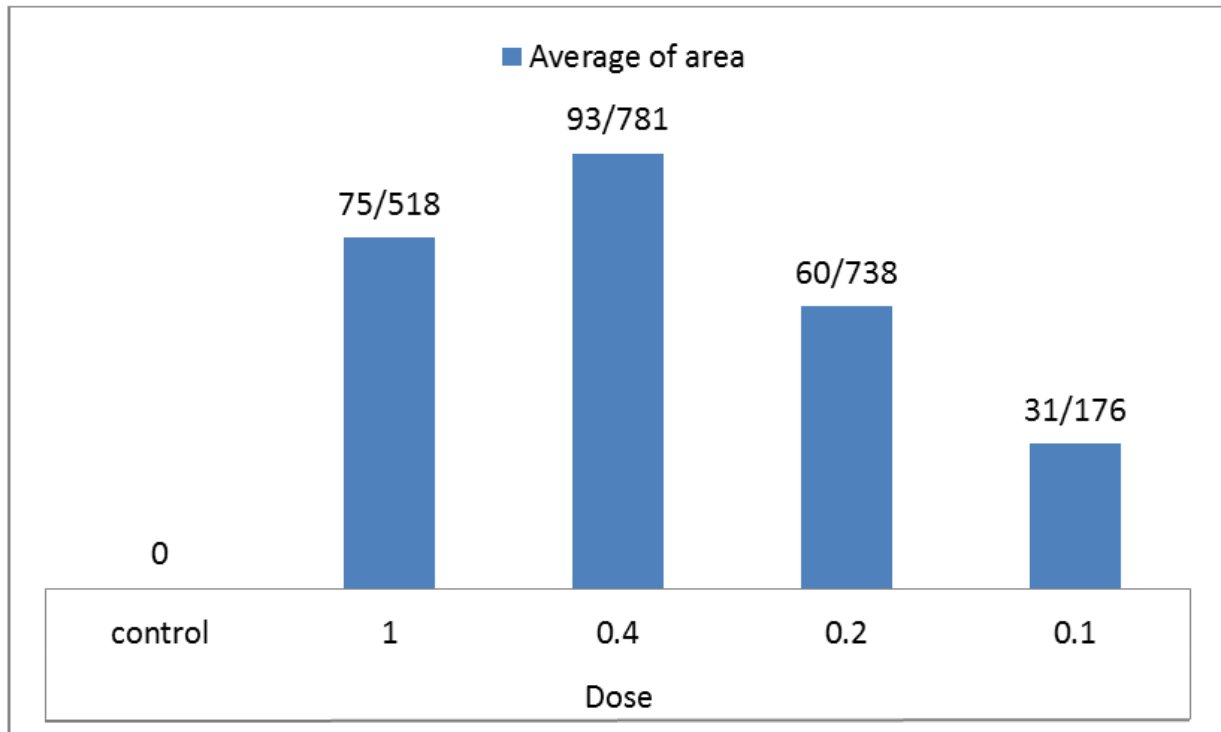
The intensity of the color of stains	Dose (ppm)/ number of necrotic stain				
	Control	1	0.4	0.2	0.1
Mild	0	1	0	1	0
Moderate	0	4	2	3	3
Severe	0	26	4	1	0



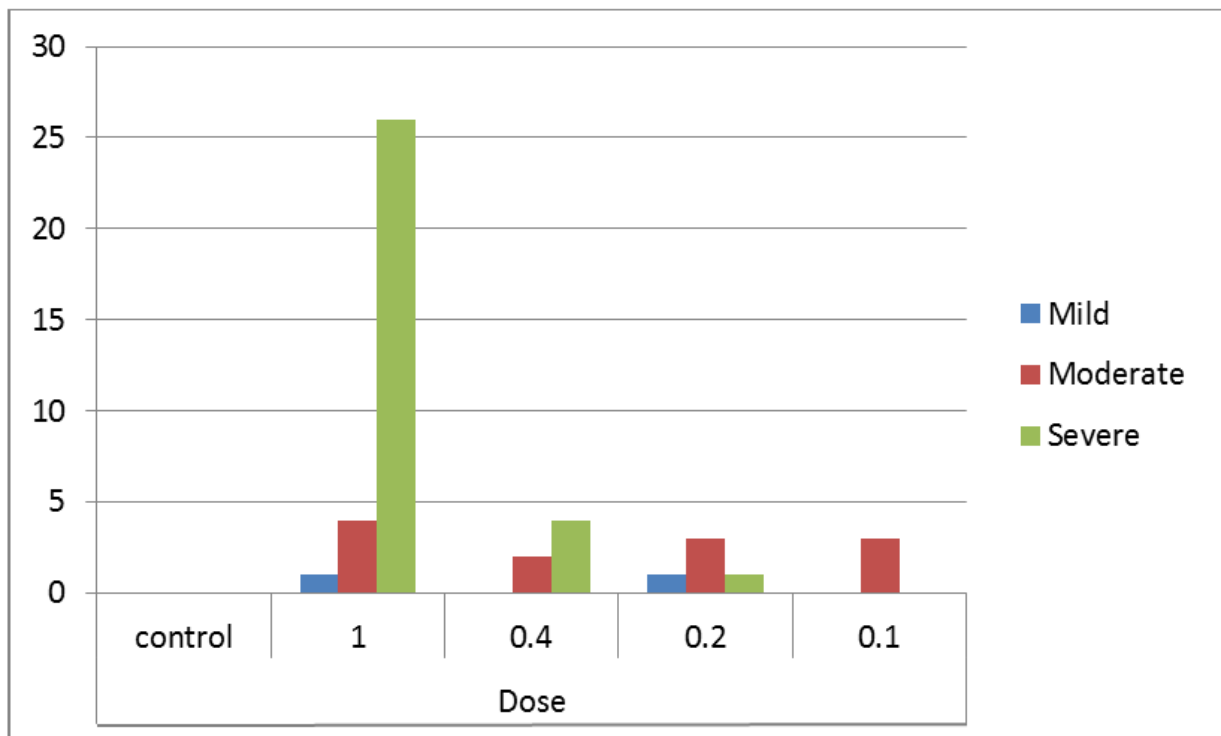
**Fig. 3.** Comparing the average area (µm<sup>2</sup>) of necrotic stains in sub-lethal doses (ppm) of *Mesobuthus eupeus* venom on Nmri liver tissue in the first round



**Fig. 4.** Comparing the number of color intensity of necrotic stains in sub-lethal dose (ppm) of *Mesobuthus eupeus* venom on Nmri liver tissue in the first round of test



**Fig. 5.** Comparing the average area (µm<sup>2</sup>) of necrotic spots in sub-lethal doses (ppm) of *Mesobuthus eupeus* venom on Nmri liver tissue in the second round



**Fig. 6.** Comparing the number of color intensity of necrotic stains in sub-lethal doses (ppm) of *Mesobuthus eupeus* venom on Nmri liver tissue in the second round of test

## Discussion

Phospholipase A2 is an important cause of inflammation in tissues (5). During 2005, some researcher used sub lethal doses of cobra venom and examined its effect on normal tissues as well as cancerous tissues such as skin, liver, kidney and heart tissue in animal models (rabbit). The results showed an increase in the synthesis of nucleic acids and a concentration of 25µg/ml was introduced as a therapeutic dose that prevents the increase in the production of nucleic acids and can be used in the treatment of cancerous tissues (10).

In some studies, the inhibitory effect of fraction 3 anticancer peptide of the scorpion venom of *Botus martensi* crush on liver cancer cells and its mechanism of action at different concentrations and at different times were investigated. They found that fraction 3 of the anti-cancer peptide of scorpion venom induces apoptosis endothelial in a dose-dependent manner. After 12 hours of treatment with different concentrations of 5, 10, 50, 100 and 200mg/l of scorpion venom, the rates of apoptosis were reported 6.1±3.0%, 15.3±4.9%, 48.5±5.2%, 66.7±6.5% and 91.2±6.9%, respectively. The results showed that fraction 3 of the anti-cancer peptide of scorpion venom was able to inhibit human liver cancer cells by inducing G2 apoptosis (11)

In addition, other studies investigated the effect of the SV-1 fraction of scorpion venom on the growth of SKOV3 ovarian cancer cells. The results showed that SV-1 could significantly inhibit the growth of SKOV3 ovarian cancer cells at concentrations of 200, 400 and 800mg/l.

Inhibition rates were reported at 29.87%, 48.11% and 67.77%, respectively. Therefore, they suggested that SV-1 could inhibit the proliferation and growth of SKOV3 ovarian cancer cells and that changes in the cell cycle and apoptosis may be important mechanisms of SV-1 inhibitory effects (12).

Necrosis, apoptosis, nuclear caryolysis, shrinkage of the cytoplasm, increase in cytoplasmic vacuoles and mitochondrial destruc-

tion are the results of the effects of animal venom that may be seen in various tissues (13).

In Cuba, the native scorpion species *Rhopalurus junceus* has been used in traditional medicine to treat cancer. The researchers found a range of scorpion venom concentrations (0.1, 0.25, 0.5, 0.75 and 1mg/ml) in a panel of human tumor epithelial cell lines (Hela, SiHa, Hep-2, NCI H292, A549, MDA-MB- 231, MDA-MB-468, HT-29) used hematopoietic cells and normal cells and compared the results. Only epithelial cancer cells showed a significant reduction in viability (IC50) of 0.6–1mg/ml and showed no effect on normal cells and hematopoietic cells. Hela cells also showed little effect on apoptosis. Among tumor cell types, A549 was the most sensitive. Necrosis caused by scorpion venom with acridine orange/ ethidium bromide fluorescent dye showed decreased expression of apoptosis-related genes. They concluded that the scorpion's venom has selective toxicity against epithelial cancer cells.

In general, we should know that scorpion venom fractions act selectively, and those compounds that inhibit the progression and proliferation of cancer cells by inducing apoptosis have no effect on normal cells. Therefore, it does not pose a risk to the person because it only targets cancer cells (15).

Necrosis studies agree the data of this study according to some others study (10, 12, 14). In this study, the number of spots did not show a significant increase with increasing dose from 0 to 0.4ppm, while increasing the number of necrosis spots increased from 0.5ppm to 1. The area of the spots increased with changes in dose from 0 to 0.5ppm (Figs. 3, 4) and did not show a significant change in the dose range of 0.5 to 1ppm (Figs. 5, 6). The intensity of necrosis spots in the dose range of 0 to 0.4ppm did not show a significant increase, while with a dose increase of 0.5 to 1ppm, a significant increase was observed.



## Conclusion

In the current study, the 0.05ppm of scorpion's venom of the doses used is a threshold dose for the appearance of symptoms. Signs began from the above dose and no other symptoms were noticed seen in the lower doses. In the field of scorpion's venom dose-response and its impacts on nucleic acid's synthesis Further studies are strongly recommended for more explanation.

## Acknowledgements

The authors would like to highly appreciate Dr H Sameni, Faculty of Medical Sciences for cooperation to the observation of microscopic slides and provide useful comments. This study was a part of PhD project of Sara Mojdegani-Fard at Department of Entomology, Science and Research Branch, Islamic Azad University, Tehran, Iran. The authors declare that there is no conflict of interests.

## References

- Xie W, Xing D, Zhao Y, Su H, Meng Z, Chen Y, Du L (2005) A new tactic to treat postprandial hyper-lipidemia in diabetic rats with gastro paresis by improving gastrointestinal transit. *Eur J Pharmacol.* 510(1–2): 113–120.
- Moosavi SM, Imani S, Haghighi S, Mousavi SE, Karimi A (2012) Effect of Iranian honey bee (*Apis mellifera*) venom on blood glucose and insulin in diabetic rats. *J Arthropod Borne Dis.* 6(2): 136–143.
- Roodbari L (2012) Effect of *Anderoctonus crassicauda* venom in the treatment of type 1 diabetes in rats. [MSC dissertation]. Tehran Islamic Azad University, Science and Research, Iran. (In Persian).
- Morgan NG, Montague W (1984) Stimulation of insulin secretion from isolated rat islets of Langerhans by melittin. *Biosci Rep.* 4(8): 665–671.
- Simonsson E, Karlsson S, Ahren B (2000) Islet phospholipase A(2) activation is potentiated in insulin resistant mice. *Biochem Biophys Res Commun.* 272(2): 539–543.
- Fujimoto WY, Metz SA (1987) Phasic effect of glucose, phospholipase A2, and lyso-phospholipids on insulin secretion. *Endocrinology.* 120(5): 1750–1757.
- Nemati M, Forouzan AR, Pouladgar A, Boroun F, Nemati A (2011) Antioxidant Effects of scorpion's venom components. The first regional congress on venomous animals and toxin, 2011 December 1–3, Razi Vaccine and Serum Research Institute, Karaj, Iran, pp. 92–93.
- Ghane M (2009) Studies on the identification, purification, determination of toxicity and molecular weight of *Bothotus schakh* venom. [MSC dissertation]. Tehran Islamic Azad University, Science and Research, Tehran, Iran (In Persian).
- Kadkhodayi alyadorani M, Amouzgari Z, Hanifi H (2007) Phospholipase and Hyaluronidase activity in *Mesobuthus eupeus* venom. *Feyz.* 4: 24–30.
- Roghani M, Bagheri A, Asyabi M, Hoda-vandkhani A (2004) Effect of the aqueous extract of coriander leaves in diabetic mice by STZ. *Iran J Endocrinol Metab.* 4: 259–255.
- Shaikh DM, Jokhio P (2005) Effect of snake venom on nucleic acid and total proteins in various normal and cancerous animal tissues. *Pak J Physiol.* 1: 1–2.
- Jian-Wei L, Jing H, Gui-Rong Z, Zheng-Ren W (2006) Effects of anti-cancer peptide fraction 3 from *Buthus Martensii Karsch* on apoptosis of human liver cancer cells. *J Jilin Univ Med Ed.* 32: 625–628.
- Shi-bo F, Ying Y, Feng-qin Y, Shu-chun L, Peng-wu L, Gui-zhi J (2007) Inhibitory effects of fraction from scorpion venom on growth of SKOV3 ovarian carcinoma cells. *J Jilin Univ Med Ed.* 33: 41–43.
- Shahramyar Z, ZareMirakabad A, Morovat



- H, Lotfi M, Nouri AQ (2011) Induction of apoptosis in human Leukemia cell line (HL60) by animal's venom derived peptides (ICD-85). The first regional congress on venomous animals and toxin, 2011 December 1–3, Razi Vaccine and Serum Research Institute, Karaj, Iran, pp. 174–175.
15. García AD, Díaz LM, Herrera YF, Sánchez HR, Lorenzo YC, Llanes DM, Garlobo YR, Castro JF (2013) In vitro anticancer effect of venom from Cuban scorpion *Rhopalurus junceus* against a panel of human cancer cell lines. J Venom Res. 4: 5–12.