



2020

## Detection of Left Ventricular Thrombi On Cardiac Magnetic Resonance Viability Studies

Follow this and additional works at: <https://www.j-saudi-heart.com/jsha>



Part of the [Cardiology Commons](#), [Diagnosis Commons](#), and the [Radiology Commons](#)



This work is licensed under a [Creative Commons Attribution-Noncommercial-No Derivative Works 4.0 License](#).

### Recommended Citation

Alhassan, Donya Ahmed; Waheed, Khawaja Bilal; Sharif, Muhammad Nasim; UIHassan, Muhammad Zia; Ghaffar, Fazal; Saleem, Khaled Saleh; Said, Emad Fouad Mahmoud; Altalaq, Bayan Mohammed; Arulanantham, Zechariah Jebakumar; and Qarmash, Ahmad Omar (2020) "Detection of Left Ventricular Thrombi On Cardiac Magnetic Resonance Viability Studies," *Journal of the Saudi Heart Association*: Vol. 32 : Iss. 3 , Article 2.

Available at: <https://doi.org/10.37616/2212-5043.1042>

This Original Article is brought to you for free and open access by Journal of the Saudi Heart Association. It has been accepted for inclusion in Journal of the Saudi Heart Association by an authorized editor of Journal of the Saudi Heart Association.

---

## Detection of Left Ventricular Thrombi On Cardiac Magnetic Resonance Viability Studies

### Cover Page Footnote

We like to pay special thanks to our senior colleague Dr. Donya Ahmed AlHassan for providing her assistance in reviewing the submitted figures for clarity and correctness.

# Detection of Left Ventricular Thrombi on Cardiac Magnetic Resonance Viability Studies

Donya A. Alhassan<sup>a</sup>, Khawaja Bilal Waheed<sup>a,\*</sup>, Muhammad N. Sharif<sup>b</sup>, Muhammad Z. Ul Hassan<sup>a</sup>, Fazal Ghaffar<sup>b</sup>, Khaled S. Salem<sup>a</sup>, Emad F.M. Said<sup>a</sup>, Bayan M. Altalaq<sup>a</sup>, Ahmad O. Qarmash<sup>a</sup>, Zechariah J. Arulanantham<sup>c</sup>

<sup>a</sup> Department of Radiology, King Fahad Military Medical Complex, Dhahran, Saudi Arabia

<sup>b</sup> Department of Cardiology, King Fahad Military Medical Complex, Dhahran, Saudi Arabia

<sup>c</sup> Prince Sultan Military College of Health Science, Dhahran, Saudi Arabia

## Abstract

**Objective:** To highlight detection of left ventricular thrombi on cardiac magnetic resonance (CMR) viability studies.

**Method:** This retrospective observational study was conducted in the Radiology Department at our Hospital in Dhahran, from April 2015-2019. All recently re-perfused (post-percutaneous coronary intervention/ PCI) patients with ST-segment elevation myocardial infarctions (STEMI), having low ejection fractions (<40%), impaired LV functions or abnormal wall motions on transthoracic echocardiographies (TTEs), who underwent cardiac magnetic resonance (CMR) imaging viability studies were included. Patients with incomplete or limited studies (due to artifacts), previous coronary artery bypass graft (CABG), those who lost follow-ups, and those who were contraindicated or unfit for MRIs were excluded. An area of low signal intensity with no late gadolinium enhancement (LGE) was defined as thrombus on MR imaging, and two radiologists reached consensus report for the diagnoses. Patients with anterior or non-anterior wall MI were documented, and their ejection fractions were recorded. Percentage estimation of LV thrombi as detected on CMR studies was made. Any complications (like MI, stroke or death) that occurred within one year of diagnoses were documented. A Chi-square was used to determine association.

**Results:** Of the 125 patients, most were men (71.2%) with a mean age of 56.78 years. Eleven patients had left ventricular thrombi (8.8%), and most of these were anterior wall infarctions with low ejection fractions (<40%). Three out of 11 patients with LV thrombi developed complications versus 3 out of 114 without LV thrombi (P- value, .0005).

**Conclusion:** Left ventricular thrombi can be detected on cardiac viability studies in recently re-perfused STEMI patients and may possibly predict the risk of complications.

**Keywords:** Magnetic resonance imaging, Thrombus, Myocardial infarction

## 1. Introduction

Myocardial infarction (MI) is a life-threatening condition that occurs when the blood flow to the heart muscle (or myocardium) is abruptly restricted, leading to tissue death or infarction. Acute myocardial infarction is one of the leading causes of death in the developed world, affecting nearly 3 million people worldwide and accounts

for more than a million deaths annually in the United States [1]; 70% of victims have occlusions from atherosclerotic plaques. Acute MI can be either a non-ST-segment elevation MI (NSTEMI) or ST-segment elevation MI (STEMI). Treatment for STEMI includes immediate reperfusion i.e., emergent percutaneous coronary intervention (PCI) within 12–48 h of admission. This may reduce in-hospital mortality and decrease the

Received 30 April 2020; revised 31 May 2020; accepted 17 June 2020.  
Available online 17 August 2020

\* Corresponding author. Consultant Radiology Department, King Fahad Military Medical Complex, Dhahran, Saudi Arabia  
E-mail addresses: docbil@hotmail.com, khawaja@kfmmc.med.sa (K.B. Waheed).



<https://doi.org/10.37616/2212-5043.1042>

2212-5043/© 2020 Saudi Heart Association. This is an open access article under the CC-BY-NC-ND license (<http://creativecommons.org/licenses/by-nc-nd/4.0/>).

length of stay [2]. Acute MI continues to have a high mortality out of the hospital [3]. The risk of cardiovascular events, stroke, and death increase after the acute myocardial event [4] and may be multifactorial [5].

Several indirect techniques have been introduced to assess myocardial viability including echocardiography, fluoro-2-deoxyglucose (FDG) positron emission tomography (PET), and  $^{201}\text{Tl}$  single-photon emission computed tomography (SPECT) [6]. More recently, cardiac computed tomography has also been used to identify coronary artery disease (myocardial perfusion imaging), evaluate global LV function and regional wall motion (multi-phase cine imaging), and to detect myocardial scar in myocardial infarction (delayed enhancement imaging) [7]. However, MRI remains the gold standard with its unique capability to provide quantitative information on cardiac function, perfusion, and viability [8]. Unlike echocardiography, magnetic resonance imaging (MRI) has no technical limitations due to acoustic window or artifacts related to chest wall with its multiplanar acquisition. MRI also offers more spatial and temporal resolution than nuclear medicine modalities and better tissue characterization [7]. In addition, MRI does not use ionizing radiation, this is another advantage with respect to other imaging modalities such as computed tomography (CT) or nuclear medicine.

Left ventricular (LV) thrombus is a complication of acute MI and is associated with systemic thromboembolism. Although standard transthoracic echocardiogram (TTE) is commonly used for screening, it is limited by low sensitivity for detection of LV thrombus [9]. Magnetic resonance imaging has a high yield in detection of these thrombi. Anatomic (morphologic) assessment by dark blood and bright blood sequences as well as cardiac function (motion) assessment by Steady-State Free Precession (SSFP)-based bright-blood images of the beating heart are useful for diagnosis. Perfusion imaging (also known as first-pass images) and myocardial viability (or myocardial enhancement study) can add insight [10]. Pre-contrast images are first obtained with first-pass perfusion imaging following injection of a half-dose of gadolinium. After injecting an additional half-dose of gadolinium, delayed images are obtained at 10 and 20 min. Ischemic myocardium typically shows delayed enhancement due to increased accumulation of contrast agent in combination with delayed washout over time [11]. Delayed enhancement identifies infarction or fibrotic tissue, while the absence of enhancement

#### Abbreviations' list

LV	Left Ventricular
STEMI	ST segment Elevation Myocardial Infarction
NSTEMI	Non-ST segment Elevation Myocardial Infarction
CMR	Cardiac Magnetic Resonance
MI	Myocardial Infarction
MRI	Magnetic Resonance Imaging
FDG	Fluoro-2-Deoxyglucose
PET	Positron Emission Tomography
Tl	Thallium
SPECT	Single-Photon Emission Computed Tomography
TTE	Transthoracic Echocardiogram
SSFP	Steady-State Free Precession
CABG	Coronary Artery Bypass Grafting
HIS	Hospital Information System
RIS	Radiology Information System
PACS	Picture Archiving and Communication System
T	Tesla
FIESTA	Fast Imaging Employing Steady-state Acquisition
TE	Time to Echo
TR	Time to Repeat
IR	Inversion Recovery
SSh	Single Shot
PS	Phase Sensitive,
MDE	Myocardial Delayed Enhancement
SA	Short Axis
CH	Chamber
MVO	Micro-vascular Obstruction
SPSS	Statistical Package for Social Sciences
MDE	Myocardial Delayed enhancement
DGE	Delayed Gadolinium Enhancement
EGE	Early Gadolinium Enhancement
TI	Time to inversion

indicates viable myocardium, which is likely to improve following revascularization [8].

Although various studies in the literature have focused on the sensitivities and specificities of both TTE and CMR in the detection of LV thrombi after recent acute MI [12], only few of these have described ability of CMR to identify LV thrombi in patients with recently re-perfused STEMI patients specifically indicated for MRIs. Therefore, we aim to detect LV thrombi on cardiac viability studies in such selected subgroup of patients.

## 2. Materials and methods

This retrospective observational study was conducted in the Radiology Department at our Hospital in Dhahran from April 2015 to April 2019.

As the study was retrospective and did not involve disclosure of any patient information and privacy, the ethics committee of our Hospital waived the need for patient consent. The study was conducted

in accordance with the Helsinki Declaration. All clinical and radiologic information were kept strictly confidential. Literature review was performed through electronic search (Google Scholar, PubMed).

### 2.1. Study population & selection criteria

All recently re-perfused (post-PCI) STEMI patients ( $n = 125$ ) who were negative for LV thrombi on TTEs (within 24–48 h), and underwent cardiac MR viability studies (performed within 2 weeks) due to either low ejection fractions or impaired LV functions were enrolled. Patients with positive TTEs (for LV thrombi) were excluded, as majority of these were followed-up on contrast enhanced TTEs. Also, patients with limited MR studies (with artifacts), those with previous CABG and those who were contraindicated to MRI machine and contrast were excluded [Fig. 1]. Time between TTE and MRI was between 7 and 14 days.

### 2.2. Cardiac MR scanning protocol

Cardiac MR imaging studies were performed on a 1.5 T scanner machine (General Electric/GE, Optima 450 W GEM, 2013, Florence, South Carolina, USA), using gadolinium-based contrast agent (Dotarem,

.2 mmol/kg; Guerbet, France). Imaging included FIESTA (Fast Imaging Employing Steady-state Acquisition) cine, 2 and 4 Chamber (CH) FIESTA sequences (TR/TE, 3.0/1.5 msec; flip angle,  $60^\circ$ ), cine IR (inversion recovery, two R–R intervals), single shot (SSh)- early and delayed, phase sensitive (PS) myocardial delayed enhancement (MDE) short axis (SA), 2CH and 4CH 3D MDE images, besides acquiring reformatted (magnitude) SA, 2CH and 4CH MDE images. Typical imaging parameters for cine CMR were field of view (FOV) 300–360 mm, slice thickness 6 mm, 3.1 ms repetition time, 1.6 ms echo time, flip angle  $50^\circ$ , image matrix  $256 \times 156$ , and temporal resolution 30–40 ms. CMRs were also tailored for thrombus assessment by prolonging the inversion time (i.e., 600 msec) to selectively null avascular tissue such as thrombus. Delayed images were acquired up to 10–15 min after injection. Delayed enhancement images were obtained by a 2-dimensional segmented inversion-recovery gradient echo pulse sequence with slice position and parameters identical to the cine images. Total imaging time was about 45–60 min.

### 2.3. Data collection & interpretation

Clinical information and radiographic/imaging findings were acquired through patients' clinical

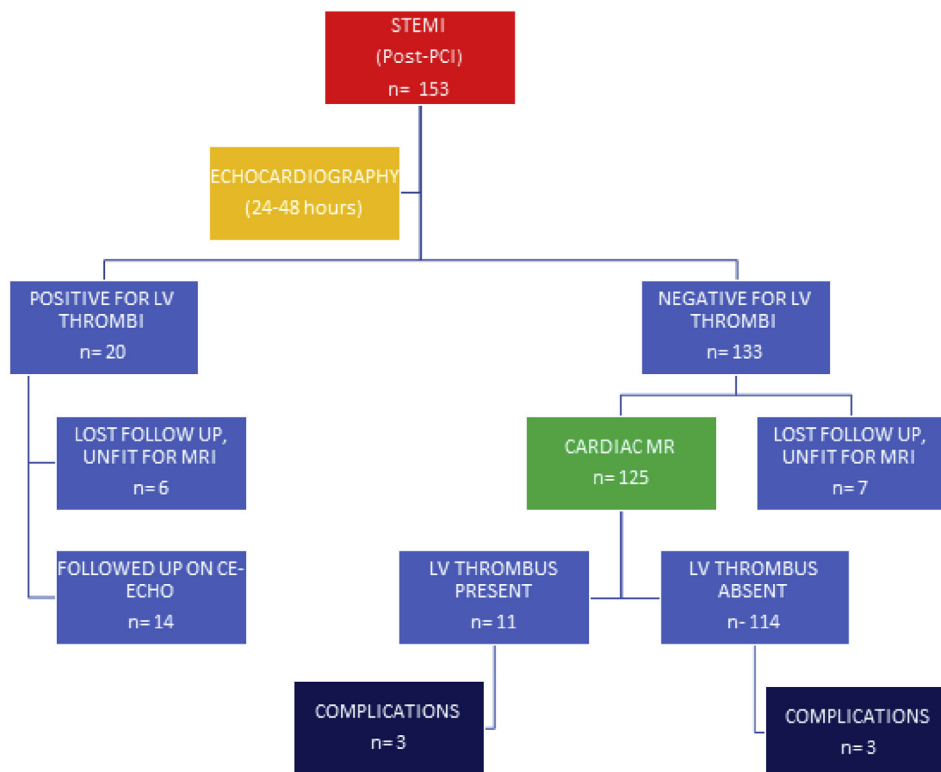


Fig. 1. Flow chart demonstrating enrolled population for cardiac MRI viability studies.

notes/Hospital Information System (HIS) and Radiology Information System/Picture Archiving and Communication System (RIS/PACS). Demographic information about age and gender of all patients was collected. Information about ejection fractions and type of STEMI (anterior wall or non-anterior wall) were recorded from the clinical notes and echocardiographies.

Cardiac MR imaging studies were interpreted by two readers, one an expert thoracic radiologist and other an experienced general radiologist (each having more than 7 years of experience). The LV thrombus was identified on cardiac MR as a low-signal intensity mass surrounded by high-signal intensity structures such as intracavitary blood or hyper-enhanced (infarcted) myocardium, typically adherent to regions of abnormal wall motion (as seen on cine and confirmed by late DE). Left ventricular thrombus was carefully distinguished from microvascular obstruction (MVO), which also appeared as a dark area in the site of infarction; LV thrombi not completely encompassed by surrounding hyperenhanced myocardium, located adjacent to LV cavity and remain stable size on early and late gadolinium enhancement in contrast to MVO that were seen completely encompassed by hyperenhanced myocardium, located within myocardium, and shrank with contrast fill-in on gadolinium enhancement [9]. Good inter-observer agreement was noted (with Cohen's kappa value of .7), and consensus reading was reached in cases of minor disagreements.

#### 2.4. Follow up

Confirmation of detected LV thrombi were made by observation of interval changes (i.e., changes in appearance and size of initially identified thrombus like regression or resolution) after commencement of anticoagulation (on identification of LV thrombi on initial CMRs) on follow-up contrast enhanced TTE and CMRs performed within 3–6 months interval.

Complications like cardiac event/MI, stroke, and death within a period of one year after detection of

thrombi were documented. Stroke was defined as new onset focal neurologic deficit caused by ischemia or hemorrhage as seen on imaging (either CT or MRI).

#### 2.5. Statistical analysis

Percentage estimation for detection of LV thrombi on CMR was made. The statistical analysis was carried out using Statistical Package for Social Sciences (SPSS, version 22). Chi-square test was used to determine association, and P-values less than .05 were considered significant.

### 3. Results

Out of 125 patients, 89 (71%) were males and 36 (29%) were females, aged between 40 and 78 years (mean age, 56.78; standard deviation, 8.42).

Left ventricular thrombi were seen in 11 patients (8.8%), of these 9 were having anterior wall infarctions [Table 1]. No significant association of LV thrombi with type of infarctions was observed (P-value, .36).

Left ventricular thrombi were seen mainly at the apex or along the wall of aneurysm [Figs. 2 and 3]. These detected thrombi were confirmed on follow-up CE-TTEs (in 7 cases) and CMRs (in 4 cases). Thrombi detected on CMR but missed by initial TTE were found to be mural and smaller in sizes.

Ejection fractions of less than 40 were observed to be associated with anterior wall location of infarctions (P-value, .0005), while these were not seen significantly associated with LV thrombi [Tables 2 and 3].

Complications (stroke, death) were seen significantly associated in patients with LV thrombi (P-value, .0005) [Table 4].

### 4. Discussion

Coronary artery disease and MI remain a major cause of global morbidity and mortality, although the incidence has reduced since the introduction of coronary intervention [13]. Prompt identification of acute myocardial event and close monitoring may

Table 1. Distribution of patients with type (location) of infarctions and presence or absence of LV thrombi.

		LV Thrombus		Total number, percentage
		Not Present	Present	
		number, percentage	number, percentage	
Location	Anterior Wall	78, 89.7%	9, 10.3%	87, 100.0%
	Non-anterior Wall	36, 94.7%	2, 5.3%	38, 100.0%
Total		114, 91.2%	11, 8.8%	125, 100.0%



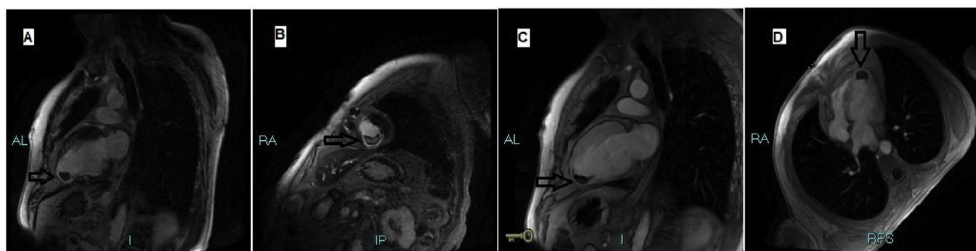


Fig. 2. Selected images of CMR in a 62 years old patient showing low intensity LV thrombus at the cardiac apex. A- Long axis vertical 2CH (DGE) view. B- Short axis MDE (DGE) view. C- Long axis vertical 2CH (EGE) view, long inversion time (TI). D- Long axis horizontal 4CH (EGE) view, long inversion time (TI). CMR- Cardiac Magnetic Resonance, LV- Left Ventricular, CH- Chamber, MDE- Myocardial Delayed enhancement, DGE- Delayed Gadolinium Enhancement, EGE- Early Gadolinium Enhancement, TI- Time to Inversion.

prevent associated complications. Detailed knowledge of complications and risk factors can help clinicians to adopt early management and better prognosis. Left ventricular (LV) thrombus is a serious complication of STEMI resulting from blood stasis after LV dysfunction and altered configuration (aneurysm formation) [14]. The LV thrombi continues to occur in a small but substantial number of such patients especially with anterior wall infarctions. The presence of the thrombus can provide an embolic substrate for future embolic events [3,4]. Echocardiography has traditionally been used for initial evaluation in these patients. However, echo can be limited or technically difficult for assessment of thrombi at the apex (i.e., close to chest wall) and are usually suspected [15]. Therefore, an additional modality like CMR imaging is needed.

We used both early and delayed myocardial enhancement (EMR and DME) in cardiac magnetic resonance (CMR) imaging for discerning viable from the infarcted tissue and also for identification of thrombus (by absence of contrast uptake). Several studies have validated yield of CMR versus echocardiography in terms of improved diagnostic performance [8,11,12]. It should be emphasized that improved detection of LV thrombi by DE-CMR over contrast-echo and even cine-CMR is largely attributable to intrinsic feature of imaging technique, evaluating tissue characterization rather than only tissue morphology. In our study, we found an 8.8% incidence of cardiac thrombus on such cardiac MRI studies. Weinsaft JW et al (2016) showed a similar percentage of 8% for MR detected LV thrombi, and observed a high yield of improved thrombus detection by the MRI when compared to echocardiography [15]. They also proposed that apical wall motion and ventricular dysfunction on echocardiogram can be an effective stratification tool for identification of patients to be assessed for contrast

enhanced cardiac MRI. Since the introduction of percutaneous coronary intervention (PCI) and more aggressive anticoagulation, the incidence of LV thrombi has reduced from less than 46% to between 4 and 15%. Pöss J et al. (2015) found an overall prevalence of LV thrombi to be 3.5% among 795 patients who underwent cardiac MRI, and 7.1% in anterior STEMI that correlated with our study results [16]. Meurin P et al. (2015) found a 26% incidence of thrombi in 100 patients, 19 of these were seen on MRI, but they included patients with positive transthoracic echocardiography (TTE) as well [9], which we did not include. We also did not document prior PCI or anticoagulation regimes in our patients, however, Meurin P et al. observed LV thrombi in 22.7% of patients who underwent primary PCI versus 50% in others (on anticoagulation). In our study, most of the thrombi were found to be at the apex and along the wall (mural), that are usually missed by echocardiography due to technical reasons of proximity to chest wall and echotextural characteristics, respectively. These observations were also highlighted by Meurin P et al in their prospective study and matched with our findings.

In our study, we found a significant association ( $p$  value, .0005) of presence of LV thrombi to complications (like stroke and death) when compared to those who were not having thrombi detected on cardiac MRI within one year of cardiac event. Also, we observed a lower EF (less than 40) to be strongly associated with anterior wall infarctions ( $p$  value, .0005), but not the with presence of thrombi. Kim J and Weinsaft JW (2015) evaluated cardiac MRI studies in 738 patients with STEMI and found that patients with thrombi had lower LV ejection fraction and larger LV volumes [14,15]. Also, they observed that thrombus related adverse events were strongly associated with heart failure rather than mortality.

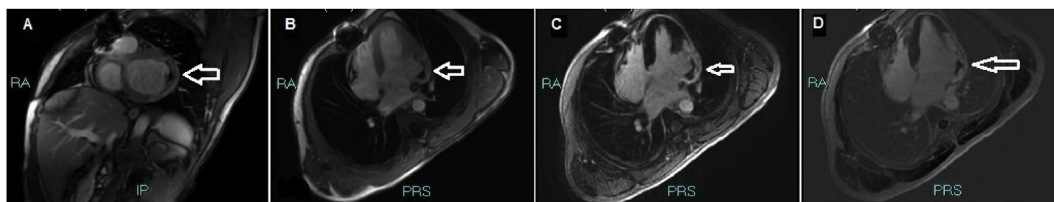


Fig. 3. Selected images of CMR in a 40 years old patient showing low intensity LV thrombus along the wall of aneurysm. A- Short axis (EGE) view. B- Long axis horizontal 4 CH (EGE) view. C- Long axis horizontal 4CH MDE (DGE) view. D- Long axis horizontal 4CH (DGE) view, PS, CMR- Cardiac Magnetic Resonance, LV- Left Ventricular, CH- Chamber, MDE- Myocardial Delayed enhancement, DGE- Delayed Gadolinium Enhancement, EGE- Early Gadolinium Enhancement, PS- Phase Sensitive.

But they did not specifically mention thrombus location and aneurysmal dilatation. Merkle AE et al. (2019) found a 9% short term risk of ischemic stroke in patients with LV thrombus detected on DE-CMR [17]. Takasugi J (2017) found prevalence of embolic stroke of undetermined source of about 22% in patients with myocardial infarctions or LVEFs less than 50; out of these nearly half of these were found to be cardioembolic in origin and 20% were having LV thrombus on cardiac MRI [18]. We found 2 of 3 patients with ischemic stroke and death in one patient within a year of LV thrombus detection. However, it should be noted that several other factors may also be related to such complications, and mere presence of LV thrombi and its correlation may not be over-emphasized. Most of these (5 out of 8) LV thrombi were subsequently confirmed on CE echocardiographies or ventriculograms. Follow up MRIs were performed in only a few of the survived patients (3 out of 8), that showed either regression or disappearance of thrombus with ongoing anti-platelet therapy. Pop C and his colleagues (2019)

observed reduction in ischemic events after dual antiplatelet anticoagulation in patients with acute coronary syndrome [19]. Rizas KD et (2019) recently presented a novel electrocardiographic phenomenon called periodic repolarization dynamics (PRD) that they found to be a strong predictor of total and cardiovascular mortality in post-infarction patients [20]. Cambroner-Cortinas E et al. found CMR to be helpful in both diagnosis and therapy by guiding the initiation or withdrawal of anticoagulants [21]. Also, they observed that the patients with simultaneous anterior wall infarctions and low EF (less than 50) were at the highest risk of developing LV thrombi, nearly like our study results.

Although we did not specifically document microvascular obstruction (MVO), however, we observed this phenomenon in few of the patients. We strongly feel that recognition of this entity by employing first pass (FP), early and late gadolinium enhancement (EGE and LGE) are important to differentiate MVO from thrombus. The hypo-perfused area within the infarct seen after 1–2 min

Table 2. Distribution of patients by ejection fractions and location of infarctions.

		Location of infarction		Total number, percentage
		Anterior wall	Non anterior wall	
		number, percentage	number, percentage	
Ejection Fraction	Less than 40	59, 100.0%	0, .0%	59, 100.0%
	41 and above	28, 42.4%	38, 57.6%	66, 100.0%
Total		87, 69.6%	38, 30.4%	125, 100.0%

Table 3. Distribution of patients by ejection fractions and presence of LV thrombi.

		LV thrombus		Total number, percentage
		Not present	Present	
		number, percentage	number, percentage	
Ejection Fraction	Less than 40	51, 86.4%	8, 13.6%	59, 100.0%
	41 and above	63, 95.5%	3, 4.5%	66, 100.0%
Total		114, 91.2%	11, 8.8%	125, 100.0%



Table 4. Distribution of patients by LV thrombi and prognosis.

		Prognosis		Total number, percentage
		No complication number, percentage	Complication number, percentage	
LV thrombus	Not present	11, 97.4%	3, 2.6%	114, 100.0%
	Present	8, 72.7%	3, 27.3%	11, 100.0%
Total		119, 95.2%	6, 4.8%	125, 100.0%

of contrast administration i.e., early MO has been found closely related to anatomic no-flow region but was smaller than pathologic region [22]. As gadolinium is not pure intravascular agent, it gradually diffuses into initially hypoperfused zone, hence the size of MVO decreases over time, being largest during first pass and smallest during late gadolinium enhancement (termed 'persistent' MO). First pass perfusion sequences (during first minute of gadolinium administration) suffer relatively low spatial resolution and reduced LV coverage resulting in reduced diagnostic sensitivity. Now, ultra-fast inversion-recovery (IR) gradient echo sequences are usually employed to assess MO on both EGE (between 2 and 4 min) and LGE, with the advantages of improved spatial resolution and complete LV coverage [23]. It should also be noted that temporal course of MO may vary in subsequent days to weeks of infarct healing and may influence LV remodeling. Earlier resolution of MO appears to correlate with improved functional recovery after MI and outcome. Concept of functional (that may resolve more quickly) and structural no-flow (that requires prolonged infarct tissue healing) need to be kept in mind for better understanding of pathophysiology and appearance on CMR [24]. We did not correlate MVO with clinical outcome, although it has been found to be predictive of clinical outcome, either independently or when adjusted with other parameters like infarct size and LV ejection fraction. Presence of hemorrhage (associated with reperfusion injury) with MVO has also been found to be highly correlated with pathologic infarct size [22–24]. Therefore, standardized approach and optimal CMR protocol are advised for acquiring detailed information from CMR.

Other limitations in our study included a small sample, retrospective, and a single center study. We strongly feel that an early CE echocardiography in 1–2 weeks interval of an acute MI can be helpful in stratifying patients for DE-CMR by identification of apical wall motion, ventricular dysfunction, or aneurysm. Such approach should be an essential part of management pathway in any cardiac center or Hospital dealing with MI patients. Documentation

of any associated LV thrombus in such patients may help to modify anticoagulation/treatment regimens and may possibly predict cardioembolic complications, though a multivariate analysis such as those presented earlier in literature [9,14,16,21] detailing patient characteristics was lacking in our study.

## 5. Conclusion

Left ventricular thrombi in patients with recent MI/STEMI can be detected by cardiac MR viability studies and may possibly predict the risk for complications.

## Author contribution

Conception: Donya Ahmed Alhassan, Khawaja Bilal Waheed, Muhammad Naseem Sharif. Literature review: Donya Ahmed Alhassan, Khawaja Bilal Waheed, Muhammad Naseem Sharif. Software: Khawaja Bilal Waheed, Muhammad Naseem Sharif, Fazal Ghaffar, Bayan Mohammed Altalaq. Analysis and/or interpretation: Donya Ahmed Alhassan, Khaled Saleh Salem, Emad Fouad Mahmoud Said. Investigation: Donya Ahmed Alhassan, Khawaja Bilal Waheed, Bayan Mohammed Altalaq, Ahmad Omar Qarmash. Resources: Khawaja Bilal Waheed, Muhammad Zia Ul Hassan, Fazal Ghaffar. Data collection and/or processing: Khawaja Bilal Waheed, Muhammad Naseem Sharif, Muhammad Zia Ul Hassan, Fazal Ghaffar. Writer-original draft: Bayan Mohammed Altalaq, Ahmad Omar Qarmash, Zechariah Jebakumar Arulanantham. Writing-review & editing: Khawaja Bilal Waheed, Muhammad Zia Ul Hassan, Khaled Saleh Salem, Emad Fouad Mahmoud Said. Visualization: Khawaja Bilal Waheed, Khaled Saleh Salem, Emad Fouad Mahmoud Said, Bayan Mohammed Altalaq, Ahmad Omar Qarmash, Zechariah Jebakumar Arulanantham. Supervision: Donya Ahmed Alhassan, Muhammad Zia Ul Hassan, Khaled Saleh Salem, Emad Fouad Mahmoud Said. Project administration: Donya Ahmed Alhassan, Khawaja Bilal Waheed, Muhammad Naseem Sharif. Fundings: Khawaja Bilal Waheed, Muhammad Zia Ul Hassan.

## Conflict of interest

The authors declare that there is no conflict of interest.

## Disclosure of funding

Authors declare that no financial assistance (grant or funding) and material support taken for this research.

## Acknowledgment

We like to pay special thanks to our senior colleague Dr. DAA for providing her assistance in reviewing the submitted figures for clarity and correctness.

## References

- [1] Mechanic OJ, Grossman SA. Acute myocardial infarction. StatPearls [internet]. Treasure island (FL). StatPearls Publishing; 2019. 2019 Jan 23. PMID: 29083808.
- [2] Ong P, Sechtem U. Controversies in the treatment of patients with STEMI and multivessel disease: is it time for PCI of all lesions? *Clin Res Cardiol* 2016 Jun;105(6):467–70. <https://doi.org/10.1007/s00392-016-0963-3>. PMID: 26850062.
- [3] Rossello X, Bueno H, Pocock SJ, Van de Werf F, Danchin N, Annemans L, et al. Predictors of all-cause mortality and ischemic events within and beyond 1 year after an acute coronary syndrome: results from the EPICOR registry. *Clin Cardiol* 2019 Jan;42(1):111–9. <https://doi.org/10.1002/clc.23116>. Epub 2018 Dec 7. PMID: 30443916.
- [4] Wang Y, Li J, Zheng X, Jiang Z, Hu S, Wadhera RK, et al. Risk factors associated with major cardiovascular events 1 Year after acute myocardial infarction. *JAMA Netw Open* 2018 Aug 3;1(4):e181079. <https://doi.org/10.1001/jama-networkopen.2018.1079>. PMID: 30646102 PMCID: PMC6324290.
- [5] Węgiel M, Dziewierz A, Wojtasik-Bakalarz J, Sorysz D, Surdacki A, Bartuś S, et al. Hospitalization length after myocardial infarction: risk-assessment-based time of hospital discharge vs. Real life practice. *pii J Clin Med* 2018 Dec 18; 7(12):E564. <https://doi.org/10.3390/jcm7120564>. PMID: 30567307 PMCID: PMC6306951.
- [6] Saeed M, Van TA, Krug R, Hetts SW, Wilson MW. Cardiac MR imaging: current status and future direction. *Cardiovasc Diagn Ther* 2015 Aug;5(4):290–310. <https://doi.org/10.3978/j.issn.2223-3652.2015.06.07>. PMID: 26331113 PMCID: PMC4536478.
- [7] Ko SM, Kim TH, Chun EJ, Kim JY, Hwang SH. Assessment of left ventricular myocardial diseases with cardiac computed tomography. *Korean J Radiol* 2019 Mar;20(3):333–51. <https://doi.org/10.3348/kjr.2018.0280>. PMID: 30799565.
- [8] Sun W, Sun L, Yang F, Zhao X, Cai R, Yuan W. Evaluation of myocardial viability in myocardial infarction patients by magnetic resonance perfusion and delayed enhancement imaging. *Herz* 2018 Oct 15. <https://doi.org/10.1007/s00059-018-4741-z>. PMID: 30324340.
- [9] Meurin P, Brandao Carreira V, Dumaine R, Shqueir A, Milleron O, Safar B, et al. Incidence, diagnostic methods, and evolution of left ventricular thrombus in patients with anterior myocardial infarction and low left ventricular ejection fraction: a prospective multicenter study. *Am Heart J* 2015 Aug;170(2):256–62. <https://doi.org/10.1016/j.ahj.2015.04.029>. PMID: 26299222.
- [10] Aljizeeri A, Sulaiman A, Alhulaimi N, Alsaileek A, Al-Mallah MH. Cardiac magnetic resonance imaging in heart failure: where the alphabet begins! *Heart Fail Rev* 2017 Jul; 22(4):385–99. <https://doi.org/10.1007/s10741-017-9609-4>. PMID: 28432605.
- [11] Franco A, Javidi S, Ruehm SG. Delayed myocardial enhancement in cardiac magnetic resonance imaging. *J Radiol Case Rep* 2015 Jun 30;9(6):6–18. <https://doi.org/10.3941/jrcr.v9i6.2328>. PMID: 26622933 PMCID: PMC4638378.
- [12] Sürder D, Gisler V, Corti R, Moccetti T, Klersy C, Zuber M, et al. Thrombus formation in the left ventricle after large myocardial infarction – assessment with cardiac magnetic resonance imaging. *Swiss Med Wkly* 2015 Jun 22;145:w14122. <https://doi.org/10.4414/sm.w.2015.14122>. eCollection 2015. PMID: 26098589.
- [13] Bajaj A, Sethi A, Rathor P, Suppogu N, Sethi A. Acute complications of myocardial infarction in the current era: diagnosis and management. *J Invest Med* 2015 Oct;63(7): 844–55. <https://doi.org/10.1097/JIM.0000000000000232>. PMID: 26295381.
- [14] Kim J, Weinsaft JW. Thrombosis and prognosis following ST-elevation myocardial infarction: left ventricular thrombus assessment by cardiac magnetic resonance. *Circ Cardiovasc Imaging* 2015 Oct;8(10):e004098. <https://doi.org/10.1161/CIRCIMAGING.115.004098>. PMID: 26481163.
- [15] Weinsaft JW, Kim J, Medicherla CB, Ma CL, Codella NC, Kukar N, et al. Echocardiographic algorithm for post-myocardial infarction LV thrombus: a gatekeeper for thrombus evaluation by delayed enhancement CMR. *JACC Cardiovasc Imaging* 2016 May;9(5):505–15. <https://doi.org/10.1016/j.jcmg.2015.06.017>. PMID: 26476503 PMCID: PMC5104336.
- [16] Pöss J, Desch S, Eitel C, de Waha S, Thiele H, Eitel I. Left ventricular thrombus formation after ST-segment-elevation myocardial infarction: insights from a cardiac magnetic resonance multicenter study. *Circ Cardiovasc Imaging* 2015 Oct;8(10):e003417. <https://doi.org/10.1161/CIRCIMAGING.115.003417>. PMID: 26481162.
- [17] Merkler AE, Alakbarli J, Gialdini G, Navi BB, Murthy SB, Goyal P, et al. Short-term risk of ischemic stroke after detection of left ventricular thrombus on cardiac magnetic resonance imaging. *J Stroke Cerebrovasc Dis* 2019 Jan 10; (18):30724–9. <https://doi.org/10.1016/j.jstrokecerebrovasdis.2018.12.025>. PMID: 30638940.
- [18] Takasugi J, Yamagami H, Noguchi T, Morita Y, Tanaka T, Okuno Y, et al. Detection of left ventricular thrombus by cardiac magnetic resonance in embolic stroke of undetermined source. *Stroke* 2017 Sep;48(9):2434–40. <https://doi.org/10.1161/STROKEAHA.117.018263>. PMID: 28818863.
- [19] Pop C, Matei C, Petris A. Anticoagulation in acute coronary syndrome: review of major therapeutic advances. *Am J Therapeut* 2019 Mar/Apr;26(2):e184–97. <https://doi.org/10.1097/MJT.0000000000000913>. PMID: 30839367.
- [20] Rizas KD, Doller AJ, Hamm W, Vdovin N, von Stuelpnagel L, Zuern CS, et al. Periodic repolarization dynamics as risk predictor after myocardial infarction: prospective validation study. *pii S1547-5271 Heart Rhythm* 2019 Feb 25;(19): 30146–8. <https://doi.org/10.1016/j.hrthm.2019.02.024>. PMID: 30818092.
- [21] Cambronero-Cortinas E, Bonanad C, Monmeneu JV, Lopez-Lereu MP, Gavara J, de Dios E, et al. Incidence, outcomes, and predictors of ventricular thrombus after reperfused ST-segment-elevation myocardial infarction by using sequential cardiac MR imaging. *Radiology* 2017 Aug;284(2):372–80. <https://doi.org/10.1148/radiol.2017161898>. PMID: 28253107.
- [22] Romero J, Lupercio F, Díaz JC, Goodman-Meza D, Haramati LB, Levsky JM, et al. Microvascular obstruction

detected by cardiac MRI after AMI for the prediction of LV remodeling and MACE: a meta-analysis of prospective trials. *Int J Cardiol* 2016 Jan;202:344–8. <https://doi.org/10.1016/j.ijcard.2015.08.197>. PMID:26426275.

[23] Abbas A, Matthews GH, Brown IW, Shambrook JS, Peebles CR, Harden SP. Cardiac MR assessment of microvascular

obstruction. *Br J Radiol* 2015 Mar;88(1047):20140470. <https://doi.org/10.1259/bjr.20140470>. PMID:25471092.

[24] Held EP, Henry TD. When small vessels become big problems! Microvascular dysfunction in NSTEMI. *Cathet Cardiovasc Interv* 2018 Nov;92(6):1075–6. <https://doi.org/10.1002/ccd.27966>. PMID:30478884.