


Results of Medium-Term Survival of the Non-Cemented Logical Femoral Stem*

Resultados de sobrevida no médio prazo da haste femoral não cimentada Logical

Cristiano Valter Diesel^{1,2,3}  Tiango Aguiar Ribeiro^{1,4,5} Carlos Alberto de Souza Macedo^{2,3}
Carlos Roberto Galia^{1,2,3}

¹ Postgraduate Program in Medicine, Ciências Cirúrgicas, Universidade Federal do Rio Grande do Sul (UFRGS), Porto Alegre, RS, Brasil

² Orthopedics and Traumatology Service, Hospital de Clínicas de Porto Alegre (HCPA), Porto Alegre, RS, Brasil

³ Department of Surgery, Faculdade de Medicina (FAMED), Universidade Federal do Rio Grande do Sul (UFRGS), Porto Alegre, RS, Brasil

⁴ Department of Surgery, Curso de Medicina, Universidade Federal de Santa Maria (UFSM), Santa Maria, RS, Brasil

⁵ Orthopedics and Traumatology Service, Hospital Universitário de Santa Maria (SOT-HUSM), Santa Maria, RS, Brasil

Address for correspondence Cristiano Valter Diesel, MD, MSc, Serviço de Ortopedia e Traumatologia do Hospital de Clínicas de Porto Alegre, Rua Ramiro Barcelos, 2350, Porto Alegre, Rio Grande do Sul, Brasil. CEP: 90035-903
(e-mail: cristianodiesel@gmail.com; cristianodiesel@ymail.com).

Rev Bras Ortop 2019;54:453–458.

Abstract

Objective The main objective of the present study was to evaluate the clinical and radiographic results of the Logical (Baumer, Mogi Mirim, SP, Brasil) cementless femoral stem in primary total hip arthroplasties (THAs).

Methods A retrospective cohort study of 632 patients submitted to primary THA with the Logical cementless femoral stem. The study period was between January 2004 and January 2015. The outcome defined to evaluate the survival of the stem was the clinical and radiographic indication of the revision hip arthroplasty or the actual revision of the femoral stem for any cause.

Results Kaplan-Meier survival curves were estimated at > 95%, with a follow-up ranging from 2 to 13 years. There was a low incidence of transoperative periprosthetic fractures (0.02%). No axial migration or cortical bone atrophy was observed in the radiographic sample evaluated.

Conclusions In the intermediate follow-up, there was excellent survival of the Logical cementless femoral stem. Although long-term studies are still awaited, this implant appears to be safe and promising to be used for primary THAs.


Keywords

- ▶ arthroplasty, replacement, hip
- ▶ bone cements
- ▶ hip joint
- ▶ follow-up studies

Resumo

Objetivo Avaliar os resultados clínicos e radiográficos da haste femoral não cimentada Logical (Baumer, Mogi Mirim, SP, Brasil) nas artroplastias totais do quadril (ATQs).

* Work performed at the Hospital de Clínicas de Porto Alegre (HCPA); Serviço de Ortopedia e Traumatologia; Ambulatório de Cirurgia do Quadril, Porto Alegre, Rio Grande do Sul, Brazil.

 Cristiano Valter Diesel's ORCID is <https://orcid.org/0000-0001-5295-9852>.

received
March 31, 2018
accepted
July 10, 2018

DOI <https://doi.org/10.1055/s-0039-1688755>.
ISSN 0102-3616.

Copyright © 2019 by Sociedade Brasileira de Ortopedia e Traumatologia. Published by Thieme Revnter Publicações Ltda, Rio de Janeiro, Brazil

License terms



Palavras-chave

- ▶ artroplastia de quadril
- ▶ cimentos para ossos
- ▶ articulação do quadril
- ▶ estudos de acompanhamento

Método Foi realizada uma coorte retrospectiva de 632 pacientes submetidos à artroplastia primária do quadril por coxartrose nos quais foram implantadas hastes femorais não cimentadas Logical. Todos os pacientes eram provenientes do ambulatório de Cirurgia do Quadril da instituição. O período do estudo compreendeu de janeiro de 2004 a janeiro de 2015. O desfecho definido para avaliar a sobrevida da haste foi a indicação clínica e radiográfica da revisão ou a revisão propriamente dita da haste femoral por qualquer causa.

Resultado Observaram-se curvas de sobrevida estimadas em > 95%, com um seguimento variando de 2 até 13 anos. Houve baixa incidência de fraturas periprotéticas transoperatórias (0,02%). Não foi observada migração axial ou atrofia óssea cortical na amostra radiográfica avaliada.

Conclusão Os resultados demonstram, no médio prazo, excelente sobrevida da haste femoral não cimentada Logical. Embora ainda sejam aguardados estudos no longo prazo, este implante parece ser seguro e promissor para ser utilizado nas artroplastias primárias do quadril.

Introduction

Cementless stems are widely used in total hip arthroplasty (THA). However, the term cementless is a generic description referring to a large group of implants without polymethylmethacrylate (PMMA) as an interface between the host bone and the prosthesis. Due to the lack of PMMA, the stem must be directly fixed to the bone, thus being more dependent on its shape, porosity, metal type, and design.

Since there is a great diversity in combining these characteristics, cementless implants have variable results. Several stem models showed excellent clinical and radiographic outcomes; others, however, did not perform well, and some had catastrophic results.¹⁻³

In the 1990s, although the world experienced a boom in cementless stems, with easy access to these implants, the socioeconomic peculiarities of some countries made the access to high-quality cementless materials scarce and difficult. We believe this was true for Brazil.

In this scenario, the development of a cementless stem with quadrangular and double-wedge design, considered the most appropriate by the authors, was initiated. In addition, this cementless stem had to be submitted to all of the tests required by the Food and Drugs Administration (FDA) and by the American Society for Testing and Materials (ASTM) and, above all, it had to demonstrate a high-quality standard at the most rigorous laboratory tests.

The result was a cementless, quadrangular, double-wedge base core with flaps on the anterior and posterior surfaces and forged in a titanium, aluminum and vanadium alloy. The adopted cervical-diaphysis angle was 135°, with a Morse cone of 12/14 mm. The entire implant was covered by thick textured sandblasting, and its proximal third had a porous circumferential layer of pure, spray-deposited titanium. These implants were produced in sizes 8, 9, 10, 11.25, 12.5, 13.75 and 15. More robust stems, sizes 16, 18 and 20, have similar characteristics, but the titanium layer virtually covers the whole device⁴ (► Fig. 1).

Although the first steps were successful and the basic metallurgical assumptions, rigorous biomechanical tests, finite element analysis, and laboratory control results validated the implant production and quality,⁴ they do not attest nor guarantee its success in the clinical environment, that is, when subjected to all kinds of in vivo situations (► Fig. 2).

To evaluate the performance of the Logical (Baumer, Mogi Mirim, SP, Brasil) cementless stem, we have analyzed all cases of primary hip arthroplasty using this implant in our institution between 2004 and 2015. The study included 632 patients.

Material and Methods

Data from all of the patients submitted to THA with a Logical stem between 2004 and 2015 and followed-up in the Hip Surgery outpatient facility were collected from the electronic and physical file system. Although the database contained > 1,000 patients, those in which the stem was used in proximal femoral fractures, arthroplasty revision, and fractures resulting from bone metastases or primary bone tumors were excluded, leaving a total of 632 patients.

All of the surgeries were performed or supervised by four orthopedic surgeons specialized in hip surgery. The posterolateral approach was used in all of the cases. The antibiotic prophylaxis adopted was intravenous cefazolin administration according to the institutional protocol, whereas postoperative thromboprophylaxis was performed with subcutaneous enoxaparin. The patients returned for visits at the 15th, 45th, and 90th postoperative days; after this initial period, visits occurred every 6 months in the first 18 months, and then annually. Control radiographs were obtained in the immediate postoperative period, at 45 days and at 180 days postoperatively. Afterwards, radiographic examinations were performed annually.

The evaluated outcome was the need for femoral component revision due to radiographic signs of loosening or to pain associated with the surgery. For outcome purposes, the

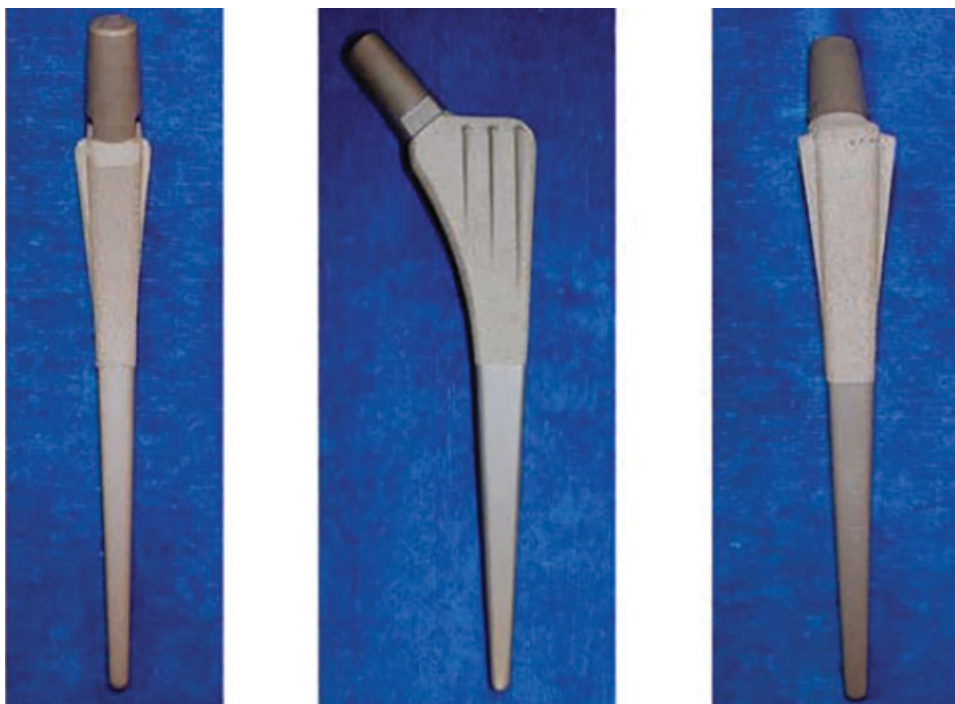


Fig. 1 Cementless femoral stem Logical – initial model.⁴




Fig. 2 Photographs of a Logical stem removed due to infection. The images show clear bone growth at the porous surface of the stem.

date of the surgical revision indication was considered the date of implant failure.

The following inclusion criteria were adopted: primary THA performed due to primary or secondary hip arthrosis with the Logical stem and compliance with the periodic follow-up in the orthopedic service. Patients who underwent partial or bipolar hip arthroplasty due to proximal femoral fracture, revisions of Logical arthroplasty, and those with pathological fractures of the proximal femur were excluded.

Epidemiological data were tabulated according to gender, age, and surgical indication. Data regarding the size of the used implants was also collected, in addition to infection, intraoperative femoral fracture and postoperative periprosthetic fracture rates.

Due to the large number of patients, a sample of 55 cases was randomly selected for radiographic analysis, which was performed by 2 different authors (Galia C. R. and Diesel C. V.), separately and at different times. The concordance between the evaluators was measured by the kappa index.

For the radiographic analysis, anterior-posterior hip radiographs were used and the axial migration of the stem, the presence of stress shielding, the appearance of radiolucent lines in the Gruen zones, and a pedestal formation at the stem tip were evaluated. Axial migration was considered present when the distance from the top of the greater trochanter and the shoulder of the stem was > 5 mm with an interval of 1 year from one radiograph to the other (**Fig. 3**).

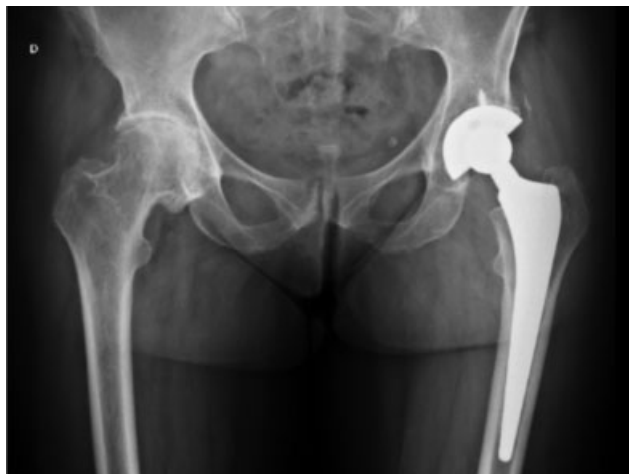

Fig. 3 Radiographical aspect of the Logical cementless stem – left hip arthroplasty performed in 2012.

Radiographic loosening was defined by axial migration > 5 mm, especially with progression over the years and associated with pedestal formation at the tip of the stem. The progressive formation of radiolucent lines > 2 mm in the Gruen areas was also used as a marker for implant loosening.

Survival curves were calculated by the Kaplan-Meier test and were expressed accordingly. The differences in survival between genders were evaluated by the Mantel-Cox test. Other numerical variables were presented in percentages.

Results

A total of 632 patients were included in the present study; all of them underwent a THA using the LOGICAL CM implant. Of these patients, 54.7% (346) were females and 45.3% (286) were males. The mean follow-up time was of 6.41 ± 3.1 years (mean \pm standard deviation [SD]), ranging from 2 to 13 years.

For a better understanding of the analysis, the subjects were divided into 2 groups from different moments in time: patients operated from January 2004 to December 2009 (totaling 244 patients), and those operated from January 2010 to December 2015 (totaling 388 patients).

Of the patients operated from January 2004 to December 2009, the mean follow-up time was of 9.73 ± 1.42 years (mean \pm SD), ranging from 8 to 13 years. Their survival curves are shown in **►Figs. 4–5 to 6**.

Of the patients operated from January 2010 to December 2015, the mean follow-up time was of 4.32 ± 1.74 years (mean \pm SD), ranging from 2 to 8 years. Their survival curves are shown in **►Figs. 7–8 to 9**.

The main sizes of the femoral components used are shown in **►Fig. 10**.

No surgical revision was performed due to residual thigh pain or to axial stem migration > 5 mm. In the studied period, 14 transoperative periprosthetic fractures (0.02%) were observed, and most of them were treated by cerclage with metallic wires.

There were no cases of bone atrophy (stress shielding) in the radiographic sample analyzed.

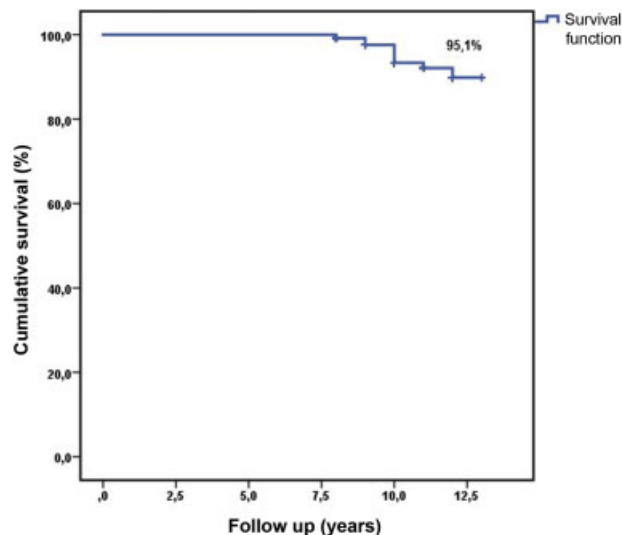


Fig. 4 LOGICAL CM implant survival in patients operated from January 2004 to December 2009. Over 95% of the implants had a mean survival of 12.72 ± 0.09 years (mean \pm standard deviation) with a confidence interval of 12.57–12.87 years.

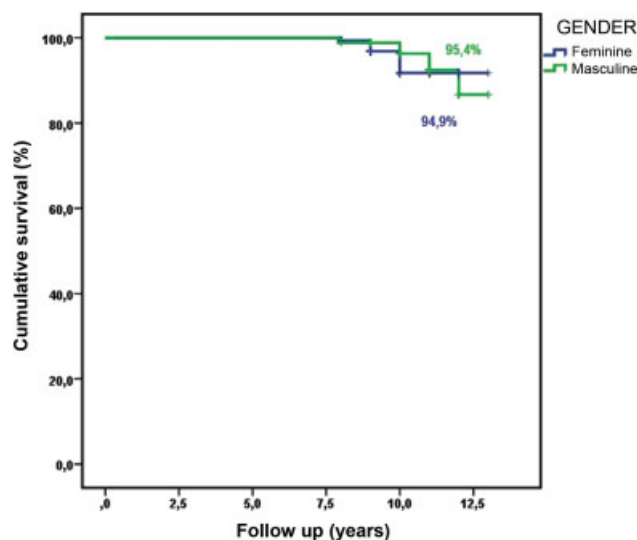


Fig. 5 LOGICAL CM implant survival in patients operated from January 2004 to December 2009 evaluating differences between genders. There was no difference in the mean implant survival comparing males and females. The Log Rank test (Mantel-Cox) was used ($p = 0.878$). The mean survival was 12.74 ± 0.10 years for females and 12.73 ± 0.13 years for males.

Discussion

Belief guides many steps in the evolution of knowledge. The fusion of belief and physical, mechanical, and biological principles in orthopedics can result in solutions, as successful or unsuccessful products. Institutionally, there was the belief that the most suitable design for a cementless femoral stem would be quadrangular and cuneiform. This belief was supported by the mechanical and biological pillars already studied by several authors and with proven success over the years, such as the CLS (Zimmer, Warsaw, Indiana, USA) femoral stems.^{5–7} This led to the development of a cementless, quadrangular, cuneiform stem with pores and proximal flaps.

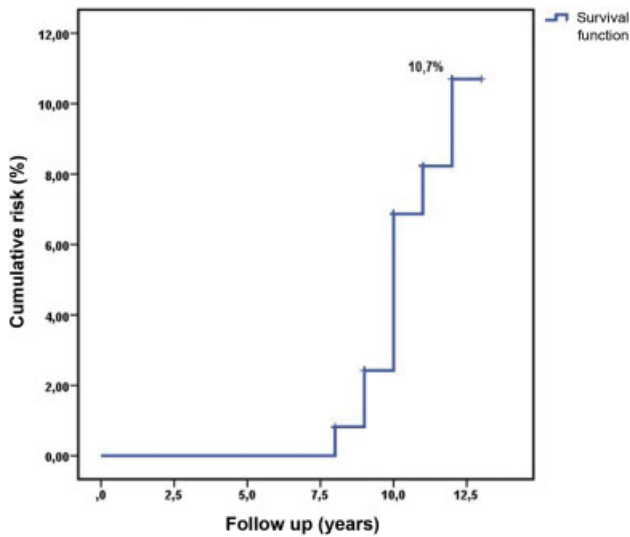


Fig. 6 The cumulative risk of failure of the LOGICAL CM implant in patients operated from January 2004 to December 2009 over 12.5 years was 10.7%.

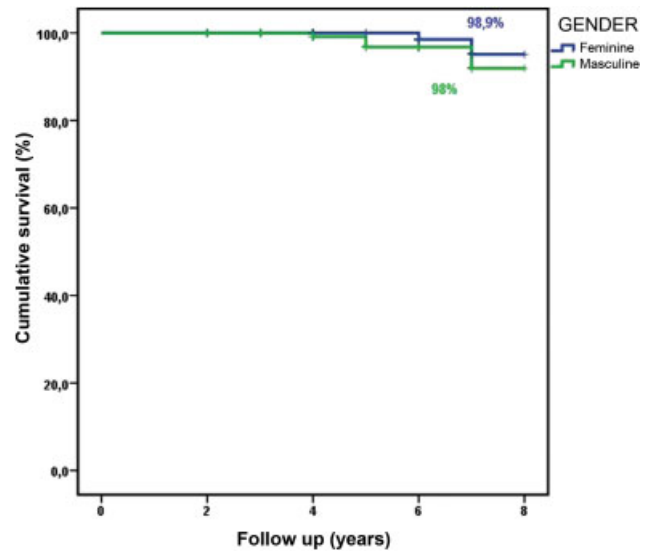


Fig. 8 LOGICAL CM implant survival of patients operated from January 2010 to December 2015 evaluating differences between genders. There was no difference in the mean implant survival comparing males and females. The Log Rank test (Mantel-Cox) ($p = 0.287$) was used. The mean survival was 7.94 ± 0.04 years for females and 7.85 ± 0.06 years for males.

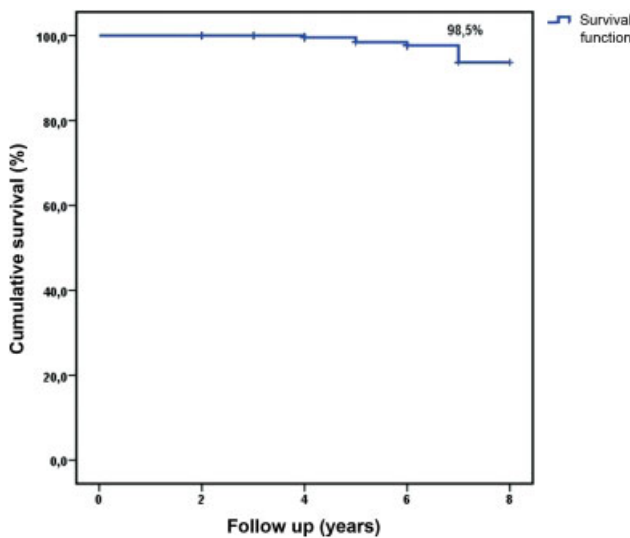


Fig. 7 LOGICAL CM implant survival in patients operated from January 2010 to December 2015. Over 98% of the implants had a mean survival of 7.89 ± 0.04 years (mean \pm standard deviation), with a confidence interval of 7.81–7.98 years.

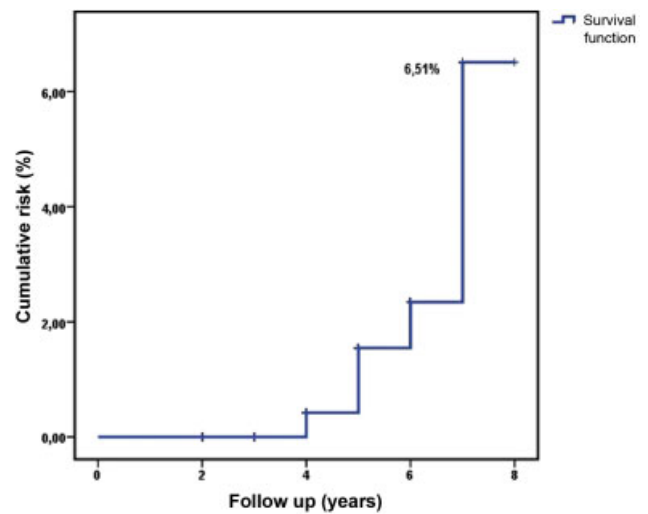


Fig. 9 The cumulative risk of failure of the LOGICAL CM implant in patients operated from January 2010 to December 2015 over 8 years was 6.51%.

The Logical stem was used in the most diverse situations and indications, such as THA, partial arthroplasty for the treatment of proximal femoral fractures, metastatic lesions of the proximal femoral third, and revisions of the femoral component. Since 2004, more than 1,000 femoral stems have been implanted in our institution.

The early years were dedicated to instrumental adjustments and improvements, in addition to the observation of the postoperative evolution of the patients. These were also the years for the learning curve of the implant.

The evolution of the first cases was encouraging, allowing a greater liberty in indicating this cementless stem. Age group, Dorr concepts, and morphocortical indexes gradually ceased to be criteria to indicate this device.

We did not observe axial migration of the femoral stem in the evaluated radiographic sample. Although not all of the radiographs were analyzed, the design of the implant and its adaptation to the femoral canal, in addition to the low number of revision indications, lead us to believe that this event is rare

A total of 14 transoperative periprosthetic fractures (0.02%) were observed. Although the values found in the literature are variable (ranging from 0.1% to 27.8%),⁸ we attribute this low number of cases to the institutional experience with this cementless stem – the only one used at our facility since 2004.

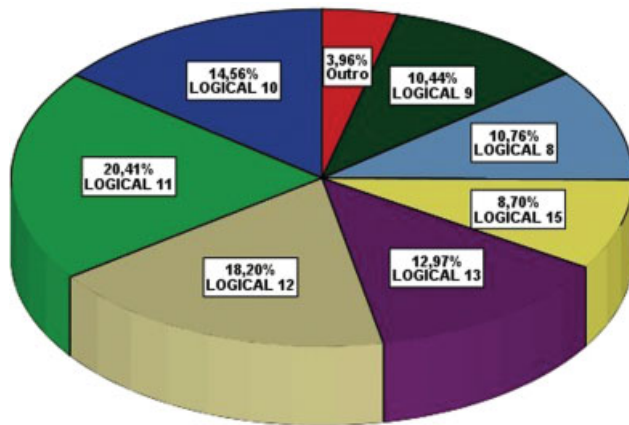


Fig. 10 Femoral components sizes.

As expected, we also did not find evidence of cortical bone atrophy (stress shielding) in the radiographic sample analyzed. We attribute this fact to the features of the cementless implant (double-wedged, with proximal porosity and biocompatible). These features, among others, increase the load distribution at the bone-implant interface and reduce the incidence of bone atrophy.

Although a medium-term follow-up is still insufficient in terms of orthopedic implants, the results obtained and expressed in the survival curves are very encouraging.

Currently, ceramic heads are adapted to the Logical stem and their acetabular assembly presents crosslinked polyethylene. Over time, we expect a greater number of revision indications in the analyzed cases, since the tribological pair used in most of them is composed of ultra-high molecular weight polyethylene and metal. Aspects related to particles generation and their repercussion in THA survival are well-

known. Therefore, we believe that the following years will be very challenging.

Conflicts of Interests

One of the authors, Macedo C. A. S., declares a conflict of interest, since he is responsible for the development of the Logical femoral stem and assigned the technology to the company Baumer, from Mogi Mirim, state of São Paulo, Brazil.

References

- 1 Aldinger PR, Jung AW, Breusch SJ, Ewerbeck V, Parsch D. Survival of the cementless Spotorno stem in the second decade. *Clin Orthop Relat Res* 2009;467(09):2297–2304
- 2 Johanson PE, Antonsson M, Shareghi B, Kärrholm J. Early Subsidence Predicts Failure of a cemented femoral stem with minor design changes. *Clin Orthop Relat Res* 2016;474(10):2221–2229
- 3 Kitamura S, Hasegawa Y, Iwasada S, Yamauchi K, Kawamoto K, Kanamono T, et al. Catastrophic failure of cementless total hip arthroplasty using a femoral component without surface coating. *J Arthroplasty* 1999;14(08):918–924
- 4 Macedo CAS. Desenvolvimento de haste femoral não cimentada nacional, validada por normas internacionais [tese]. Porto Alegre: Universidade Federal do Rio Grande do Sul; 2007
- 5 Rozkydal Z, Janíček P, Havlíček V, Pazourek L. [Long-term results of use of the CLS stem in primary total hip arthroplasty]. *Acta Chir Orthop Traumatol Cech* 2009;76(04):281–287
- 6 Evola FR, Evola G, Graceffa A, Sessa A, Pavone V, Costarella L, et al. Performance of the CLS Spotorno uncemented stem in the third decade after implantation. *Bone Joint J* 2014;96-B(04):455–461
- 7 Yamasaki T, Yasunaga Y, Mori R, Hamanishi M, Shoji T, Ochi M. The Cementless Spotorno stem in THA: 10 year results. *Hip Int* 2014; 24(01):98–102
- 8 Sidler-Maier CC, Waddell JP. Incidence and predisposing factors of periprosthetic proximal femoral fractures: a literature review. *Int Orthop* 2015;39(09):1673–1682