

Endoscopic ultrasound-guided colo-colostomy in a case of acute large bowel obstruction




Authors

James Emmanuel, Sattian Kollanavelu, Fitgerald Henry, Lee Tiong See

Institution

Department of Gastroenterology and Hepatology, Selayang Hospital, Selangor, Malaysia

submitted 29.4.2020

accepted after revision 2.11.2020

Bibliography

Endoscopy International Open 2021; 09: E289–E291

DOI 10.1055/a-1336-2213

ISSN 2364-3722

© 2021. The Author(s).

This is an open access article published by Thieme under the terms of the Creative Commons Attribution-NonDerivative-NonCommercial License, permitting copying and reproduction so long as the original work is given appropriate credit. Contents may not be used for commercial purposes, or adapted, remixed, transformed or built upon. (<https://creativecommons.org/licenses/by-nc-nd/4.0/>)

Georg Thieme Verlag KG, Rüdigerstraße 14,
70469 Stuttgart, Germany

Corresponding author

James Emmanuel, Gastroenterology Fellow, Department of Gastroenterology and Hepatology, Selayang Hospital, B21, Lebuhraya Selayang-Kepong, 68100, Batu Caves, Selangor, Malaysia

Fax: +603-61377097

sentulian83@gmail.com

ABSTRACT

Bowel obstruction is one of the most common surgical emergencies and a major cause of morbidity and mortality. Standard supportive measures must be instituted as soon as the diagnosis is confirmed. Anastomotic strictures are a benign etiology of intestinal obstruction, occurring in up to 22% of patients following colorectal resection. Traditionally, endoscopic balloon dilation (EBD) has been the intervention of choice in such cases; however, it may not be feasible in all settings. We report a novel application of the AXIOS stent and electrocautery-enhanced delivery system (Boston Scientific, Marlborough, Massachusetts, United States) to create a colo-colostomy to bypass a sigmoid colon stricture in a 51-year-old woman who presented with acute intestinal obstruction. Despite stent dislodgment during the procedure, the preexisting tract allowed us to improvise our technique with a second LAMS placement. The patient was discharged well 48 hours after the procedure. However, 4 months later, she required a session of EBD following a presentation for fecal impaction. She is currently asymptomatic and being followed up regularly as an outpatient.

Introduction

Bowel obstruction is one of the most common surgical emergencies and a major cause of morbidity and mortality [1,2]. Standard supportive measures must be instituted as soon as the diagnosis is confirmed [2]. It is commonly a result of a malignant etiology; however, benign conditions such as strictures, volvulus, and radiation injuries may contribute to this condition [3]. Anastomotic strictures occur in up to 22% of patients following colorectal resection and up to 70% of them will eventually require surgical intervention [4,5]. Traditionally the approach taken in such cases has included endoscopic balloon dilation (EBD), self-expandable metal stent insertion or surgical intervention, with EBD being the primary modality because of its efficacy and safety profile [4–6]. However, these approaches may not be feasible in all settings; therefore, in some cases, a

different alternative may need to be considered. We report a novel application of the AXIOS stent and electrocautery-enhanced delivery system (Boston Scientific, Marlborough, Massachusetts, United States) to create a colo-colostomy to bypass a sigmoid colon stricture in a patient presenting with acute intestinal obstruction. Despite stent dislodgment during the procedure, the preexisting tract allowed us to improvise our technique with a second lumen apposing metal stent (LAMS) placement.

Case report

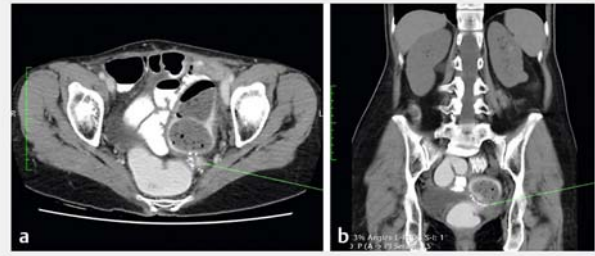
Our patient was a 51-year-old woman with an extensive surgical history, which included seven surgeries for recurrent intestinal obstruction and was further complicated by multiple iatrogenic perforations of the small and large bowel necessitating repeat-

ed colonic resection. She presented in August 2019 with abdominal pain, vomiting, and obstipation for 3 days. She was admitted to the surgical ward for further management of acute intestinal obstruction. A computed tomography (CT) scan of the abdomen done emergently revealed a discrete transition point at the sigmoid colon with no evidence of bowel ischemia (► **Fig. 1**). The patient's symptoms failed to resolve after standard conservative measures.

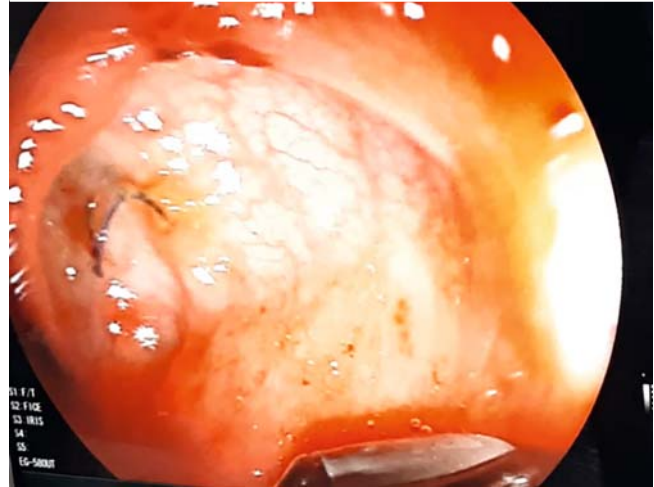
A colonoscopy was done, which revealed a tight sigmoid colon stricture 15 cm from the anal verge (► **Fig. 2**). An attempt to feed a guidewire across the stricture with the aim of inserting a colonic stent was unsuccessful. A multidisciplinary discussion was conducted and the morbidity of surgical intervention was deemed to be prohibitively high. In addition, the patient had expressed a reluctance to undergo any further surgery. The Gastroenterology team was consulted about an endoscopic approach to this case. After careful review of the CT image, trans-colonic endoscopic ultrasound (EUS) was performed as part of the road map for potential placement of a LAMS (► **Fig. 3**). The linear echoendoscope was advanced to the level of the sigmoid stricture and the surrounding structures interrogated. A proximal portion of the colon was identified in close proximity to the sigmoid colon, based on EUS imaging. An initial attempt to access the dilated proximal bowel loop with a 19 G needle failed due to inability to puncture the fibrotic colonic mucosa. The unusual position of the stricture made it difficult to access with a straight catheter. Therefore, using a sphincterotome through the EUS working channel, contrast was injected in the direction of the lumen of the stricture to delineate and further distend the proximal colon. The gradual upstream contrast flow facilitated our endosonographic localization of a suitable trans-colonic puncture site. Once an optimum position was identified, color Doppler was used to evaluate the apposing walls to exclude interposing vessels. Under EUS and fluoroscopic guidance, a 15 mm × 10 mm Hot AXIOS stent was deployed directly into the proximal loop of the large bowel utilizing pure cut current at 100W. However, the LAMS that was inserted 3 cm from the stricture dislodged immediately after deployment, falling into the sigmoid colon, where it was removed. A second 16 mm × 20 mm Spaxus stent (Taewoong Medical, Gyeonggi-do, South Korea) was immediately introduced over the guidewire in the preexisting tract (► **Fig. 4**).

There were no immediate post-procedural adverse events (AEs) noted. The patient's symptoms improved following the procedure and she was able to resume oral intake. She was discharged well 48 hours after the procedure. During the follow-up colonoscopy 6 weeks later, the LAMS was removed as the patient had complained of persistent lower abdominal pain for a week, which we deduced was stent related. Following stent removal, her symptoms subsided.

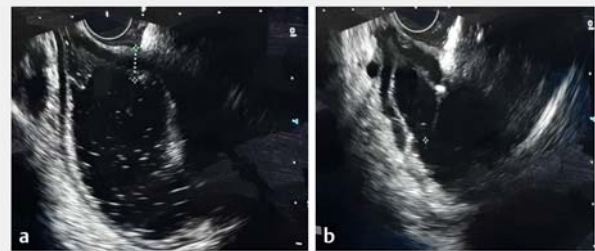
Four months after the index colonoscopy, the patient presented again with milder abdominal pain and constipation of 2 days duration. Colonoscopy was performed and fecal impaction was determined to be the underlying cause of her symptoms. We proceeded with saline flushing and mechanical recanalization. Subsequently we performed dilatation of the fistulous tract up to 15 mm, with no procedure-related AEs encountered.



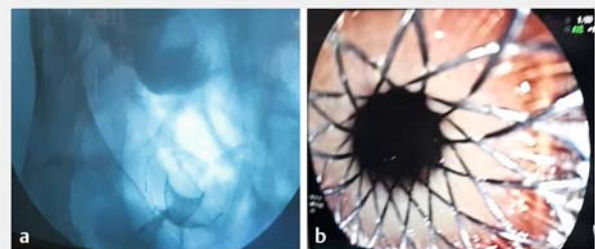
► **Fig. 1** Emergent CT of the abdomen.



► **Fig. 2** Colonoscopy revealed a tight colon stricture.



► **Fig. 3** Trans-colonic endoscopic ultrasound.



► **Fig. 4** Introduction of the stent over the guidewire in the preexisting tract.

The patient experienced immediate relief of symptoms and was able to resume eating. She has remained well at subsequent follow-up visits.

Discussion

Anastomotic strictures of the colon are a common complication after colorectal surgery [7]. Although EBD is recognized as the intervention of choice for such strictures, failure to pass a guidewire through the stricture in our patient made the procedure inapplicable. In addition, her extensive history of abdominal surgery would have resulted in very distorted anatomy with lack of discernible tissue planes to yield a favorable outcome with surgical intervention.

This case illustrates a novel technique for creating a colo-colostomy bypass in the setting of acute intestinal obstruction due to a post anastomotic sigmoid colon stricture (► **Video 1**). As described, the objective of the procedure was to create a functional anastomosis to bypass the obstructed area, which is similar in concept to the previously described EUS-guided gastrojejunostomy and enterocolostomy [8,9]. This approach prevents perioperative morbidity and helps achieve early discharge of the patient.

In the previously reported enterocolostomy procedure by Adil Mir et al, initial access to the adjacent loop was achieved with a 19G needle followed by contrast delineation of the small bowel anatomy prior to LAMS deployment. In our case, failure to puncture the colonic wall with a 19G needle due to the fibrotic colonic mucosa compelled us to resort to the one-step procedure using the AXIOS cautery tipped LAMS. The 20-mm AXIOS stent would have been preferable for approximation of both the bowel loops because of its wider diameter; however, in view, it was not applicable so we opted for the 15-mm AXIOS stent instead. Dislodgement of the stent shortly after deployment presented yet another obstacle in a procedure fraught with technical challenges. Nevertheless, we were able to proceed with a timely salvage procedure with placement of a second LAMS. Despite AXIOS stent dislodgement in our patient, it is noteworthy that the aforementioned device confers the advantage of avoiding multiple long wire exchanges, thus miti-

gating potential leak of bowel contents between the interposed spaces of the colon, which could result in peritonitis. Prospective studies are needed to further investigate the utility of this procedure as a temporizing measure for patients who may not be ideal surgical candidates on presentation.

Conclusion

To the best of our knowledge, this case is the first reported application of a LAMS to create an EUS-guided colo-colostomy bypass. Despite dislodgment of the initial stent, the tract was salvaged with placement of a second LAMS. We conclude that EUS-guided colo-colostomy may be an option in patients with acute intestinal obstruction. Further prospective studies are required to evaluate the safety and efficacy of this novel technique.

Acknowledgements

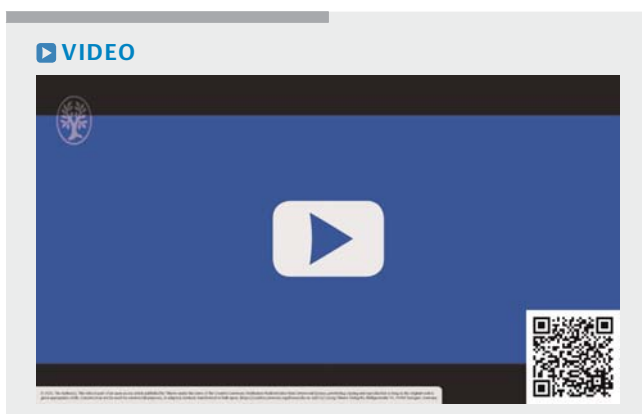
The authors thank Dr. Haniza Omar, the head of the Department of Gastroenterology and Hepatology, for her invaluable support.

Competing interests

The authors declare that they have no conflict of interest.

References

- [1] Pujahari AK. Decision making in bowel obstruction: a review. *Journal of clinical and diagnostic research: JCDR* 2016; 10: PE07
- [2] Catena F, De Simone B, Coccolini F et al. Bowel obstruction: a narrative review for all physicians. *World J Emergency Surg* 2019; 14: 1–8
- [3] Jeong SJ, Park J. Endoscopic management of benign colonic obstruction and pseudo-obstruction. *Clin Endosc* 2020; 53: 18–28
- [4] Ridditid W, Siripun A, Rerknimitr R. Stricture at colorectal anastomosis: to dilate or to incise. *Endosc Int Open* 2018; 6: E340–E341
- [5] Winder O, Fliss-Isakov N, Winder G et al. Clinical outcomes of endoscopic balloon dilatation of intestinal strictures in patients with Crohn's disease. *Medicine* 2019; 98: E16864
- [6] Sawai RS. Management of colonic obstruction: a review. *Clin Colon Rectal Surg* 2012; 25: 200–203
- [7] Chen T-A, Hsu W-L. Successful treatment of colorectal anastomotic stricture by using sphincterotomes. *Front Surg* 2014; 1: 20–22
- [8] Tyberg A, Perez-Miranda M, Sanchez-Ocaña R et al. Endoscopic ultrasound-guided gastrojejunostomy with a lumen-apposing metal stent: a multicenter, international experience. *Endosc Int Open* 2016; 4: E276–E281
- [9] Mir A, Parekh PJ, Shakhathreh M et al. Endoscopic ultrasound-guided creation of an enterocolostomy to relieve malignant bowel obstruction. *Endosc Int Open* 2019; 7: E1034–E1037



► **Video 1** Endoscopic ultrasound-guided colo-colostomy procedure.