

# The utility of the angled blade plate in hip fracture nonunion treatment

## A report of three cases and review of the literature

Joshua M. Lawrenz, MD\*, Danielle C. Marshall, BA, Brendan M. Patterson, MD, MBA

### Abstract

**Objectives:** We report the radiographic and clinical outcome of patients treated with an angled blade plate (ABP) for hip fracture nonunion. We also provide a review of the literature on joint preserving treatment approaches to hip fracture nonunions.

**Design:** Retrospective, case series.

**Setting:** Tertiary academic hospital.

**Patients/Participants:** Three.

**Intervention:** We treated three patients with varied hip fracture nonunions using a joint preserving approach with an ABP.

**Main outcome measurements:** Radiographic union and clinical outcome.

**Results:** All three patients achieved radiographic union, and were ambulating without pain at final follow-up.

**Conclusions:** The treatment approach to hip fracture nonunions is either restorative (joint preserving) or reconstructive (joint replacing). The primary restorative approach to nonunions around the hip consists of revision open reduction and internal fixation with or without bone grafting. Though a variety of implants and treatment techniques have demonstrated excellent success in this setting, revision open reduction and internal fixation with an ABP remains an efficacious implant selection in hip nonunion surgery.

**Keywords:** angled blade plate, hip fracture, nonunion

## 1. Introduction

Nonunions of hip fractures often result in significant pain and functional disability.<sup>[1,2]</sup> Treatment options after failed initial fixation are largely guided by anatomic location and etiology, while also factoring in patient age, activity level, bone quality, comorbidities, and initial fixation method. Integrity of the articular surface remains key to delineating whether joint preservation is possible or if reconstruction by arthroplasty is warranted.<sup>[1]</sup>

The primary salvage approach to nonunions around the hip consists of revision open reduction and internal fixation (ORIF)

with or without bone grafting.<sup>[3–6]</sup> Coupled with appropriate patient selection and sound surgical technique, a variety of implants have been reported to facilitate healing in the treatment of femoral neck, intertrochanteric and subtrochanteric nonunions. Depending on the fracture type, other advanced techniques may be indicated, such as the valgus producing intertrochanteric osteotomy in a femoral neck nonunion in a young patient.<sup>[7–11]</sup> In this report, we highlight the utility of the ABP, and review the recent literature on joint preserving hip fracture nonunion treatment.

## 2. Case Report

We review three cases of hip fracture nonunions (1 femoral neck and 2 peritrochanteric) following internal fixation. In all cases, a joint preserving approach with an ABP was utilized. Institutional review board exemption was attained to report the following cases without consent. All patient anonymity has been preserved.

### 2.1. Patient 1

A 13-year-old male sustained a displaced right femoral neck fracture after falling while playing basketball. He underwent surgical reduction and fixation with 3 partially threaded screws (Fig. 1A). His postoperative course was uncomplicated until 6-month follow-up, when the patient reported new-onset pain after jumping down the stairs at school. Imaging revealed fixation failure with interval fracture of the inferior 2 screws, complete cutout of the proximal screw, and a varus nonunion (Fig. 1B). Revision surgery was performed with valgus intertrochanteric osteotomy (VITO) and revision ORIF with a 130° ABP. The osteotomy wedge was utilized as autograft. At 6-month follow-up, he was full weight bearing without pain, and radiographs demonstrated healed nonunion and osteotomy sites with a viable femoral head (Fig. 1C).

*This work has not been featured in a prior abstract, presentation, or manuscript.*

*The authors have no conflicts of interest to disclose.*

*Source of funding: Nil*

*Department of Orthopaedic Surgery, Orthopaedic and Rheumatologic Institute, Cleveland Clinic, Cleveland, OH*

*\* Corresponding author. Address: Chief Resident, Department of Orthopaedic Surgery, Orthopaedic and Rheumatologic Institute, Cleveland Clinic, Crile Building, Mail Code A41, 9500 Euclid Avenue, Cleveland, OH 44195. Tel: +630 291 4417. E-mail address: lawrenz4@ccf.org/josh.lawrenz@gmail.com (J. M. Lawrenz).*

*Copyright © 2019 The Authors. Published by Wolters Kluwer Health, Inc. on behalf of the Orthopaedic Trauma Association.*

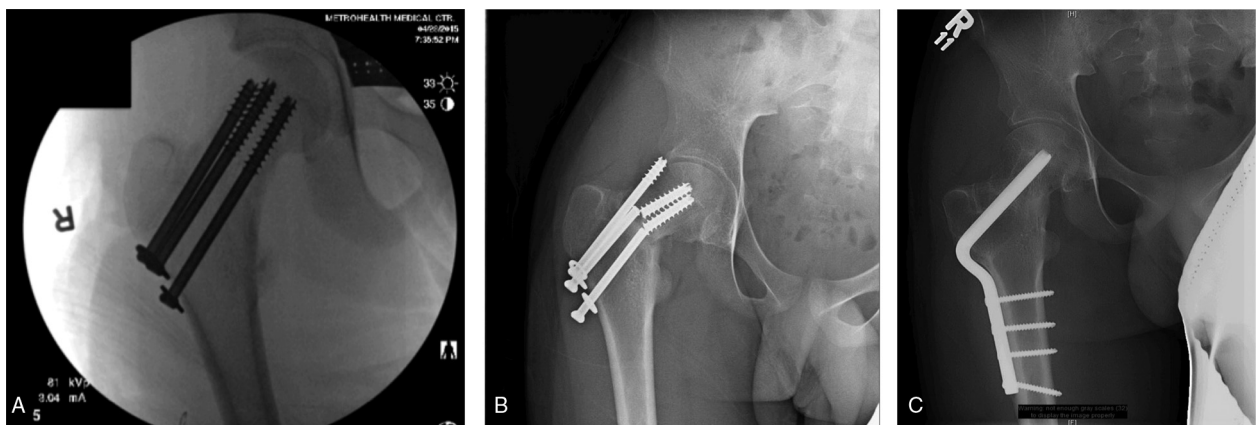
*This is an open-access article distributed under the terms of the Creative Commons Attribution-Non Commercial-No Derivatives License 4.0 (CCBY-NC-ND), where it is permissible to download and share the work provided it is properly cited. The work cannot be changed in any way or used commercially without permission from the journal.*

*OTA (2019) e041*

*Received: 15 December 2018 / Accepted: 4 June 2019*

*Published online 13 August 2019*

*<http://dx.doi.org/10.1097/O19.000000000000041>*



**Figure 1.** (A) Intraoperative AP fluoroscopic image of the right hip demonstrates a well-reduced femoral neck fracture with interval placement of 3 partially threaded screws across the fracture. (B) AP radiograph of the right hip demonstrates implant failure of the distal and middle screw, complete cutout of proximal screw from the femoral head, and a varus femoral neck nonunion six-months status post initial fixation. (C) AP radiograph of the right hip demonstrates healed intertrochanteric osteotomy and previous femoral neck nonunion site 6 months postrevision ORIF with an ABP and bone grafting.

## 2.2. Patient 2

A 60-year-old male sustained a displaced intertrochanteric hip fracture during a motorcycle accident that was fixed acutely with a 95° ABP. His postoperative course was unremarkable until 5-month follow-up, when he presented with sudden-onset left hip pain, a notable abductor lurch and leg length inequality. Radiographs demonstrated a varus deformity, nonunion, and a broken ABP (Fig. 2A). He underwent revision ORIF with a new 95° ABP, this time utilizing an external compression device and associated distal bicortical screw to load the implant and compress the nonunion. A wedge osteotomy was performed to restore the neck-shaft angle, though it remained under corrected (Fig. 2B). Postoperatively, the patient continued to have pain until 9-month follow-up, where a computed tomography scan demonstrated a hypertrophic nonunion of the proximal femur (Fig. 2C). He underwent a third ORIF procedure with a 130° ABP and a 20° osteotomy wedge to achieve further deformity correction. The inferior of the 3 fully threaded screws was placed across the osteotomy site, effectively increasing the working length of the relatively short blade, while the 2 proximal screws serve simply as a structural roof to the blade itself. At 6-month follow-up, the patient was ambulating without pain, with radiographs demonstrating a restored neck-shaft angle and progressive bone consolidation at the prior nonunion site demonstrating union (Fig. 2D).

## 2.3. Patient 3

A 68-year-old female, who was 3 months post left femur cephalomedullary nail fixation, presented with sudden left hip pain after leaning over her bed. Radiographs revealed varus collapse and implant failure, signifying a peritrochanteric nonunion (Fig. 3A). Revision ORIF with a 95° ABP and valgus realignment using two 4.5 partially threaded screws was performed (Fig. 3B). Postoperatively, she had intermittent pain with ambulation. At her 6-month follow-up, the patient presented with elevated inflammatory markers (C-reactive protein, CRP=5.8, and erythrocyte sedimentation rate, ESR=51) and radiographs demonstrated a left varus hip deformity with proximal pullout of the blade through the femoral neck (Fig. 3C). Intraoperative findings during revision surgery did not include

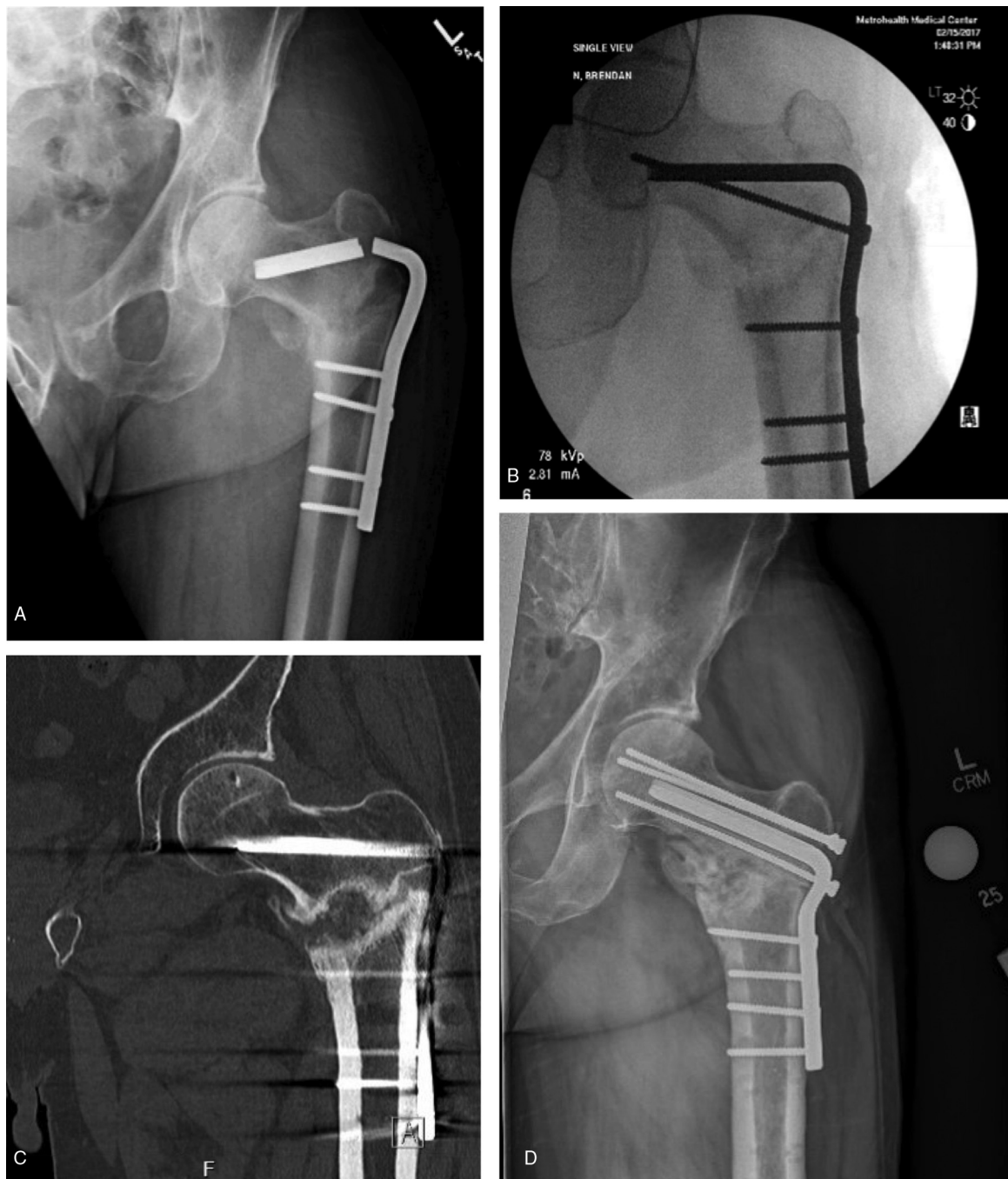
gross purulence, but soft tissue around the implant had a soupy puree consistency that was suspicious for infection. Multiple cultures were sent. A diagnosis of septic nonunion was suspected, and she underwent debridement, placement of antibiotic beads, and exchange to a small proximal femoral locking plate for provisional stability.

After 6 weeks of intravenous antibiotics (until normalization of her CRP (0.9) and ESR (19), and a healed soft tissue envelope), she underwent subtrochanteric osteotomy, revision ORIF with a 130° ABP and a fibular strut allograft secured with a 50 mm bicortical screw (Fig. 3D). At 6-year follow-up, the patient was ambulating without pain. Radiographs demonstrated restored femoral neck-shaft angle and union (Fig. 3E).

## 3. Discussion

We present three cases demonstrating the successful treatment of hip fracture nonunions with an ABP. Conventional ABPs have been utilized in the surgical management of fractures of the femur for over half a century.<sup>[12]</sup> Though technically less forgiving than modern locking plate and screw constructs due to the increased multiplane accuracy required in their placement, ABPs provide a material advantage by compromising less metaphyseal bone volume.<sup>[13]</sup> Moreover, at our institution, they are over 3 times less expensive than modern locking plates or intramedullary devices.<sup>[14]</sup> Accommodating diverse clinical scenarios, we believe the ABP remains an effective implant selection in hip nonunion surgery.

Patient 1 illustrates the use of an ABP in the treatment of a femoral neck nonunion in an adolescent. Risk of femoral neck nonunion has been associated with an increased Pauwels' angle, severity of comminution, and lack of anatomic reduction.<sup>[15-17]</sup> Though there is no specific age cutoff in our practice, in older patients (>60 years old), those with compromised bone stock, or those with femoral head collapse secondary to avascular necrosis (AVN), total hip arthroplasty becomes a strong consideration.<sup>[15,18]</sup> However, in the young patient (<60 years old), revision ORIF with a VITO has been widely shown to be the primary treatment approach.<sup>[10,19]</sup> In this patient, there was little consideration for replacement given the patient's age (13 years old) and lack of AVN on radiographs. Assessment with an MRI is

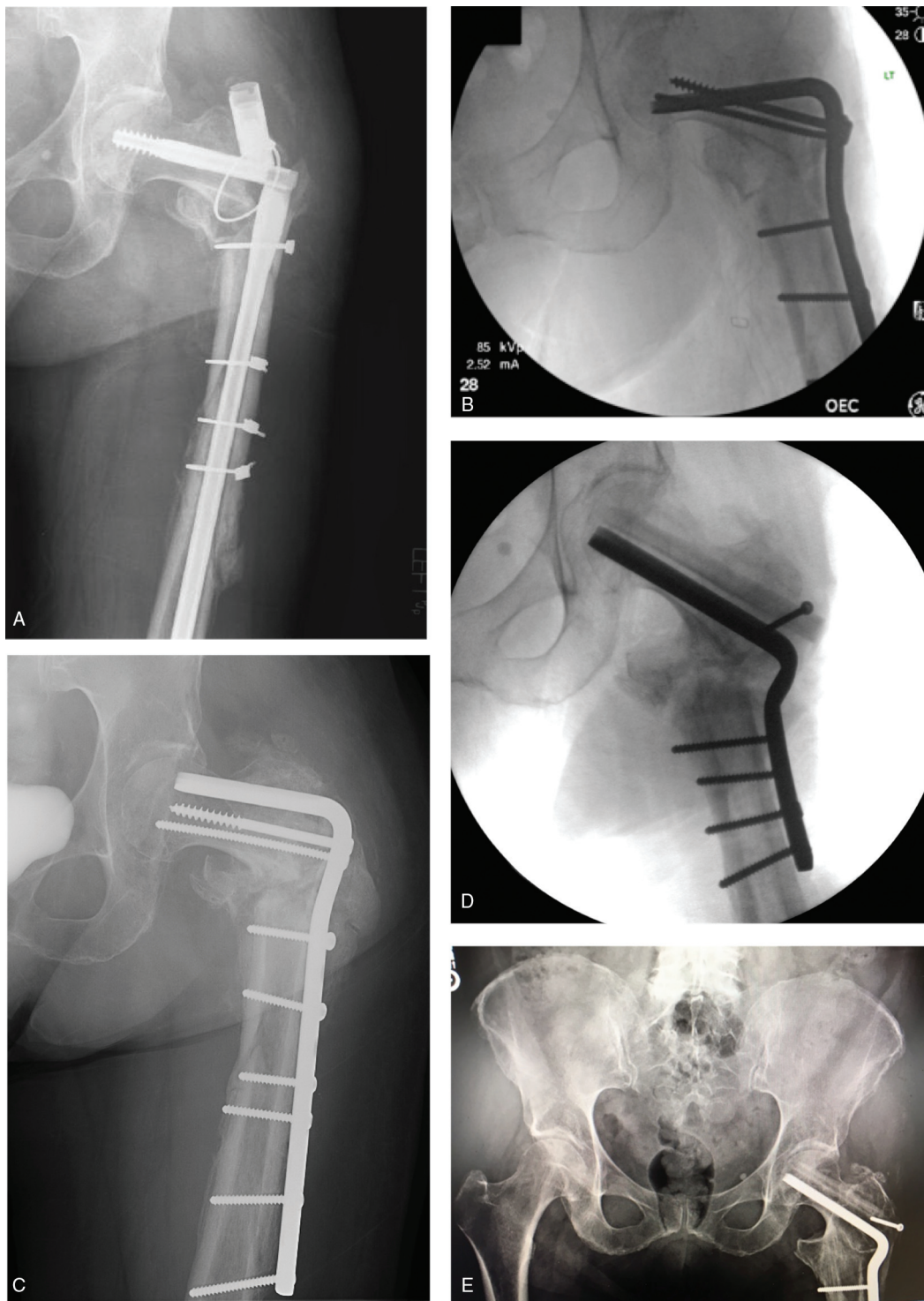


**Figure 2.** (A) AP radiograph of the left hip demonstrates varus failure of the ABP with associated intertrochanteric nonunion. (B) Intraoperative AP fluoroscopic image of the left hip demonstrates a slightly improved neck-shaft angle using another 95° ABP, though it remained under corrected. (C) A coronal CT image of the left hip demonstrates a hypertrophic nonunion at 9 month follow-up. (D) AP radiograph of the left hip demonstrates an improved neck-shaft angle with progressive bone consolidation at the prior intertrochanteric nonunion site.

not routinely performed in our practice, as the previous stainless steel hardware would make interpretation of early AVN difficult. Moreover, even if early signs of AVN were found with advanced imaging, with the lack of femoral head collapse noted on radiographs, it would not have changed surgical treatment plans toward replacement in our hands; thus, salvage was decided without advanced imaging.

In VITO, the goal of the osteotomy is to convert the typical vertically oriented femoral neck fracture into a more horizontal

type, changing the forces at the nonunion site from shear to compression.<sup>[8,20]</sup> Furthermore, this osteotomy has been shown to reliably restore the native neck-shaft angle and has the potential to correct for leg shortening.<sup>[20–23]</sup> As noted in Table 1, the VITO has been reported with excellent success using either an ABP or dynamic hip screw. Union rates greater than 90%, time to union of around 5 months, and good to excellent functional outcomes can be expected at >2 year follow-up with this technique.<sup>[10,19]</sup>



**Figure 3.** (A) AP radiograph of the left hip demonstrates varus collapse and catastrophic implant failure signifying a peritrochanteric nonunion. (B) Intraoperative AP fluoroscopic image of the left hip demonstrates revision ORIF with an ABP and improved neck-shaft angle. (C) AP radiograph of the left hip at 6-month follow-up demonstrates a varus deformity with associated proximal pullout of the blade through the femoral neck and a persistent peritrochanteric nonunion. (D) Intraoperative AP fluoroscopic image of the left hip demonstrates revision ORIF with a 130° ABP with a fibular strut allograft secured to the native bone with a 50 mm bicortical screw. (E) AP pelvis radiograph at 6-year follow-up demonstrates restored and near symmetric femoral neck-shaft angle, and a well-maintained joint space.

It should be noted that an osteotomy is not without risk, including nonunion of the osteotomy site and postoperative limp that can occur secondary to changing the native femoral offset.<sup>[23,24]</sup> For these reasons, and also in cases of femoral neck

nonunion with minimal varus deformity and/or negligible leg length discrepancy, fibular bone grafting techniques without osteotomy have proven successful. In 2002, LeCroy et al<sup>[25]</sup> demonstrated free vascularized fibular grafting to achieve a 91%

**Table 1**  
**Selected literature review – hip fracture nonunion treatment**

Authors	Year	No. of patients	Mean age, yrs	Type of fixation	Bone graft	Union rate and mean time to union, mo	Pertinent outcome	Mean follow-up, mo
Femoral neck LeCroy	2002	22	29	3 mm C-wire transfixing fibula + large cannulated screws parallel to fibula	Free vascularized fibula autograft	91% (20/22) TTU = 9.9	HHS: 56.4 (preop) to 78.9 (postop) All achieved eventual union	85
	2005	7	46	DHS + VITO	Osteotomy wedge autograft	100% (7/7) TTU = 3	HHS: 24 (preop) to 73 (postop) No AVN	24
	2012	22	38	130° blade plate	Free nonvascularized fibula autograft	95% (21/22) TTU = 4.4	20/22 with fair, good or excellent functional outcome	38
Magu	2014	39	47	130° blade plate + VITO (36), DHS + VITO (3)	None	92% (36/39) TTU = n/a	1 AVN requiring THA 32/39 with good or excellent functional outcome (HHS 80–100) 3 AVN	95
Intertrochanteric Haidukewych	2003	20	58	Blade plate (11), DHS (5), DCS (3), Cephalomedullary nail (1)	Autograft (17), allograft (3)	95% (19/20) TTU = n/a	16/19 w/o pain 0 AVN	27
	2006	26	61	DHS (8), DHS + VSTO (6), Blade plate + VSTO (4), THA (3), Endoprosthesis (5)	None	100% (18/18) TTU = 4	16/18 w/o pain, 2/18 occasional pain 1 AVN	31
Xue	2017	23	60	DHS (3), Cephalomedullary nail (9), Proximal locking plate (3), THA (4), Antibiotic rod staged to proximal locking plate (4)	Iliac crest autograft (6)	100% (19/19) TTU = 4.7	HHS: 28.9 (preop) to 83.8 (postop)	16
Subtrochanteric Haidukewych	2004	21	55	Cephalomedullary nail (8), standard antegrade IMN (7), 95° blade plate (5), DHS (1), 95° DCS (1), dual large-fragment plates (1)	Autograft (8), allograft (6), both (3), free vascularized fibula (1)	95% (20/21) TTU = n/a	16/20 with no pain; 4/20 with mild pain. All ambulatory.	12
	2004	26	63	Long Gamma cephalomedullary nail	Autograft (5)	96% (25/26) TTU = 7	21/26 restored to preinjury functional status (Traumatic Hip Rating Scale)	27
de Vries	2006	33	57	95° blade plate (24), 100–125° blade plate (7), 90° blade plate (2)	Iliac crest autograft (13), local bone graft (1), DBX (10)	97% (32/33) TTU = 5	25/33 good or excellent Merle d'Aubigne score 5 complications requiring reoperation	31

DBX = demineralized bone matrix; DCS = dynamic condylar screw; DHS = dynamic hip screw; HHS = Harris Hip Score; IMN = intramedullary nail; n/a = not available; THA = total hip arthroplasty; TTU = time to union; VSTO = valgus subtrochanteric osteotomy.

union rate at a mean follow-up of 10 months. Sen et al<sup>[5]</sup> demonstrated similar success using nonvascularized fibular grafting with an ABP, advocating that the use of a more rigid device lessens the mechanical stress seen by the graft and theoretically improves healing potential. Lastly, Elgafy et al<sup>[26]</sup> showed better union rate (69% vs. 33%) with a shorter time to union (5 vs. 13 mo) using nonvascularized fibular autograft compared to fibular allograft, respectively. Future comparative studies are needed to delineate the appropriate indication for each technique.

Patients 2 and 3 highlight the use of an ABP in peritrochanteric nonunions. Over the last 15 years, several series have demonstrated near 100% union rate at around 5 months using a variety of implants with restoration of preinjury functional status at 1 to 2 year follow-up (Table 1).<sup>[4,27–31]</sup> However, even in the most experienced hands, there can be technical challenges using an ABP.<sup>[3,28,31,32]</sup> In patient 2, an ABP was used to acutely fix a displaced intertrochanteric fracture. Notably, the ABP was not used in a compression manner and placed in varus, which we believe led to increased shear forces at the fracture site and ultimately implant failure (Fig. 2A). In the second procedure, though an external compression device was utilized, the amount of varus correction proved to be inadequate (Fig. 2B), creating motion at the fracture site and leading to a hypertrophic nonunion (Fig. 2C). These two failures demonstrate the importance of both deformity correction and fracture site compression to achieve union. Thus, it was only after both a compression technique and a more valgus angled blade (130°) were utilized that union occurred (Fig. 2D).

As noted in patient 2, the use of an ABP does not come without technical challenges and potential complication. Its “unforgiving” nature stems from the lack of modification permitted once the blade has been inserted in the bone. In a reduced fracture, a blade inserted inappropriately in the coronal plane will likely lead to varus or valgus fracture malreduction, and if not perpendicular to the femur in the sagittal plane will push the distal aspect of the plate either too anterior or posterior on the femur. In this scenario, attempting to manipulate the plate to the bone will often force the fracture into either procurvatum or recurvatum. For these reasons, precise guide pin and chisel placement prior to blade insertion in both planes remains paramount to successful use.<sup>[13,33,34]</sup> In contrast, there remains a relative ease to placing cephalomedullary nails, likely due to the increased familiarity in obtaining the starting point for their insertion. This advantage however may be compromised if the fracture extends significantly into the greater trochanter where nail insertion can potentially lead to fracture propagation or cause unwanted comminution compromising the reduction. In this setting, an ABP may serve as a reliable alternative.<sup>[33]</sup>

Despite these few technical considerations, the ABP has several potential benefits over other modern implants. Patient 3 illustrates a unique advantage of this implant in the revision setting: the ability to strategically place the blade in uncompromised bone in the inferomedial portion of the femoral neck while also facilitating deformity correction. This avoids reusing the weaker central portion of the neck created by initial screw fixation. However, this approach does not completely eliminate the risk of implant loosening. Proximal migration of the blade through the bony void is a real concern, particularly in osteopenic bone, as we observed in this patient (Fig. 3C). This led to the novel use of a fibular allograft as a structural ceiling to prevent remigration of the blade and ultimately assist in the stability of the construct to promote fracture healing (Fig. 3E).

Though provisional reduction is often sought and recommended prior to implant insertion in hip fracture nonunion, another potential benefit of the ABP is its ability to help achieve additional deformity correction when appropriately inserted, particularly if the fracture is in varus. We have not had similar anecdotal success to this end with the cephalomedullary nail or proximal locking plate. Obtaining an intraoperative contralateral hip radiograph guides us in our decision as to how much to correct, with the goal of restoring the patient’s native hip morphology and neck-shaft angle. We also appreciate the ABP’s theoretical bone preserving nature, with a relatively smaller bony footprint thought to be created compared to larger lag screws or barrels, though we are unaware of any direct comparative studies.<sup>[13]</sup> As well, substantial compression can be achieved and is recommended through the ABP, as it accommodates the use of an external compression device. To this point, however, a relative contraindication to the blade plate can be poor bone quality, or significant fracture comminution such that it cannot endure adequate compression at the fracture site. Furthermore, fractures with substantial subtrochanteric fracture extension often warrant a long intramedullary device.<sup>[33]</sup> In summary, we recommend implant selection should be made on a patient-specific and surgeon-specific basis, considering the host of factors previously mentioned.

In conclusion, these three cases demonstrate the efficacy of the ABP in a joint preserving approach to hip fracture nonunion treatment. Though current retrospective literature reveals excellent radiographic and clinical outcome is achievable with a variety of implants and bone grafts, prospective comparative studies are needed to elucidate further distinctions.

## References

- Haidukewych GJ, Berry DJ. Salvage of failed treatment of hip fractures. *J Am Acad Orthop Surg.* 2005;13:101–109.
- Angelini M, McKee MD, Waddell JP, et al. Salvage of failed hip fracture fixation. *J Orthop Trauma.* 2009;23:471–478.
- Haidukewych GJ, Berry DJ. Salvage of failed internal fixation of intertrochanteric hip fractures. *Clin Orthop Relat Res.* 2003; 184–188.
- Haidukewych GJ, Berry DJ. Nonunion of fractures of the subtrochanteric region of the femur. *Clin Orthop Relat Res.* 2004; 185–188.
- Sen RK, Tripathy SK, Goyal T, et al. Osteosynthesis of femoral-neck nonunion with angle blade plate and autogenous fibular graft. *Int Orthop.* 2012;36:827–832.
- Tripathy SK, Sen RK, Goyal T. Nonvascularized fibular grafting in nonunion of femoral neck fracture: a systematic review. *Indian J Orthop.* 2016;50:345–351.
- Varghese VD, Boopalan PR, Titus VTK, et al. Indices affecting outcome of neglected femoral neck fractures after valgus intertrochanteric osteotomy. *J Orthop Trauma.* 2014;28:410–416.
- Varghese VD, Livingston A, Boopalan PR, et al. Valgus osteotomy for nonunion and neglected neck of femur fractures. *World J Orthop.* 2016;7:301–307.
- Mayo K, Kuldjanov D. Generic preoperative planning for proximal femoral osteotomy in the treatment of nonunion of the femoral neck. *J Orthop Trauma.* 2018;32 (suppl 1):S46–54.
- Hartford JM, Patel A, Powell J. Intertrochanteric osteotomy using a dynamic hip screw for femoral neck nonunion. *J Orthop Trauma.* 2005;19:329–333.
- Schoenfeld AJ, Vrabec GA. Valgus osteotomy of the proximal femur with sliding hip screw for the treatment of femoral neck nonunions: the technique, a case series, and literature review. *J Orthop Trauma.* 2006;20:485–491.
- Altenberg AR, Shorkey RL. Blade-plate fixation in non-union and in complicated fractures of the supracondylar region of the femur. *J Bone Joint Surg Am.* 1949;31A:312–316.

13. Amorosa LF, Jayaram PR, Wellman DS, et al. The use of the 95-degree-angled blade plate in femoral nonunion surgery. *Eur J Orthop Surg Traumatol.* 2014;24:953–960.
14. Vallier HA, Immler W. Comparison of the 95-degree angled blade plate and the locking condylar plate for the treatment of distal femoral fractures. *J Orthop Trauma.* 2012;26:327–332.
15. Mathews V, Cabanela ME. Femoral neck nonunion treatment. *Clin Orthop Relat Res.* 2004;57–64.
16. Ju L, Jiang B, Lou Y, et al. Delayed treatment of femoral neck fractures in 58 children: open reduction internal fixation versus closed reduction internal fixation. *J Pediatr Orthop B.* 2016;25:459–465.
17. Wang S-H, Yang J-J, Shen H-C, et al. Using a modified Pauwels method to predict the outcome of femoral neck fracture in relatively young patients. *Injury.* 2015;46:1969–1974.
18. Haidukewych GJ. Salvage of failed treatment of femoral neck fractures. *Instr Course Lect.* 2009;58:83–90.
19. Magu NK, Singla R, Rohilla R, et al. Modified Pauwels' intertrochanteric osteotomy in the management of nonunion of a femoral neck fracture following failed osteosynthesis. *Bone Joint J.* 2014;96-B:1198–1201.
20. Chotigavanichaya C, Leeprakobboon D, Eamsobhana P, et al. Results of surgical treatment of coxa vara in children: valgus osteotomy with angle blade plate fixation. *J Med Assoc Thai.* 2014;97 (suppl 9):S78–82.
21. Marti RK, Schüller HM, Raaymakers EL. Intertrochanteric osteotomy for non-union of the femoral neck. *J Bone Joint Surg Br.* 1989;71:782–787.
22. Magu NK, Singh R, Sharma AK, et al. Modified Pauwels' intertrochanteric osteotomy in neglected femoral neck fractures in children: a report of 10 cases followed for a minimum of 5 years. *J Orthop Trauma.* 2007;21:237–243.
23. Said GZ, Farouk O, Said HGZ. Valgus intertrochanteric osteotomy with single-angled 130° plate fixation for fractures and non-unions of the femoral neck. *Int Orthop.* 2010;34:1291–1295.
24. Wu CC, Shih CH, Chen WJ, et al. Treatment of femoral neck nonunions with a sliding compression screw: comparison with and without subtrochanteric valgus osteotomy. *J Trauma.* 1999;46:312–317.
25. LeCroy CM, Rizzo M, Gunneson EE, et al. Free vascularized fibular bone grafting in the management of femoral neck nonunion in patients younger than fifty years. *J Orthop Trauma.* 2002;16:464–472.
26. Elgafy H, Ebraheim NA, Bach HG. Revision internal fixation and nonvascular fibular graft for femoral neck nonunion. *J Trauma.* 2011;70:169–173.
27. Haidukewych GJ, Berry DJ. Hip arthroplasty for salvage of failed treatment of intertrochanteric hip fractures. *J Bone Joint Surg Am.* 2003;85-A:899–904.
28. Said GZ, Farouk O, El-Sayed A, et al. Salvage of failed dynamic hip screw fixation of intertrochanteric fractures. *Injury.* 2006;37:194–202.
29. Xue D, Yu J, Zheng Q, et al. The treatment strategies of intertrochanteric fractures nonunion: an experience of 23 nonunion patients. *Injury.* 2017;48:708–714.
30. Barquet A, Mayora G, Fregeiro J, et al. The treatment of subtrochanteric nonunions with the long gamma nail: twenty-six patients with a minimum 2-year follow-up. *J Orthop Trauma.* 2004;18:346–353.
31. de Vries JS, Kloen P, Borens O, et al. Treatment of subtrochanteric nonunions. *Injury.* 2006;37:203–211.
32. Yoo M-C, Cho Y-J, Kim K-I, et al. Treatment of unstable peritrochanteric femoral fractures using a 95 degrees angled blade plate. *J Orthop Trauma.* 2005;19:687–692.
33. Hartline BE, Achor TS. Use of the 95-degree angled blade plate to treat a proximal femur fracture. *J Orthop Trauma.* 2018;32 (suppl 1):S26–S27.
34. Rollick NC, Bear J, Diamond O, et al. Orthogonal plating with a 95 degree blade plate for salvage of unsuccessful cephalomedullary nailing of atypic femur fractures: a technical trick. *J Orthop Trauma.* 2019;33:e246–e250.