

# Cecal Perforation in the Setting of *Campylobacter jejuni* Infection

Seema Jain, MD<sup>1</sup>, Weston Bettner, MD<sup>2</sup>, Dane C. Olevia, MD<sup>3</sup>, and Dhiraj Yadav, MD, MPH<sup>2</sup>

<sup>1</sup>Department of Internal Medicine, University of Pittsburgh Medical Center, Pittsburgh, PA

<sup>2</sup>Department of Gastroenterology, Hepatology and Nutrition, University of Pittsburgh Medical Center, Pittsburgh, PA

<sup>3</sup>Department of Pathology, Anatomy, and Laboratory Medicine, West Virginia University, Morgantown, WV

## ABSTRACT

*Campylobacter* infection is the leading cause of bacterial gastroenteritis worldwide, yet life-threatening complications are extremely rare. We present a 32-year-old previously healthy man who presented with dysentery from *Campylobacter jejuni*, which was complicated by cecal perforation and secondary bacterial peritonitis.

## INTRODUCTION

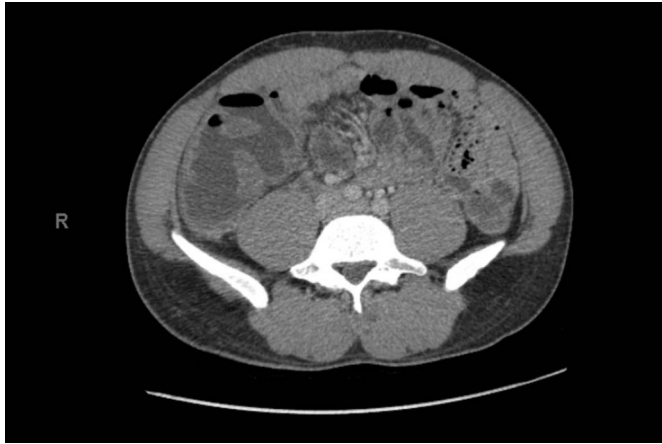*Campylobacter* is the leading cause of bacterial gastroenteritis worldwide, with *Campylobacter jejuni* being the most common species to cause illness. Typically, *C. jejuni* causes acute self-limited gastroenteritis. However, 10%–20% of culture-confirmed cases in the United States require hospitalization.<sup>1</sup> Acute enteric complications are uncommon and include mesenteric adenitis, pseudomembranous colitis, massive gastrointestinal bleeding, ischemic bowel disease, and bowel perforation.<sup>1,2</sup> Colonic perforation is exceedingly rare; only a handful of reported cases exist, primarily in the context of toxic megacolon.<sup>3,4</sup> We present a case of enterocolitis secondary to *C. jejuni* complicated by cecal perforation.

## CASE REPORT

A 32-year-old previously healthy man presented with 4 days of fevers, bilateral lower quadrant abdominal pain, and bloody diarrhea after returning from a 9-day trip to Japan. Stools were initially watery but progressed to a bloody, currant-jelly consistency. He was febrile up to 39.5°C before presentation. He presented to the emergency department 1 day after returning from his trip, where he was febrile to 38.2°C and tachycardic to 108 beats per minute. A basic metabolic panel and complete blood count were remarkable for mild hyponatremia of 132 mmol/L and mild hypokalemia of 3.3 mmol/L; no leukocytosis was evident. Stool samples were obtained, and he was discharged on a 3-day course of azithromycin for the treatment of dysentery. Within 12 hours, however, he re-presented with severe right lower quadrant abdominal pain. Abdominal and pelvic computed tomography (CT) scan demonstrated acute enterocolitis consisting of moderately distended, thickened, fluid-filled loops of the distal ileum and colon, most prominent in the right hemicolon and cecum (Figure 1). Reactive mesenteric lymph nodes up to 1.5 cm in the right lower quadrant and diffuse mesenteric edema were also demonstrated.

The patient was given intravenous fluids and discharged. Despite 2 days of adherence to azithromycin therapy, he had persistent symptoms and so presented to the infectious disease clinic. Stool nucleic acid amplification testing had by then returned positive for *C. jejuni* with negative results for other bacterial pathogens. He was admitted for initiation of intravenous meropenem, given a concern for macrolide resistance.

On admission, he remained tachycardic and developed a leukocytosis to  $12.6 \times 10^9$  cells/L with neutrophil predominance. On day 2 of admission, he developed a new singultus with an abdominal examination demonstrating rebound and guarding. His laboratory results were remarkable for a new bandemia of 22% and a fall in his albumin from 3.8 to 2.8 g/dL. An abdominal x-ray revealed free air underlying the diaphragm (Figure 2).



**Figure 1.** Abdominal and pelvic computed tomography showing distended and thickened fluid-filled loops of distal ileum and colon.

The patient underwent an emergent exploratory laparotomy, which revealed cecal perforation complicated by gross fecal contamination of the abdomen. Peritoneal cultures were obtained, and an ileocolic resection with a side-to-side ileocolonic anastomosis was performed. Pathology demonstrated active enterocolitis with ulceration, patchy mild crypt distortion, transmural colonic perforation, and acute serositis (Figure 3). There was no evidence of chronic mucosal injuries such as granulomas, transmural chronic inflammation, or mural scarring, arguing against an underlying diagnosis of inflammatory bowel disease. Intraoperative cultures grew pan-sensitive *Enterococcus faecalis*, whereas blood cultures remained negative. He was treated with 8 days of meropenem overlapped with 3 days of gentamicin for empiric treatment of *C. jejuni*. Antibiotic therapy was extended with an additional 4 days of piperacillin-tazobactam to complete treatment of *E. faecalis*.

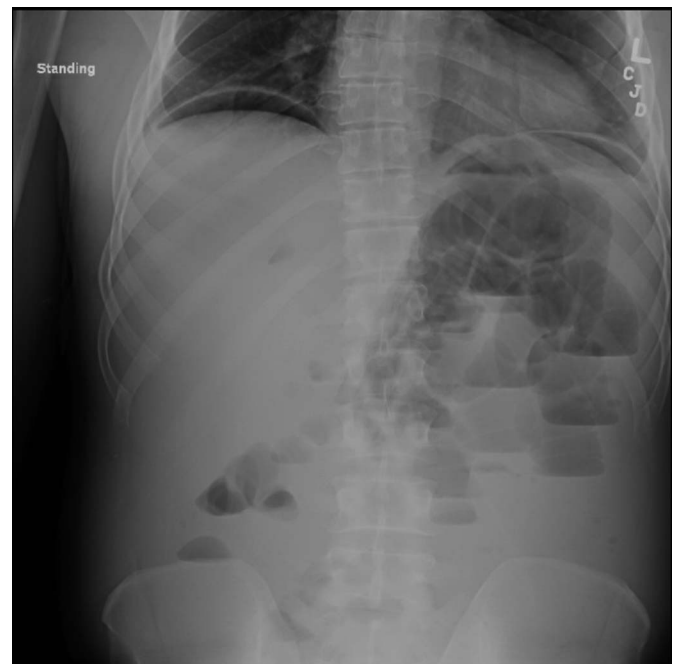
Postoperatively, his hemoglobin dropped from 12.2 to 7.5 g/dL over the course of 4 days with no overt gastrointestinal bleeding. A CT scan demonstrated a large hematoma in the right lower quadrant of the retroperitoneum without active contrast extravasation on angiogram. The patient then underwent a repeat exploratory laparotomy that revealed a large clot in the pelvis near the anastomosis, which was evacuated; no active source of bleeding was seen, and his hemoglobin stabilized thereafter. He subsequently developed a postoperative ileus and briefly required total parenteral nutrition. He was discharged on hospital day 16 with negative pressure wound therapy. He was evaluated in the clinic 2 weeks after discharge with significant improvement in his symptoms.

## DISCUSSION

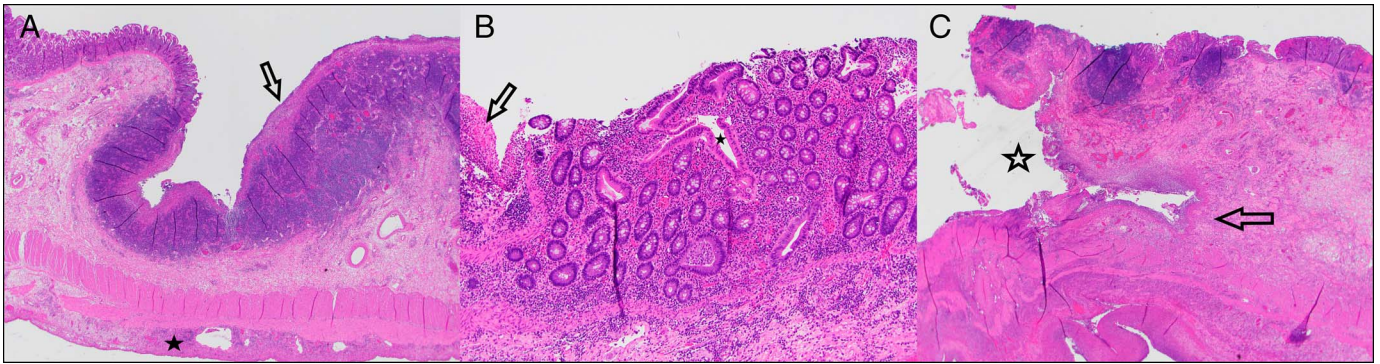
*Campylobacter jejuni* infection typically causes acute self-limited gastroenteritis or colitis with symptoms lasting 1 day to 1 week. The most common symptoms are crampy abdominal pain, malaise, fever, and diarrhea, with stools that can range from loose to watery to bloody.<sup>2</sup> The cornerstone of treatment, as for any diarrheal illness, is fluid and electrolyte replacement.<sup>5</sup>

In a meta-analysis of 11 small randomized trials, antimicrobial therapy, when started early in the disease course, reduced duration of symptoms by 1.3 days.<sup>6</sup> Antimicrobial therapy is typically reserved for patients with severe symptoms such as high fever, massive or bloody diarrhea, or symptoms persisting for more than 1 week. Owing to increased rates of fluoroquinolone resistance, macrolides are considered first-line therapy when antimicrobials are warranted.<sup>5</sup>

Identifying and treating patients at risk for enteric complications of *C. jejuni* infection is challenging as complications are so rare. Only a handful of cases of perforation from *C. jejuni* infection have been reported. In previous cases of perforation, patients had sudden worsening of their abdominal examination along with concurrent fevers and increasing leukocytosis before the development of toxic megacolon.<sup>3,4,7</sup> Similarly, our patient had an ongoing systemic inflammatory response despite adequate fluid resuscitation and antimicrobial therapy as his abdominal examination progressed to an acute abdomen. Persistent systemic inflammatory response criteria in concordance with other inflammatory laboratory markers despite adequate initial therapy may, therefore, be helpful in identifying patients at risk for toxicity who warrant serial examinations or repeat imaging. Our patient developed a new leukocytosis on admission followed by a bandemia and hypoalbuminemia approximately 12 hours before his surgical resection. C-reactive protein was not checked for our patient but may have been an additional helpful tool for risk stratification, as markedly elevated C-reactive protein was noted in 2 cases of bowel perforation secondary to *C. jejuni*.<sup>7,8</sup>



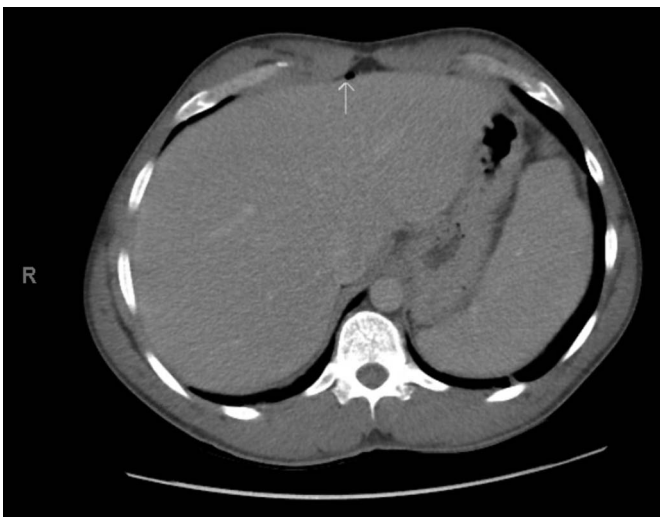**Figure 2.** Abdominal x-ray showing large volume pneumoperitoneum with diffuse distended and dilated loops of the small bowel and numerous air-fluid levels.



**Figure 3.** (A) Histological examination of the terminal ileum showing neutrophilic inflammation and superficial mucosal ulceration (arrow) overlying prominent Peyer's patches with acute and organizing serositis (star) secondary to the nearby colonic perforation. Histological examination of the cecum showing the (B) colonic mucosa which shows widespread evidence of acute colitis, including cryptitis, crypt abscesses, and expansion of the lamina propria by mixed inflammatory cells. There is patchy, mild crypt architectural distortion (star), including irregular and branched crypts (center). However, well-developed features of chronic mucosal injury are absent. The edge of an adjacent ulcer with fibrinopurulent exudate is shown at left (arrow), and (C) there is a transmural defect present (star) that is associated with ulceration, transmural neutrophilic inflammation (arrow), edema, focal necrosis, and acute serositis.

In most of the previously reported cases of intestinal perforation from *C. jejuni* infection, colonic dilation, particularly in the form of toxic megacolon, was a harbinger for perforation, although perforation in the absence of marked distension has also been reported.<sup>7</sup> In our case, the initial CT exhibited moderate colonic distension, particularly in the right hemi-colon. On further review of the initial CT, a punctate focus of free air was seen adjacent to the liver, which was not formally reported (Figure 4). This finding suggests a sentinel micro-perforation that could have preceded macroscopic complications and highlights the importance of imaging review with radiology. To our knowledge, no other study has noted this finding.

An additional risk factor for enteric complications may be the virulence of the *C. jejuni* isolate. Drug-resistant *C. jejuni* species are associated with an increased risk for invasive illness and



**Figure 4.** Abdominal and pelvic computed tomography showing punctate focus of free air adjacent to liver (arrow).

death.<sup>9</sup> Our patient may have grown a multidrug-resistant organism because he did not respond to macrolide therapy within 48 hours, and his *C. jejuni* isolate revealed doxycycline resistance on send-out testing; unfortunately, other sensitivities were not reported. Resistance would have been unexpected, however, because rates of macrolide resistance for *C. jejuni* species from Japan are stably low.<sup>10</sup> In patients failing to respond to conventional macrolide therapy, especially those contracting disease in regions with higher rates of drug-resistant *C. jejuni*, such as Thailand, Africa, and Mexico, escalation to a carbapenem or aminoglycoside should be considered.<sup>2</sup> Our case demonstrates an atypical life-threatening complication of colonic perforation in a common illness that is usually self-limiting.

## DISCLOSURES

Author contributions: S. Jain and W. Bettner wrote and revised the manuscript. DC Olevian provided the histological images. D. Yadav edited the manuscript, revised the manuscript for intellectual content, and is the article guarantor.

Financial disclosure: None to report.

Informed consent was obtained for this case report.

Received June 25, 2019; Accepted September 23, 2019

## REFERENCES

- Kirkpatrick BD, Tribble DR. Update on human *Campylobacter jejuni* infections. *Curr Opin Gastroenterol*. 2011;27(1):1-7.
- Allos CM, Iovine NM, Blaser MJ. *Campylobacter jejuni* and related species. In: Bennett JE, Dolin R, Blaser MJ (eds). *Mandell, Douglas, and Bennett's Principles and Practice of Infectious Diseases*. 8th edn. Elsevier: Philadelphia, PA, 2015, pp 2485-93.
- Kummer AF, Meyenberger C. Toxic megacolon as a complication of *Campylobacter jejuni* enterocolitis. *Schweiz Med Wochenschr*. 1998; 128(41):1553-8.

4. Vyas SK, Law NN, Hill S, et al. Toxic megacolon with late perforation in *Campylobacter colitis*—A cautionary tale. *Postgrad Med J*. 1993;69(810):322–4.
5. Shane AL, Mody RK, Crump JA, et al. 2017 Infectious Disease Society of America Clinical Practice Guidelines for the Diagnosis and Management of Infectious Diarrhea. *Clin Infect Dis*. 2017;65(12):e45–80.
6. Ternhag A, Asikainen T, Giesecke J, Ekdahl K. A meta-analysis on the effects of antibiotic treatment on duration of symptoms caused by infection with *Campylobacter* species. *Clin Infect Dis*. 2007;44(5):696–700.
7. Fischer J, Mackay B, Wakeman C. Caecal perforation in the absence of toxic dilatation in *Campylobacter colitis*. *ANZ J Surg*. 2013;83:583–4.
8. Jassim SS, Malik A, Aldridge A. Small bowel perforation: An unusual case. *Grand Rounds*. 2011;11:17–9.
9. Helms M, Simonsen J, Olsen KEP, et al. Adverse health events associated with antimicrobial drug resistance in *Campylobacter* species: A registry-based cohort study. *J Inf Dis*. 2005;191(7):1050–5.
10. Gibreel A, Taylor DE. Macrolide resistance in *Campylobacter jejuni* and *Campylobacter coli*. *J Antimicrob Chemother*. 2006;58(2):243–55.

---

**Copyright:** © 2019 The Author(s). Published by Wolters Kluwer Health, Inc. on behalf of The American College of Gastroenterology. This is an open-access article distributed under the terms of the Creative Commons Attribution-Non Commercial-No Derivatives License 4.0 (CCBY-NC-ND), where it is permissible to download and share the work provided it is properly cited. The work cannot be changed in any way or used commercially without permission from the journal.