

# Orthokeratinized odontogenic cyst of the mandible: A rare case report with a systematic review

Bhumi Sarvaiya, Hitesh Vadera<sup>1</sup>, Vimal Sharma<sup>2</sup>, Kaustubh Bhad<sup>1</sup>, Zinal Patel<sup>3</sup>,  
Mimansa Thakkar<sup>3</sup>

Departments of Pedodontics and Preventive Dentistry, and <sup>2</sup>Orthodontics and Dentofacial Orthopedics, faculty of dental science, Dharmsinh Desai University, Nadiad, Departments of <sup>1</sup>Oral and Maxillofacial Surgery, and <sup>3</sup>BDS, Karnavati School of Dentistry, Uvarsad, Gandhinagar, Gujarat, India

Corresponding author (email: <sarvaiyabhumi@gmail.com>)

Dr. Bhumi Sarvaiya, Department of Pedodontics and Preventive Dentistry, Faculty of Dental Sciences, Dharmsinh Desai University, Nadiad, Gujarat, India.

## Abstract

Orthokeratinized odontogenic cyst (OOC) is an odontogenic cyst was initially termed as the uncommon orthokeratinized type of odontogenic keratocyst by the World Health Organization. It usually occurs in mandible. Various studies have shown that OOC has typical characteristic clinicopathologic features when compared to other developmental odontogenic lesions such as dentigerous cyst and the keratocystic odontogenic tumor (KCOT). Rare recurrence was noted after surgical removal of the lesion. The purpose of this article is to present a case of OOC arising in the posterior mandible and emphasize on differentiating it from the KCOT and dentigerous cyst.

**Key words:** *Odontogenic cyst, odontogenic keratocyst, orthokeratinization*

## INTRODUCTION WITH REVIEW OF LITERATURE

In 1992, World Health Organization (WHO) (1992) has defined Orthokeratinized odontogenic cyst (OOC) as the uncommon orthokeratinized type of odontogenic keratocyst (OKC). OOC differs in many aspects from developmental odontogenic cysts, especially dentigerous cyst and OKCs.<sup>[1]</sup> Other than OKC, there are many other odontogenic cysts which also produce orthokeratin.<sup>[2]</sup> In 1927, OOC was first described as an orthokeratinized variant of the formerly called OKC, which is known as the keratocystic odontogenic tumor (KCOT) by Schultzas. In 1981, Wright defines this as a separate entity.<sup>[3]</sup> In 2005, WHO redefined OKC as a neoplasm and termed it as KCOT.<sup>[4]</sup> KCOT occurs in

the oral cavity about eight times more commonly than OOC.<sup>[1]</sup>

## Clinical features

Males are more commonly affected than females and more commonly this lesion is seen the third and fourth decades.<sup>[3,4]</sup> The mandible is affected twice as often as the maxilla. The molar and ramus regions are more commonly involved.<sup>[3]</sup> About two-third of OOCs are associated with impacted teeth, which appear clinically and radiographically similar like dentigerous cyst.<sup>[2,5]</sup>

The age of occurrence and site of predilection for OOC is same as for KCOT, yet these two lesions differ in their biological activity. The difference lies in the fact that KCOT can occur at multiple sites. Nevroid basal cell carcinoma syndrome can be associated with KCOT.<sup>[4]</sup> OOC can be presented as a swelling with or without pain which can reach a large size that causes cortical expansion. In most of the cases, it can be detected incidentally during a radiographic examination. Size of the lesion can vary from <1 cm to 7 cm.<sup>[3,6]</sup>

Access this article online	
Quick Response Code:	Website: <a href="http://www.jispcd.org">www.jispcd.org</a>
	DOI: 10.4103/2231-0762.131265

## Radiographic features

Radiographically the cyst appears as a well-circumscribed radiolucency that occasionally, which is associated with an unerupted tooth or with the root without causing resorption. This radiolucency can be unilocular or multilocular. It can displace neighboring teeth and of the inferior dental canal too.<sup>[7-10]</sup>

## Histologic features

Epithelial lining of OOC lesions show four to eight cell layers of thick, uniform orthokeratinized stratified squamous epithelium with a prominent granular cell layer. The basal cells are flat to cuboidal, without the palisading or polarization features, which are commonly seen in the KCOT.<sup>[3]</sup>

## Etiopathogenesis

The OOC is a developmental odontogenic cyst relatively rare; arising from the cell rests of the dental lamina. Kotwaney S *et al.*, had shown the role of reduced enamel epithelium in formation of dentigerous cyst that had completed its tooth-forming function and which had the capability to keratinize under appropriate stimuli, This is how the true dentigerous cyst with keratinization may be formed.<sup>[5]</sup> Zhu suggested that like KCOT, which arise from the dental lamina with the presence of the dental papilla, the OOC may arise from oral epithelium under the influence of the dental papilla or only the oral epithelium. Due to this different histogenesis of KCOTs and OOCs further investigation is required. Most of the studies suggest KCOT originate from dental lamina. This would explain their common occurrence in the posterior mandible, because the dental lamina is more active in this area at the age when many patients develop their cysts.<sup>[1,2,5]</sup>

## Immunohistochemistry

The KCOT is clinically more aggressive than other forms of odontogenic cyst and tends to recur after surgery. The recurrence in KCOT has varied from 12% to 60%. These may be due to significantly less expression of p63 in OOCs than KCOTs. p63 which is a member of the p53 tumor suppressor gene family, plays a major role in the terminal differentiation of epithelial stem cells as well as their maintenance. Due to less significant expression of p63 in OOC, epithelial cells have less proliferative and selfrenewal potential. p63 expression usually seen be more intensive and diffuse in malignant odontogenic tumors and benign odontogenic tumors, which showed local aggressiveness in comparison of other odontogenic tumors. Even recent immunocytochemical results

demonstrated fewer Ki-67-positive proliferating cells, which are mostly confined to the basal cell layer in the epithelial linings of OOC than KCOT. Thus, KCOT lining demonstrate more prominent suprabasal proliferative activity than that of OOC.<sup>[11-14]</sup>

## Treatment

Enucleation with curettage is the treatment of choice for OOCs. Only 4% of OOCs showed recurrence. In a study done by Crowley, Kaugars and Gunsolle recurrence rates of the OOC was 2.2%.<sup>[3,5,15]</sup>

To get more knowledge about OOC a systematic review was performed using various exclusion and inclusion criteria [Tables 1 and 2]. Various studies including review articles, research studies, and case reports were analyzed [Table 3]. These showed OOC as less aggressive lesion than OKC and had less malignant potential too as well as various tumor markers and immunohistochemistry can be used to distinguish OOC from OKC [Table 4].

In this paper, we report a case of the OOC, which clinically and radiographically appears lesions like dentigerous cyst or KCOT, but histologically proved to be OOC. Hence, this case draws attention to put

**Table 1: Criteria for inclusion of studies for OKC**

Criteria
<i>In vivo</i> studies
Conducted in humans
Prospective
Experimental and control group
Related to the case report and treatment of OKC
Studies published in English language
OKC=Odontogenic keratocyst

**Table 2: Criteria for exclusion of article for OKC**

Criteria
<i>In vitro</i> studies
Developed in animals
Departmental review of the literature or narrative reviews
Nontreated/incomplete cases report
Works with no summary
Study in the source language is not in English
Noncomparative pilot studies

**Table 3: Type of studies retrieved**

Types of study	Number of articles
Studies	9
Case reports	13
Review	1
Total	24

**Table 4: Summary of studies for OOC**

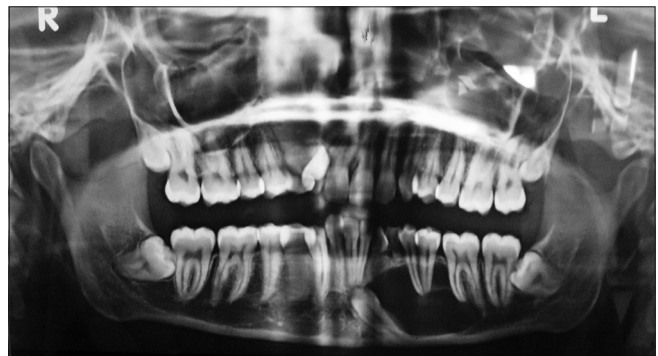Sample	Reference	Number of subjects	Outcome
Evaluation of Ki-67 and cyclin D1 expression in OKCs and OJCs	Gani <i>et al.</i> , 2012	OKC-15 patients, OOC-15 patients	Expression of Ki-67 and cyclin D1 differed significantly quantitatively and by distribution pattern in OKC and OJC respectively
Immunohistochemical study of the OOC: a comparison with the OKC	Da silva <i>et al.</i> , 2002	OKC-12 patients, OOC-12 patients	OOC presents a well-formed cystic enveloping, in comparison of OKC which showed a more aggressive biologic behavior
Orthokeratinized OKCs in Malaysians	Siar <i>et al.</i> , 1988	9 cases	Peak incidence in the second decade of life, an almost even distribution in the maxilla and mandible, and a distinct predilection for the Chinese were observed in OOC
Study of the biologic behavior of OKC and OOC using TGF-alpha and p53 markers	Deyhimi <i>et al.</i> , 2014	15 OKC and 15 OOC	In OKC compared to OOC higher expression of p53 and TGF-alpha were noted suggesting that the probability of carcinomatous changes was higher in OKC than in OOC
Evaluation of stromal MFs expression in KCOT and OOCs: A comparative study	Roy <i>et al.</i> , 2013	10 cases of KCOT and 10 cases of OOC	Due to aggressive behavior and increased tendency towards recurrence of KCOT, number of stromal MFs were increased in KCOT than OOC
OOC: a clinicopathologic study of 61 cases	Donq <i>et al.</i> , 2010	61 cases of OOC	Due to distinct clinicopathologic features OOC should be identified separately than KCOT
OKC, OOC and EDC: An immunohistochemical study including markers of proliferation, cytokeratin and apoptosis related factors	Yasuyuki Koizum, 2003	Fourteen cases of OKC, nine cases of OOC and eighteen cases EDC	It was possible to consider OOC as a distinct entity from OKC. EDC had the lowest cellular activity in the three cysts and it was comparatively matured lesion
OOC: a clinicopathological and immunocytochemical study of 15 cases	Li <i>et al.</i> , 1998	15 patients	OOC should identified with a distinct clinical entity due to its different clinicopathologic features than other odontogenic cyst
OOC in a Hong Kong community: the clinical and radiological features	Macdonald-jankowaski and Li 2010	5 patients	OOCs expressed as an expansile character, but did not recur after moderately long follow-up in this community

OKC=Odontogenic keratocyst; OJC=Orthokeratinized jaw cyst; OOC=Orthokeratinized odontogenic cyst; TGF=Transforming growth factor; KCOT=Keratocystic odontogenic tumor; MFs=Myofibroblasts, EDC=Epidermal cyst

OOC as one of the differential diagnosis of various pericoronal radiolucent lesions of jaw.

## CASE REPORT

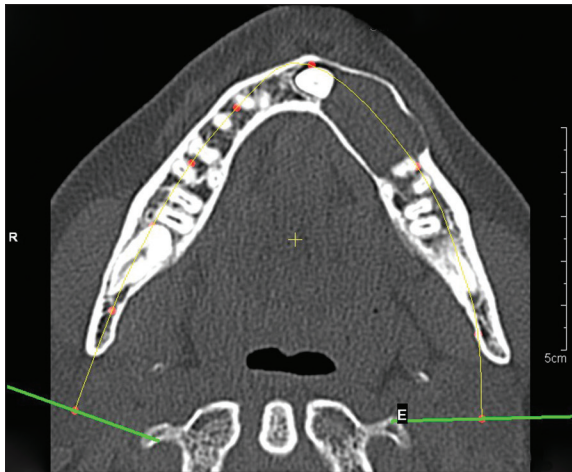
A 30-year-old female patient presented with the complaint of pain in the lower left jaw since last 4 months. Extra oral examination revealed no facial asymmetry. Intra-oral mild swelling was present extending from lower left lateral incisor to left first molar region. Expansion of buccal cortical plate was evident with crepitus at some area. All laboratory findings were within normal range. Orthopentogram showed a well-defined radiolucency with corticated border in the body of the mandible extending from 32 to 36 regions and extending up to the inferior border of the mandible with impacted canine. Over-retained deciduous canine was present in lower left mandible [Figure 1]. Computed tomography showed an expansile osteolytic lesion with buccal cortical plate perforation [Figures 2 and 3]. Provisional diagnosis of lateral dentigerous cyst with impacted canine was suggested with differential diagnosis of KCOT, unicystic



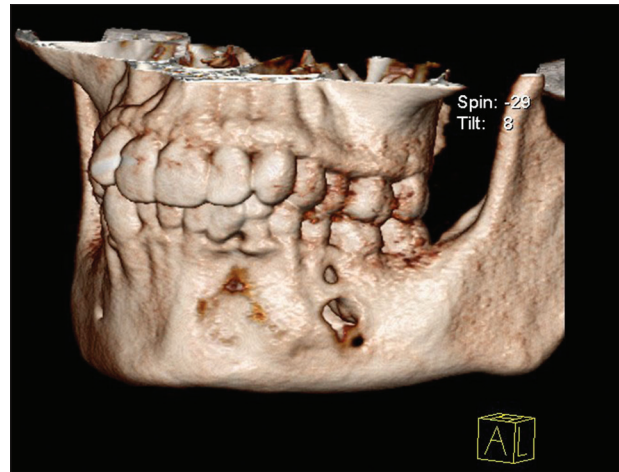
**Figure 1:** Orthopantogram showing Unilocular radiolucent lesion in left body of mandible

ameloblastoma and orthokeratinized OKC. Surgical enucleation of the lesion was done along with surgical removal of the impacted teeth [Figures 4 and 5]. Gross examination of the excised specimen revealed a thin cystic sac with luminal surface. The lumen also contained white cheesy material. Microscopic examination [Figures 6 and 7] of the specimen revealed an orthokeratinized stratified squamous epithelium of varying thickness lining a thin fibrous wall.

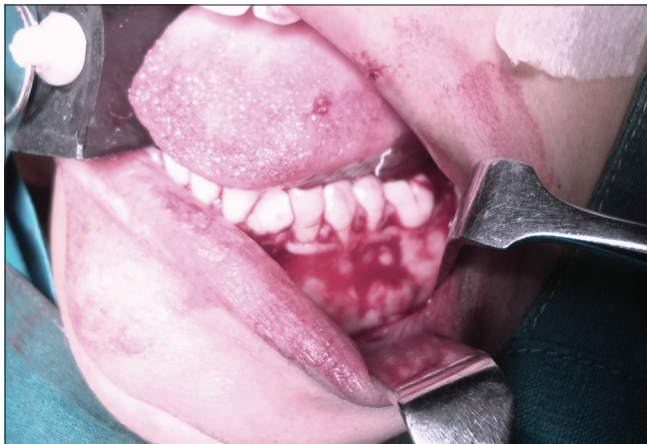



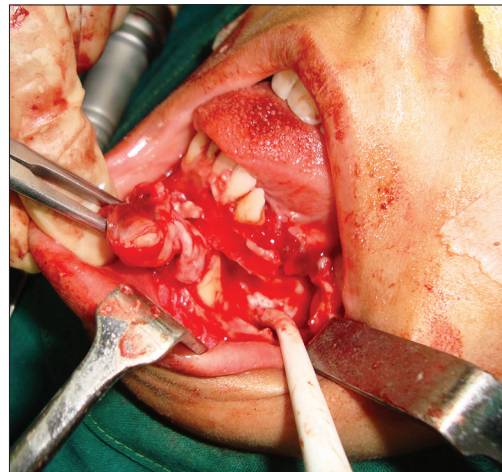
**Figure 2:** Computed tomography scan showed thinning and perforation of cortical plate



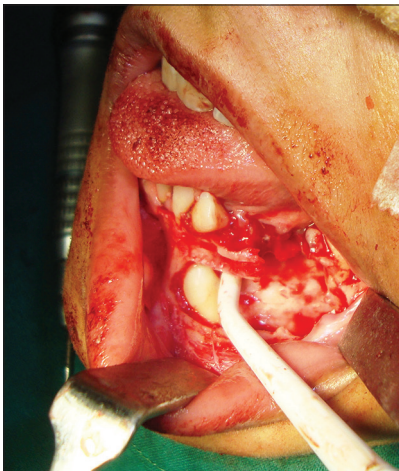
**Figure 3:** Three-dimensional computed tomography scan showed perforation of buccal cortical plate



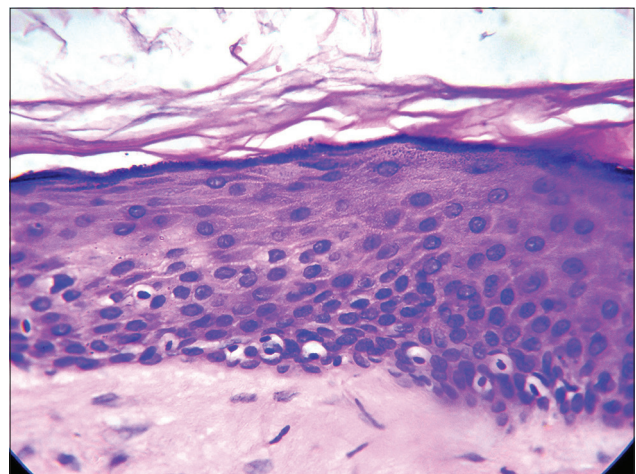
**Figure 4:** Preoperative photograph of the patient



**Figure 5:** Surgical removal of lesion



**Figure 6:** After surgical removal of lesion impacted teeth visible

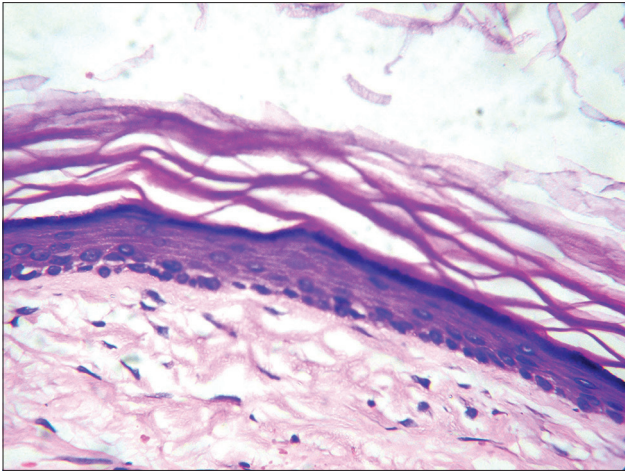


**Figure 7:** Histopathologic features showing orthokeratinized stratified squamous epithelium of varying thickness lining a thin fibrous wall

## DISCUSSION

Orthokeratinized odontogenic cyst usually occurs most often between third and fourth decades and with a male gender predilection.<sup>[7,11]</sup> In this case, 30-year-old

female was reported with OOC. In contrast to other studies, the lesion was located in the body of mandible, starting from lower left canine region involving lower



**Figure 8:** Histopathologic features showing orthokeratinized stratified squamous epithelium of varying thickness lining a thin fibrous wall

left premolars and lower left first molar. Swelling is the main clinical feature with or without pain in cases of OOC.<sup>[8]</sup> In the present case, patient was mild swelling with pain in lower left canine region.

Radiographically, the OOC appear as a radiolucent solitary lesion which frequently associated with impacted teeth with or without expansion and/ displacement of the inferior alveolar canal.<sup>[3]</sup> In this case, large expansile unilocular radiolucent lesion was present, which was associated with impacted canine along with perforation of buccal cortical plate.

Histologically, the cavity of OOC is lined by a uniform 4- to 9-cell layers thick regular stratified squamous epithelium, which showed a basal layer that exhibits palisade cuboidal or flat cells, with nuclear hyperchromatism. The intermediate layer is made up of polyhedral cells with eosinophilic cytoplasm with a thick superficial layer of orthokeratin. While KCOT shows of 5- to 10-cell layers thick epithelium with the basal cells lined with an elongated nucleus with the presence of a characteristic superficial corrugated layer of parakeratin.<sup>[16,17]</sup> In this case classical histologic features of OOC were present.

Other radiolucent lesions of the jaw differentiated from the OOC are mainly odontogenic lesions such as dentigerous cyst, unicystic ameloblastoma and KCOT. The OOC may appear as multilocular radiolucency in posterior mandible like the ameloblastoma and the KCOT, but OOC usually shows no root resorption of involved teeth, which is a characteristic feature of ameloblastoma.<sup>[7,10]</sup> KCOT can be differentiated from OOC on various features like older age group, more antero-posterior extension without expansion,

characteristic histopathological features different from OOC, parakeratinized layer, high recurrence rate, association with basal cell nervous syndrome.<sup>[1]</sup> Silva *et al.* and Onuki *et al.* in their study have reported OOC mimicking as periapical lesions. All radiolucent lesions should be sent for histopathological examination.<sup>[18,19]</sup>

Surgical excision of lesion conservatively with removal of involved teeth is the treatment of choice. Long-term follow-up of the lesion showed no remarkable recurrence. In this case also enucleation of the lesion was done with removal of associated teeth.<sup>[2]</sup>

Very limited information is present about orthokeratinizing odontogenic cyst due to very low prevalence rate and due to lack of specific clinical and radiographic features. Due to the similarity between OOC and the dentigerous cyst, numerous studies have been carried out to identify if there is any connection between a dentigerous cyst and an OOC. These data reveals that CK10 and CK17 expression is negative-to-weak in a dentigerous cyst, and moderate in OOC and KCOT. These two cytokeratins are expressed in the keratinized epithelium. CK18 and CK19, expressed in the non-keratinized epithelium are expressed in the dentigerous cyst and not in OOC or KCOT. CK7 and CK13, normally expressed by the dental lamina and enamel organ, are weakly positive in a dentigerous cyst, while OOC and KCOT show the expression of only CK13. This supports the view that KCOT and OOC may be derived from the dental lamina.<sup>[20,21]</sup> More research work is necessary in cases with OOC to find out etiopathogenesis and clinical-radiographic feature of this lesion. OOC should be considered always in the differential diagnosis of all the radiolucent lesions involving impacted teeth. This is a classic example of odontogenic lesion having clinic-radiographic features similar to dentigerous cyst diagnosed histopathologically as OOC.

## REFERENCES

1. Sandhu SV, Rao SK, Brar RS, Kakkar T. Orthokeratinized odontogenic cyst of the mandible: A case report. *Int J Oral Maxillofac Pathol* 2012;3:69-73.
2. Byatnal A, Natarajan J, Narayanaswamy V, Radhakrishnan R. Orthokeratinized odontogenic cyst-critical appraisal of a distinct entity. *Braz J Oral Sci* 2013;12:1-10.
3. González Galván Mdel C, García-García A, Anitua-Aldecoa E, Martínez-Conde Llamosas R, Aguirre-Urizar JM. Orthokeratinized odontogenic cyst: A report of three clinical cases. *Case Rep Dent* 2013;2013:672383.
4. Kotwaney S, Shetty P. Orthokeratinized odontogenic cyst: A milder variant of an odontogenic keratocyst. *Univers Res J Dent* 2013;3:101-3.



5. Pillai AK, Gupta MK, Mhaske SJ, Satpathy M, Singh SK. An aggressive orthokeratinized odontogenic cyst of the mandible: A case report. *IOSR J Dent Med Sci* 2013;12:45-8.
6. Swain N, Patel S, Poonja LS, Pathak J, Dekate K. Orthokeratinized odontogenic cyst. *J Contemp Dent* 2012;2:31-3.
7. Li TJ, Kitano M, Chen XM, Itoh T, Kawashima K, Sugihara K, *et al.* Orthokeratinized odontogenic cyst: A clinicopathological and immunocytochemical study of 15 cases. *Histopathology* 1998;32:242-51.
8. MacDonald-Jankowski DS, Li TK. Orthokeratinized odontogenic cyst in a Hong Kong community: The clinical and radiological features. *Dentomaxillofac Radiol* 2010;39:240-5.
9. P´erez Gonz´alez E, L´opez Labady J, Villarroel Dorrego M. Quiste odontog´enico ortoqueratinizado: Una nueva entidad derivada del queratoquiste odontog´enico. Revisi´on de la literatura. *Acta Odontol Venez* 2006;44:419-23.
10. Macdonald-Jankowski DS. Orthokeratinized odontogenic cyst: A systematic review. *Dentomaxillofac Radiol* 2010;39:455-67.
11. Dong Q, Pan S, Sun LS, Li TJ. Orthokeratinized odontogenic cyst: A clinicopathologic study of 61 cases. *Arch Pathol Lab Med* 2010;134:271-5.
12. Li TJ, Browne RM, Matthews JB. Quantification of PCNA + cells within odontogenic jaw cyst epithelium. *J Oral Pathol Med* 1994;23:184-9.
13. Li TJ, Browne RM, Matthews JB. Epithelial cell proliferation in odontogenic keratocysts: A comparative immunocytochemical study of Ki67 in simple, recurrent and basal cell naevus syndrome-associated lesions. *J Oral Pathol Med* 1995;24:221-6.
14. Senoo M, Pinto F, Crum CP, McKeon F. p63 Is essential for the proliferative potential of stem cells in stratified epithelia. *Cell* 2007;129:523-36.
15. Kulkarni M, Kheur S, Agrawal T, Ingle Y. Orthokeratinizing odontogenic cyst of maxilla with complex odontoma. *J Oral Maxillofac Pathol* 2013;17:480.
16. Shear M, Speight PM. Cyst of the Oral and Maxillofacial Regions. 4<sup>th</sup> ed.. Denmark: Blackwell, Munksgaard; 2007.
17. Philipsen HP. Keratocystic odontogenic tumour. In: Barnes EL, Eveson JW, Reichart P, Sidransky D, editors. *Pathology and Genetics of Head and Neck Tumors. World Health Organization Classification of Tumors.* Lyon, France: IARC Press; 2005. p. 306-7.
18. Onuki M, Saito A, Hosokawa S, Ohnuki T, Hayakawa H, Seta S, *et al.* A case of orthokeratinized odontogenic cyst suspected to be a radicular cyst. *Bull Tokyo Dent Coll* 2009;50:31-5.
19. Silva Servato JP, Cardoso SV, Parreira da Silva MC, Cordeiro MS, Rog´erio de Faria P, Loyola AM. Orthokeratinized odontogenic cysts presenting as a periapical lesion: Report of a case and literature review. *J Endod* 2014;40:455-8.
20. Thosaporn W, Iamaroon A, Pongsiriwet S, Ng KH. A comparative study of epithelial cell proliferation between the odontogenic keratocyst, orthokeratinized odontogenic cyst, dentigerous cyst and ameloblastoma. *Oral Dis* 2004;10:22-6.
21. Koizumi Y. Odontogenic keratocyst, orthokeratinized odontogenic cyst and epidermal cyst: An immunohistochemical study including markers of proliferation, cytokeratin and apoptosis related factors. *Int J Oral-Med Sci* 2004;2:14-22.

**How to cite this article:** Sarvaiya B, Vadera H, Sharma V, Bhad K, Patel Z, Thakkar M. Orthokeratinized odontogenic cyst of the mandible: A rare case report with a systematic review. *J Int Soc Prevent Communit Dent* 2014;4:71-6.

**Source of Support:** Nil, **Conflict of Interest:** None declared.