

## Assessment of retinal manifestations of Parkinson's disease using spectral domain optical coherence tomography: A study in Indian eyes

Shishir Verghese, Sean T Berkowitz<sup>1</sup>, Virna M Shah<sup>2</sup>, Parag Shah, Priya S<sup>2</sup>, Veerappan R Saravanan, Venkatapathy Narendran, V A Selvan<sup>3</sup>

**Purpose:** To assess the retinal manifestations of Parkinson's disease using optical coherence tomography. **Methods:** A prospective case-control study comparing 30 eyes from 15 patients with Parkinson's disease and 22 eyes from 11 healthy age-matched controls. Total macular subfield thickness and the thickness of the ganglion cell layer, nerve fiber layer, and peripapillary retinal nerve fiber layer were measured with spectral-domain optical coherence tomography (SD-OCT). **Results:** The mean age of PD patients was 68.4 years  $\pm$  10.64 (range: 46–82) and in the control group was 66.36  $\pm$  5.22 (range: 64–68). The average disease duration in patients with PD was 6.7  $\pm$  2.8 years (range: 2–10 years). The mean best-corrected visual acuity in PD was 20/26 and 20/20 in controls, with  $P = 0.0059$ , which was significant. Significant difference was also found in the contrast sensitivity between both groups. Structural differences in the central macular thickness ( $P = 0.0001$ ), subfield thicknesses in the superior ( $P = 0.003$ ), inferior ( $P = 0.001$ ), nasal ( $P = 0.004$ ), and temporal subfields ( $P = 0.017$ ) was seen. Severe thinning of the ganglion cell layer was seen in PD patients ( $P = 0.000$ ) as well as of the nerve fiber layer ( $P = 0.004$ ). Peripapillary retinal nerve fiber thickness measured showed significant thinning in superotemporal ( $P = 0.000$ ), superonasal ( $P = 0.04$ ), inferonasal ( $P = 0.000$ ), inferotemporal ( $P = 0.000$ ), nasal ( $P = 0.000$ ), and temporal quadrants ( $P = 0.000$ ). **Conclusion:** Visual dysfunction was observed in patients with PD along with structural alterations on OCT, which included macular volumes, ganglion cell layer, and peripapillary retinal nerve fiber layer.

**Key words:** Ganglion cell layer, Parkinson's disease, retinal nerve fiber layer, SD-OCT

The gold standard for Parkinson's disease (PD) diagnosis is expert clinical evaluation, with special attention to cardinal features of bradykinesia, tremor, rigidity, and postural instability, as well as clinical response to dopaminergic therapy. Global estimates of the prevalence of PD are variable, though estimates suggest roughly 6000 cases per 100,000, with a burden of roughly 3000 daily-adjusted life years (DALYs) per 100,000.<sup>[1]</sup>

Attempts to quantify disease burden such as the clinimetric assessment and the Movement Disorder Society-Sponsored Revision of the Unified Parkinson's Disease Rating Scale (MDS-UPDRS) are often used in clinical research.<sup>[2]</sup> However, early, reliable, objective biomarkers for Parkinson's disease presence and severity remain to be elucidated.

Parkinson's has a complex etiopathology influenced to varying degrees by genetics, exposures, and lifestyle factors, which complicate diagnostic clarity and epidemiologic studies.<sup>[3]</sup> In the past 20 years, alpha-synuclein, a filamentous protein, was found to be the predominant component of Lewy

Bodies and Lewy Neurites, the pathologic hallmarks of the disease.<sup>[4,5]</sup>

Misfolded and abnormal alpha-synuclein is believed to underly neurotoxic sequelae in dopaminergic neurons, contributing to cell loss in PD.<sup>[6]</sup> The progression of neuronal lesions in PD follows a well-studied progression beginning in the medulla oblongata and pontine tegmentum and progressing to the midbrain and higher cortical areas, which serves as the basis for post-mortem staging.<sup>[7]</sup>

Interestingly, the retina utilizes dopaminergic signaling via D1 and D2 receptors, which helps explain visual phenomena in Parkinson's disease.<sup>[8,9]</sup> While retinal neuro-architecture dysfunction related to changes in dopaminergic neuro-architecture has historically been explored via histologic analysis,<sup>[10]</sup> studies of living patients have not been possible until more recent, noninvasive optical coherence tomography (OCT) technology.<sup>[11]</sup> OCT being noninvasive has been utilized to assess the retinal neuro-architecture *in vivo*. OCT studies have become very prevalent in the

### Access this article online

#### Website:

www.ijo.in

#### DOI:

10.4103/ijo.IJO\_1409\_21

### Quick Response Code:



Departments of Retina and Vitreous and <sup>2</sup>Neuro Ophthalmology, Aravind Eye Hospital and Postgraduate Institute of Ophthalmology, <sup>3</sup>Department of Neurology, Kovai Medical College and Hospital, Coimbatore, Tamil Nadu, India, <sup>1</sup>Department of Ophthalmology, Vanderbilt University School of Medicine, Nashville, USA

**Correspondence to:** Dr. Shishir Verghese, Aravind Eye Hospital and Postgraduate Institute of Ophthalmology, Civil Aerodrome Post, Peelamedu, Coimbatore - 641 004, Tamil Nadu, India. E-mail: shishirverghese@gmail.com

Received: 25-May-2021

Revision: 21-Aug-2021

Accepted: 06-Oct-2021

Published: 27-Jan-2022

This is an open access journal, and articles are distributed under the terms of the Creative Commons Attribution-NonCommercial-ShareAlike 4.0 License, which allows others to remix, tweak, and build upon the work non-commercially, as long as appropriate credit is given and the new creations are licensed under the identical terms.

**For reprints contact:** WKHLRPMedknow\_reprints@wolterskluwer.com

**Cite this article as:** Verghese S, Berkowitz ST, Shah VM, Shah P, Priya S, Saravanan VR, *et al.* Assessment of retinal manifestations of Parkinson's disease using spectral domain optical coherence tomography: A study in Indian eyes. *Indian J Ophthalmol* 2022;70:448-52.

literature, with varying degrees of evidence for changes in retinal nerve fiber layer (RNFL) thickness,<sup>[12-14]</sup> ganglion cell layer (GCL) and plexiform layers,<sup>[15]</sup> and central macular thickness (CMT).<sup>[16]</sup> Despite the abundance of OCT studies in PD in various populations, the study of OCT changes in the Indian population is lacking.<sup>[17]</sup> Consequently, the investigation here sought to determine whether prior findings are replicable in the Indian population.

## Methods

This was a prospective case-control study conducted at the neuro-ophthalmology and retina outpatient departments of a tertiary eye care hospital for a period of 1 year between January 2018 and December 2019. The patients gave informed consent for the study. The study adhered to the tenets of the Declaration of Helsinki and was approved by the Ethics Committee of Kovai Medical College and Hospital affiliated to the Tamil Nadu Dr. MGR Medical University, Chennai. Fifteen patients with PD diagnosed using the Movement Disorder Society – Unified Parkinson's Disease Rating Scale (MDS – UPDRS) were recruited from the Neurology department of an adjacent multispecialty hospital. Eleven age-matched controls without PD as determined clinically were recruited for controls. Exclusion criteria included any preexisting ocular disorder, inability to follow instructions, presence of retinal pathology, or advanced motor dysfunction prohibiting OCT acquisition, and images with incomplete data. Patients received a comprehensive eye exam, including best-corrected visual acuity (BCVA), intraocular pressure with Goldman applanation tonometer, color vision (Ishihara) and contrast sensitivity (Mars contrast sensitivity test), central fields (Bjerrum screen), anterior and posterior segment evaluation by slit-lamp biomicroscopy, and dilated fundus evaluation. There was no difference between the two groups with relation to any ocular disease such as corneal or lens-related pathology or glaucomatous optic disc damage and even any systemic disease such as diabetes mellitus, hypertension, and lifestyle changes such as smoking. Spectral-domain optical coherence tomography (SD-OCT) was done using Heidelberg Engineering, Spectralis HRA after dilation. The OCT machine obtained separate reflexes of the polarized single-mode light from various layers of the retina, starting from the inner limiting membrane to the retinal pigment epithelial layer, analysis of which gave the thickness of the different retinal layers. The standard definition of the inner and outer retinal layers which has been stated by Hajee *et al.*<sup>[18]</sup> is clearly delineated by the standard color-coding in any modern OCT machine; the same was used for this study. This study focused on the inner retinal layer that reflected the nerve fiber changes, which are of interest. The macular thickness was also studied in three concentric circles of 1 mm (central macula), 3 mm, and 6 mm, respectively. The outer two circles were further divided into four sectors as superior (S), inferior (I), temporal (T), and nasal (N) by diagonal lines.

The total macular thickness from the central subfield as well as from the eight sectors was calculated. Using the segmentation software of the SD-OCT individual thickness of the Ganglion cell complex (GCC) and the nerve fiber layer (NFL) were obtained from the central subfield as well as from the eight sectors. SD-OCT was also done over the optic disc using the peripapillary retinal nerve fiber layer (RNFL) protocol, which utilized a circle grid composed of three circles of 1, 2.22, and

3.45-mm diameter centered on the optic disc. The circle grid allowed calculation of the retinal thickness at each diameter for the superior, inferior, temporal, and nasal sectors [Fig. 1]. Figure All SD-OCT scans were obtained by the same operator who ensured that the scan quality, indicated by a horizontal bar turning red in the presence of poor signal strength, was always under acceptable limits during scan acquisition. For statistical analysis, Snellen's BCVA was converted to logarithm of the minimum angle of resolution (log MAR). All the data was entered in an excel spreadsheet and statistical analysis was performed using SPSS 20.0 statistical software (SPSS Inc., Chicago Illinois, USA). Average values for each parameter were compared using Student's *t* test and Mann-Whitney's U test. Regional values not captured on OCT were excluded from the analysis.

## Results

This prospective study included 30 eyes of 15 patients with PD (11 males and 4 females), which constituted the cases, and 22 eyes of 11 normal patients (7 male and 4 females), which were controls. The mean age in the PD group was 68.4 years  $\pm$  10.64 (range: 46–82) and in the control group was 66.36  $\pm$  5.22 (range: 64–68). The average disease duration in patients with PD was 6.7  $\pm$  2.8 years (range: 2–10 years). The mean best-corrected visual acuity in PD was 20/26 and 20/20 in controls ( $P = 0.0059$ ). The anterior segment, intraocular pressure, and fundus appearance were within normal limits in both cases and controls. Nine patients in the PD group had impaired color vision as compared to controls where none of the patients had impaired color vision. The mean contrast sensitivity was significantly reduced in patients with PD as compared to controls ( $P = 0.012$ ).

### Central macular thickness

The mean central macular thickness in the PD group was 221.6  $\pm$  6.93  $\mu$  (range: 209–233  $\mu$ ), whereas in controls, it was 255.86  $\pm$  25.31  $\mu$  (range: 204–289  $\mu$ ), which was statistically significant ( $P = 0.0001$ ).

### Macular subfield thickness

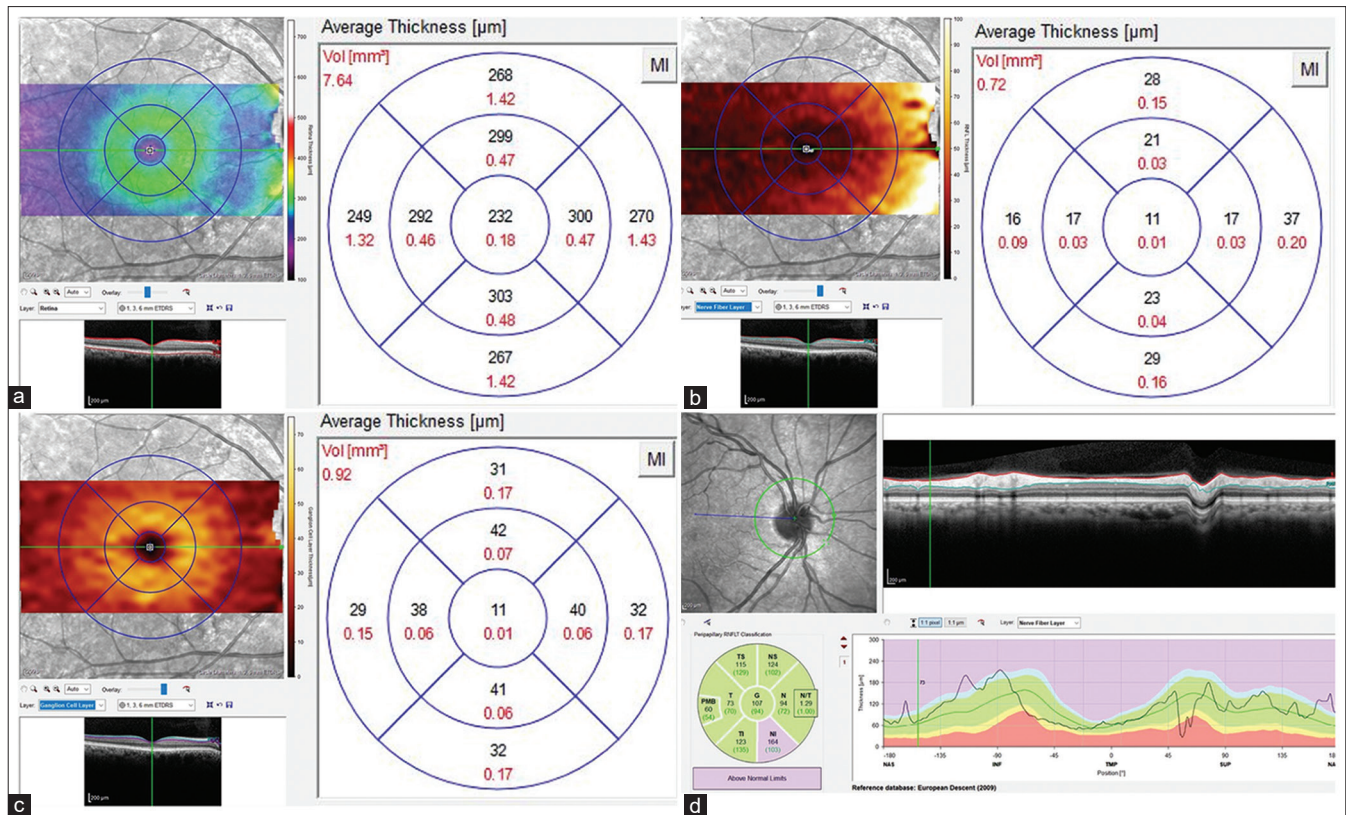
Statistically significant reduced mean subfield thickness was found in the superior (311  $\pm$  9.69  $\mu$  vs. 327  $\pm$  21.19  $\mu$ ;  $P = 0.003$ ) inferior (306  $\pm$  12.97  $\mu$  vs. 328  $\pm$  23.06  $\mu$ ;  $P = 0.001$ ), nasal (318.86  $\pm$  14.58  $\mu$  vs. 331.5  $\pm$  21.0  $\mu$ ;  $P = 0.004$ ), and temporal subfields (304.33  $\pm$  21.5  $\mu$  vs. 321.40  $\pm$  17.84  $\mu$ ;  $P = 0.0172$ ) in the PD group as compared to normal subjects.

### Ganglion cell thickness

Significant differences in the mean ganglion cell thickness in the central (10.06  $\pm$  1.48  $\mu$  vs. 13.09  $\pm$  1.54  $\mu$ ;  $P = 0.000$ ) as well as superior (42.06  $\pm$  3.01  $\mu$  vs. 48.09  $\pm$  5.63  $\mu$ ;  $P = 0.000$ ), inferior (42.46  $\pm$  4.59  $\mu$  vs. 47.59  $\pm$  6.14  $\mu$ ;  $P = 0.008$ ), nasal (42.36  $\pm$  1.71  $\mu$  vs. 48.77  $\pm$  3.72  $\mu$ ;  $P = 0.000$ ), and temporal subfields (38.7  $\pm$  4.22  $\mu$  vs. 44.59  $\pm$  4.64  $\mu$ ;  $P = 0.000$ ) were seen between both groups with significantly less thickness in the PD group.

### Nerve fiber layer thickness

Significant differences in the mean nerve fiber layer thickness in the central (9.9  $\pm$  1.84  $\mu$  vs. 11.86  $\pm$  2.86  $\mu$ ;  $P = 0.004$ ) as well as superior (20.13  $\pm$  2.01  $\mu$  vs. 22.68  $\pm$  1.78  $\mu$ ;  $P = 0.000$ ), inferior (42.46  $\pm$  4.59  $\mu$  vs. 47.59  $\pm$  6.14  $\mu$ ;  $P = 0.008$ ),



**Figure 1:** Image showing the acquisition of central and subfield retinal thickness as well as retinal nerve fiber layer (RNFL) thickness using spectral-domain optical coherence tomography (SD-OCT) (a) Measurement of the central macular thickness as well as the ganglion cell layer (GCL) thickness; (b) Measurement of nerve fiber layer (NFL) thickness centrally at the fovea as well as macular subfield; (c) Measurement of ganglion cell layer (GCL) thickness centrally at the fovea as well as macular subfield; (d) RNFL thickness measurement using optic disc scan protocol

nasal ( $21.93 \pm 3.05 \mu$  vs.  $24.72 \pm 4.69 \mu$ ;  $P = 0.005$ ) and temporal subfields ( $16.06 \pm 1.63 \mu$  vs.  $19.31 \pm 4.35 \mu$ ;  $P = 0.001$ ) were seen between both groups with significantly less thickness in the PD group.

#### Peripapillary retinal nerve fiber layer thickness

RNFL thickness over the optic disc was measured in the temporal, nasal, superotemporal, superonasal, and inferotemporal quadrants. An average RNFL thickness was also obtained. Significant differences in the mean RNFL thickness in the superotemporal ( $113 \pm 12.31 \mu$  vs.  $141.59 \pm 11.41 \mu$ ;  $P = 0.000$ ) as well as superonasal ( $108.3 \pm 15.03 \mu$  vs.  $116.18 \pm 10.35 \mu$ ;  $P = 0.04$ ), inferotemporal ( $106.96 \pm 3.62 \mu$  vs.  $130.04 \pm 15.66 \mu$ ;  $P = 0.000$ ), inferonasal ( $104.8 \pm 13.68 \mu$  vs.  $121.59 \pm 10.99 \mu$ ;  $P = 0.000$ ), temporal RNFL ( $62.53 \pm 5.68 \mu$  vs.  $82.81 \pm 9.45 \mu$ ;  $P = 0.000$ ) and nasal RNFL ( $67.76 \pm 5.27 \mu$  vs.  $82.68 \pm 9.13 \mu$ ;  $P = 0.000$ ) were seen to be significantly of less thickness in the PD group. The average RNFL thickness was significantly reduced in the PD group ( $95.5 \pm 7.04 \mu$  vs.  $106.6 \pm 6.28 \mu$ ;  $P = 0.000$ ) as compared to normal subjects.

## Discussion

OCT has become a fast and noninvasive tool for generating cross-sectional images of the retina *in vivo*, is reliable for quantitative assessment of the peripapillary RNFL thickness, and has been used for diagnosing as well as following up patients with various neurodegenerative diseases such as optic neuritis, multiple sclerosis, migraine, and Alzheimer's

disease.<sup>[12]</sup> Reduced RNFL thickness on OCT could act as a valuable biomarker for evaluating progressive RNFL thinning over time in these neurodegenerative disorders.<sup>[12]</sup>

PD is a commonly encountered disease among the aging population, with the accuracy of clinical diagnosis being limited. With the value of RNFL examination as a method of detecting neurodegenerative disease progression and facilitating diagnosis of disease, the aim of our study was to evaluate functional and structural OCT changes in PD patients. Strong differences between PD and healthy controls were identified in this minimally powered study.

In our study, patients with PD had reduced visual acuity and contrast sensitivity as compared to controls, which could not be attributed to any other ocular cause. This was similar to previous reports which showed declining visual acuity in patients with increased severity of the disease.<sup>[19]</sup> Deficits in visual acuity, color, and contrast sensitivity are at least partly due to retinal dopamine deficiency in patients with PD as they have reduced dopamine innervations around the fovea.<sup>[20]</sup> In a study by Kaur *et al.*<sup>[21]</sup> there was no significant difference in visual acuity in patients with PD; however, they found contrast sensitivity to be significantly reduced in PD patients. Our study found significantly reduced central macular thickness as well as of the four macular subfields and in the peripapillary RNFL. Additionally, GCL and NFL were analyzed using the segmentation protocol of our Heidelberg Spectralis SD-OCT and we found significantly reduced thickness for the same.

Multiple other studies have similarly analyzed the structural parameters of OCT.

Sengupta *et al.*<sup>[17]</sup> studied 34 patients with PD and 50 healthy age-match controls with OCT, finding significantly thinner RNFL thickness in PD patients, and diminished macular volumes correlating with disease severity. Hajee *et al.*<sup>[18]</sup> demonstrated thinning of the inner ganglion complex (as defined by the specific OCT manufacturer) in PD patients using autosegmentation OCT scans. Altıntaş *et al.*<sup>[22]</sup> in their study examined 17 PD and 11 controls and reported reduced mean RNFL thicknesses in all quadrants except at the 8 o'clock position in comparison to control subjects. Kirbas *et al.*<sup>[23]</sup> studied 42 PD patients and found similar differential hemiretinal thinning of the temporal retina. Moschos *et al.*<sup>[24]</sup> had corroborative findings in their study on 16 PD patients; however, in addition to the temporal hemiretina, they found differential thinning in the inferior quadrant too. These findings were corroborated despite unclear medication effects and the small patient cohort with heterogeneous disease severity. Aaker *et al.*<sup>[16]</sup> in their study on patients found significant differences in three of the nine macular subfields but no changes in the inner retinal layer and peripapillary RNFL thickness. Kaur *et al.*<sup>[21]</sup> in their study found that GCL-IPL alterations were a sensitive indicator of structural alterations in patients with PD. A meta-analysis done on patients with PD showed a generalized RNFL thinning in all quadrants similar to our study.<sup>[12]</sup> Shrier *et al.*<sup>[25]</sup> also reported foveal thinning in PD patients which was more apparent at an annular zone between 0.5 mm and 2 mm from the fovea. Our study also showed central macular thinning in PD as compared to controls.

Dopamine has been postulated to control the efficiency of some neurochemical systems such as glutamate, gamma-aminobutyric acid (GABA), and glycine in the retino-optic pathway, including amacrine cells in the retina, lateral geniculate body, and the occipital cortex.<sup>[12]</sup> Dysfunction that results from dopamine depletion which is controlled by amacrine cells is affected in PD and this, in turn, may cause long-term complex synaptic effects.<sup>[17]</sup> The RNFL represents axons of the ganglion cells and impoverished dopaminergic input to the ganglion cells contributes to abnormal glutamate production, which leads to atrophy of these selected fibers, which reflects as RNFL thinning. This could explain the reduced GCL and RNFL thickness seen in our study.

Visual deficits are common in patients with PD and include abnormal contrast sensitivity, motion perception abnormalities, impaired visual acuity and color vision, and visual hallucinations; however, the exact loci of impairment remain unclear.<sup>[12]</sup> Our cohort of PD patients had reduced vision as well as a reduced contrast as compared to normal subjects. Visual impairment in PD has also been postulated due to dopaminergic loss in the retina. Retinal dopamine deficiency alters visual processing by modification of receptive-field properties of ganglion cells. Ultimately, this study allows for interesting hypothesis generation regarding OCT findings in Parkinsonism.

Some of the limitations of our study include small sample size, lack of inclusion of PD severity, effects of anti-Parkinson drugs and Parkinson-like syndromes as well as adjunct investigations such as Humphery visual field perimetry, pattern visual evoked potentials, or multifocal electroretinography,

which can help in augmenting the predictive power of OCT biomarkers for neurodegeneration. In addition, patients with severe disease for whom an OCT acquisition was difficult were excluded and hence this study may not really reflect the OCT changes in all patients with PD.

## Conclusion

In conclusion, the results of our study showed a reduction in macular thickness, GCL, NFL, and peripapillary RNFL in all quadrants as compared to healthy controls. In view of these results and the noninvasive nature of OCT, we recommend the use of OCT for detecting PD as well as evaluating disease progression.

## Financial support and sponsorship

Nil.

## Conflicts of interest

There are no conflicts of interest.

## References

1. GBD 2016 Neurology Collaborators. Global, regional, and national burden of neurological disorders, 1990-2016: A systematic analysis for the Global Burden of Disease Study 2016. *Lancet Neurol* 2019;18:459-80.
2. Goetz CG, Tilley BC, Shaftman SR, Stebbins GT, Fahn S, Martinez-Martin P, *et al.* Movement Disorder Society-sponsored revision of the Unified Parkinson's Disease Rating Scale (MDS-UPDRS): Scale presentation and clinimetric testing results. *Mov Disord Off J Mov Disord Soc* 2008;23:2129-70.
3. Wirdefeldt K, Adami H-O, Cole P, Trichopoulos D, Mandel J. Epidemiology and etiology of Parkinson's disease: A review of the evidence. *Eur J Epidemiol* 2011;26(Suppl 1):S1-58.
4. Goedert M. Alpha-synuclein and neurodegenerative diseases. *Nat Rev Neurosci* 2001;2:492-501.
5. Baba M, Nakajo S, Tu PH, Tomita T, Nakaya K, Lee VM, *et al.* Aggregation of alpha-synuclein in Lewy bodies of sporadic Parkinson's disease and dementia with Lewy bodies. *Am J Pathol* 1998;152:879-84.
6. Recchia A, Debetto P, Negro A, Guidolin D, Skaper SD, Giusti P. Alpha-synuclein and Parkinson's disease. *FASEB J Off Publ Fed Am Soc Exp Biol* 2004;18:617-26.
7. Braak H, Del Tredici K, Rüb U, de Vos RAI, Jansen Steur ENH, Braak E. Staging of brain pathology related to sporadic Parkinson's disease. *Neurobiol Aging* 2003;24:197-211.
8. Witkovsky P. Dopamine and retinal function. *Doc Ophthalmol Adv Ophthalmol* 2004;108:17-40.
9. Archibald NK, Clarke MP, Mosimann UP, Burn DJ. The retina in Parkinson's disease. *Brain J Neurol* 2009;132:1128-45.
10. Nguyen-Legros J. Functional neuroarchitecture of the retina: Hypothesis on the dysfunction of retinal dopaminergic circuitry in Parkinson's disease. *Surg Radiol Anat* 1988;10:137-44.
11. Huang D, Swanson EA, Lin CP, Schuman JS, Stinson WG, Chang W, *et al.* Optical coherence tomography. *Science* 1991;254:1178-81.
12. Yu J, Feng Y, Xiang Y, Huang J, Savini G, Parisi V, *et al.* Retinal nerve fiber layer thickness changes in Parkinson disease: A meta-analysis. *PLoS One* 2014;9:e85718.
13. Inzelberg R, Ramirez JA, Nisipeanu P, Ophir A. Retinal nerve fiber layer thinning in Parkinson disease. *Vision Res* 2004;44:2793-7.
14. Jiménez B, Ascaso FJ, Cristóbal JA, López del Val J. Development of a prediction formula of Parkinson disease severity by optical coherence tomography: Prediction of PD severity by OCT. *Mov Disord* 2014;29:68-74.

15. Albrecht P, Müller A-K, Südmeyer M, Ferrea S, Ringelstein M, Cohn E, *et al.* optical coherence tomography in Parkinsonian syndromes. *PLoS One* 2012;7:e34891.
16. Aaker GD, Myung JS, Ehrlich JR, Mohammed M, Henchcliffe C, Kiss S. Detection of retinal changes in Parkinson's disease with spectral-domain optical coherence tomography. *Clin Ophthalmol* 2010;4:1427-32.
17. Sengupta P, Dutta K, Ghosh S, Mukherjee A, Pal S, Basu D. Optical coherence tomography findings in patients of Parkinson's disease: An Indian perspective. *Ann Indian Acad Neurol* 2018;21:150-5.
18. Hajee ME, March WF, Lazzaro DR, Wolintz AH, Shrier EM, Glazman S, *et al.* Inner retinal layer thinning in Parkinson disease. *Arch Ophthalmol Chic Ill* 1960 2009;127:737-41.
19. Biousse V, Skibell BC, Watts RL, Loupe DN, Drews-Botsch C, Newman NJ. Ophthalmologic features of Parkinson's disease. *Neurology* 2004;62:177-80.
20. Weil RS, Schrag AE, Warren JD, Crutch SJ, Lees AJ, Morris HR. Visual dysfunction in Parkinson's disease. *Brain* 2016;139:2827-43.
21. Kaur M, Saxena R, Singh D, Behari M, Sharma P, Menon V. Correlation between structural and functional retinal changes in Parkinson disease. *J Neuroophthalmol* 2015;35:254-8.
22. Altıntaş O, Işeri P, Ozkan B, Çağlar Y. Correlation between retinal morphological and functional findings and clinical severity in Parkinson's disease. *Doc Ophthalmol Adv Ophthalmol* 2008;116:137-46.
23. Kirbas S, Turkyilmaz K, Tufekci A, Durmus M. Retinal nerve fiber layer thickness in Parkinson disease. *J Neuro-Ophthalmol Off J North Am Neuro-Ophthalmol Soc* 2013;33:62-5.
24. Moschos MM, Tagaris G, Markopoulos I, Margetis I, Tsapakis S, Kanakis M, *et al.* Morphologic changes and functional retinal impairment in patients with Parkinson disease without visual loss. *Eur J Ophthalmol* 2011;21:24-9.
25. Shrier EM, Adam CR, Spund B, Glazman S, Bodis-Wollner I. Interocular asymmetry of foveal thickness in parkinson disease. *J Ophthalmol* 2012;2012:1-6. doi: 10.1155/2012/728457.