

This is an Open Access article licensed under the terms of the Creative Commons Attribution-NonCommercial-NoDerivs 3.0 License ([www.karger.com/OA-license](http://www.karger.com/OA-license)), applicable to the online version of the article only. Distribution for non-commercial purposes only.

# Tic Disorder: An Unusual Presentation of Neurotoxoplasmosis in a Patient with AIDS

Camila Catherine Henriques Aquino  
André Carvalho Felício Clecio Godeiro-Junior  
Denizart Santos-Neto José Luiz Pedroso  
Acary Souza Bulle Oliveira Sônia Maria Azevedo Silva  
Vanderci Borges Henrique Ballalai Ferraz

Department of Neurology and Neurosurgery, Federal University of São Paulo, São Paulo, Brazil

## Key Words

AIDS · Movement disorders · Neurotoxoplasmosis · Tic disorder

## Abstract

Movement disorders have been increasingly recognized in patients with HIV infection and may be due to distinct causes, as opportunistic infections or medication side effects for example. Parkinsonism, tremor and hemichorea have been more frequently noted in association with HIV and opportunistic infections. However, a variety of involuntary movements have already been described. We report a case of neurotoxoplasmosis in a patient with HIV infection who presented with a dystonic tic involving ocular, oral and cervical movements.

## Introduction

In patients with human immunodeficiency virus (HIV) infection, neurological involvement is a common occurrence, possibly due to chronic immunosuppression and consequent opportunistic infections, direct neurotropic effects of HIV or even medication side effects [1].

Movement disorders have been increasingly recognized and may appear as first symptoms of HIV or opportunistic infections. Clinically relevant movement disorders were identified in 3% of the patients with acquired immunodeficiency syndrome (AIDS)

in a tertiary referral center, and, during a prospective follow-up, 50% of these patients developed tremor, parkinsonism or other extrapyramidal features [2].

The exact frequency of these disorders has not been clearly established. Some studies report hemichorea-hemiballism as the most frequent abnormal movement in HIV patients [3, 4]; however, it has also been described as the second abnormal movement after tremor and parkinsonism [5].

Herein, we present a case of a woman who presented with a tic disorder which contributed to the diagnosis of HIV infection and neurotoxoplasmosis.

### Case Report

A 30-year-old woman presented with a 3-month history of headache, vomiting and weight loss followed by clumsiness of her right arm and leg. One week before admission, uncontrollable movements of the neck started, which interfered with her activities. General physical examination disclosed oral candidiasis and a herpes zoster scar on the left T8–T10 dermatomes. Neurological examination showed mild pyramidal signs on the right side and upward gaze palsy. Stereotypic slow movements of the head with rotation to the right side were noted, causing an abnormal posture, accompanied by right deviation of gaze and mouth opening like a yawn (online suppl. video 1, [www.karger.com/doi/10.1159/000322185](http://www.karger.com/doi/10.1159/000322185)). This movement disorder was preceded by a premonitory urge, with discomfort on the neck, which was relieved by cervical rotation. If asked to volitionally suppress this movement, it could be done for few seconds but would become worse later on.

Her brain CT and MRI showed bilateral basal ganglion granuloma using peripheral contrast enhancement and edema, which were suggestive of cerebral toxoplasmosis ([fig. 1](#)). HIV ELISA and Western blot were positive. CD4+ count was 28 cells/μl. Electroencephalogram recordings were normal, even during her abnormal movements. A routine blood sample revealed only positive anti-HCV serology.

Due to the clinical and complementary data, she was diagnosed with cerebral toxoplasmosis associated with HIV and hepatitis C virus infection. She was treated with sulfadiazine, pyrimethamine and folinic acid for 6 weeks, with partial clinical and radiological improvement.

In spite of the treatment, the involuntary movement persisted. It was interpreted as a complex dystonic tic involving the cervical, extraocular and oral musculature, occurring secondary to toxoplasmosis lesions involving the basal ganglia. Treatment was started with risperidone 1 mg/day, with full remission of her tic symptoms within 7 days.

### Discussion

The aim of this report was to present a tic disorder, a rare occurrence in patients with HIV, highlighting that abnormal movements can give an important clue to HIV diagnosis or its complications, if recognized. Differential diagnosis is not easy, demanding subsidiary examinations and careful evaluation of the movement disorder phenomenology. Cervical dystonia is the most common form of focal dystonia [6]. Dystonia has been rarely reported in patients with AIDS [7, 8], although it has been hypothesized that there are dopamine-related changes in patients with HIV infection that could increase the susceptibility to develop dystonia [9]. Factor et al. [8] reported 4 patients with dystonia and AIDS due to different causes, e.g. multifocal leukoencephalopathy, toxoplasmosis and drugs. The movement disorder of our patient resembled cervical dystonia, but the simultaneous oral and ocular movements,

premonitory feelings and partial voluntary suppression of movements were against this hypothesis.

In our case, stereotypes were also considered for differential diagnosis especially due to the partial voluntary suppression of symptoms that the patient achieved, but there was a premonitory urge suggestive of tic disorder. Most cases of stereotypes are simple, with rocking, hugging, self-touching, patting, grunting, foot tapping, leg swinging and hair pulling [10]. Stereotypes are more common in children, mainly in the context of autism or other hereditary diseases, or even secondary to some drugs. The presence of this movement disorder has not been reported in patients with brain infections.

Paroxysmal dyskinesias can be dystonic or choreic, and occur suddenly and transiently in the absence of an altered level of consciousness, with complete recovery between attacks. There are few reports on this movement disorder in HIV patients [11]. It can be associated with neuronal injury and loss in the basal ganglia, but the exact mechanism has not been determined yet. In a series of 6 seropositive patients with paroxysmal dyskinesia, it was attributed to primary HIV infection or HIV-associated dementia [12]. It was not considered in this case, since the movement disorder was continuous, lacking a remission period.

Tics are involuntary movements induced either by an inner sensory stimulus, like needing to stretch a body part, or by an unwanted feeling or compulsion. They are characterized by sudden, often repetitive, movements, gestures and utterances that mimic fragments of normal behavior and are typically present in Tourette's syndrome. Tics may be classified as simple or complex, and as tonic, clonic or dystonic, according to their velocity and muscle contraction, isometric and isotonic [13]. They may resemble a number of movement disorders even of psychogenic nature. Its phenomenology, however, may help in the diagnosis, if carefully obtained.

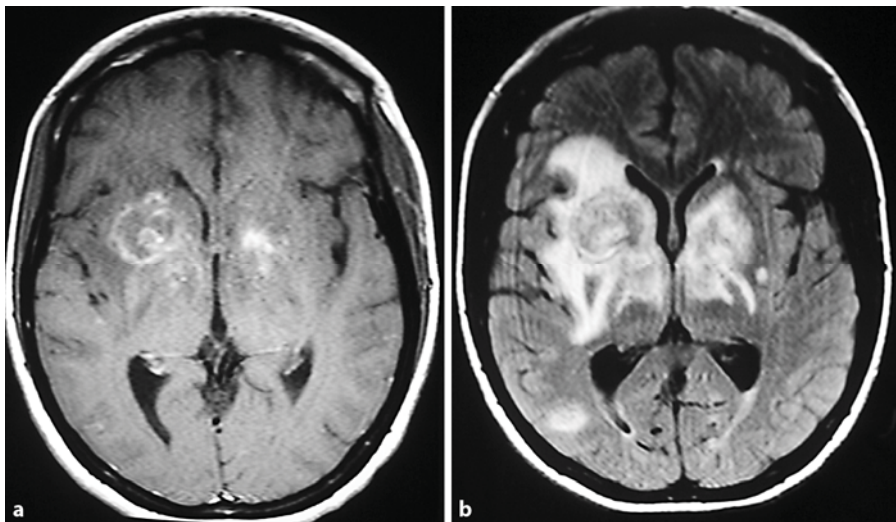
Studies concerning the pathogenesis of tics have been mainly directed to Tourette's syndrome, and most of them point to an abnormality in frontal-subcortical pathways, which possibly causes a decreased inhibition of the motor cortex, but the exact mechanisms are still unknown. Preliminary functional MRI studies have shown significant changes in signal intensity in basal ganglia and thalamus, as well as in connected cortical regions. A hypothesis attributing tic pathophysiology to neurotransmitters pointed to a distinct level of dopaminergic changes, such as dopamine hyperinnervation, presynaptic dopa decarboxylase abnormality or even a postsynaptic involvement of the dopamine receptor. On the other hand, those dopamine abnormalities would not be sufficient to explain Tourette's syndrome, and many authors also ascribe serotonin a possible role [14].

A summary of the results of those theories and studies converge to the fact that tics are related to cortical-striato-thalamo-cortical circuits, with decreased inhibition of the cortex. Previously, cases of tics or tourettism have been reported in the context of focal lesions, e.g. tumors involving basal ganglia and also multiple sclerosis lesions [15, 16]. The diagnosis reached after excluding the aforementioned differential diagnoses and considering the topography of lesions was dystonic tic. We believe that toxoplasma granulomas and perilesional edema involving basal ganglia can explain this movement disorder. Tic disorder was previously reported in the context of HIV infection in a patient with encephalopathy and transient motor and vocal tics [14].

In conclusion, treating physicians should be aware that abnormal movements – even tics – may be a potential source for misdiagnosis in HIV patients and that the correct identification of the movement disorder supplemented with subsidiary examinations ruling out other differential diagnoses helps to establish the diagnosis and improve therapeutic outcomes.

### Acknowledgment

We thank the infectious disease team from the Federal University of São Paulo for their assistance.



**Fig. 1.** **a** Brain MRI (T<sub>1</sub>-weighted image) shows a solid lesion of the right striatum and a smaller lesion of the left internal capsule (with gadolinium enhancement) and peripheral edema. **b** Fluid attenuation inversion recovery reveals bilateral lesions and edema (larger on the right side) compromising striatum, pallidus and thalamus.

### References

- 1 Weisberg LA: Neurologic abnormalities in human immunodeficiency virus infection. *South Med J* 2001;94:266–275.
- 2 Cardoso F: HIV-related movement disorders: epidemiology, pathogenesis and management. *CNS Drugs* 2002;16:663–668.
- 3 Piccolo I, Causarano R, Sterzi R, et al: Chorea in patients with AIDS. *Acta Neurol Scand* 1999;100:332–336.
- 4 Iranzo A, Kulisevsky J, Cadafalch J, Serrano C, Grau JM: Movement disorders and AIDS. *Neurologia* 1996;11:70–75.
- 5 Mattos JP, Rosso AL, Correa RB, Novis SA: Movement disorders in 28 HIV-infected patients. *Arq Neuropsiquiatr* 2002;60:525–530.
- 6 Dauer WT, Burke RE, Greene P, Fahn S: Current concepts on the clinical features, aetiology, and management of idiopathic cervical dystonia. *Brain* 1998;121:547–560.

- 7 Tse W, Cersosimo MG, Gracies JM, Morgello S, Olanow CW, Koller W: Movement disorders and AIDS: a review. *Parkinsonism Relat Disord* 2004;10:323–334.
- 8 Factor SA, Troche-Panetto M, Weaver SA: Dystonia in AIDS: report of four cases. *Mov Disord* 2003;18:1492–1498.
- 9 Hollander H, Golden J, Mendelson T, Cortland D: Extrapramidal symptoms in AIDS patients given low-dose metoclopramide or chlorpromazine. *Lancet* 1985;ii:1186.
- 10 Friedman JH: Stereotypy and catatonia; in Jankovic J, Tolosa E (eds): *Parkinson's Disease and Movement Disorders*. Philadelphia, Lippincott Williams & Wilkins, 2007, pp 468–480.
- 11 Nath A, Jankovic J, Pettigrew LC: Movement disorders and AIDS. *Neurology* 1987;37:37–41.
- 12 Mirsattari SM, Berry ME, Holden JK, Ni W, Nath A, Power C: Paroxysmal dyskinesias in patients with HIV infection. *Neurology* 1999;52:109–114.
- 13 Jankovic J: Tics and Tourette's syndrome; in Jankovic J, Tolosa E (eds): *Parkinson's Disease and Movement Disorders*. Philadelphia, Lippincott Williams & Wilkins, 2007, pp 356–375.
- 14 Singer HS: Current issues in Tourette syndrome. *Mov Disord* 2000;15:1051–1063.
- 15 Luat AF, Behen ME, Juhász C, Sood S, Chugani HT: Secondary tics or tourettism associated with a brain tumor. *Pediatr Neurol* 2009;41:457–460.
- 16 Nociti V, Fasano A, Bentivoglio AR, et al: Tourettism in multiple sclerosis: a case report. *J Neurol Sci* 2009;287:288–290.
- 17 McDaniel JS, Summerville MB: Tic disorder associated with encephalopathy in advanced HIV disease. *Gen Hosp Psychiatry* 1994;16:298–300.